



# Laparoscopic complete mesocolic excision for cancer of the right colon

Zhidong Gao, Kewei Jiang

Department of Gastrointestinal Surgery, Peking University People's Hospital, Beijing 100044, China

Correspondence to: Kewei Jiang. Department of Gastrointestinal Surgery, Peking University People's Hospital, Beijing 100044, China.

Email: jiangkewei@pkuph.edu.cn.

**Abstract:** Complete mesocolic excision (CME) is a high-quality colon radical surgery, which follows fine surgical dissection and precise surgical concept. Laparoscopic CME combines the above advantages theoretically, while it is still in the early stages of application for the higher quality requirements and longer learning curve of CME. The current literatures suggested that laparoscopic CME could be achieved the same effect with the open for colon cancer. However in order to maximize patient benefits, laparoscopic CME needs more strict indications. Compared with the left colon, transverse colon, right colon resection specimens are of higher quality. So the right colon cancer is more suitable for laparoscopic CME. This article will describe the procedure of laparoscopic CME of the right colon step by step.

**Keywords:** Complete mesocolic excision (CME); laparoscopy; right colon cancer

Received: 16 March 2017; Accepted: 30 March 2017; Published: 26 April 2017.

doi: 10.21037/jxym.2017.04.05

View this article at: <http://dx.doi.org/10.21037/jxym.2017.04.05>

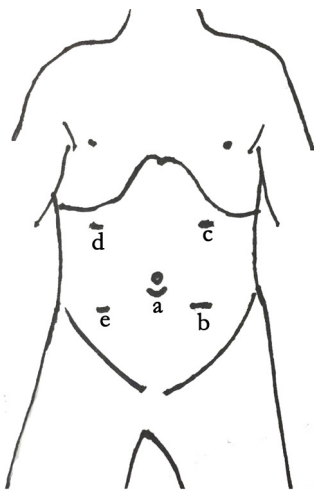
Because of minor injuries and rapid postoperative recovery, laparoscopic technique had been developed rapidly and used widely in colorectal surgery since the 1990s. Moreover, National Comprehensive Cancer Network (NCCN) had confirmed the feasibility of laparoscopic colectomy in 2008. Complete mesocolic excision (CME) is a high-quality radical surgery for colon cancer, which follows fine surgical dissection and precise surgical concept. NCCN had recommended it as a standardized surgical procedure for locally advanced colon cancer. Laparoscopic CME combines the above advantages theoretically, while it is still in the early stages of application for the higher quality requirements and longer learning curve of CME.

Laparoscopic right hemicolectomy is mainly used for cecal and ascending colon cancer. The patients were placed in supine position after the administration of general anesthesia. Using a five-port technique (*Figure 1*), the operator and camera operator stood on the left and the assistant on the other side.

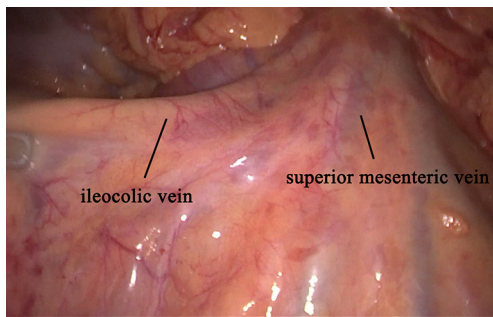
The abdominal cavity was explored carefully. There were three approaches for laparoscopic colectomy: medial to lateral approach (medial approach), lateral to

medial approach (lateral approach), and hybrid approach. The medial approach are thought to be due to decrease manipulation of the cancer, and reduce the vessel-related complication rate for prior division of vessels (1-3). As the initial step for the medial approach, the dissection started at ileocolic vessel (see *Figure 2*) and proceeded along superior mesenteric vein (SMV) (*Figure 3*). The ileocolic artery and vein were ligated at the root with clips (*Figure 4*), and the dissection continued upward to the right colic artery and vein, and the gastrocolic venous trunk (Henle trunk). The colic branch was transected, while the pancreatic and gastric branches were preserved. Hereafter the middle colic artery was exposed at its origin. After lymph node dissection in this region, the right branch of the middle colic artery was ligated.

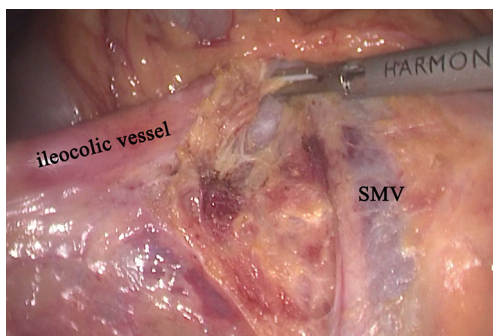
Maintaining tension during exposing the potential surgical plane formed between the visceral fascia (posterior lobe of mesocolon) and the underlying parietal fascia (covering retroperitoneum, such as pancreas, duodenum, kidney, gonadal vessels, ureter, etc.) (see *Figure 5*). The mobilising range begins from the origin of transverse colon mesentery to the side peritoneum.



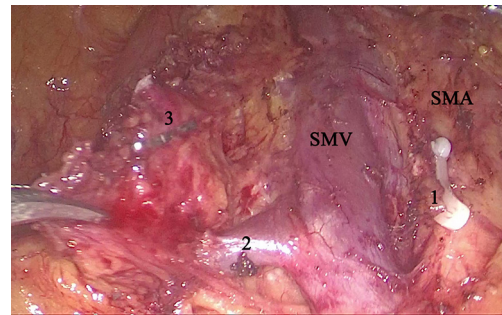
**Figure 1** Skin incision of trocar placement of a 10 mm port for a camera (umbilicus) (a), a 12 mm port for a working port (below the umbilicus, left side, midclavicular line) (b) and another three 5 mm ports in each remaining quadrant (c,d,e).



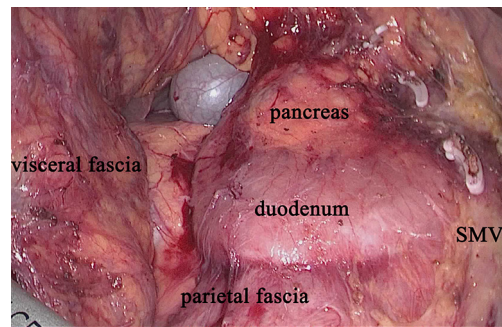
**Figure 2** Using tension by retracting to confirm the vessels line.



**Figure 3** Exposing the superior mesenteric vein (SMV), in order to dividing the corresponding vessels at their origin from the superior mesenteric vessels.



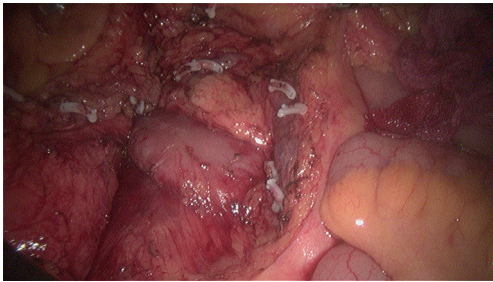
**Figure 4** To expose the superior mesenteric artery (SMA), exposure of the superior mesenteric vein (SMV) at its right is necessary: root of the ileocolic artery [1]; ileocolic vein [2]; ileocolic artery [3].



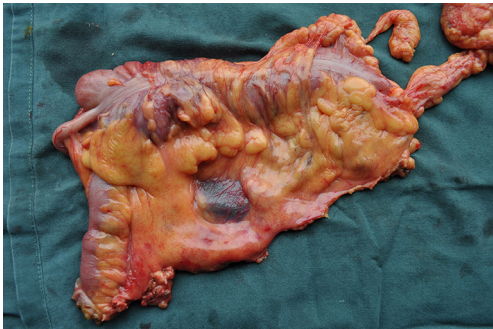**Figure 5** By a sharp dissection following an avascular surgical plane composed of visceral (covering the posterior mesocolon) and parietal (covering the retroperitoneal organs) fascia was exposed.

The entire mesocolon was preserved carefully. After removal of the specimen by enlarging the right upper quadrant incision (see *Figures 6,7*), an end-to-side ileocolic anastomosis was performed extracorporeally using stapled technique. It should be noted that the angle of anastomosis is smooth, in order to avoiding mesangial twist. After anastomosis, we need check it's no anastomotic bleeding and stenosis.

In cases of difficulty of finding the exact location of ileocolic pedicles, such as obese patients, blindly dissection will cause mesocolon rupture. For these patients, hybrid approach maybe an option. We can mobilise the ileocecal area firstly by lateral approach. The discrimination of the ileocolic pedicle from the SMV could be facilitated by prior mobilization of the ileocecal area (1) (see *Figure 8*).



**Figure 6** Viewing the operative field, including whether the parietal fascia is intact, and the retroperitoneal organs such as ureter and reproductive vascular are uninjured.



**Figure 7** Resected specimen of ascending colon cancer. A peritoneal window was made gently on the mesentery along the flow of the ileocolic artery to the SMV.

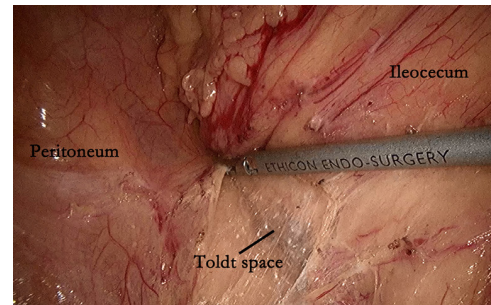
## Acknowledgments

*Funding:* None.

## Footnote

*Conflicts of Interest:* Both authors have completed the ICMJE uniform disclosure form (available at <http://dx.doi.org/10.21037/jxym.2017.04.05>). The authors have no conflicts of interest to declare.

*Ethical Statement:* The authors are accountable for all aspects of the work in ensuring that questions related to the accuracy or integrity of any part of the work are appropriately investigated and resolved. All procedures performed in studies involving human participants were in accordance with the ethical standards of the institutional and/or national research committee(s) and with the Helsinki



**Figure 8** After the sharp incision at Toldt's line, The peritoneum lateral to the ileocecum is incised from Toldt's line applying traction and countertraction. An avascular plane in Toldt's space was developed by sharp dissection.

Declaration (as revised in 2013). Written informed consent was obtained from the patient for publication of this manuscript and any accompanying images.

*Open Access Statement:* This is an Open Access article distributed in accordance with the Creative Commons Attribution-NonCommercial-NoDerivs 4.0 International License (CC BY-NC-ND 4.0), which permits the non-commercial replication and distribution of the article with the strict proviso that no changes or edits are made and the original work is properly cited (including links to both the formal publication through the relevant DOI and the license). See: <https://creativecommons.org/licenses/by-nc-nd/4.0/>.

## References

1. Kang J, Kim IK, Kang SI, et al. Laparoscopic right hemicolectomy with complete mesocolic excision. *Surg Endosc* 2014;28:2747-51.
2. Feng B, Ling TL, Lu AG, et al. Completely medial versus hybrid medial approach for laparoscopic complete mesocolic excision in right hemicolon cancer. *Surg Endosc* 2014;28:477-83.
3. Pigazzi A, Hellan M, Ewing DR, et al. Laparoscopic medial-to-lateral colon dissection: how and why. *J Gastrointest Surg* 2007;11:778-82.

doi: 10.21037/jxym.2017.04.05

**Cite this article as:** Gao Z, Jiang K. Laparoscopic complete mesocolic excision for cancer of the right colon. *J Xiangya Med* 2017;2:39.