

Young lady presented with sudden loss of vision

Huliyurdurga Srinivasasetty Natraj Setty, Babu Reddy, Budanar Chikkaswamy Srinivas, Togachagere Ramegowda Raghu, Jayashree Kharge, Rahul Patil, Sathwik Raj, Camrajnagara Mahadevappa Nagesh, Cholenahalli Nanjappa Manjunath

Sri Jayadeva Institute of Cardiovascular Sciences and Research, Bangalore, Karnataka, India

Correspondence to: Huliyurdurga Srinivasasetty Natraj Setty, MD, DM, FICC, FACC. Assistant Professor of Cardiology, Sri Jayadeva Institute of Cardiovascular Sciences and Research, Bangalore, Karnataka, India. Email: drnatrajsetty75@gmail.com.

Abstract: Takayasu's arteritis (TA) is a chronic inflammatory granulomatous vasculitis which influences large and medium arterial vessels. It is an unusual and idiopathic disease that affects aorta and its branches. The disease involves especially subclavian arteries and aortic branches. The major pathology is granulomatous panarteritis with intimal proliferation and defects of the elastic lamina of the vessels. The clinical presentation is related to the location of the involved artery. Patients with carotid artery involvement encounter decreased retinal perfusion leading to chronic ocular ischemia. Ocular ischemic syndrome and related ocular manifestations such as retinal microaneurysms, microhemorrhages, branch retinal vein occlusion, proliferative retinopathy, neovascular glaucoma, ischemic optic neuropathy, retinal detachment. Ocular involvement is common in primary vasculitis and potentially leads to significant morbidity, including complete loss of vision. Early diagnosis and treatment improves visual prognosis. We here by present a case report of a 23-year aged young lady who presented with sudden loss of bilateral vision and successfully underwent endovascular intervention to the occluded right carotid artery.

Keywords: Takayasu arteritis; central retinal artery occlusion; carotid

Received: 02 January 2019; Accepted: 25 February 2019; Published: 14 March 2019.

doi: 10.21037/jxym.2019.02.04

View this article at: <http://dx.doi.org/10.21037/jxym.2019.02.04>

Clinical case presentation

A 23-year-old female presented with a 3-month history of acute loss of vision in the right eye and 1 month history of loss of vision in the left eye. There was an associated severe retro-orbital headache. There was no history of vomiting, fever, skin rash, oral ulcers. No other co-morbidities or significant family history was present. On examination, mentation was found to be intact. Right upper limb pulse was absent and blood pressure was not recordable in that arm. Temperature was normal and no apparent signs of compartment syndrome or forearm ischemia were present. Bilateral carotid pulse was absent. Left upper limb blood pressure was 110/70 mmHg. Pupils were dilated and not reactive to light. Complete hemogram and biochemical investigations including a metabolic profile were normal. ECG, chest X-ray, and 2D Echocardiography were

unremarkable. Her initial diagnosis was central retinal artery occlusion (CRAO) for which she underwent laser treatment without any improvement in her vision and was subsequently transferred to a larger tertiary referral centre. Contrast enhanced MRI brain was done which on T2/FLAIR sequences showed hyperintensity at bilateral Centrum semiovale along internal watershed zone and at the left paraventricular deep white matter, suggestive of ischemic change. Left vitreous chamber on T2/FLAIR sequences showed similar hyperintensity. Orbital ultrasonography (o-USG) correlation revealed features suggestive of retinal detachment. Doppler ultrasonography screening of the carotid artery revealed occlusive disease and therefore the patient was underwent evaluation by a neurologist. Takayasu arteritis was then diagnosed and revascularization of the obstructed vessels was considered.

CT right upper limb and angiogram, revealed 50–60% proximal innominate artery luminal compromise, 90% distal innominate artery luminal compromise, 90% proximal right common carotid artery luminal compromised with circumferential mural thickening of the left common carotid artery involving proximal 50 mm. The detailed angiogram is shown in *Figure 1*. Fundus examination at presentation is shown in *Figure 2*.

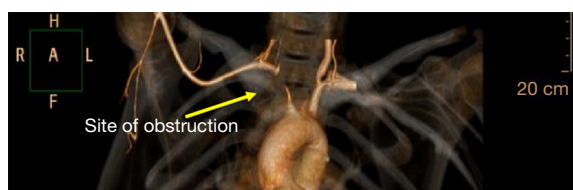


Figure 1 CT right upper limb angiogram shows carotid artery stenosis.

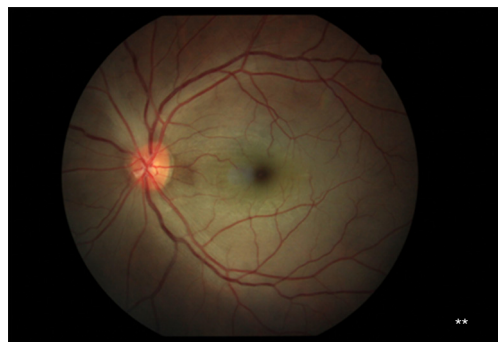


Figure 2 Fundus examination showing pale disk, pigmentary changes (**) suggestive of central retinal artery occlusion (CRAO).

The patient underwent successful PTA with a stent to right carotid and right subclavian artery. A 7.0×80 mm absolute pro self-expanding stent was used for this purpose after pre-dilation. Post-dilatation was subsequently performed shown in *Figure 3*. On table, the patient demonstrated improvement in her vision. The patient was initially started on pulse steroid therapy, each pulse cycle consisted of 3 days of IV methylprednisolone 1 g/day, Followed by oral corticosteroids 1 mg/kg/day and for systemic immunosuppression was continued on oral methotrexate 20 mg/week which aided in the recovery and suppression of disease. Interventional therapy for ocular Takayasu especially in the form of Central retinal artery occlusion (CRAO) include Vitrectomy/Nd:YAG laser.

Discussion

Takayasu arteritis disease is an uncommon inflammatory arteritis predominantly affecting the aorta and its branches (1). Uyama and Asayama broadly classified the ocular manifestations into three types (2), type 1 comprised of the ischemic ocular manifestations of Takayasu arteritis, termed as Takayasu Retinopathy which has been further classified into four stages. Stage one is characterized by the distention of veins, stage two consists of microaneurysm formation, the occurrence of arteriovenous anastomoses indicates stage three and complications like retinal ischemia, neovascularization, rubeosis iridis and vitreous hemorrhage occurs in stage four. The variability of ischemic changes in Takayasu arteritis probably depends upon the involvement of the carotid arteries which are occluded, and the duration and rate of ocular vascular insufficiency, in addition to the

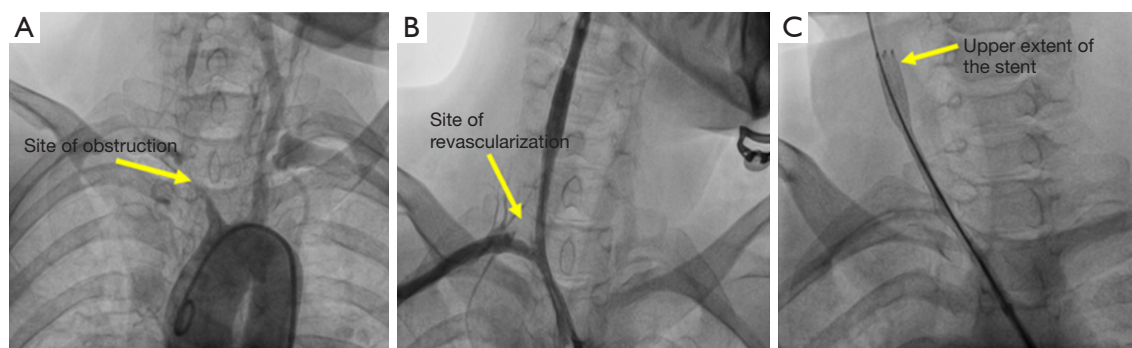


Figure 3 Peripheral angiography showing (A) bilateral carotid and subclavian artery stenosis. (B) Site of revascularization. (C) Upper extent of the stent.

development of collateral blood supply. Ocular presentation of Takayasu arteritis is reported to vary between 8.1% and 68% of the patients (3). The ocular findings of the disease are related to carotid artery obliteration which leads to hypoperfusion of all the eye structures. Reduced blood flow in the carotid arteries causes Takayasu's retinopathy which is related Takayasu arteritis the chronic ischemia and occurs in the late phase of the disease (4). Retinal vessel involvement, branch retinal artery occlusion, central retinal artery occlusion (CRAO), and branch retinal vein occlusion were demonstrated (5). Classical ophthalmological presentations are due to hypotension or hypertensive retinopathy. The ocular manifestation in the disease commonly results from the ocular hypotension secondary to occlusion of the arteries. The variable ocular presentations of Takayasu arteritis depend on the anatomy of the carotid artery occluded, duration, rate of vascular insufficiency and development of collateral blood supply (6). Revascularization-percutaneous transluminal angioplasty or bypass grafts may be considered in late cases when irreversible arterial stenosis has occurred and when significant ischemic symptoms are present (7). Percutaneous transluminal angioplasty is preferable when the stenosis is amenable to catheter based therapy. Percutaneous endovascular techniques provide a vista for prevention of irreversible neurological damage in the setting of impending deficit. These techniques help in the immediate relief of occlusive disease. They provide the patient and physician with a means to temporize disease manifestations while systemic manifestations and disease progression is retarded by immunosuppressive therapy (8).

Conclusion

Although retinal artery involvement is a very rare presentation in Takayasu arteritis, it is important to consider Takayasu arteritis particularly in young patients with retinal artery occlusion. Early revascularization may perhaps limit vision loss.

Acknowledgments

Funding: None.

Footnote

Conflicts of Interest: All authors have completed the ICMJE

uniform disclosure form (available at <http://dx.doi.org/10.21037/jxym.2019.02.04>). The authors have no conflicts of interest to declare.

Ethical Statement: The authors are accountable for all aspects of the work in ensuring that questions related to the accuracy or integrity of any part of the work are appropriately investigated and resolved. All procedures performed in studies involving human participants were in accordance with the ethical standards of the institutional and/or national research committee(s) and with the Helsinki Declaration (as revised in 2013). Written informed consent was obtained from the patient for publication of this manuscript and any accompanying images.

Open Access Statement: This is an Open Access article distributed in accordance with the Creative Commons Attribution-NonCommercial-NoDerivs 4.0 International License (CC BY-NC-ND 4.0), which permits the non-commercial replication and distribution of the article with the strict proviso that no changes or edits are made and the original work is properly cited (including links to both the formal publication through the relevant DOI and the license). See: <https://creativecommons.org/licenses/by-nc-nd/4.0/>.

References

1. Chun YS, Park SJ, Park IK, et al. The clinical and ocular manifestations of Takayasu arteritis. *Retina* 2001;21:132-40.
2. Uyama M, Asayama K. Retinal vascular changes in Takayasu disease (pulseless disease), occurrence and evaluation of the lesion. *Doc Ophthalmol Proc Ser* 1976;9:549-54.
3. Noel N, Butel N, Le Hoang P, et al. Small vessel involvement in Takayasu's arteritis. *Autoimmun Rev* 2013;12:355-62.
4. Elizalde J, Capella MJ. Takayasu's retinopathy. *Int Ophthalmol* 2011;31:533-7.
5. Noel N, Butel N, Le Hoang P, et al. Small vessel involvement in Takayasu's arteritis. *Autoimmun Rev* 2013;12:355-62.
6. Nakabayashi K, Nitadori T, Kamiya Y, et al. Atypical Takayasu arteritis: late onset and arthritic manifestations: report of two cases. *Int J Cardiol* 1998;66 Suppl 1:S221-7; discussion S229.
7. Ishikawa K, Maetani S. Long-term outcome for 120 Japanese patients with Takayasu's disease. *Clinical and*

- statistical analyses of related prognostic factors. *Circulation* 1994;90:1855-60.
8. Liang P, Tan-Ong M, Hoffman GS. Takayasu's arteritis: vascular interventions and outcomes. *J Rheumatol* 2004;31:102-6.

doi: 10.21037/jxym.2019.02.04

Cite this article as: Natraj Setty HS, Reddy B, Srinivas BC, Raghu TR, Kharge J, Patil R, Raj S, Nagesh CM, Manjunath CN. Young lady presented with sudden loss of vision. *J Xiangya Med* 2019;4:13.