



## Innovations in perforator flaps

Unlike most surgical interventions, the goal of the reconstructive surgeon is not just preservation of life; but to insure recovery of function with minimal complications at any recipient site while minimizing donor site morbidity. Often this will require utilization of a vascularized block of tissue or “flap”. To achieve the aforementioned goals, adoption of the perforator flap genre where muscle preservation specifically is its major asset has gained international attention. Today, the perforator flap has indeed become “mainstream (1)” and must be found within the armamentarium of every skilled reconstructive surgeon. Thus, it has been the privilege of both guest editors to be asked to organize this innovative focus on perforator flaps, as we have had a longtime interest not only in learning about this subject; but then teaching our colleagues not just about their attributes, but how to do them easily.

Our emphasis is not about the “history” of the perforator flap, that is only important so we do not repeat any missteps; but what will be the future? The perforator flap is all about the anatomy; and specifically the vasculature to the skin, as Jiang *et al.* show in their report on that discovered around the clavicle. Next, the pre-operative identification of adequate perforators may now be simpler, and certainly cheaper (2), as Muntean *et al.* prove using dynamic infrared thermography (DIRT). Qing *et al.*, have improved the traditional retrograde dissection of perforator vessels with a detailed description of their operative technique. As our guru Marko Godina emphasized many years ago, the early repair of any defect always gave better results (3). Chang-Xiong Liu *et al.* proved this to be true for pilon fractures, while also introducing the ipsilateral lateral thigh perforator free flap based on a profunda femoris perforator, which has a surprisingly long pedicle. Similarly, many may now consider the medial sural perforator flap from the calf to be a “workhorse” flap (4).

Perforator flaps can be used in many varieties, and not necessarily as free flaps, although microsurgical capabilities will be a prerequisite for their proper dissection (5). Yuanbo Liu *et al.* showed that the distal based anterolateral thigh flap when pedicled on an “oblique branch” can reach the knee region. Georgescu and Matei can provide coverage even of remote finger defects with “propeller” perforator flaps. Qing *et al.* in an additional paper, reviewed special form perforator flaps that included the concepts of the flow-through perforator flap, chimeric or conjoined perforator flaps, the micro-dissected or thinned perforator flap, and multi-lobed perforator flaps. Jiga and Jandali used a chimeric flap that included vascularized bone to heal a hand segmental defect.

May we again thank all the authors who have contributed to this focus, from China, Germany, Romania, the United States, and around the world, for their insight and worthwhile efforts. They are not just our colleagues, but our friends. Hopefully, those readers who have taken the opportunity to investigate what they have presented will gain new insights in taking care of their patients the best way possible. That is really all that is important.

### Acknowledgments

*Funding:* None.

### Footnote

*Provenance and Peer Review:* This article was commissioned by the editorial office, *Journal of Xiangya Medicine* for the series “Perforator Flap”. The article did not undergo external peer review.

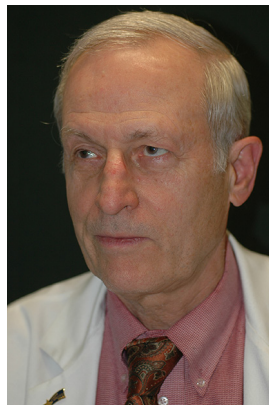
*Conflicts of Interest:* Both authors have completed the ICMJE uniform disclosure form (available at <http://dx.doi.org/10.21037/jxym.2019.03.04>). The series “Perforator Flap” was commissioned by the editorial office without any funding or sponsorship. GGH and JYT served as the unpaid Guest Editors of the series. GGH serves as an unpaid editorial board member of *Journal of Xiangya Medicine*. The authors have no other conflicts of interest to declare.

*Ethical Statement:* The authors are accountable for all aspects of the work in ensuring that questions related to the accuracy or integrity of any part of the work are appropriately investigated and resolved.

*Open Access Statement:* This is an Open Access article distributed in accordance with the Creative Commons Attribution-NonCommercial-NoDerivs 4.0 International License (CC BY-NC-ND 4.0), which permits the non-commercial replication and distribution of the article with the strict proviso that no changes or edits are made and the original work is properly cited (including links to both the formal publication through the relevant DOI and the license). See: <https://creativecommons.org/licenses/by-nc-nd/4.0/>.

## References

1. Hallock GG. If based on citation volume, perforator flaps have landed mainstream. *Plast Reconstr Surg* 2012;130:769e-771e.
2. Pereira N, Valenzuela D, Mangelsdorff G, et al. Detection of Perforators for Free Flap Planning Using Smartphone Thermal Imaging: A Concordance Study with Computed Tomographic Angiography in 120 Perforators. *Plast Reconstr Surg* 2018;141:787-92.
3. Godina M. Early microsurgical reconstruction of complex trauma of the extremities. *Plast Reconstr Surg* 1986;78:285-92.
4. Daar DA, Abdou SA, Cohen JM, et al. Is the Medial Sural Artery Perforator Flap a New Workhorse Flap? A Systematic Review and Meta-Analysis. *Plast Reconstr Surg* 2019;143:393e-403e.
5. Georgescu AV, Matei I, Ardelean F, et al. Microsurgical nonmicrovascular flaps in forearm and hand reconstruction. *Microsurgery* 2007;27:384-94.



Geoffrey G. Hallock



Juyu Tang

### **Geoffrey G. Hallock, MD**

*Division of Plastic Surgery, Sacred Heart Hospital, Allentown, Pennsylvania 18103, USA. (Email: gghallock@hotmail.com)*

### **Juyu Tang, MD, PhD**

*Department of Microsurgery and Hand Surgery, Xiangya Hospital of Central South University, Changsha 410008, China. (Email: tangjuyu@csu.edu.cn)*

Received: 01 March 2019; Accepted: 22 March 2019; Published: 01 April 2019

doi: 10.21037/jxym.2019.03.04

**View this article at:** <http://dx.doi.org/10.21037/jxym.2019.03.04>

doi: 10.21037/jxym.2019.03.04

**Cite this article as:** Hallock GG, Tang J. Innovations in perforator flaps. *J Xiangya Med* 2019;4:17.