

Qingdai ointment in the treatment of plaque psoriasis: a case report

Shangpu Gao¹, Weisong Kong², Xin Zhou²

¹Department of Dermatology, ²Department of Pharmacy, Longhua Hospital, Shanghai University of Traditional Chinese Medicine, Shanghai 200032, China

Correspondence to: Weisong Kong. Department of Pharmacy, Longhua Hospital, Shanghai University of Traditional Chinese Medicine, Shanghai 200032, China. Email: kws2009@126.com.

Abstract: Plaque psoriasis is a severe and refractory skin disease of psoriasis vulgaris, which lacks an ideal therapeutic method at present. Recently Qingdai ointment, an in-hospital preparation, was used alone to treat a case of plaque psoriasis, and the curative effect was excellent.

Keywords: Plaque psoriasis; Qingdai ointment; indigo naturalis (IN); case report

Received: 28 August 2019; Accepted: 13 September 2019; Published: 22 November 2019.

doi: 10.21037/lcm.2019.09.03

View this article at: <http://dx.doi.org/10.21037/lcm.2019.09.03>

Introduction

Plaque psoriasis is a severe and refractory skin disease of psoriasis vulgaris, which lacks an ideal therapeutic method at present. Recently Qingdai ointment was used alone to treat a case of plaque psoriasis, and the curative effect was excellent. Now it is reported as follows.

Case presentation

An outpatient, a 35-year-old man with a 2-month history of aggravated rash, first presented in dermatology on March 13, 2019. The patient had a repeating rash that itched for 15 years, and the symptoms got worse in winter than summer. Physical examination revealed that the torso and upper limbs were scattered with bright red patches which were partly coin-like and covered with silvery-white scales. The erythema on the calves merged into pieces, thickened with desquamation. The patient was diagnosed with psoriasis vulgaris. He refused to use oral medicines or glucocorticoids for topical use and was allergic to calcipotriol ointment. Then he was treated with Qingdai ointment twice a day and medical packets for 1 h. Two weeks later, the color of the skin lesions went lighter, and the scales became thinner. Qingdai ointment was continuously applied to him. Two weeks later, the skin lesions came to reddish. Healthy skin could be seen in the center of them (*Figure 1*).

Discussion

For personal reasons, this patient came to our hospital seeking the treatment of topical preparations of traditional Chinese medicine. Qingdai ointment, an in-hospital preparation, has been topically used for psoriasis for 60 years in our hospital. Qingdai ointment consists of indigo naturalis (IN) and vaseline, which has the effects of astringing dampness and relieving itching, clearing away heat and detoxifying. It is a widely used topical preparation in Dermatology of traditional Chinese medicine. The progressive stage of psoriasis is a blood-heat Zheng formed by evil heat going into blood. IN, derived from indigo plants such as *Baphicacanthus cusia* (Nees) Bremek, the main ingredient of Qingdai ointment, salty and cold, belongs to the liver jing. It can clear heat and detoxify cool blood and eliminate plaques. When used for treating psoriasis blood-heat Zheng, the drug is suitable for the disease. Therefore, it has a beneficial effect.

A systematic review of 57 trials and 3 meta-analyses found that IN together with other complementary and alternative medicine treatments had the most robust evidence of efficacy in the treatment of plaque psoriasis (1). Literatures showed that IN could inhibit the hyperproliferation of keratinocytes. Qingdai ointment could directly inhibit proliferating cell nuclear antigen (PCNA) in skin lesions of psoriasis patients. IN and its constituent—indirubin—can regulate

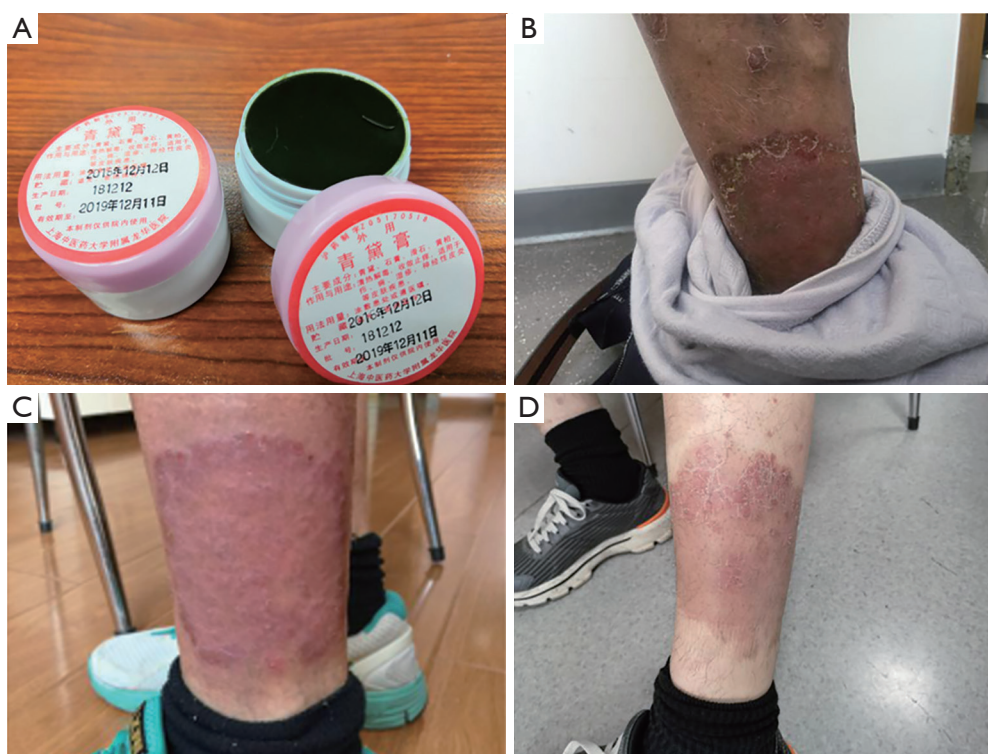


Figure 1 Qingdai ointment and changes in the skin of plaque psoriasis patient before and after applying with Qingdai ointment. (A) Qingdai ointment; (B) affected part of the patient, March 13, 2019; (C) affected part of the patient, March 27, 2019 (using Qingdai ointment for 2 weeks); (D) affected part of the patient, April 10, 2019 (using Qingdai ointment for 4 weeks).

the proliferation and differentiation of keratinocytes (2). Qingdai ointment could significantly reduce punctate hemorrhage, erythema, and inflammatory reaction by decreasing the expression of VEGF and inhibiting microvascular proliferation (3,4). Via G0/G1 cell cycle arrest, indirubin handled the antipsoriatic effects, which decreased the hyperproliferation that characterized psoriasis, according to Lin *et al.* (5). Also, Gaitanis *et al.* (6) pointed out that the effectiveness of indirubin might highlight a potential engagement of the *Malassezia* metabolome in the pathophysiology of psoriasis.

Acknowledgments

Funding: None.

Footnote

Conflicts of Interest: All authors have completed the ICMJE uniform disclosure form (available at <http://dx.doi.org/10.21037/lcm.2019.09.03>). The authors have no

conflicts of interest to declare.

Ethical Statement: The authors are accountable for all aspects of the work in ensuring that questions related to the accuracy or integrity of any part of the work are appropriately investigated and resolved. All procedures performed in studies involving human participants were in accordance with the ethical standards of the institutional and/or national research committee(s) and with the Helsinki Declaration (as revised in 2013). Written informed consent was obtained from the patient for publication of this case report and any accompanying images.

Open Access Statement: This is an Open Access article distributed in accordance with the Creative Commons Attribution-NonCommercial-NoDerivs 4.0 International License (CC BY-NC-ND 4.0), which permits the non-commercial replication and distribution of the article with the strict proviso that no changes or edits are made and the original work is properly cited (including links to both the formal publication through the relevant DOI and the license).

See: <https://creativecommons.org/licenses/by-nc-nd/4.0/>.

References

1. Gamret AC, Price A, Fertig RM, et al. Complementary and Alternative Medicine Therapies for Psoriasis: A Systematic Review. *JAMA Dermatol* 2018;154:1330-7.
2. Lin YK, Wong WR, Chang YC, et al. The efficacy and safety of topically applied indigo naturalis ointment in patients with plaque-type psoriasis. *Dermatology* 2007;214:155-61.
3. Chen L, Zhao W. Natural indigo compound ointment in the treatment of 60 cases of psoriasis vulgaris. *Guangming J Chin Med* 2014;(7):1413-4.
4. Zhao W, Chen L. Natural indigo compound ointment on psoriasis vulgaris by detecting VEGF in lesions. *J Changchun Univ Chin Med* 2015;31:1046-8.
5. Lin YK, Leu YL, Yang SH, et al. Anti-psoriatic effects of indigo naturalis on the proliferation and differentiation of keratinocytes with indirubin as the active component. *J Dermatol Sci* 2009;54:168-74.
6. Gaitanis G, Magiatis P, Velegraki A, et al. A traditional Chinese remedy points to a natural skin habitat: indirubin (indigo naturalis) for psoriasis and the *Malassezia* metabolome. *Br J Dermatol* 2018;179:800.

doi: 10.21037/lcm.2019.09.03

Cite this article as: Gao S, Kong W, Zhou X. Qingdai ointment in the treatment of plaque psoriasis: a case report. *Longhua Chin Med* 2019;2:15.