

Robotic surgery for endometriosis

Vito Cela, Elisa Malacarne, Francesca Braganti, Francesca Papini

Department of Maternal Fetal Medicine, Infertility and IVF Center, University of Pisa, Pisa, Italy

Correspondence to: Dr. Vito Cela, MD, PhD. Department of Maternal Fetal Medicine, Division of Obstetrics and Gynecology, University of Pisa, Via Roma 67, Pisa, Italy. Email: celav2001@gmail.com.

Abstract: Endometriosis is an estrogen-dependent, benign, debilitating disease that affects women during the reproductive age. Its clinical behaviour is extremely heterogeneous ranging from an asymptomatic finding to a severe disorder involving multiple extragenital organs and causing symptoms as infertility, dysmenorrhea, or chronic pelvic pain. The first line of treatment should include medical therapy, but when it fails or if the patient does not tolerate it, surgery is often the most effective treatment of endometriosis, and a minimally invasive approach using laparoscopy is considered the gold standard. Robotic surgery has taken more and more space in endometriosis treatment, especially to achieve a safe and radical surgery for deep infiltrating endometriosis (DIE), overcoming the intrinsic technical limitation of conventional laparoscopy thanks to the greater freedom of movements made possible by seven-degree laparoscopic instruments, the magnified and high-definition 3D camera and the tremor filtering. Robotic surgery also allows the real-time visualization of vascular and microvascular flow. Robotic surgery seems to be a safe and feasible technique even in the management of critical condition, as for example obese patients, extragenital endometriosis involving bowel, bladder, ureters, or diaphragm. The injection of indocyanine green (ICG), thanks to the Firefly technique, allows a further improvement in the eradication of DIE.

Keywords: Endometriosis; robotic surgery; deep infiltrating endometriosis (DIE); indocyanine green (ICG)

Received: 30 May 2020; Accepted: 11 June 2020; Published: 25 September 2020.

doi: 10.21037/gpm-20-43

View this article at: <http://dx.doi.org/10.21037/gpm-20-43>

Introduction

Endometriosis is defined as endometrial glands and stroma that occur outside the uterine cavity. It is an estrogen-dependent, benign, chronic disease. Its exact prevalence is not well defined, although estimates range from 2% to 10% within the general population. These percentages have been shown to increase up to 50% if infertile patients are considered (1). The lesions are typically located in pelvis but can occur at multiple sites as including the bowel, diaphragm, and pleural cavity.

A correct diagnosis of endometriosis is essential to evaluate the correct therapeutic approach and the possible need of surgery is based on the patient's history, symptoms and signs, physical examination, and imaging techniques, and a histologic examination is used to assess whether the patient require surgery. Because of his heterogeneity a long delay in its diagnosis has been reported in various studies,

and many women receive delayed or suboptimal care (2).

Endometriosis has a highly variable phenotype and the severity of clinical presentation may vary greatly.

Being a chronic and progressive condition, endometriosis requires prolonged management, and it is important to consider the characteristics and needs of each individual patient. The first-line treatment of endometriosis should include medical therapy, but when it fails or if patient does not tolerate them, surgery is often the most effective treatment of endometriosis, and a minimally invasive approach using laparoscopy is considered the gold standard.

The advantages of minimal invasive approach compared to the traditional open technique have been confirmed in recent years by many authors, among which shorter hospitalization, less pain, better cosmetic results, and lower postoperative morbidity (3,4). Nevertheless, laparoscopic surgery has several intrinsic technical limitations, for

which experience of the surgeon is essential to perform an optimal surgery with a correct and complete excision of endometriosis (5). Ergonomic limitations, bi-dimensional view and a reduced degree of freedom are among the most critical aspects of laparoscopic surgery, together with the limits of a narrow operating field and lack of anatomical landmarks.

For these reasons robotic surgery has taken more and more space in endometriosis treatment, especially to achieve a safe and radical surgery for deep infiltrating endometriosis (DIE). Robotic technology represents the latest developments in minimally invasive surgery and makes it possible to overcome the intrinsic limitations of conventional laparoscopy thanks to its innovative features, such as the comfortable working position for the surgeon, the more flexible movements made possible by seven-degree laparoscopic instruments, the magnified and high-definition 3D camera and the tremor filtering (6). The most widely used robotic system is the da Vinci system.

DIE affects about 1% of all women during reproductive period and about 20% of women with endometriosis (7).

DIE is defined as a solid endometriosis mass situated more than 5 mm deep to the peritoneum (8). DIE generally is found in the rectovaginal septum, rectum, rectosigmoid colon, bladder, ureter, and other pelvic fibromuscular structures such as the uterine ligaments and vagina.

When medical therapy fails, the treatment of symptomatic DIE consists of complete surgical excision of endometriosis, after a complete mapping of the lesions performed with transvaginal sonography and possibly with the addition of 3D magnetic resonance imaging reconstructions (9).

Currently, minimally invasive surgery is considered the standard approach in the treatment of DIE. The surgical treatment of DIE presents intrinsic technical difficulties due to distorted anatomy of pelvis which make it difficult to recognize and isolate the pelvic structures and the need to be as radical as possible to improve the quality of life and fertility. In this scenario the role of robotic assisted surgery may represent an indispensable tool to achieve an optimal surgical target, with the purpose of overcoming the kinematic limitation of conventional laparoscopy, especially in complex procedures, when extragenital endometriosis diffusely involves pelvic or abdominal structures such as bowel and urinary tracts.

DIE surgical eradication presents indeed a high risk of major complications such as recto-vaginal fistulae, dehiscence of urinary or intestinal anastomoses and

urological sequelae, that considering the young age of the patient and the characteristics of benignity of this disease must be even more avoided.

Different studies demonstrate the feasibility and the safety of robot-assisted surgery for the debulking of DIE involving the bladder, the rectovaginal septum or the bowel (10) showing favourable outcomes in terms of improving quality of life and urinary and sexual functions (11).

One of the most important problem in patient with endometriosis is subfertility or infertility. It is well-known that the treatment of endometriosis must be as radical as possible, in order to significantly increase the likelihood of spontaneous pregnancy (12). Conventional Laparoscopy has proven better than laparotomy in increasing both the chances of spontaneous conception and those after *in vitro* fertilization and in improving pregnancy outcomes (13). In this scenario there are no studies comparing conventional laparoscopy and robotic assisted laparoscopy as regards fertility and postoperative pregnancy-rate. For this reason, attention must be paid to the use of robot-assisted laparoscopy in patients who have infertility as the only indication for surgery.

Operative technique

Robotic surgery represents the new frontier of minimally invasive surgery.

The da Vinci surgical system is the most advanced robotic system for minimally invasive surgery.

The surgeon, physically far from the operating field and sitting at a console equipped with monitor and controls, moves the robotic arms connected to endoscopic instruments introduced into the patient's body through small skin incision, features of minimally invasive laparoscopic surgery.

The surgical system basically consists of three main components:

(I) The surgical console, the control center of the da Vinci system. Through the console, positioned outside the sterile field, the surgeon controls the 3D endoscope and the EndoWrist instruments by means of two manipulators (master) and pedals. The robot can faithfully replicate the gestures performed by the surgeon at the console, improving their performance thanks to the suppression of the natural tremor of the hand and the ability to multiply the movements. In addition, the enlarged and three-dimensional view of the operating field allows the operator

to distinguish very small anatomical structures that are difficult to see with the naked eye.

(II) The patient trolley, the operating component of the da Vinci system, whose main function is to support the robot arms (instrument arms and video camera arm), materially responsible for carrying out the intervention. EndoWrist instruments are installed on the arms of the robot, equipped with a wrist capable of rotating almost 360°. The instruments are designed with seven degrees of movement, a far greater range of action than that of the human wrist.

(III) The vision trolley contains the central processing unit and a high definition video system (Full HD). The operating field is captured at the camera head, designed to have a 60° field of view and capable of enlarging the surgical area by 6–10 times. It should be added that in recent years, Firefly™ technology (14) has been significantly developed to improve diagnostics in robotic surgery. The Firefly™ vision system is designed for the real-time visualization of high-resolution images of vascular and microvascular flow, tissues, and organ perfusion. The video camera control unit processes and displays endoscopic images in the form of a fluorescent film over a black and white image. Fluorescence images are obtained by administering to the patient a contrast medium, indocyanine green (ICG). The operator switches the image easily from normal mode (visible light) to Firefly™ mode (near infrared) using the controls of the surgical console.

The patient is positioned on the operating table using anti-skid material in a low dorsal lithotomy position with the legs inside special thighs and the arms along the body. Correct positioning of the body is essential to prevent nerve injuries and to improve surgery (15). The surgical procedure is performed under general anaesthesia. Foley catheter is inserted. Uterine manipulator is needful for a correct mobilization of the uterus (16). The patient is placed in Trendelenburg position on the surgical table to make possible a better visualization of pelvis and to turn away bowel. Conventional robot-assisted surgery is a multiport robotic surgery, despite it can be performed using a single site approach. Laparoendoscopic-single-site surgery reduces invasiveness because it uses a single skin incision to gain access to abdominal or pelvic cavities which might result into a benefit for patients in terms of port-related complications, pain and aesthetic outcome.

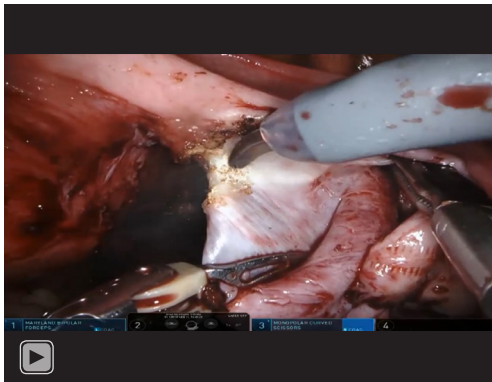
For the treatment of deep endometriosis, it is recommended to use 3 or 4 arms according to the operator's expertise. It's recommended to use the 4th arm when the

surgeon has gained experience. Experienced operators use it to create spaces or to keep anatomical structures outside the operative field. It is our habit to use bipolar forceps on the left, scissors on the right and grasping forceps always on the right. Sometimes, the grasping forceps can be replaced with a vacuum cleaner. With the Xi platform, the trocars are positioned in line with the umbilical trocar. With the SI platform the trocars of the 3rd and 4th arm are placed vertically. It is always convenient to work at low flows with pressures around 8 mmHg. The technique of approach to deep endometriosis, in particular to the rectal vaginal nodules, involves going from the lateral to the medial, from the front to the back and the top to the bottom to isolate the endometriotic pathology without injuring the organs involved. The bipolar forceps can be used as a dissector, thanks to the strength of the branch. The robotic bipolar forceps allow to isolate the ureter bilaterally when necessary, until it arrives in the cardinal ligament, starting from its passage above the external iliac vessels up to the passage under the uterine artery. The bilateral dissection of hypogastric nerves, when recognizable as not compromised by the disease, allows to preserve the functions of the rectum and bladder. Always with the bipolar forceps and scissors, it is useful to recognize the anterior limit of the part of the nodule at the level of the rectal vaginal space. This technique called "bridge" allows you to completely distance the rectum from the vagina and leave only the nodule attached, which will then be easily recognized and detached from the vagina. The rectal vaginal nodule left on the intestinal wall will then be removed with "shave" technique with cold scissors from the intestinal wall. The injection of ICG, thanks to the Firefly technique, allows to better highlight the lump which will remain dark in colour compared to the healthy part of the intestine which will be intense green (*Video 1*).

Comments

The advent of robotic surgery is an important innovation that has provided new perspectives in the treatment of endometriosis. This technique offers numerous advantages over traditional surgery, enormously more evident in complex procedures, as oncology and deep endometriosis and when extragenital endometriosis widely involves pelvic structures such as the intestine and urinary tract.

The advantages offered by the robotic technique could be of great value in the management of infertility with the assimilation of the principles of microsurgery in surgical



Video 1 Robotic surgery for endometriosis.

procedures for the promotion/preservation of fertility. It is known that the treatment of endometriosis must be as radical as possible to significantly increase the probability of spontaneous pregnancy. Various studies have shown an increase in the rate of spontaneous postoperative pregnancy after surgical treatment of endometriosis-associated infertility, however, this type of surgery is complex and requires a well-trained, experienced and often multidisciplinary surgical team (urologist, visceral surgeon) to promote fertility and avoid complications instead. The associated morbidity is in fact significant, due to the invasion of surrounding organs, nerves, and blood vessels, as well as the limits of laparoscopic dissection (17).

Deep endometriosis is probably one of the main indications for robotic surgery, in gynecological surgery (18). However, to date, very few retrospective studies, small case series, metanalysis and only one randomized clinical trial have been published and in many of these studies patients had different stages of the disease. The role of the robot in deep endometriosis appears promising as it does not lead to an increase in surgical time, blood loss and intra and postoperative complications and instead appears to reduce conversion rates to laparotomy. Furthermore, it can overcome the limits of standard laparoscopy, allowing to complete resections in poorly accessible areas, in particular in the cul-de-sac, with greater dexterity (articulated robotic arms) and greater precision thanks to the use of smaller instruments, 3D magnification of the operating field and tremor filtering. An adequate application of the rules of microsurgery also allows to reduce postoperative adhesions and the implementation of this technology could allow a minimally invasive safe surgical approach even in obese women. Robot assisted surgery seems to be safe even in the

management of critical conditions, such as diaphragmatic endometriosis (19), especially when larger deep infiltration implants are present. It is important to underline the possibility of working simultaneously on two parallel consoles reducing the learning curve as well as complication rates, facilitating the training of less experienced surgeons and allowing more surgeons to use this technology to perform complex procedures excellently in the future. In addition, the implementation of the Firefly™ technology and the ICG dye facilitate the detection of endometriosis, allow to successfully perform a resection of severe endometriosis with a complete resolution of the symptoms of pelvic pain and excellent aesthetic results (20). Despite the numerous advantages described, further studies regarding robotic surgery in the different stages of endometriosis and combined with different types of procedure (rectal shaving or segmental rectal resection, partial cystectomy, resection of the uterosacral ligament with or without ureterolysis) are necessary and expected.

A “patient-centered” approach oriented towards shared objectives must be the cornerstone in the evaluation of treatment options in the management of the patient suffering from endometriosis.

Discussion

- (I) Dr. Liliana Mereu: Could the authors evidence if there are advantages in using robotics for the treatment of endometriosis over laparoscopy?
Answer: Robotic surgery is a safe and feasible technique in patients affected by endometriosis. Robotic approach could be a valid option and might be considered an alternative to laparoscopy especially in advanced and complex cases.
- (II) Dr. Liliana Mereu: Does the use of fluorescence camera to evidence endometriosis have any surgical and clinical advantages?
Answer: The use of fluorescence camera to evidence deep infiltrating endometriosis can bring surgical advantages including the ability to better highlight the transecting line for rectal resection, a good control of vascularization after bowel anastomosis and a better visualization of rectal nodules limits during shaving technique.
- (III) Dr. Liliana Mereu: Are there any evidence that endometriotic patients treated with robotics surgery improve fertility?
Answer: There are no studies that could disentangle

this issue until now.

Acknowledgments

Funding: None.

Footnote

Provenance and Peer Review: This article was commissioned by the Guest Editor (Liliana Mereu) for the series “Robotic Surgery for Benign and Malignant Gynecological Diseases” published in *Gynecology and Pelvic Medicine*. The article has undergone external peer review.

Conflicts of Interest: All authors have completed the ICMJE uniform disclosure form (available at <https://gpm.amegroups.com/article/view/10.21037/gpm-20-43/coif>). The series “Robotic Surgery for Benign and Malignant Gynecological Diseases” was commissioned by the editorial office without any funding or sponsorship. The authors have no other conflicts of interest to declare.

Ethical Statement: The authors are accountable for all aspects of the work in ensuring that questions related to the accuracy or integrity of any part of the work are appropriately investigated and resolved. All procedures performed in studies involving human participants were in accordance with the ethical standards of the institutional and/or national research committee(s) and with the Helsinki Declaration (as revised in 2013). Written informed consent was obtained from the patient for publication of this study and any accompanying images.

Open Access Statement: This is an Open Access article distributed in accordance with the Creative Commons Attribution-NonCommercial-NoDerivs 4.0 International License (CC BY-NC-ND 4.0), which permits the non-commercial replication and distribution of the article with the strict proviso that no changes or edits are made and the original work is properly cited (including links to both the formal publication through the relevant DOI and the license). See: <https://creativecommons.org/licenses/by-nc-nd/4.0/>.

References

- Giudice LC. Clinical practice. Endometriosis. *N Engl J Med* 2010;362:2389-98.
- Kennedy S, Bergqvist A, Chapron C, et al. ESHRE guideline for the diagnosis and treatment of endometriosis. *Hum Reprod* 2005;20:2698-704.
- Dunselman GA, Vermeulen N, Becker C, et al. ESHRE guideline: management of women with endometriosis. *Hum Reprod* 2014;29:400-12.
- Angioni S, Peiretti M, Zirone M, et al. Laparoscopic excision of posterior vaginal fornix in the treatment of patients with deep endometriosis without rectum involvement: surgical treatment and long-term follow-up. *Hum Reprod* 2006;21:1629-34.
- Vitobello D, Fattizzi N, Santoro G, et al. Robotic surgery and standard laparoscopy: a surgical hybrid technique for use in colorectal endometriosis. *J Obstet Gynaecol Res* 2013;39:217-22.
- Cela V, Obino ME, Sergiampietri C, et al. The role of robotics in the management of endometriosis. *Minerva Ginecol* 2017;69:504-16.
- Giannini A, Pisaneschi S, Malacarne E, et al. Robotic Approach to Ureteral Endometriosis: Surgical Features and Perioperative Outcomes. *Front Surg* 2018;5:51.
- De Cicco C, Corona R, Schonman R, et al. Bowel resection for deep endometriosis: a systematic review. *BJOG* 2011;118:285-91.
- Giusti S, Forasassi F, Bastiani L, et al. Anatomical localization of deep infiltrating endometriosis: 3D MRI reconstructions. *Abdom Imaging* 2012;37:1110-21.
- Collinet P, Leguevaque P, Neme RM, et al. Robot-assisted laparoscopy for deep infiltrating endometriosis: international multicentric retrospective study. *Surg Endosc* 2014;28:2474-9.
- Morelli L, Perutelli A, Palmeri M, et al. Robot-assisted surgery for the radical treatment of deep infiltrating endometriosis with colorectal involvement: short- and mid-term surgical and functional outcomes. *Int J Colorectal Dis* 2016;31:643-52.
- Angioni S, Cela V, Sedda F, et al. Focusing on surgery results in infertile patients with deep endometriosis. *Gynecol Endocrinol* 2015;31:595-8.
- Roman H. Endometriosis surgery and preservation of fertility, what surgeons should know. *J Visc Surg* 2018;155 Suppl 1:S31-S36.
- Cela V, Sergiampietri C, Rosa Obino ME, et al. Sentinel-lymph-node mapping with indocyanine green in robotic-assisted laparoscopic surgery for early endometrial cancer: a retrospective analysis. *Facts Views Vis Obgyn* 2020;11:323-8.
- Barnett JC, Hurd WW, Rogers RM Jr, et al. Laparoscopic positioning and nerve injuries. *J Minim Invasive Gynecol*

- 2007;14:664-72; quiz 73.
16. Saceanu SM, Cela V, Pluchino N, et al. Robotic-assisted laparoscopic surgery in uterine pathology. *Eur J Obstet Gynecol Reprod Biol* 2013;169:340-2.
 17. Pisanu A, Deplano D, Angioni S, et al. Rectal perforation from endometriosis in pregnancy: case report and literature review. *World J Gastroenterol* 2010;16:648-51.
 18. Restaino S, Mereu L, Finelli A, et al. Robotic surgery vs laparoscopic surgery in patients with diagnosis of endometriosis: a systematic review and meta-analysis. *J Robot Surg* 2020. [Epub ahead of print].
 19. Cela V, Simi G, Obino MER, et al. Diaphragmatic Endometriosis: Review of the Literature and First Case of Robot-Assisted Laparoscopic Treatment. *J Endometr Pelvic Pain Disord* 2004;6:219-24.
 20. Guan X, Nguyen MT, Walsh TM, et al. Robotic Single-Site Endometriosis Resection Using Firefly Technology. *J Minim Invasive Gynecol* 2016;23:10-1.

doi: 10.21037/gpm-20-43

Cite this article as: Cela V, Malacarne E, Braganti F, Papini F. Robotic surgery for endometriosis. *Gynecol Pelvic Med* 2020;3:25.