



# The use of plasmakinetic cautery compared to conventional electrocautery for dissection of abdominal free flap for breast reconstruction: single-centre, randomized controlled study

Whitney T. H. Chow, Georgette Oni, Venkat V. Ramakrishnan, Mat Griffiths

St Andrew's Centre for Plastic Surgery and Burns, Broomfield Hospital, Mid Essex Hospital Services NHS Trust, Chelmsford, UK

*Contributions:* (I) Conception and design: WT Chow, VV Ramakrishnan, M Griffiths; (II) Administrative support: WT Chow, VV Ramakrishnan, M Griffiths; (III) Provision of study materials or patients: WT Chow, VV Ramakrishnan, M Griffiths; (IV) Collection and assembly of data: WT Chow, VV Ramakrishnan, M Griffiths; (V) Data analysis and interpretation: All authors; (VI) Manuscript writing: All authors; (VII) Final approval of manuscript: All authors.

*Correspondence to:* Whitney T. H. Chow. St Andrew's Centre for Plastic Surgery and Burns, Broomfield Hospital, Mid Essex Hospital Services NHS Trust, Chelmsford, UK. Email: [chowwhitney@yahoo.com](mailto:chowwhitney@yahoo.com).

**Background:** The plasmakinetic cautery is a surgical dissection instrument that combines scalpel-like cutting precision with electrocautery-like haemostasis properties, and operates at lower temperatures (40–170 °C) than conventional electrocautery (200–350 °C). The aim of this study is to evaluate the clinical benefits of using plasmakinetic cautery in abdominal free flap dissection for breast reconstruction.

**Methods:** Forty women undergoing abdominal-based microsurgical breast reconstruction (DIEP/MS-TRAM) were randomized to plasmakinetic cautery (n=20) or conventional electrocautery (n=20) for dissection of the abdominal free flap. Total abdominal wound drainage volume/duration, operation time and complications such as seroma and haematoma were examined.

**Results:** Age, body mass index, type of reconstruction and abdominal flap weight were similar in both groups. Mean abdominal drainage volume was (279±262) mL in conventional electrocautery group and (294±265) mL in plasmakinetic cautery group (P=0.853). Plasmakinetic cautery group mean drainage duration (4.3±2.2 days) was no difference compared to conventional diathermy group (3.8±2.0 days, P=0.501). Mean operation time in the conventional electrocautery group and plasmakinetic cautery group was 157±50 *vs.* 174±70 min respectively (P=0.195). There was more seroma detected in the conventional electrocautery group compared to plasmakinetic cautery group at days 7, 14 and 42 post-operation, but this was not statically significant. 2 haematomas in conventional diathermy group and 1 haematomas in the plasmakinetic cautery group required evacuation.

**Conclusions:** This study demonstrates that there are no significant differences between the use of plasmakinetic cautery and conventional electrocautery for abdominal free flap dissection.

**Keywords:** Breast reconstruction; plasmakinetic cautery; peak plasmablade; abdominal flap dissection; breast reconstruction complications; seroma

Submitted Oct 18, 2018. Accepted for publication Dec 11, 2018.

doi: [10.21037/gs.2018.12.04](https://doi.org/10.21037/gs.2018.12.04)

View this article at: <http://dx.doi.org/10.21037/gs.2018.12.04>

## Introduction

Breast cancer is the most common cancer affecting women in the UK (1). NICE guidelines [2009] recommend reconstruction following mastectomy (2). The abdomen is

regarded as an ideal source for reconstructive tissue, because large volumes may be available. In addition, abdominal tissue based reconstruction results in an acceptable donor site scar (3). Therefore, abdominal-based free flaps have become the gold standard method for breast reconstruction

**Table 1** Inclusion and exclusion criteria

Inclusion criteria
Age 18 to 80 years
Able to consent
Immediate or delay unilateral DIEP/MS-TRAM breast reconstruction
BMI 25–35 kg/m <sup>2</sup>
Exclusion criteria
Bilateral reconstruction
BMI <25 or >35 kg/m <sup>2</sup>
Active smoker
Diabetes
Ischaemic heart disease
Immunosuppression
Clotting disorder/liver dysfunction
On steroid medications

DIEP, deep inferior epigastric perforator; MS-TRAM, muscle sparing transverse rectus abdominis musculocutaneous; BMI, body mass index.

following mastectomy (4,5). Although it is a relatively safe procedure (6), extensive dissection of the abdominal tissue may lead to disruption of the normal lymphatic and vascular channels, resulting in seroma development (7). Postoperative donor site seroma can occur in up to 26% of patients undergoing abdominal-based free flap breast reconstruction (8-10). Donor site seroma is problematic in that patients often require multiple outpatient visits for evacuation or aspiration of the seroma. This can prolong recovery, delay wound healing and therefore, potentially interrupt post-operative adjuvant cancer treatment.

Commonly, abdominal flap dissection is performed using a handheld electrocautery device which generates temperatures up to 350 °C for tissue dissection. There are studies that suggest using electrocautery for abdominal tissues dissection can increase incidence of postoperative seroma (11,12). This has prompted surgeons to look for alternative devices such as the plasmakinetic energy device.

The plasmakinetic energy device, PEAK PlasmaBlade (Medtronic, Surrey, UK), dissects tissues at lower temperatures than electrocautery device (40–170 °C) (13). Previous studies suggest that operating at these lower temperatures would result in less inflammation, reduced thermal injury to the adjacent tissues, better wound healing

and clinically less wound drainage volume production when compared to electrocautery device (13-15).

This prospective randomized blinded study aims to investigate whether the use of the plasmakinetic cautery confers clinical benefits over conventional electrocautery diathermy in abdominal flap dissection during breast reconstruction.

## Methods

This study was approved by the NRES Committee East of England (REC reference: 13/EE/0346). Written informed consent was obtained from all subjects. This study was conducted at St Andrew's Centre for Plastic Surgery, Broomfield Hospital, Mid Essex Hospital NHS Services Trust, from January 2014 to November 2014.

After ethics approval patients were randomized to either plasmakinetic cautery or conventional electrocautery during the abdominal flap dissection of their breast reconstruction. All patients and assessors were blinded to which cutting instrument was used. All surgery was performed on consecutive patients by the two senior authors (VV Ramakrishnan and M Griffiths). Inclusion and exclusion criteria to the study were specified in *Table 1*.

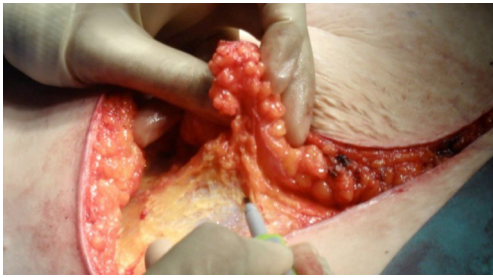
The primary outcome measure was total postoperative drainage volume. Secondary outcome measures were drainage duration, operation time and postoperative complications such as seroma and haematoma. Drainage volume and duration was measured from day 1 post operation to drain removal. Operation time was defined from the skin incision to complete closure of the abdomen. A seroma was defined as a postoperative fluid collection as detected by ultrasonic examination at postoperative day 7 prior to their discharge, and/or at the routine follow-up appointments (2 and 6 weeks). Haematoma was defined as a blood fluid collection, which requires evacuation or aspiration in outpatient patient clinic or return to theatre for bleeding control.

## Randomisation

All eligible patients were blindly randomised to either 'Group 1- Conventional electrocautery' or 'Group 2- Plasmakinetic cautery' with the ratio of 1:1, for the dissection of the abdominal free flap.

## Surgical technique

All patients had pre-operative CT-angiogram for surgical



**Figure 1** Dissecting abdominal free flap with plasmakinetic cautery.

planning. All patients received pre-operative prophylactic dose low molecular weight heparin the evening before surgery and continued every evening until the patient was discharged. In all cases, a scalpel was used to make the skin incision down to dermis, then depending on the randomization, conventional cautery or the plasmakinetic cautery (*Figure 1*) was used to dissect the flap down to Scarpa's fascia. The plasmakinetic device was set to coagulation mode with a range from 6 to 10, and conventional diathermy was used in the coagulation mode with range from 20 to 40. Bleeding vessels were cauterized except for large perforating branches, which were clipped with ligaclips (Ethicon, Johnson & Johnson, UK). Vicryl mesh (Ethicon, Johnson & Johnson, UK) was routinely placed under the rectus sheath on closure. In the abdomen, no quilting sutures were used. Two closed-suction drains were inserted at the inferior aspect of the wound before the closure of the abdominal wound in layers with 3/0 Vicryl to the fascia, Stratafix™ barbed sutures to dermis and Dermbond topical skin adhesive for wound final approximation. The overall operation time for the dissection of the abdominal flap to complete closure of the abdomen were recorded.

After surgery, all patients were treated according to a standardized protocol. All patients were given intravenous antibiotic for 2 days followed by oral course for 5 days. Abdominal compression garments (9-inch abdominal binder, Marena) were for 6 weeks postsurgery. Abdominal drainage output was recorded daily at 7 am and drains were only removed when drainage was less than 30 mL in 24 hours. The drainage duration over 24 hours was noted. Any complications required return to theatre for intervention such as donor site haematoma and seroma were documented.

### Follow-up

Clinical assessment of abdominal wound was performed

daily for up to 7 days during their in-patient stay. All subjects had an ultrasound scan of the abdomen at days 7, 14 and 42 post-operation to detect any fluid collection. All non-symptomatic collection was noted with no further intervention performed, unless it became symptomatic. If seroma is detected, this would be aspirated under ultrasound guidance using a needle to dryness, and the volume removed would be recorded.

### Statistical analysis

The sample size was calculated based on 5% significance, 80% power, to detect a difference in total abdominal drainage volume by 11%, based on Dogan *et al.* [2013], who investigated the effect of using plasmakinetic cautery for mastectomy without reconstruction.

Statistical analysis was performed using Prism 7 version 7.0 (GraphPad Software, USA). Continuous variables were compared using *t*-test and categorical variables were compared using Fisher's Exact test. Analysis of covariance was used to compare the total drainage volumes between the plasmakinetic cautery and conventional electrocautery groups taking into account the two different surgeons as a separate variable.  $P < 0.05$  was used for determination of statistical significance.

## Results

### Patient demographics (Table 2)

Both groups had similar baseline characteristics including age, BMI, type of reconstruction, and weight of abdominal flap harvested. The women were predominantly Caucasian, middle-aged and had a BMI average of  $29 \pm 2.9$  in group 1 (conventional electrocautery) and  $27.9 \pm 2.4$  in group 2 (plasmakinetic cautery). The mean resection flap weights were  $897.5 \pm 328.4$  g in group 1 and  $875 \pm 327$  g in group 2. Mean operation time was  $157 \pm 50$  min in group 1 and  $174 \pm 70$  min in group 2 ( $P = 0.195$ ).

### Wound drainage (Table 3)

Mean drainage volume was  $279 \pm 262$  mL in group 1 and  $294 \pm 265$  mL in group 2 ( $P = 0.853$ ). Similarly, there was no significant difference in the drainage duration between group 1 ( $4.3 \pm 2.2$  days) and group 2 ( $3.8 \pm 2.0$  days,  $P = 0.501$ ).

The two different surgeons were factored into the statistical analyses as an additional variable and found

**Table 2** Baseline characteristics of patients

Characteristics	Conventional electrocautery (n=20)	Plasmakinetic cautery (n=20)	P value
Age (years)	55±8.2	54±8.9	NS
BMI (kg/m <sup>2</sup> )	29±2.9	27.9±2.4	NS
Type of reconstruction			
DIEP	20 [100]	19 [95]	NS
MS-TRAM	0 [0]	1 [5]	NS
Weight of flap (g)	897.5±328.4	875±327	NS
Number of perforators			
1	11 [55]	12 [60]	NS
2	9 [45]	8 [40]	NS

Data are shown as mean ± SD or number [percentage]. BMI, body mass index; DIEP, deep inferior epigastric perforator flap; MS-TRAM, muscle sparing transverse rectus abdominis musculocutaneous flap; NS, not significant.

**Table 3** Comparative results of drain-related and operation outcomes

Parameters	Conventional electrocautery (n=20)	Plasmakinetic cautery (n=20)	P value
Drainage duration <sup>a</sup> (day)	3.8±2.0	4.3±2.2	0.501
Drainage volume <sup>a</sup> (mL)	279±261.7	294±264.7	0.853
Operation duration <sup>a</sup> (min)	157±50.3	174±69.6	0.195
Seroma <sup>#</sup>			
POD 7	3 [15.8] <sup>b</sup>	1 [5.0]	0.342
POD 14	10 [50.0]	4 [21.1]	0.096
POD 42	6 [31.6]	3 [16.7] <sup>c</sup>	0.447
Complications requiring treatment			
Seroma	1 [5]	0 [0]	NS
Haematoma	2 [10]	1 [5]	NS

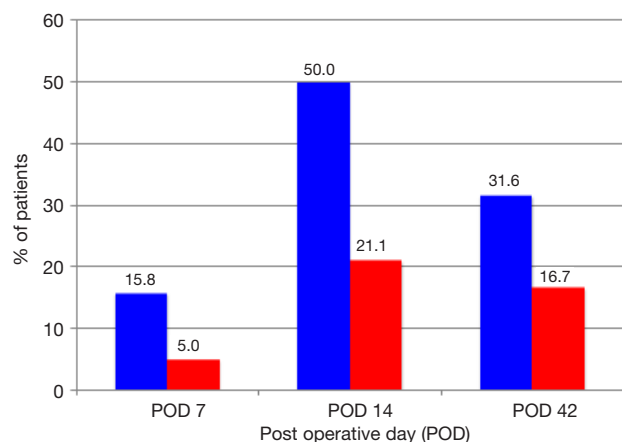
Data are shown as mean ± SD or number [percentage]. <sup>#</sup>, one seroma required drainage in the conventional electrocautery group because of patient discomfort. <sup>a</sup>, P value calculated with unpaired student *t*-test; <sup>b</sup>, data for one patient is missing; <sup>c</sup>, data for two patients are missing. POD, postoperative day; Seroma, serous fluid collection in wound; Haematoma, blood stained collection in wound; NS, not significant.

there were no significant differences between operation time, drainage volume and drainage duration between the plasmakinetic cautery and conventional electrocautery

**Table 4** Outcome (drainage volume, drainage duration and operation time) measures between the two surgeons

Variables	Surgeon I	Surgeon II	P value
Drainage volume (mL)			
Conventional electrocautery	241±269	388±230	0.24
Plasmakinetic cautery	284±296	355±65	0.739
Drainage duration (day)			
Conventional electrocautery	3±2	5±2	0.196
Plasmakinetic cautery	4±2	6±1	0.217
Operation time (min)			
Conventional electrocautery	155±55	166±35	0.684
Plasmakinetic cautery	175±73	173±62	0.961

P value calculated with unpaired *t*-test.

**Figure 2** Percent of patients with seroma on postoperative days (POD) 7, 14 and 42 in conventional electrocautery group (blue) and plasmakinetic cautery group (red).

groups (Table 4).

### Complications

In the conventional electrocautery group, there were 3, 10 and 6 seromas detected at days 7, 14 and 42 post-operation respectively. In the plasmakinetic cautery group, there were 1, 4 and 3 seromas detected at days 7, 14 and 42 post-operation respectively, with no statistical significant differences between the two groups in the prevalence of seroma at any of the time points (Figure 2). One seroma in the conventional electrocautery group required drainage during their outpatient visit at 14 days post-operation.

There were 2 haematomas in conventional electrocautery group and 1 haematoma in the plasmakinetic cautery group which required further surgery to evacuate the haematoma.

## Discussion

The UK national audit of 1,009 women who underwent mastectomy with immediate or delayed autologous breast reconstruction reported that the most common donor site complications were haematoma and seroma, accounting for up to 8% (16). Nearly 50% of those receiving a mastectomy alone or with immediate reconstruction required drainage of collection, whereas 33% of those undergoing delayed reconstruction required drainage of a collection. In addition, one in four patients in this audit need antibiotics post-discharge for treatment of suspected wound infection, indicating that following mastectomy and breast reconstruction, a significant number of patients suffer post-operative complications.

The purpose of this study was to evaluate if plasmakinetic cautery could improve clinical outcomes in abdominal free flap breast reconstruction surgery. Management of seromas is labour-intensive, which often require multiple outpatient visits for drainage (17). Seromas also increase the risks of developing other wound complications such as infection and wound breakdown (18). Therefore, potential deleterious consequences of seromas include prolonged recovery and delays in receiving any necessary adjuvant chemo/radiotherapy for satisfactory treatment of the breast cancer.

The plasmakinetic cautery used pulsed radiofrequency energy to stimulate a plasma-mediated discharge along the blade, for precise tissue dissection and haemostasis using lower temperature generated than traditional electrocautery, thus reducing collateral thermal damage. This had been demonstrated in studies performed in swine and human abdominal skin (13,14). The present study showed no statistical difference in the drainage volume/duration and operation time in the plasmakinetic cautery group compared to conventional electrocautery group. Not every high-draining wound will lead to development of a clinically apparent seroma, and there may be other less well-understood clinical/biological factors which may determine risk of seroma development. Indeed, the composition of the seroma fluid may warrant future investigation to determine relevant biomarkers associated with improved wound healing (13,14), however, these investigations on

the composition of wound drainage fluid are not currently performed normally in clinical practice.

There is only one other clinical study reported in the literature and this was the use of plasmakinetic cautery in breast surgery, which demonstrated in 46 radical mastectomy patients without reconstruction a mean reduction of 386 mL in wound drainage volume, mean reduction of drainage duration by 2.4 days with no increase in operation times and post-operative complications (15). In this published study, the authors believed that the plasmakinetic cautery causes less devitalization of tissue and lysis of subcutaneous fat which had resulted in shorter drainage amount and duration. However, mastectomy and abdominal free tissue flap dissection are very different procedure, the composition of fat contents between breast and abdomen are also very different, which could be the reason for the difference in finding between their paper and the current study.

Seroma following surgery is usually a clinical diagnosis as the majority of small-volume, non-palpable seromas are not routinely identified (19), they can cause further wound problems if they persist (18), which would support the rationale for using ultrasound examination to detect subclinical seromas as in this study. Ultrasonography is an inexpensive, reliable and convenient tool for detection of fluid collections in tissues. It provides a valuable guide for accurate aspiration and drainage of collections, and may be used in outpatient clinics as a useful diagnostic or interventional adjunct to clinical examination (20-23). Di Martino *et al.* suggested that most seromas were detected at day 14 postoperatively (24,25). Our study showed similar results with 50% of patients in the traditional electrocautery group and 21% of patients in the PEAK PlasmaBlade group developing seromas. While this was not statistically significant it may well be clinically significant and further studies with larger numbers may be required to further investigate this. The seroma incidences in our study were higher than those from Jeevan *et al.* (16), who published a national survey of complications following mastectomy and breast reconstruction. However in our study, seromas were detected with ultrasound examination which is more sensitive and therefore, higher incidences of seromas would be identified than if only clinical examination was performed. In addition the methods were not clearly described and differences might be attributable to self-reporting of complications.

Patient selection is crucial to reduce postoperative complication in DIEP/MS-TRAM breast reconstruction

surgery (26-28). An ideal patient for DIEP breast reconstruction would be a young, non-smoker, BMI <35, non-diabetic and no history of cardiovascular disease (29). Our study was set up with very controlled inclusion and exclusion criteria, such that high-risk patients with comorbidities that impact on wound healing were excluded. Our study did however show a trend towards seroma detected by ultrasound was increased in the conventional group compared to the plasmakinetic group. It is possible therefore, that the clinical benefit of this device over conventional diathermy would be more apparent if the study was conducted in a larger cohort of patients, broader inclusion criteria more relevant to the general population of patients that we would treat, as would including multiple centres that perform abdominal based free flap reconstruction.

If the use of this new dissection device in DIEP/MS-TRAM breast reconstruction surgery would reduce complications such as seroma and haematoma, this could lead to a cost saving from needing further hospital visits and hospitalization. In addition this might have applications beyond breast reconstructive surgery, in other aesthetic realm where extensive tissue dissection is required. This device could be used for procedures such as abdominoplasty or body contouring surgeries following massive weight lost.

## Conclusions

This study demonstrated although there was no significant difference in the donor site drainage volume/duration, and overall postoperative incidence of seroma/haematoma between the two randomized groups, there was a trend towards less seromas in the plasmakinetic cautery group. This is in keeping with other studies in the literature. Future randomized controlled studies with larger sample size would be required to show whether the plasmakinetic cautery confers a postoperative benefit for abdominal flap dissection in breast reconstruction surgery over conventional electrocautery.

## Acknowledgments

None.

## Footnote

*Conflicts of Interest:* The authors have no conflicts of interest

to declare.

*Ethical Statement:* This study was approved by the NRES Committee East of England (REC reference: 13/EE/0346). Written informed consent was obtained from all subjects.

## References

1. Cancer Research UK. Breast cancer incidence statistics. 2014; Available online: <http://www.cancerresearchuk.org/health-professional/cancer-statistics/statistics-by-cancer-type/breast-cancer/incidence-invasive>. Accessed April 5, 2016.
2. National Institute for Health and Care Excellent. NICE guidance2009. Early and locally advanced breast cancer: diagnosis and treatment. Available online: <https://www.nice.org.uk/guidance/CG80/chapter/1-Guidance#breast-reconstruction>. Accessed April 5, 2016.
3. Niddam J, Bosc R, Lange F, et al. DIEP flap for breast reconstruction: retrospective evaluation of patient satisfaction on abdominal results. *J Plast Reconstr Aesthet Surg* 2014;67:789-96.
4. Allen RJ, Treece P. Deep inferior epigastric perforator flap for breast reconstruction. *Ann Plast Surg* 1994;32:32-8.
5. Blondeel PN. One hundred free DIEP flap breast reconstructions: a personal experience. *Br J Plast Surg* 1999;52:104-11.
6. Zoghbi Y, Gerth DJ, Tashiro J, et al. Deep Inferior Epigastric Perforator Versus Free Transverse Rectus Abdominis Myocutaneous Flap: Complications and Resource Utilization. *Ann Plast Surg* 2017;78:516-20.
7. Fang RC, Lin SJ, Mustoe TA. Abdominoplasty flap elevation in a more superficial plane: decreasing the need for drains. *Plast Reconstr Surg* 2010;125:677-82.
8. Salgarello M, Tambasco D, Farallo E. DIEP flap donor site versus elective abdominoplasty short-term complication rates: a meta-analysis. *Aesthetic Plast Surg* 2012;36:363-9.
9. Venkat R, Lee JC, Rad AN, et al. Bilateral autologous breast reconstruction with deep inferior epigastric artery perforator flaps: Review of a single surgeon's early experience. *Microsurgery* 2012;32:275-80.
10. Seidenstuecker K, Munder B, Mahajan AL, et al. Morbidity of microsurgical breast reconstruction in patients with comorbid conditions. *Plast Reconstr Surg* 2011;127:1086-92.
11. Swanson E. Reducing seroma rates after abdominoplasty by avoiding electrodissection. *J Plast Reconstr Aesthet Surg* 2015;68:864-5.
12. Rousseau P, Vincent H, Potier B, et al.

- Diathermocoagulation in cutting mode and large flap dissection. *Plast Reconstr Surg* 2011;127:2093-8.
13. Loh SA, Carlson GA, Chang EI, et al. Comparative healing of surgical incisions created by the PEAK PlasmaBlade, conventional electrosurgery, and a scalpel. *Plast Reconstr Surg* 2009;124:1849-59.
  14. Ruidiaz ME, Messmer D, Atmodjo DY, et al. Comparative healing of human cutaneous surgical incisions created by the PEAK PlasmaBlade, conventional electrosurgery, and a standard scalpel. *Plast Reconstr Surg* 2011;128:104-11.
  15. Dogan L, Gulcelik MA, Yuksel M, et al. The effect of plasmakinetic cautery on wound healing and complications in mastectomy. *J Breast Cancer* 2013;16:198-201.
  16. Jeevan R, Cromwell DA, Browne JP, et al. Findings of a national comparative audit of mastectomy and breast reconstruction surgery in England. *J Plast Reconstr Aesthet Surg* 2014;67:1333-44.
  17. Kuroi K, Shimozuma K, Taguchi T, et al. Pathophysiology of seroma in breast cancer. *Breast Cancer* 2005;12:288-293.
  18. Sadeghi A, Malata C. CASE REPORT Persistent Seromas in Abdominal Free Flap Donor Sites After Postmastectomy Breast Reconstruction Surgery: Case Reports and Literature Review. *Eplasty* 2013;13:e24.
  19. Mohammad JA, Warnke PH, Stavrakys W. Ultrasound in the diagnosis and management of fluid collection complications following abdominoplasty. *Ann Plast Surg* 1998;41:498-502.
  20. Ahmed M, Abdullah N, Cawthorn S, et al. Why should breast surgeons use ultrasound? *Breast Cancer Res Treat* 2014;145:1-4.
  21. Thomason K, Cooke PH. The use of surgeon-performed ultrasound assessment in a foot and ankle clinic. *Foot Ankle Surg* 2012;18:213-5.
  22. Bennett IC, Biggar MA. The role of ultrasound in the management of breast disease. *Australas J Ultrasound Med* 2011;14:25-8.
  23. Lee SH, Kim YJ. Managing a seroma with wireless mobile ultrasound device. *J Plast Reconstr Aesthet Surg* 2017;70:e7-9.
  24. Di Martino M, Nahas FX, Barbosa MV, et al. Seroma in lipoabdominoplasty and abdominoplasty: a comparative study using ultrasound. *Plast Reconstr Surg* 2010;126:1742-51.
  25. Di Martino M, Nahas FX, Kimura AK, et al. Natural evolution of seroma in abdominoplasty. *Plast Reconstr Surg* 2015;135:691e-8e.
  26. Chang DW, Wang B, Robb GL, et al. Effect of obesity on flap and donor-site complications in free transverse rectus abdominis myocutaneous flap breast reconstruction. *Plast Reconstr Surg* 2000;105:1640-8.
  27. Chang DW, Reece GP, Wang B, et al. Effect of smoking on complications in patients undergoing free TRAM flap breast reconstruction. *Plast Reconstr Surg* 2000;105:2374-80.
  28. Scheer AS, Novak CB, Neligan PC, et al. Complications associated with breast reconstruction using a perforator flap compared with a free TRAM flap. *Ann Plast Surg* 2006;56:355-8.
  29. Garcia-Tutor E, Murillo J. The ideal patient for the first breast reconstruction using a diep flap. *Plast Reconstr Surg* 2003;111:947-8.

**Cite this article as:** Chow WT, Oni G, Ramakrishnan VV, Griffiths M. The use of plasmakinetic cautery compared to conventional electrocautery for dissection of abdominal free flap for breast reconstruction: single-centre, randomized controlled study. *Gland Surg* 2019;8(3):242-248. doi: 10.21037/gs.2018.12.04