



# Subxiphoid thymectomy with a double sternum retractor: a pilot study

Beatrice Aramini<sup>1,2#</sup>, Nan Song<sup>2#</sup>, Federico Banchelli<sup>3</sup>, Gening Jiang<sup>2</sup>, Diego Gonzalez-Rivas<sup>2</sup>, Jiang Fan<sup>2</sup>

<sup>1</sup>Division of Thoracic Surgery, Department of Medical and Surgical Sciences for Children and Adults, University of Modena and Reggio Emilia, Modena, Italy; <sup>2</sup>Department of Thoracic Surgery, Shanghai Pulmonary Hospital, Tongji University School of Medicine, Shanghai 200433, China; <sup>3</sup>Center of Statistic, Department of Medical and Surgical Sciences for Children and Adults, University of Modena and Reggio Emilia, Modena, Italy  
*Contributions:* (I) Conception and design: J Fan; (II) Administrative support: G Jiang, D Gonzalez-Rivas; (III) Provision of study materials or patients: J Fan, N Song; (IV) Collection and assembly of data: B Aramini, N Song; (V) Data analysis and interpretation: B Aramini, F Banchelli, N Song; (VI) Manuscript writing: All authors; (VII) Final approval of manuscript: All authors.

<sup>#</sup>These authors contributed equally to this work.

*Correspondence to:* Jiang Fan, MD, PhD. Associate Professor in Thoracic Surgery, Department of Thoracic Surgery, Shanghai Pulmonary Hospital, Tongji University School of Medicine, Shanghai 200433, China. Email: fan\_jiang@tongji.edu.cn.

**Background:** Our study aims to describe the experience of a single team in terms of the potential and benefits of subxiphoid thymectomy using a double sternum hook retractor.

**Methods:** From November 2016 to July 2018, 34 patients have been undergone subxiphoid thymectomy at our Department. Twenty patients were diagnosed with Masaoka Stage I–III thymomas, 12 with thymic hyperplasia or cysts of the thymus, 2 with thymic tumors. All patients underwent a chest computed tomography (CT) with enhancement. 18-Fluorodeoxyglucose positron emission tomography (<sup>18</sup>F-DG-PET) was performed when recurrence was suspected. Neurological examinations were set. Patients underwent video-assisted thoracoscopic surgery (VATS) subxiphoid thymectomy with a double sternum retractor. A retrospective analysis of clinical, perioperative data, and follow-up was performed. Incidence rates for death or recurrence were calculated. Average pain score (NRS scale), average mental health, and physical health scores (SF-12) were analyzed.

**Results:** Thirty-four patients (mean age 54; 12 men and 22 women) with thymic neof ormation (from 1.0 cm × 1.0 cm × 1.0 cm to 14.0 cm × 9.0 cm × 4.5 cm) were enrolled. All patients underwent subxiphoid thymectomy. No mortality or recurrence was observed. Median follow-up time was 17.9 months (range, 2.2–23.3 months). The morbidity rate was 9.7 events per 100 person-years. Average pain scores after surgery and after follow-up were 1.7±0.4 and 0.1±0.4, respectively; average mental health and physical health scores on the SF-12 scale were 45.6±2.4 and 33.6±2.4, respectively.

**Conclusions:** Subxiphoid thymectomy is a high satisfaction approach with positive aesthetic outcomes and low pain. Double sternum retractors are especially useful for creating space during thymectomy. However, the qualified experience is needed.

**Keywords:** Subxiphoid thymectomy; minimally invasive; thymoma; thymic carcinoma; retractors

Submitted Oct 20, 2019. Accepted for publication Nov 12, 2019.

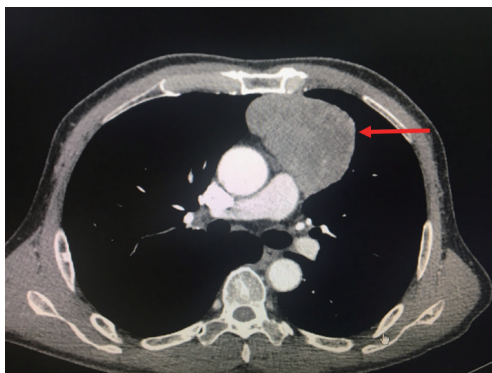
doi: 10.21037/gs.2019.11.05

View this article at: <http://dx.doi.org/10.21037/gs.2019.11.05>

## Introduction

The performance of thymectomies via the subxiphoid approach was first introduced by Kido *et al.* in 1999 (1,2). Since then, many new aspects of this approach have been introduced, such as the lifting of the sternum through

CO<sub>2</sub> insufflation and a sternum retractor (3). Because a camera is inserted through the midline subxiphoid region, the operative view of the neck region and locations of the bilateral intercostal nerves are easily accessible, particularly with the help of a sternum retractor (1). In particular, the subxiphoid approach is an excellent technique for



**Figure 1** A chest CT that is showing the thymic mass (arrow).

both surgeons and patients because the operative field in the neck region is secured, bilateral phrenic nerve identification is possible, cosmetic outcomes are superior, and pain is minimal (4). The introduction of the double hook before the operation is critical to creating more space for the surgeon. One hook is usually placed at the level of the manubrium and one at the level of the subxiphoid process.

In our pilot study, we enrolled 34 patients who underwent thymectomy using the subxiphoid approach for an anterior mediastinal benign or resectable malignant tumor, and double sternum hooks were used to improve our vision of the anatomical structures and create a better space during resection. This study aims to determine the safety and usefulness of the subxiphoid approach associated with the use of sternum retractors.

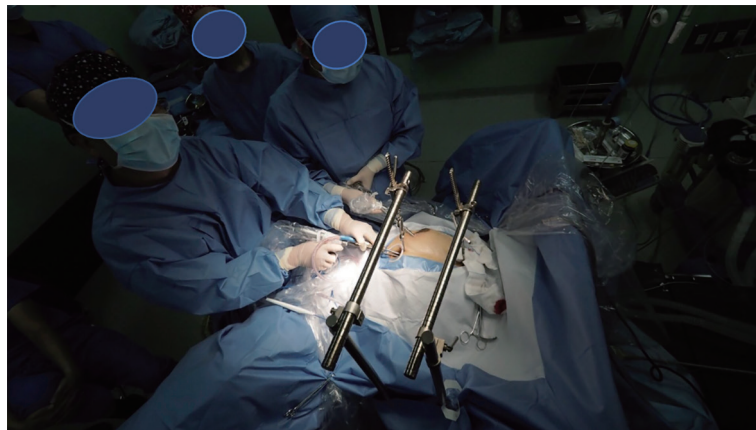
## Methods

From November 2016 until July 2018, we enrolled 34 patients who underwent subxiphoid thymectomy with a double sternum retractor in our Thoracic Surgery Department. The Ethics Board Committee approved the study, and each patient provided written informed consent before enrollment. The Masaoka staging system was adopted as commonly used for thymomas (5), in particular, stage I represented by intact thymic capsule, stage II represented by capsular invasion into adjacent mediastinal fat or pleura, stage III represented by macroscopic invasion into adjacent organs, vessels. Twenty of these patients were diagnosed with Masaoka Stage I–III thymomas, 12 with thymic hyperplasia or cysts of the thymus, and 2 with thymic tumors. All patients underwent a chest CT with enhancement (*Figure 1*).  $^{18}\text{F}$ FDG-PET was performed

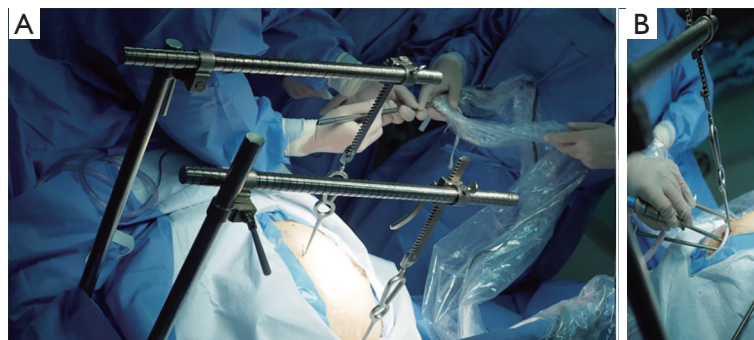in patients with thymomas or when recurrence was suspected. Anti-acetylcholine receptor (AChR) antibody levels were measured in all patients, and a neurological assessment was performed. Patients underwent subxiphoid thymectomy using a video-assisted thoracoscopic surgery (VATS) approach and the elevation of the sternum with a double retractor. A retrospective analysis of the clinical characteristics, operative data, postoperative events, such as the average pain score (NRS scale) (6,7) after surgery and average mental health and physical health scores (SF-12) (8), and follow-up was performed.

## Operative technique

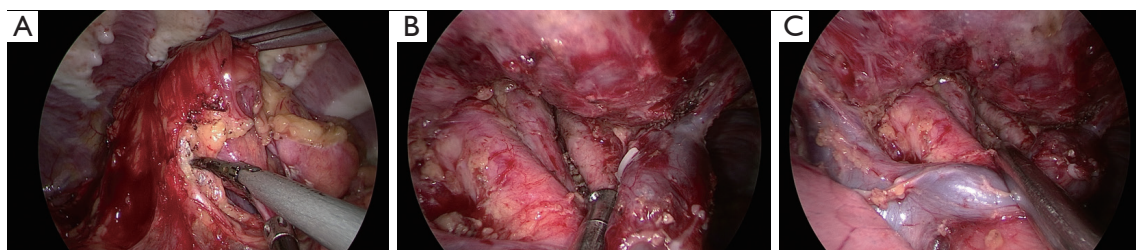
Subxiphoid thymectomy is performed in an intubated patient placed in the supine position. The operator stands between the legs and the surgical assistant to the right of the patient. A 4-cm vertical incision approximately 1-cm caudal to the xiphoid process and an additional 2-cm skin incision between the 4<sup>th</sup> and 5<sup>th</sup> intercostal anterior axillary line on the right side is usually performed (*Figure 2*). A 1-cm incision is generated to place hooks, which are tightened by two retractors: one at the level of the jugular process behind the manubrium of the sternum and the other one behind of the lower portion of the sternum after resection of the subxiphoid process, connected to a traction frame (*Figure 3*). The surgeon detaches the thymus and proceeds along the innominate vein by closing the thymic veins with vascular clips until the left internal thoracic vein is visualized. The dissection continues cranially with closure and division of the lower thyroid veins. The left lobe of the thymus is pulled toward the right side of the patient. At this point, the surgeon detaches the left lobe with an electronic device. The right lobe of the thymus is pulled towards the left side of the patient. The superficial adipose tissue is gradually detached from the area to expose the distal side of the left brachiocephalic vein safely. The neck portion is identified, and the thin membrane above the thymus is dissected. The superior pole of the thymus and the cervical adipose tissue are dissected from the right brachiocephalic vein on the right side, the thyroid at the upper end, the brachiocephalic artery and trachea on the posterior aspect, and the left brachiocephalic vein on the left side (*Figure 4*). Finally, the thymus is pulled to either the right or left and dissected from the innominate vein. All the fatty tissue around the thymus is removed to guarantee the cleanness of the margins. In sequential



**Figure 2** Intraoperative view during subxiphoid thymectomy.



**Figure 3** Subxiphoid thymectomy technique. (A) Hook placement and bars to elevate the sternum; (B) subxiphoid access and hook placement in the subxiphoid process.



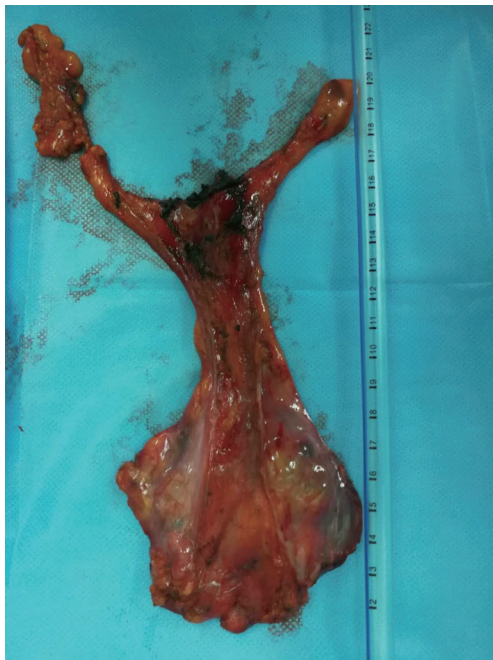**Figure 4** Subxiphoid thymectomy (thoracoscopic images). (A) Pericardial fat resection; (B) dissection along the main vessels; (C) the thymus is wholly removed.

order, the thymic vein is dissected using the electronic device, and the thymectomy is completed (*Figure 5*).

#### **Statistical analysis**

Quantitative data are presented as medians and ranges,

while qualitative data are presented as absolute and percentage frequencies. The incidence rates of mortality and complications were calculated as the number of events per 100 person-years. Patient pain was measured using a Numerical Rating Scale (NRS) ranging from 0 (no pain) to 10 (maximum pain) points (6,7), and quality of life was



**Figure 5** Thymoma and thymus tissue.

measured using the SF-12 questionnaire (8). Pain and quality of life were reported as average scores  $\pm$  standard deviations.

## Results

From November 2016 until July 2018, 34 patients were enrolled, with a median age of 56.5 years (range, 25–71 years); 12 (35.3%) were men and 22 (64.7%) women. Thymic neof ormation ranged from 1.0 cm  $\times$  1.0 cm  $\times$  1.0 cm to 14.0 cm  $\times$  9.0 cm  $\times$  4.5 cm. PET-FDG showed hypermetabolism (SUV max  $>$ 2.5) in 23 (69%) of patients. Neurological signs and the AChR antibody were positive in only 3 (15%) patients with thymomas. All patients underwent a subxiphoid thymectomy. The median operative time in all the stages considered was 2 hours (range, 1.3–4.0 hours), and intraoperative bleeding was 94 cc (range, 20–500 cc). A double hook was placed to elevate the sternum in all patients. Histology was positive in 20 patients with Masaoka Stage I–III thymomas, in 12 with thymic hyperplasia or cysts of the thymus and 2 with thymic tumors. No mortality or recurrence was observed after a median follow-up time of 17.9 months after surgery (range, 2.2–23.3 months). Complications occurred in 3 patients for a myasthenic crisis and two patients for diaphragmatic

palsy. The mortality rate was zero, and the morbidity rate for complications was 8.8%. The average pain scores after surgery and after follow-up were  $1.7 \pm 0.4$  and  $0.1 \pm 0.4$ , respectively, on the NRS scale. Average mental health and physical health scores after follow-up were  $45.6 \pm 2.4$  and  $33.6 \pm 2.4$ , respectively, on the SF-12 scale.

## Discussion

Although VATS provides clear benefits during thymus removal, it also has some disadvantages for the operator, such as the placement of long instruments through fixed entry points to create a fulcrum effect, bidimensional screen vision of the surgical field, and the creation of an unnatural visual effect that can cause the surgeon to lose the orientation and the eye-hand target axis when the camera is under an assistant's control (9,10). Some robotic systems have been developed over the last two decades to overcome these limitations (11). However, few centers currently can use a robot, due to the costs (11,12). Subxiphoid thymectomy is considered a good compromise between robotic and VATS surgery to remove benign and no infiltrated malignant tumors, reducing the probability of intercostal nerve injuries (13). The benefits of this technique are the reduction in pain after surgery, the aesthetic result, and the lower costs. We strongly believe that the subxiphoid approach may be useful not only for removing small thymomas but also in treating more difficult selected cases. In particular, the use of double sternum retractors may be the best solution to visualize the mass at the level of the anterior mediastinum, particularly in patients with large tumors that infiltrate the tissue around the mass. The use of double sternum retractors provides the surgeon with a better view of the tumor, improving the surgical technique, and offers the possibility to remove the fat around the thymus altogether. This aspect is vital to ensure the radicality related to the surgical margins, although the VATS approach is limited and more static because the surgical instruments can only be manipulated in a limited space. This difficulty experienced during VATS surgery may affect the surgeon during the operation, reducing the concept of radicality. However, the subxiphoid approach is not yet considered the most common technique used to remove thymic masses because of one main disadvantage, the difficulty of this unusual uniportal approach. This technique not only relies on the experience of the surgeon but also the physical conformation of the patient. In some situations, obese patients and long-limbed patients may

**Table 1** Subxiphoid thymectomy and unilateral VATS approaches

No.	Author and publication	Technique	No. of patients/No. of patients with MG	Masaoka stage/tumor dimension (cm)
1	Uchiyama <i>et al.</i> 2004 (14)	Substernal VATS	16/11	I–13; II–1; III–2
2	Zieliński <i>et al.</i> 2013 (4)	Subxiphoid right VATS	24/11	I–21; II–0; III–3
3	Numanami <i>et al.</i> 2018 (15)	Subxiphoid VATS	36/19	4.1±2.3 cm (1.2–9.0 cm). <3.0 cm (n=17); 3.0≤ MD <5.0 cm (n=8); 5.0≤ MD <7.0 cm (n=8); ≥7.0 (n=3)
4	Yano <i>et al.</i> 2017 (16)	Subxiphoid VATS/lateral VATS	60/33	4.5±2.7 (n=14) subxiphoid thymectomy; 4.3±3.3 (n=46) lateral approach
5	Suda <i>et al.</i> 2016 (13)	Subxiphoid VATS/lateral VATS	146/46	2.92±1.66 cm, subxiphoid; 3.09±1.63 VATS lateral
6	Sakamakiet <i>et al.</i> 2014 (17)	Unilateral VATS/11; infrasternal mediastinal total/19	82/13	I–44; II–38
7	Okada <i>et al.</i> 2010 (18)	Unilateral VATS subtotal	22/0	I–II
8	Agasthian <i>et al.</i> 2017 (19)	Unilateral VATS subtotal	58/32	I/IVA
9	Yim <i>et al.</i> 1995 (20)	Right VATS	21	NA
10	Mineo <i>et al.</i> 2000 (21)	Left VATS	31	NA

VATS, video-assisted thoracoscopic surgery; NA, not available.

increase the difficulty of the surgery. Obese patients present with a small thorax, and double sternum retractors may be a beneficial instrument to create more space at the level of the thymic mass. We believe that extensive training is needed for surgeons to learn the highly specific technique of single-port surgery (9,13), particularly in the case of the subxiphoid approach. VATS subxiphoid thymectomy was developed many years ago and has continuously evolved from open to minimally invasive surgery, and in particular, from bilateral VATS to single port right or left VATS an ultimately to the monoportal subxiphoid approach (*Table 1*) (14–21). However, regarding the subxiphoid access, some operators regularly use two ports, one along the subxiphoid process and one between the 4<sup>th</sup> and 5<sup>th</sup> intercostal anterior axillary line on the right side for camera placement. This method improves the learning curve, reducing the risks of bleeding and intraoperative surgical complications. In 2017, Zieliński *et al.* reported the use of the hooks and described the technique of minimally invasive extended thymectomy performed through the uniportal subxiphoid approach for patients with nonthymomatous myasthenia gravis (MG) (22). In our case, we used the hooks for patients with thymomatous and nonthymomatous MG, as well as two patients with thymic carcinoma.

In summary, subxiphoid thymectomy could be extended

to severe cases, such as large thymomas or thymic tumors infiltrating the pericardium or vessels; however, this approach should only be used in very selected cases, in high volume centers and by surgeons who are already well-trained in monoportal surgery with a high level of experience in this field. We strongly support the hypothesis that the use of the hooks in subxiphoid thymectomy is beneficial and facilitates the dissection by the surgeon, particularly in patients with large tumors where the visibility and the access of the anterior mediastinum are not guaranteed. Our experience obtained in this pilot study highlights the importance of the use of double sternum retractors in subxiphoid thymectomy for beginners and trained surgeons, particularly in challenging cases. This study proved the baseline for further investigations aiming to analyze the long-term results in a larger cohort of patients.

### Acknowledgments

**Funding:** This Project has been funded by the National Natural Science Foundation of China (No. 81870008) and Shanghai Municipal Health Commission Special Program for Clinical Research in Health Industry (No. 201840175).

## Footnote

*Conflicts of Interest:* The authors have no conflicts of interest to declare.

*Ethical Statement:* The authors are accountable for all aspects of the work in ensuring that questions related to the accuracy or integrity of any part of the work are appropriately investigated and resolved. Ethical Board Committee approved this study. Each patient signed a consent form to be enrolled.

## References

- Shi Y, Sun F, Jin Y, et al. Subxiphoid approach with sternum retractor for mediastinal tumor cephalad to brachiocephalic vein. *J Thorac Dis* 2018;10:E473-E475.
- Kido T, Hazama K, Inoue Y, et al. Resection of anterior mediastinal masses through an infrasternal approach. *Ann Thorac Surg* 1999;67:263-5.
- Takeo S, Sakada T, Yano T. Video-assisted extended thymectomy in patients with thymoma by lifting the sternum. *Ann Thorac Surg* 2001;71:1721-3.
- Zieliński M, Czajkowski W, Gwozdz P, et al. Resection of thymomas with use of the new minimally-invasive technique of extended thymectomy performed through the subxiphoid-right video-thoracoscopic approach with double elevation of the sternum. *Eur J Cardiothorac Surg* 2013;44:e113-9; discussion e119.
- Detterbeck FC, Nicholson AG, Kondo K, et al. Masaoka-Koga Stage Classification for Thymic Malignancies Clarification and Definition of Terms. *J Thorac Oncol* 2011;6:S1710-6.
- Bieri D, Reeve R, Champion GD, et al. The Faces Pain Scale for the self-assessment of the severity of pain experienced by children: development, initial validation and preliminary investigation for ratio scale properties. *Pain* 1990;41:139-50.
- Jensen MP, McFarland CA. Increasing the reliability and validity of pain intensity measurement in chronic pain patients. *Pain* 1993;55:195-203.
- Ware J, Kosinski M, Keller SD. A 12-item short-form health survey: construction of scales and preliminary tests of reliability and validity. *Med Care* 1996;34:220-33.
- Suda T. Single-port thymectomy using a subxiphoid approach—surgical technique. *Ann Cardiothorac Surg* 2016;5:56-8.
- Suda T, Kaneda S, Hachimaru A, et al. Thymectomy via a subxiphoid approach: single-port and robot-assisted. *J Thorac Dis* 2016;8:S265-71.
- Simorov A, Otte RS, Kopietz CM, et al. Review of surgical robotics user interface: what is the best way to control robotic surgery? *Surg Endosc* 2012;26:2117-25.
- Buentzel J, Straube C, Heinz J, et al. Thymectomy via open surgery or robotic video assisted thoracic surgery. Can a recommendation already be made? *Medicine (Baltimore)* 2017;96:e7161.
- Suda T, Hachimaru A, Tochii D, et al. Video-assisted thoracoscopic thymectomy versus subxiphoid single-port thymectomy: initial results†. *Eur J Cardiothorac Surg* 2016;49 Suppl 1:i54-8.
- Uchiyama A, Shimizu S, Murai H, et al. Infrasternal mediastinoscopic surgery for anterior mediastinal masses. *Surg Endosc* 2004;18:843-6.
- Numanami H, Yano M, Yamaji M, et al. Thoracoscopic Thymectomy Using a Subxiphoid Approach for Anterior Mediastinal Tumors. *Ann Thorac Cardiovasc Surg* 2018;24:65-72.
- Yano M, Moriyama S, Haneda H, et al. The Subxiphoid Approach Leads to Less Invasive Thoracoscopic Thymectomy Than the Lateral Approach. *World J Surg* 2017;41:763-70.
- Sakamaki Y, Oda T, Kanazawa G, et al. Intermediate-term oncologic outcomes after video-assisted thoracoscopic thymectomy for early-stage thymoma. *J Thorac Cardiovasc Surg* 2014;148:1230-1237.e1.
- Odaka M, Akiba T, Yabe M, et al. Unilateral thoracoscopic subtotal thymectomy for the treatment of stage I and II thymoma. *Eur J Cardiothorac Surg* 2010;37:824-6.
- Agasthian T. Beyond the limits, extreme minimally invasive surgery in invasive thymic tumours. *J Vis Surg* 2017;3:58.
- Yim AP, Kay RL, Ho JK. Video-assisted thoracoscopic thymectomy for myasthenia gravis. *Chest* 1995;108:1440-3.
- Mineo TC, Pompeo E, Lerut TE, et al. Thoracoscopic Thymectomy in Autoimmune Myasthenia: Results of Left-Sided Approach. *Ann Thorac Surg* 2000;69:1537-41.
- Zieliński M, Rybak M, Solarczyk-Bombik K, et al. Subxiphoid uniportal VATS thymectomy. *J Vis Surg* 2017;3:171.

**Cite this article as:** Aramini B, Song N, Banchelli F, Jiang G, Gonzalez-Rivas D, Fan J. Subxiphoid thymectomy with a double sternum retractor: a pilot study. *Gland Surg* 2019;8(6):657-662. doi: 10.21037/gs.2019.11.05