

# Clinical applications of dynamic infrared thermography in plastic surgery: a systematic review

Hannah Eliza John<sup>1</sup>, Vachara Niumsawatt<sup>2</sup>, Warren Matthew Rozen<sup>2,3</sup>, Iain S. Whitaker<sup>1,4</sup>

<sup>1</sup>Department of Plastic and Reconstructive Surgery, Cambridge University Teaching Hospitals, NHS Trust, Cambridge, UK; <sup>2</sup>Department of Surgery, School of Clinical Science at Monash Health, Faculty of Medicine, Monash University, Monash Medical Centre, Clayton 3168, Victoria, Australia; <sup>3</sup>Department of Surgery, School of Medicine and Dentistry, James Cook University Clinical School, Townsville Hospital, Douglas, Townsville, Queensland 4814, Australia; <sup>4</sup>The Welsh Centre for Burns and Plastic Surgery, Swansea University College of Medicine, Wales, UK

*Contributions:* (I) Conception and design: WM Rozen, IS Whitaker; (II) Administrative support: All authors; (III) Provision of study materials or patients: All authors; (IV) Collection and assembly of data: All authors; (V) Data analysis and interpretation: All authors; (VI) Manuscript writing: All authors; (VII) Final approval of manuscript: All authors.

*Correspondence to:* Prof. Warren Matthew Rozen, MBBS, MD, PhD. Department of Plastic and Reconstructive Surgery, Frankston Hospital, Peninsula Health, 2 Hastings Road, Frankston Victoria 3199, Australia. Email: warrenrozen@hotmail.com.

**Background:** Infrared thermography (IRT) has become an increasingly utilized adjunct to more expensive and/or invasive investigations in a range of surgical fields, no more so than in plastic surgery. The combination of functional assessment, flow characteristics and anatomical localization has led to increasing applications of this technology. This article aims to perform a systematic review of the clinical applications of IRT in plastic surgery.

**Methods:** A systematic literature search using the keywords ‘IRT’ and ‘dynamic infrared thermography (DIRT)’ has been accomplished. A total of 147 papers were extracted from various medical databases, of which 34 articles were subjected to a full read by two independent reviewers, to ensure the papers satisfied the inclusion and exclusion criteria. Studies focusing on the use of IRT in breast cancer diagnosis were excluded.

**Results:** A systematic review of 29 publications demonstrated the clinical applications of IRT in plastic surgery today. They include preoperative planning of perforators for free flaps, post operative monitoring of free flaps, use of IRT as an adjunct in burns depth analysis, in assessment of response to treatment in hemangioma and as a diagnostic test for cutaneous melanoma and carpal tunnel syndrome (CTS).

**Conclusions:** Modern infrared imaging technology with improved standardization protocols is now a credible, useful non-invasive tool in clinical practice.

**Keywords:** Infrared thermography (IRT); skin temperature; dynamic infrared thermography (DIRT); location of perforators; burns

Submitted Sep 01, 2015. Accepted for publication Nov 05, 2015.

doi: 10.3978/j.issn.2227-684X.2015.11.07

View this article at: <http://dx.doi.org/10.3978/j.issn.2227-684X.2015.11.07>

## Introduction

Infrared radiation was discovered in 1800, by Sir William Herschel who measured the temperature of each visible light band and noticed that when the thermometer was placed beyond the red band of the visible spectrum, there was a further increase in temperature. Herschel called this

invisible light “infrared” (1). In 1929, Hungarian physicist Kalman Tihanyi invented the first infrared-sensitive camera based on the idea that all objects emit a heat signal in the form of infrared radiation. An infrared thermographic camera can detect this radiation in a similar way to an ordinary camera that can detect visible light (2).

The use of infrared thermography (IRT) in medicine

**Table 1** Oxford Centre For Evidence-Based Medicine, Levels Of Evidence For Diagnostic Or Monitoring Tests [2011]

Level of evidence	Description
Level 1	Systematic review of cross sectional studies with consistently applied reference standard and blinding
Level 2	Individual cross sectional studies with consistently applied reference standard and blinding
Level 3	Non-consecutive studies, or studies without consistently applied reference standards*
Level 4	Case-control studies, or “poor or non-independent reference standard**”
Level 5	Mechanism-based reasoning

Level may be graded down on the basis of study quality, imprecision, indirectness (study PICO does not match questions PICO), because of inconsistency between studies, or because the absolute effect size is very small; level may be graded up if there is a large or very large effect size. \*, a systematic review is generally better than an individual study.

was adopted from the principle that increase in body temperature causes a higher amount of radiation emitted. Hence an increase in vascularity, which is a hallmark of many pathological changes such as inflammation or neoplasms with increased metabolic activity, leads to increase in temperature, which can be detected by an infrared thermographic camera. This can be observed in the form of static single images or noting the thermal recovery process in response to thermal stress; which is called dynamic infrared thermography (DIRT). This term was coined by De Weerd *et al.*, to describe the form of IRT in which a thermal challenge (warm or cold) is applied to an area of interest, and the rate and pattern of temperature changes towards equilibrium is registered with an infrared camera. The analysis of the rate and pattern of rewarming is an indicator of the underlying skin and subcutaneous tissue perfusion (3). This paper aims to conduct a systematic review of the clinical applications of IRT imaging in plastic surgery.

## Methods

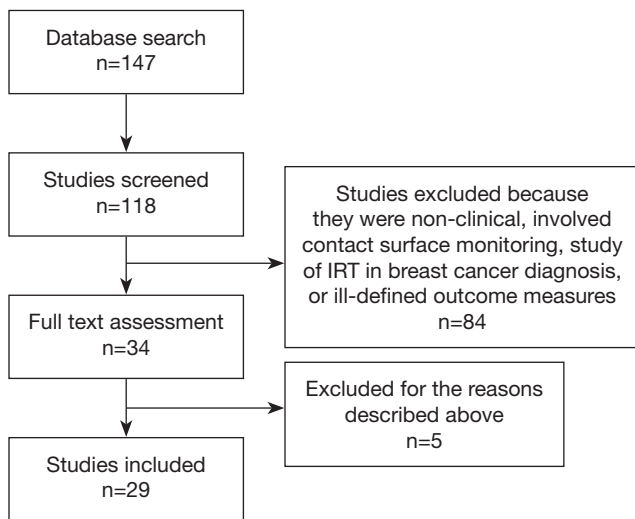
A systematic review of scientific literature was undertaken. All prospective and retrospective studies including case reports, cohort studies, randomized control trials and clinical trials which analyze the applications of dynamic IRT in a medical setting, were included. All clinical and laboratory studies with human participants, cadavers and animals that underwent IRT imaging and computer software analysis were included in the review. Subgroup analyses were performed, with the use of DIRT divided into the following subgroups for analyses: to assess perforators in planning for flap reconstruction and wound closure; to monitor flaps post-operatively; to assess burn wound depth; to diagnose carpal tunnel syndrome (CTS); for other uses in

plastic surgery. Inclusion criteria comprised all studies that use DIRT with the aforementioned endpoints. All animal, human and cadaveric studies that were published in English were included for analysis. Exclusion criteria comprised studies which analyzed temperature changes but did not use the IRT camera and studies analyzing the usefulness of IRT in diagnosing breast cancer.

The search strategy involved searching electronic databases Medline, OVID Old MEDLINE, EMBASE and Cochrane collaboration for all articles on the topic of DIRT published up till June 2012. The bibliographic references of the captured articles were examined in order to search for additional relevant citations. The search strategy was sensitive to texts and abstracts, with the keywords “thermography” and/or “infrared” and/or “DIRT”. Each potential paper was examined by two reviewers for adherence to inclusion/exclusion criteria. There were no conflicts of opinion between the two reviewers. All included studies were separated for a full reading, critical assessment and data extraction. The following data were gathered: general information on each study (author and publication year), type of study, types of participants, study location, subject number, study aim, type of infrared thermographic camera, type of analytical software and result. The data extracted by each publication were then separated according to clinical applications of the DIRT camera, and analyzed. The quality of each paper was assessed based on the Oxford levels of evidence scale as demonstrated in *Table 1* (4).

## Results

Electronic search using the prescribed criteria revealed 147 studies. After reading the titles and abstracts and eliminating duplicates, a total of 34 publications were chosen for a full reading and assessment in relation to



**Figure 1** Literature review, citation attrition flow diagram. IRT, infrared thermography.

inclusion and exclusion criteria (See *Figure 1*). Several studies were subsequently excluded. Bulstrode *et al.*, 2002 assessed the use of surface thermography for post-operative monitoring of free flap reconstruction. This study was excluded as the study utilized surface temperature camera rather than digital infrared thermographic camera in the study (5). Rustemeyer *et al.*, 2007 used an electronic contact thermometer to determine the reference value for surface temperature of the different facial regions. Again this study was excluded due to the use of a surface temperature camera (6). A study by May *et al.*, 1985 was also excluded as they used thermocouple probe monitoring for free tissue transfer, replantation and revascularization procedure rather than digital infrared thermographic (DIRT) camera (7).

### Included studies

After full reading and analysis, a total of 29 publications met the inclusion criteria. The papers were then separate into categories for systemic review according to the application of DIRT.

#### *Use of dynamic infrared thermography (DIRT) in assessing and mapping perforators in pre-operative flap reconstructions*

After literature review, nine publications were analyzed. These included seven prospective studies and two case reports. All these studies use a similar type of digital infrared

thermographic (DIRT) camera and analytical software, as described in *Table 2*. Theuvenet *et al.* used the DIRT camera to evaluate cadavers for the marking of perforators in various areas that could be harvested as free flaps. The skin and subcutis were dissected from the underlying fascia and muscle; and 31 out of 36 perforators that were detected by DIRT, were located. A further 16 living volunteers had their perforators analyzed after cooling, exsanguination and use of tourniquet. After the tourniquet was released, hot spots were detected with DIRT (8). Five publications (Itoh 1995, Salmi 1995, Zetterman 2000, Kalra 2007 and De Weerd 2009) use DIRT camera to detect perforators in abdominal free flaps (9-13). Chijiwa *et al.* used IRT to create a facial map of perforators to enable planning of flaps of the face (14). In all the studies, the subjects' skin was cooled and allowed to rewarm while the thermal images were recorded. Two publications (Salmi 1995 and Kalra 2007) further analyze deep inferior epigastric perforators (DIEP) intra-operatively, both report a decrease in temperature of  $3.4 \pm 1.05$  °C of the whole flap from the reference point ( $P < 0.05$ ) detected by DIRT, after ligation of the pedicles (10,12). De Weerd *et al.* also observed the rate and pattern of rewarming of the hot spots to represent quality of the perforators. A hot spot (reperfusion) that produces a rapid rewarming for a larger area is preferable for flap reconstruction (13). Tenorio *et al.* conducted a trial comparing DIRT with handheld Doppler on 16 patients with surgical dissection confirming the perforator location, as the reference standard. They found that location matched within a distance of 0-15 mm in 67% of patients. They concluded that while Doppler located perforators in the deeper level, where they exited the muscular fascia; thermography detected their location beneath the skin and hence both techniques were complementary. Using a thermographic map obtained by DIRT the Doppler flow examination time could be shortened and the Doppler was useful to recognize arterial versus venous flow (15). These were all well presented photographically (see *Figures 2,3*).

A total of 108 patients were included in the studies. Although many of the studies were self-described as prospective clinical trials, as there were no established reference standards, control groups or randomization in the processes described, or in some cases, the lack of critical appraisal and sensitivity analysis, they were classified as evidence level 3 to 4. The case reports with expert opinions were classified as level 5 evidence. As Salmi *et al.* and Tenorio *et al.*'s studies included the use of a reference standard, in the form of an exploratory cohort study; it was

**Table 2** Use of digital infrared thermography (DIRT) for assessing and mapping perforators in pre-operative flap reconstruction

Author	Journal and year of publication	Participants	Type of DIRT	Software	Oxford level of evidence
Theuvenet	<i>Scandinavian Journal of Plastic and Reconstructive Surgery</i> , 1986	N=4 TFL flap in cadavers; N=16 volunteers	Digital thermograph camera (Philips) with photovoltaic in liquid nitrogen cooled detector	Not mentioned	4
Salmi	<i>Annals of Plastic Surgery</i> , 1995	N=8 TRAM for breast reconstruction	Inframetrics 600	Manual analysis from video recording	2
Itoh	<i>Annals of Plastic Surgery</i> , 1995	N=12 volunteers; N=2 case reports of trauma reconstruction	Fujitsu Infra Eye 180	Manual analysis	4
Zetterman	<i>European Journal of Plastic Surgery</i> , 1999	N=16 women, abdominal perforators	Inframetrics 600	Thermogram 95 software	4
Chijiwa	<i>Annals of Plastic Surgery</i> , 2000	N=12 mapping facial perforators	Fujitsu Infra Eye 1200A; Thermal Vision Laird 3ME	Manual analysis	4
Kalra	<i>Journal of Plastic, Reconstructive and Aesthetic Surgery</i> , 2007	N=2 patients for DIEP free flaps reconstruction	NEC Thermo Tracer TH7102MV	MiKroSpec R/T and MiKroSpec 2.9	5
De Weerd	<i>Annals of Plastic Surgery</i> , 2009	N=23 patients for DIEP free flaps reconstruction	Nikon Laird S270; FLIR ThermoCam S65 HS	PicWin-IRIS; ThermoCam Researcher Pro 2.8 SR-1	3
Tenorio	<i>Annals of Plastic Surgery</i> , 2011	N=16 patients, 10 DIEPs, 6 free fibula flaps	BioScan IR system	DIRI software	2
Whitaker	<i>Journal of Plastic, Reconstructive and Aesthetic Surgery</i> , 2012	N=1 patient for bilateral DIEP	NEC Thermotracer TH 7800	Not mentioned	5

TFL, tensor fascia lata; DIEP, deep inferior epigastric perforators.

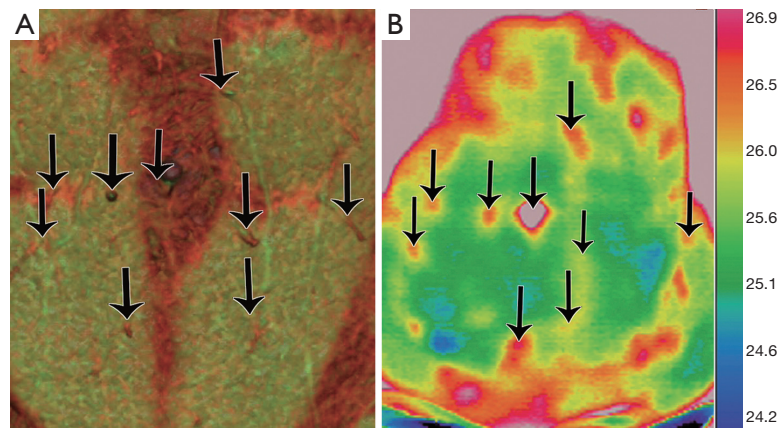
classified as evidence level 2.

### ***Use of dynamic infrared thermography (DIRT) in post-operative monitoring of flap reconstruction***

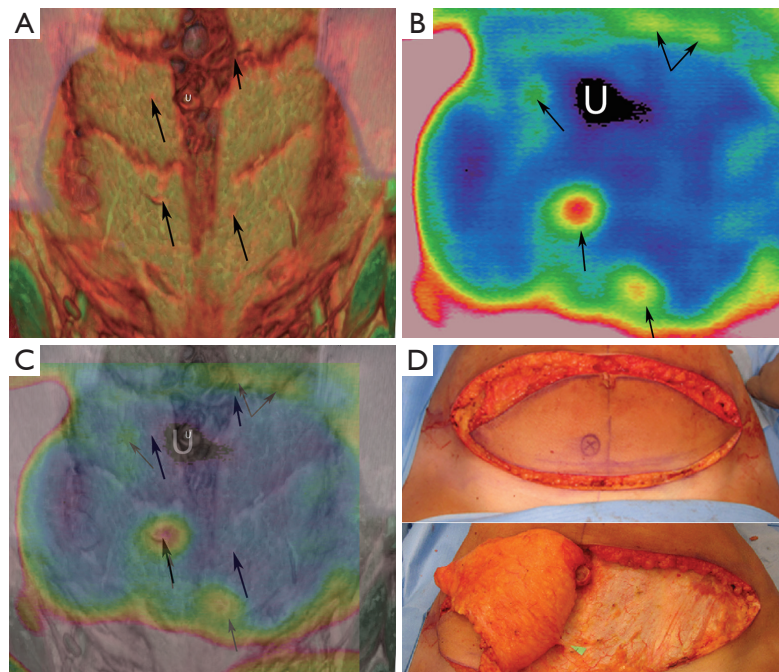
A total of five publications were included in the study. There were three randomized controlled trials and two prospective clinical studies as shown in *Table 3*. All of the randomized controlled trials were conducted using laboratory animal experiments with two publications using DIRT to determine the end point (flap necrosis and reperfusion state) for the given interventions. Tenorio *et al.*, found that after raising a pedicled island flap and ligating the arterial supply, DIRT detected a change in temperature from red to green with the disappearance of the hot spot representing the pedicle within 20 minutes, well before any macroscopic changes

were visible. Whereas, in venous occlusion there was a brief increase followed by a steady decrease of the infrared emission observed. In contrast to the arterial ligation group, macroscopic signs of venous congestion were obvious, at the same time as detectable by DIRT (15). This was a validating cohort study with a clear reference standard and hence was classified as 2 level of evidence.

Two publications (Wolff 1995 and Shejbal 2011) used DIRT to assess the flap survival and perfusion and to compare the use of vasoactive drugs (capsaicin, methyl prednisolone and mitomycin) in improving survival of random pattern skin flaps and different types of venous flaps (16,17). Both studies used DIRT to determine perfusion status with Wolff's study using isotope perfusion as a comparison (18). In view of this comparison study, it has been classified as level 2 evidence. Although Shejbal's study



**Figure 2** Comparison between computed tomography and infrared thermography imaging modalities. (A) Computed tomographic angiogram (CTA) of the abdominal wall vasculature, highlighting the location of deep inferior epigastric artery (DIEA) perforators; (B) digital thermographic photograph of the abdominal wall of the same patient, demonstrating concordance in localizing perforators. The thermographic image has been taken 1 minute after removal of a cold challenge. Arterial perforators have preferentially rewarmed the skin in a pattern that highlights their distribution. The scale on the right demonstrates increasing thermal activity from blue to red. Reproduced with permission from: “Chubb D, Rozen WM, Whitaker IS, Ashton MW. Images in plastic surgery: digital thermographic photography (“thermal imaging”) for preoperative perforator mapping. *Ann Plast Surg* 2011 Apr;66(4):324-5.”

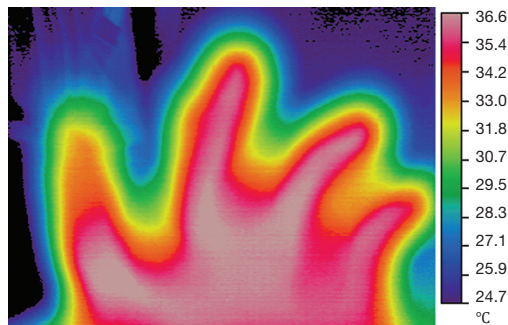


**Figure 3** Comparison between computed tomography, infrared thermography and operative findings. (A) Preoperative computed tomographic angiogram (CTA) showing one suitable single medial row perforator supplying the right hemi-abdomen, with a diameter of 2 mm. The other perforators were felt to be insufficient to supply a flap. This image shows one small perforator to the right of the umbilicus and two small perforators just to the left of the midline; (B) thermal image after 10 minutes of cold challenge using a water pack at 5 °C showing the presence of one ‘hot spot’ confirming the presence of the dominant perforator on the right and the lack of visible hot spots on the left; (C) preoperative thermal image overlying the pre-operative CTA, showing the correlation between the findings of the two modalities (black arrows); (D) intra-operative photographs showing the raised deep inferior epigastric perforators (DIEP) flap, with the marked perforator of choice on the right hemi-abdomen. The left hemiabdomen had no perforators of note. Reproduced with permission from: “Whitaker IS, Lie KH, Rozen WM, et al. Dynamic infrared thermography for the preoperative planning of microsurgical breast reconstruction: a comparison with CTA. *J Plast Reconstr Aesthet Surg*. 2012 Jan;65(1):130-2.”

**Table 3** Use of digital infrared thermography (DIRT) in the postoperative monitoring of flap reconstruction

Author	Journal and year of publication	Participants	Type of DIRT	Software	Oxford level of evidence
Salmi	<i>Annals of Plastic Surgery</i> , 1995	N=8 TRAM for breast reconstruction	Inframetrics 600	Human analysis from video recording	2
Wolff	<i>British Journal of Plastic Surgery</i> , 1995	N=12 rat models	Not stated	Not stated	2
De Weerd	<i>Annals of Plastic Surgery</i> , 2009	N=16 DIEP; N=4 SIEA	Nikon Laird S270 IR	PicWin-IRIS; ThermoCam Researcher Pro 2.8 SR-1	4
Tenorio	<i>Journal of Surgical Research</i> , 2009	N=20 SIEA flaps rat model	BioScan IR System	DIRI	3
Shejbal	<i>Skin Research and Technology</i> , 2011	N=40 rats	ThermoCam SC 2000 (FLIR system)	ThermoCam Research 2002 (FLIR Systems Inc.)	4

TRAM, transverse rectus abdominis myocutaneous; DIEP, deep inferior epigastric perforators; SIEA, superficial inferior epigastric artery.



**Figure 4** Postoperative digital thermograph of a replanted index finger. Thermography was used as an adjunct to postoperative monitoring, and demonstrates the presence of active blood flow, albeit at altered thermographic levels to the rest of the fingers and hand. Reproduced with permission from: Niumsawatt V, Rozen WM, Whitaker IS. Digital Infra-Red Thermographic (DIRT) Photography in Perforator Flap Imaging. In textbook: Saba L, Rozen WM, Alonso-Burgos A, Ribuffo D. Editors. Imaging in Plastic Surgery. CRC Taylor and Francis Press, London UK, 2013.

found that DIRT was accurate in determining flap viability, DIRT was a tool used in the trial and was not the focus of the trial itself and hence, for the purposes of this review, was classified as evidence level 4. An application in digital replantation has also been assessed (unpublished), as shown in *Figure 4*.

#### *Use of dynamic infrared thermography (DIRT) in burns*

In 1974 Hackett demonstrated that diminished blood flow

to deep dermal and full thickness burns can be identified by thermography (19). Several authors have since then, discussed the use of thermography to accurately assess the depth of burns, especially since studies have shown that clinical acumen is only 60–75% accurate, even with experienced burn surgeons (20). In a study of 30 patients with burns, Zhu *et al.* concluded that IRT was an effective method of burn depth measurement as long as the temperature difference was calibrated in relation to a symmetrical normal part of the body. This study was classified as level 4 due to the absence of a good reference standard (21). Renkielska *et al.* used DIRT to analyze burn depth in determining treatment options, operative versus conservative management. They used animal models, assessing 23 wounds of different carefully calculated depths and the tissue was histologically assessed to determine the degree of dermis injury. To improve on the existing studies that used static thermograms, they made it dynamic using a thermal challenge in the form of heating by optical irradiation. The results of DIRT assessment corresponded exactly with the histological evaluation and hence they concluded that DIRT is an effective method of burn wound discrimination and early burn treatment planning (22). A subsequent review done at the John Hopkins Burns Centre in USA in 2006 (Devgan *et al.*) concluded that although there were reports of high accuracy in burn depth assessment with thermography, it was limited by the confounding effects of ambient heat loss and sensitive timing (23). In 2008, Monstrey *et al.* reviewed the various techniques used for burn depth assessment, including IRT and concluded that, laser Doppler imaging was the most accurate in predicting

**Table 4** Use of digital infrared thermography (DIRT) in identifying burn depth

Author	Journal and year	Participants	Type of DIRT	Software	Oxford level of evidence
Hackett	<i>British Journal of Plastic Surgery</i> , 1974	N=109	Not mentioned	Manual	5
Zhu	<i>Annals of the New York Academy of Sciences</i> , 1999	N=30	Thermovision 470 Pro camera	IRwin 2.01	4
Renkielska	<i>Burns</i> , 2006	N=23	AGEMA THV-900	Incorporated	2
Devgan	<i>Journal of Burns and Wounds</i> , 2006	Review	–	–	3
Saxena	<i>European Journal of Paediatrics</i> , 2008	N=30	Talytherm	Incorporated	4
Monstrey	<i>Burns</i> , 2008	Review	–	–	3

**Table 5** Use of digital infrared thermography (DIRT) in carpal tunnel syndrome (CTS)

Author	Journal and year of publication	Participants	Conclusions	Oxford level of evidence
Herrick	<i>American Journal of Hand Surgery</i> , 1987	N=90	Probably useful	4
So	<i>Neurology</i> , 1989	N=20 volunteers; N=37 patients	Not useful	2
Reilly	<i>British Journal of Rheumatology</i> , 1989	N=23	Not useful	2
Tchou	<i>American Journal of Hand Surgery</i> , 1992	N=61 patients; N=40 volunteers	Useful	2
Papez	<i>Journal of International Medical Research</i> , 2009	N=132 volunteers; N=119 patients	Probably useful	2

wound outcome, based on published evidence so far (20). The studies and their findings are summarized in *Table 4*.

#### ***Use of dynamic infrared thermography (DIRT) in carpal tunnel syndrome (CTS)***

In 1987, Herrick's study of 90 patients with inadequately applied reference standards (and hence evidence level 4) proposed that thermography is probably useful in diagnosing CTS (24). This was followed by So *et al.* in 1989 who studied the use of IRT in diagnosing patients with entrapment neuropathies, as part of a level 2 study. They studied 20 healthy volunteers and 37 patients but found the sensitivity of thermography far below that of nerve conduction studies and concluded that thermography was not useful for this purpose (25). These findings were also confirmed by Reilly *et al.* in the same year, in their study with 23 patients (26). However, a randomized controlled trial with blinding, performed by Tchou in 1992, concluded that for diagnosing CTS thermography had a specificity of 98–100% (27). However these results have not been duplicated since then. In 2008, Jesensek Papez *et al.* conducted a study into the use of IRT for diagnosing CTS, with better technology using artificial neural networks. They studied 502 images of hands (from 132 healthy, 119 affected patients) and demonstrated that IRT was

able to correctly classify 72.2% of the hands. They used nerve conduction studies as the reference standard. They concluded that IRT could be useful as a screening method in populations with high ergonomic risk factors for CTS, but was inadequate as a diagnostic tool where severity level is required to determine further management (28). *Table 5* summarizes this review.

#### ***Use of dynamic infrared thermography (DIRT) for hemangiomas***

There is only level five evidence (Saxena *et al.* in 2008), where they used DIRT to document and plan further treatment for 102 children with cutaneous haemangiomas and other vascular malformations after conservative management, cryotherapy and laser therapy (29).

#### ***Use of dynamic infrared thermography (DIRT) in melanoma***

Identifying melanomas is one of the oldest applications of infrared thermal imaging in medicine as studied by Maillard and Hessler in 1969 (30). Recent studies have shown that temperature changes are different in benign and malignant pigmented cutaneous lesions, as discussed by Centigul *et al.*, but these promising results are yet to be confirmed with larger sample groups (31). At present, there is only



**Figure 5** The digital thermographic camera (Thermo Tracer TH 7800, NEC Avio Infrared Technologies, Tokyo). Image retrieved from: <http://www.namicon.com/products.xpg?catid=121&prodid=575> on December 27<sup>th</sup>, 2012.

level five evidence (Santa Cruz *et al.* 2009), suggesting the possibility of the usefulness of DIRT, in melanoma (32).

#### ***Use of dynamic infrared thermography (DIRT) in detecting breast neoplasms***

Over 800 peer-reviewed studies have been published on the use of breast thermography to diagnose breast cancer, and there are over 110 review articles on this topic. Lack of standardization of technique and continual evolution in the technology and equipment used, makes a comprehensive review of the subject extremely difficult, and attempting a systematic review of this topic is beyond the remit of this paper. A recent systematic review by Fitzgerald *et al.* published in March 2012, using QUADAS criteria concluded that, as most of the studies were of average quality, there is insufficient evidence to support thermography or to show that it provides benefit to patients as an adjunctive tool to mammography (33). With the advent of the use of texture features and support vector machine, as suggested by Acharya *et al.* (34) or using three-dimensional close-actual-breast model with a numerical grid

and tetrahedral elements, as suggested by Ng *et al.* (35) the sensitivity and specificity of thermography as a screening tool is likely to increase. DIRT may be a useful adjunct to existing methods of breast cancer diagnosis, but at present still cannot replace mammography or ultrasound.

#### **Discussion**

The objective of this systematic review is to analyze the clinical applications of DIRT in plastic surgery. In planning flap reconstruction, it is crucial to be able to identify a suitable perforator. Currently there is a need for a non-invasive, inexpensive, sensitive, accurate bedside device with minimal or no adverse effect. Doppler ultrasound yields a low sensitivity and is operator dependent for both identifying and interpretation of results. Cutaneous perforators can be mapped by magnetic resonance imaging (MRI), computer tomographic angiography (CTA) and digital subtraction angiography (DSA) but these diagnostic imaging techniques are expensive, are not suitable for intra-operative or post-operative monitoring, and may be associated with high radiation dose, risk of contrast extravasation and nephrotoxicity. The average CTA involves a separate hospital visit with a CT appointment taking up to 30 minutes, requiring the skills of a radiographer, sophisticated expensive equipment and a radiologist to verify the report, whereas infrared thermal photography can be performed by the surgeon, in the preliminary clinic visit, using simpler less expensive equipment and usually takes only 10 minutes to perform (see *Figure 5*) (36).

While the need for such a device is evident, the data does not offer DIRT as a definitive improvement over current techniques in a holistic manner. While its benefits have been demonstrated, at best the data suggests that DIRT is a useful adjunct to current techniques.

DIRT can be used as an alternative or collaborate with other diagnostic interventions to map and characterize perforators in designing cutaneous and musculocutaneous flaps, by the presence of hot spots. It has a similar sensitivity and specificity in detecting cutaneous perforators as CTA and tissue dissection (10,13). However while the CTA provides information on all the perforators in the area, giving a precise location less than 1 mm, vessel calibre and additionally gives the exact course of the vessel helping surgeons choose the perforator that requires the least intramuscular dissection, DIRT can only identify perforators that are more than 1 mm in diameter, with a location precision of less than 1 cm (36). The short course



of the perforator from the source vessel to the skin explains the rapid rewarming of the skin at the hot spot. DIRT provides a qualitative assessment of perforators to the flap which can provide additional information when combined with CTA to choose the best flap for reconstruction.

With the introduction of free style reconstruction flaps comes a need for a safe and reliable method of perforator mapping. Wei *et al.*, described “free style” flaps when a flap is raised after a perforator was identified in an unfamiliar region, flap harvest can still be done, by surgically exploring the region for vessels of suitable size (37). This had led to an increase in the number of flaps available. Based on the evidence published in literature thus far, DIRT may provide an accurate, inexpensive method that is useful in identifying perforators for flap planning.

Flap and re-implantation monitoring, as well as assessing ischaemic limbs is still heavily reliant on clinical evaluation, which in itself, is dependent on the experience and knowledge of the medical staff, in recognizing tissue that is vascularly compromised. Early and accurate recognition of perfusion failure is critical. If surgical revision is performed within the first hour after detection of venous or arterial occlusion, the salvage can reach 68–70% and the salvage rates decrease thereafter (38). Ideally, the monitoring system needs to be non-invasive, free of side-effects, reliable, rapid, repeatable, accurate, painless and easy to operate. With the developments in computer analytical software and technology, DIRT equipment has become smaller and can accurately analyze, with finer detail. This has allowed DIRT to be used intra-operatively and on the ward as a post-operative monitoring device. The studies that used DIRT to monitor flaps showed that the flap temperature increased by  $1.4 \pm 0.18$  °C, following completion of anastomosis. They also noted the temperature in the free flap was generally higher than the tissue in its original position, which may indicate decrease in vascular resistance due to it being a non-innervated flap (10,18). De Weerd *et al.*, found that DIRT had a higher sensitivity in detecting early vascular flow in flap reconstruction than arterial Doppler ultrasound. Thus, DIRT joins the plethora of methods currently in use to monitor flap perfusion, which include near-infrared spectroscopy, implantable Doppler probes, colour Duplex sonography, laser Doppler flowmetry and microdialysis. Although a validating cohort study with absolute reference standards or a comparison study with current flap monitoring techniques, is pending, it is safe to say that literature points to the usefulness of DIRT for postoperative flap monitoring.

In burns, differentiating between superficial dermal and deep dermal burns is difficult even for experienced practitioners. But this differentiation is significant in the option of treatment prescribed, as superficial dermal wounds can be treated conservatively and will heal within 3 weeks, whereas deep dermal burns should ideally be excised and grafted. Various techniques have been used to accurately identify the depth of a burn wound, with the reference standard being the histological diagnosis or the clinical appearance of the wound on follow-up. Although thermography benefits from relative technical ease and validity, it is limited by the confounding effects of ambient heat loss and sensitive timing. Evaporative loss of heat to the environment causes wounds to be interpreted as falsely deep, introducing systematic error to this technique. In addition, accuracy is compromised if wounds begin to granulate, so optimal results occur when thermography is done within 3 days of sustaining the burn injury (39,40). Existing literature at present, points to laser Doppler flowmetry as the ideal method for burn depth assessment, with higher accuracy and specificity.

Clinical signs and symptoms alone are not often enough to diagnose CTS. There is a large amount of evidence to support the use of nerve conduction studies as the gold standard for the diagnosis of CTS. Despite Tchou's remarkable results in their randomized controlled trial in 1992, the most recent large review, conducted in 2008 by Jesensek Papez *et al.*, confirmed that although IRT was useful in identifying severe cases of CTS, nerve conduction studies were still the only reliable gold standard (28). Despite improvement in technology and research, IRT is still considered fairly unreliable and hence should not be used as a diagnostic test for CTS.

Over the last 20 years, there have been calls for increased standardization of procedures associated with IRT from patient preparation and body positioning for image recording, to evaluation of thermal imaging. A total of 24 body positions and 90 regions of interest have been defined to construct a clinical database of reference thermograms. This has shown to have a significant influence on the accuracy of measurements obtained from thermal images (41). Currently, there is no system or a consistent value which can be used to standardize a thermal profile (‘thermoprofile’) of the human body.

## Conclusions

DIRT gives indirect information on tissue perfusion.

From attention deficit hyperactivity disorder (42) to complex regional pain syndrome, the use of IRT as a diagnostic tool continues to expand. With the advantages of improved technology in the form of smaller, portable cameras with quick set up and simple data capture, along with standardization protocols set in place for uniformity and repeatability of data capture, the use of a non-invasive tool to diagnose as well as assess response to treatment for various clinical conditions, is extremely appealing. In plastic surgery, DIRT can be used to identify perforators in planning flap reconstruction, intraoperatively to assess perfusion and post operatively for flap monitoring. Ambient heat loss and the time sensitivity of wound assessment preclude the use of DIRT for burn depth analysis. So also, there is not enough evidence to support the use of DIRT for the diagnosis of CTS. It is clear from all the studies to date that current DIRT technology does not give the best sensitivity or specificity. Rather, it provides additional information which should be used in conjunction with existing diagnostic modalities and clinical assessment.

### Acknowledgements

None.

### Footnote

*Conflicts of Interest:* The authors have no conflicts of interest to declare.

### References

1. Ring EF. The discovery of infrared radiation in 1800. *Imaging Sci J* 2000; 48:1-8.
2. Ring EF. The historical development of thermal imaging in medicine. *Rheumatology (Oxford)* 2004;43:800-2.
3. de Weerd L, Mercer JB, Weum S. Dynamic infrared thermography. *Clin Plast Surg* 2011;38:277-92.
4. Patsopoulos NA, Analatos AA, Ioannidis JP. Relative citation impact of various study designs in the health sciences. *JAMA* 2005;293:2362-6.
5. Bulstrode NW, Wilson GR, Inglis MS. No-touch free-flap temperature monitoring. *Br J Plast Surg* 2002;55:174.
6. Rustemeyer J, Radtke J, Bremerich A. Thermography and thermoregulation of the face. *Head Face Med* 2007;3:17.
7. May JW Jr, Halls MJ. Thermocouple probe monitoring for free tissue transfer, replantation, and revascularization procedures. *Clin Plast Surg* 1985;12:197-207.
8. Theuvenet WJ, Koeyers GF, Borghouts MH. Thermographic assessment of perforating arteries. A preoperative screening method for fasciocutaneous and musculocutaneous flaps. *Scand J Plast Reconstr Surg* 1986;20:25-9.
9. Itoh Y, Arai K. Use of recovery-enhanced thermography to localize cutaneous perforators. *Ann Plast Surg* 1995;34:507-11.
10. Salmi AM, Tukiainen E, Asko-Seljavaara S. Thermographic mapping of perforators and skin blood flow in the free transverse rectus abdominis musculocutaneous flap. *Ann Plast Surg* 1995;35:159-64.
11. Zetterman E, Salmi AM, Suominen S, et al. Effect of cooling and warming on thermographic imaging of the perforating vessels of the abdomen. *Eur J Plast Surg* 1999; 22:58-61.
12. Kalra S, Dancey A, Waters R. Intraoperative selection of dominant perforator vessel in DIEP free flaps based on perfusion strength using digital infrared thermography - a pilot study. *J Plast Reconstr Aesthet Surg* 2007;60:1365-8.
13. de Weerd L, Weum S, Mercer JB. The value of dynamic infrared thermography (DIRT) in perforatorselection and planning of free DIEP flaps. *Ann Plast Surg* 2009;63:274-9.
14. Chijiwa T, Arai K, Miyazaki N, et al. Making of a facial perforator map by thermography. *Ann Plast Surg* 2000;44:596-600.
15. Tenorio X, Mahajan AL, Wettstein R, et al. Early detection of flap failure using a new thermographic device. *J Surg Res* 2009;151:15-21.
16. Wolff KD, Telzrow T, Rudolph KH, et al. Isotope perfusion and infrared thermography of arterialised, venous flow-through and pedicled venous flaps. *Br J Plast Surg* 1995;48:61-70.
17. Shejbal D, Drvis P, Bedekovic V. Thermography-measured effect of capsaicin, methylprednisolone and mitomycin on the survival of random skin flaps in rats. *Skin Res Technol* 2012;18:157-61.
18. de Weerd L, Miland AO, Mercer JB. Perfusion dynamics of free DIEP and SIEA flaps during the first postoperative week monitored with dynamic infrared thermography. *Ann Plast Surg* 2009;62:42-7.
19. Hackett ME. The use of thermography in the assessment of depth of burn and blood supply of flaps, with preliminary reports on its use in Dupuytren's contracture and treatment of varicose ulcers. *Br J Plast Surg* 1974;27:311-7.
20. Monstrey S, Hoeksema H, Verbelen J, et al. Assessment

- of burn depth and burn wound healing potential. *Burns* 2008;34:761-9.
21. Zhu WP, Xin XR. Study on the distribution pattern of skin temperature in normal Chinese and detection of the depth of early burn wound by infrared thermography. *Ann N Y Acad Sci* 1999;888:300-13.
  22. Renkielska A, Nowakowski A, Kaczmarek M, et al. Burn depths evaluation based on active dynamic IR thermal imaging--a preliminary study. *Burns* 2006;32:867-75.
  23. Devgan L, Bhat S, Aylward S, et al. Modalities for the assessment of burn wound depth. *J Burns Wounds* 2006;5:e2.
  24. Herrick RT, Herrick SK. Thermography in the detection of carpal tunnel syndrome and other compressive neuropathies. *J Hand Surg Am* 1987;12:943-9.
  25. So YT, Olney RK, Aminoff MJ. Evaluation of thermography in the diagnosis of selected entrapment neuropathies. *Neurology* 1989;39:1-5.
  26. Reilly PA, Clarke AK, Ring EF. Thermography in carpal tunnel syndrome (CTS). *Br J Rheumatol* 1989;28:553-4.
  27. Tchou S, Costich JF, Burgess RC, et al. Thermographic observations in unilateral carpal tunnel syndrome: report of 61 cases. *J Hand Surg Am* 1992;17:631-7.
  28. Jesensek Papez B, Palfy M, Mertik M, et al. Infrared thermography based on artificial intelligence as a screening method for carpal tunnel syndrome diagnosis. *J Int Med Res* 2009;37:779-90.
  29. Saxena AK, Willital GH. Infrared thermography: experience from a decade of pediatric imaging. *Eur J Pediatr* 2008;167:757-64.
  30. Maillard GF, Hessler C. Thermography of malignant melanoma. Preliminary report. *Dermatologica* 1969;139:353-8.
  31. Centigul MP, Herman C. Quantification of the thermal signature of a melanoma lesion. *Int J Therm Sci* 2011; 50:421-31.
  32. Santa Cruz GA, González SJ, Bertotti J, et al. First application of dynamic infrared imaging in boron neutron capture therapy for cutaneous malignant melanoma. *Med Phys* 2009;36:4519-29.
  33. Fitzgerald A, Berentson-Shaw J. Thermography as a screening and diagnostic tool: a systematic review. *N Z Med J* 2012;125:80-91.
  34. Acharya UR, Ng EY, Tan JH, et al. Thermography based breast cancer detection using texture features and Support Vector Machine. *J Med Syst* 2012;36:1503-10.
  35. Ng EY, Sudharsan NM. Computer simulation in conjunction with medical thermography as an adjunct tool for early detection of breast cancer. *BMC Cancer* 2004;4:17.
  36. Whitaker IS, Lie KH, Rozen WM, et al. Dynamic infrared thermography for the preoperative planning of microsurgical breast reconstruction: a comparison with CTA. *J Plast Reconstr Aesthet Surg* 2012;65:130-2.
  37. Wei FC, Mardini S. Flaps and reconstructive surgery. Elsevier Health Sciences, 2009.
  38. Brown JS, Devine JC, Magennis P, et al. Factors that influence the outcome of salvage in free tissue transfer. *Br J Oral Maxillofac Surg* 2003;41:16-20.
  39. Anselmo V, Zawacki B. Infrared photography as a diagnostic tool for the burn ward. *Proc Soc Photo-Optical Instr Eng* 1973; 8:181.
  40. Liddington MI, Shakespeare PG. Timing of the thermographic assessment of burns. *Burns* 1996;22:26-8.
  41. Ammer K. The Glamorgan protocol for recording and evaluation of thermal images of the human body. *Thermol Int* 2008;18:125-44.
  42. Coben R, Myers TE. Sensitivity and specificity of long wave infrared imaging for attention-deficit/hyperactivity disorder. *J Atten Disord* 2009;13:56-65.

**Cite this article as:** John HE, Niumsawatt V, Rozen WM, Whitaker IS. Clinical applications of dynamic infrared thermography in plastic surgery: a systematic review. *Gland Surg* 2016;5(2):122-132. doi: 10.3978/j.issn.2227-684X.2015.11.07