

The laparoscopic liver resections – an initial experience and the literature review

Mislav Rakić, Leonardo Patrlj, Robert Kliček, Mario Kopljar, Antonija Đuzel, Kristijan Čupurdija, Željko Bušić

Department of Abdominal Surgery, Surgical Clinic, Clinical Hospital Dubrava, Zagreb, Avenija Gojka Šuška 6, 10000 Zagreb, Croatia

Correspondence to: Mislav Rakić, MD. Department of Abdominal Surgery, Surgical Clinic, Clinical Hospital Dubrava, Zagreb, Avenija Gojka Šuška 6, 10000 Zagreb, Croatia. Email: mrakic@kbd.hr.

Abstract: The laparoscopic liver resection (LLR) represents a new pathway in hepatic surgery. Several studies have reported its application in both malignant and benign liver diseases. The most common liver resections performed laparoscopically are wedge, segmental resections and metastasectomy; although in large centers the laparoscopic right and left hepatectomies have begun to perform more frequently. We report the initial experience in LLRs at our department including a case of the first laparoscopic left lateral liver bisegmentectomy performed in patient with follicular nodular hyperplasia and the 15 cases of wedge laparoscopic resections of echinococcal liver cysts. According to literature the mortality rate in LLRs is up to 0.3% and morbidity rate up to 10.5%. The most common cause of the death is liver failure, while the most frequent complication is the bile leakage. Advantages for patients include smaller incisions, less blood loss, and shorter lengths of hospital stay. The LLRs in experienced hands were shown to be safe with acceptable morbidity and mortality for both minor and major hepatic resections in benign and malignant diseases.

Keywords: Laparoscopic liver resection (LLR); segmental resections; left lateral bisegmentectomy; liver echinococcal cyst laparoscopic treatment

Submitted Aug 06, 2014. Accepted for publication Sep 16, 2014.

doi: 10.3978/j.issn.2304-3881.2014.09.10

View this article at: <http://dx.doi.org/10.3978/j.issn.2304-3881.2014.09.10>

In general, liver surgery has seen significant advances in the last decades, particularly associated with improvements in anesthesia and critical care as well as surgical techniques. The improved understanding of the vascular anatomy of the liver based on Couinaud segments, has also led to a great reduction in morbidity and mortality associated with liver resection (1).

Clearly challenging, the laparoscopic liver resections (LLRs) were not accepted until recently due to the several reasons: the problem of intraoperative bleeding control, the technical difficulties, the learning curve and the fear of gas embolism (2). Since the first reported cases of liver resection in 1991 and 1992 (3,4), more than 3,000 cases have been reported in literature worldwide.

In general, LLR is associated with significant advantages: faster recovery, less post-operative pain, less morbidity, easier subsequent surgery and better cosmetic results (5).

At first the indications limited to easily accessible tumors mostly placed at the peripheral portion of liver, the anterolateral segments (II, III, V, VI and the inferior part of IV liver segment) (6,7). The majority of initial reports suggested that LLR is poorly indicated when the lesion is located in the posterior or superior part of the liver (segments I, VII and VIII, the same as the superior part of segment IV) (8,9).

The indications for LLRs widened from solitary, small, easily approachable lesions, to more demanding procedures including the major liver resections such as left and right hepatectomies (10-14). The disease-related indications for LLRs included various conditions of benign, but also the malignant diseases especially the hepatocellular carcinoma and colorectal liver metastases (15-21).

In our department the laparoscopic surgical procedures are widespread. The laparoscopic cholecystectomies

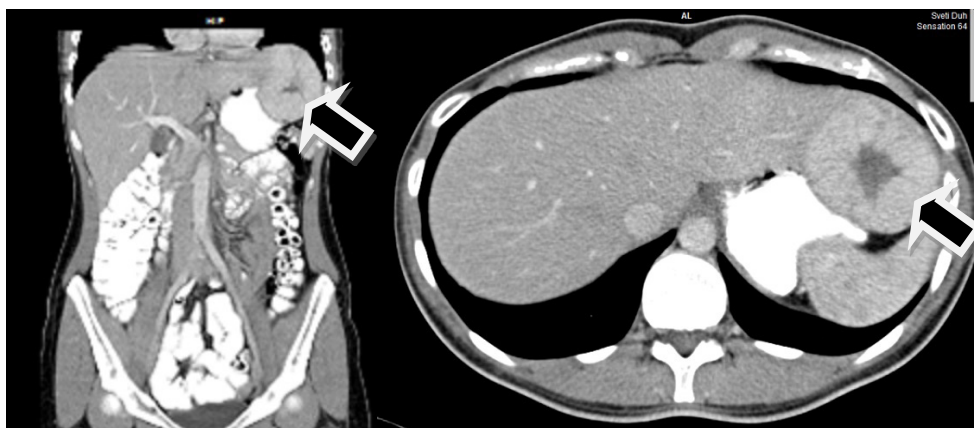

Figure 1 Magnetic resonance imaging (MRI) record of the operated patient with focal nodular hyperplasia (FNH). The tumor located in segments II and III of the liver, shown with black arrows.

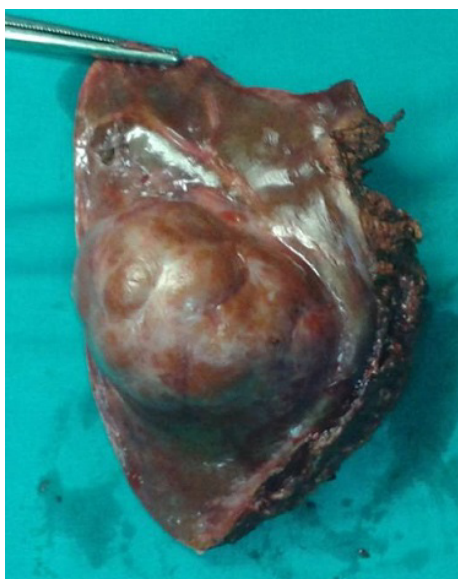

Figure 2 Resected tumor along with the segment II and III of liver.

and appendectomies are performed routinely and have outnumbered the open cholecystectomies and appendectomies that are done only in a narrow spectrum of indications. Apart from that the explorations, the ulcer perforation and hernia repair are performed laparoscopically, as well. During last 10 years the elective splenectomies and colon resections are performed laparoscopically in the high number of cases.

On the other hand, more than 100 open liver resections are performed per year. The experience in laparoscopic surgery and open liver surgery encouraged our surgeons to start performing LLRs. There have already been some

reports of laparoscopic operations of the echinococcal cysts performed in our institution (1,10,11).

Through this paper we aim to report our initial experience in laparoscopic liver surgery with the emphasis on the first left lateral bisegmentectomy and to show a brief literature review onto the main problems and concerns concerning the LLRs.

Report of a case

A 29 years old female patient was admitted to hospital for operative therapy of a liver tumor found on a magnetic resonance imaging (MRI) scan performed as gastroenterological workup for symptoms related to chronic gastritis (*Figure 1*). There were no co-morbidities other than mild ankylosing spondylitis and the general clinical state was proper to the age of the patient. According to MRI record the tumor was situated at the left hepatic lobe and its diameters were 62×57 mm. There were no other tumors found inside of the abdominal and thoracic cavity. The patient underwent the laparoscopic left lateral bisegmentectomy of the 2nd and 3rd liver segments (*Figure 2*). The resection was performed through three skin incisions (*Figure 3*), using the harmonic scalpel and the vascular structures were ligated by the endoscopic vascular staplers (35 and 45 mm). The operation lasted for an hour. The patient spent a day in intensive care unit (ICU). There were no any early complication found and the patient was released home on the third postoperative day. The pathology of the resected tumor had shown the follicular nodular hyperplasia. The consequent perioperative period passed without complications.

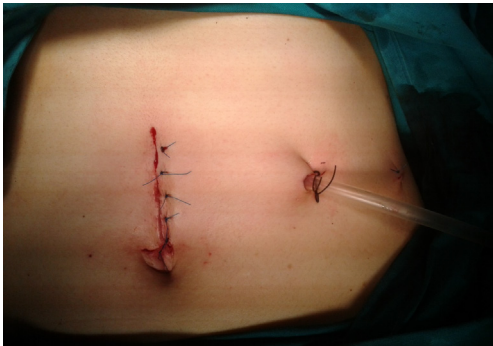


Figure 3 Postoperative skin incisions.

Report of laparoscopically treated patients with echinococcal liver disease

In our institution 15 laparoscopic pericystectomies were performed to date. All patients were pre-operatively treated with albendazole. Total pericystectomy without opening the cyst cavity was performed laparoscopically in seven patients, while the partials pericystectomy was done laparoscopically five patients. In another three patients the procedure started laparoscopically but were converted and completed as an open procedure. The median operative time was 67.5 minutes (range, 60.0-120.0 minutes) and the median hospital stay 5.0 days (range, 4.0-7.0 days). In one patient the echinococcal cyst was situated in 7th liver segment and another three cysts were found intraabdominally. All of them were removed laparoscopically. There were no complication nor recurrences reported until now in laparoscopically operated patients. During the same period of time 32 patients underwent the open operation of the echinococcal liver cysts. In those patients the operation lasted longer [mean operative time 100.0 minutes (range, 60.0-210.0 minutes)]. On the other hand, the hospital stay was longer in patient that underwent the open surgical procedure [median hospital stay 8.0 days (range, 7.0-14.0 days)]. Also there was one case of recurrence in patient treated with the open procedure 3 years following the operation. There was no mortality reported until now in both groups of patients.

Discussion

As the experience and technical improvement grow the spectrum of indications expands. According to recently published study the LLR can be performed safely in selected patients with both benign and malignant liver tumors regardless to the dimensions, location or previous operating

history with comparable morbidity and mortality to those in open surgical procedures (12). LLRs were concluded to be comparable or even better than open liver resection in the context of intraoperative blood loss and the length of hospital stay (13). A similar or lower mortality (0.3%) and morbidity (10.5%) were reported at LLR in comparison to open operative technique of the liver resection (14). There was no significant difference in overall and disease-free 5-year survival rate for hepatocellular carcinoma between open and laparoscopic hepatectomies (15). The conversion rates vary from 8.1% to 17.6% and the reported rate of complications was 3.6% with the postoperative bile leakage rate of 1.1% in 27 analyzed studies that included 619 patients (16).

Conclusions

In our initial experience of operated patients the performed laparoscopic surgical procedures were found safe and efficient with the acceptable operative time and hospital stay. The data found in literature are encouraging, however the proper surgical training and experience the same as well technically equipped centers are essential for performing LLRs.

Acknowledgements

Disclosure: The authors declare no conflict of interest.

References

1. Busić Z, Lemac D, Stipančić I, et al. Surgical treatment of liver echinococcosis--the role of laparoscopy. *Acta Chir Belg* 2006;106:688-91.
2. Cai X, Li Z, Zhang Y, et al. Laparoscopic liver resection and the learning curve: a 14-year, single-center experience. *Surg Endosc* 2014;28:1334-41.
3. Reich H, McGlynn F, DeCaprio J, et al. Laparoscopic excision of benign liver lesions. *Obstet Gynecol* 1991;78:956-8.
4. Gagner M, Rheault M, Dubuc J. Laparoscopic partial hepatectomy for liver tumor [abstract]. *Surg Endosc* 1992;6:99.
5. Tranchart H, Dagher I. Laparoscopic liver resection: a review. *J Visc Surg* 2014;151:107-15.
6. Gigot JF, Glineur D, Santiago Azagra J, et al. Laparoscopic liver resection for malignant liver tumors: preliminary results of a multicenter European study. *Ann Surg* 2002;236:90-7.

7. Kaneko H, Takagi S, Shiba T. Laparoscopic partial hepatectomy and left lateral segmentectomy: technique and results of a clinical series. *Surgery* 1996;120:468-75.
8. Laurent A, Cherqui D, Lesurtel M, et al. Laparoscopic liver resection for subcapsular hepatocellular carcinoma complicating chronic liver disease. *Arch Surg* 2003;138:763-9; discussion 769.
9. Dulucq JL, Wintringer P, Stabilini C, et al. Laparoscopic liver resections: a single center experience. *Surg Endosc* 2005;19:886-91.
10. Busić Z, Cupurdija K, Servis D, et al. Surgical treatment of liver echinococcosis--open or laparoscopic surgery? *Coll Antropol* 2012;36:1363-6.
11. Busić Z, Lovrić Z, Kolovrat M, et al. Laparoscopic operation of hepatic hydatid cyst with intraabdominal dissemination--a case report and literature review. *Coll Antropol* 2009;33 Suppl 2:181-3.
12. Han HS, Yoon YS, Cho JY, et al. Laparoscopic liver resection for hepatocellular carcinoma: korean experiences. *Liver Cancer* 2013;2:25-30.
13. Simillis C, Constantinides VA, Tekkis PP, et al. Laparoscopic versus open hepatic resections for benign and malignant neoplasms--a meta-analysis. *Surgery* 2007;141:203-11.
14. Nguyen KT, Gamblin TC, Geller DA. World review of laparoscopic liver resection--2,804 patients. *Ann Surg* 2009;250:831-41.
15. Kaneko H, Takagi S, Otsuka Y, et al. Laparoscopic liver resection of hepatocellular carcinoma. *Am J Surg* 2005;189:190-4.
16. Laurence JM, Lam VW, Langcake ME, et al. Laparoscopic hepatectomy, a systematic review. *ANZ J Surg* 2007;77:948-53.
17. Jurisić I, Paradzik MT, Jurić D, et al. National program of colorectal carcinoma early detection in Brod-Posavina County (east Croatia). *Coll Antropol* 2013;37:1223-7.
18. Milas J, Samardžić S, Miskulin M. Neoplasms (C00-D48) in Osijek-Baranja County from 2001 to 2006, Croatia. *Coll Antropol* 2013;37:1209-22.
19. Samardžić S, Mihaljević S, Dmitrović B, et al. First six years of implementing colorectal cancer screening in the Osijek-Baranja County, Croatia--can we do better? *Coll Antropol* 2013;37:913-8.
20. Boras Z, Kondza G, Sisljagić V, et al. Prognostic factors of local recurrence and survival after curative rectal cancer surgery: a single institution experience. *Coll Antropol* 2012;36:1355-61.
21. Krebs B, Kozelj M, Potrc S. Rectal cancer treatment and survival--comparison of two 5-year time intervals. *Coll Antropol* 2012;36:419-23.

Cite this article as: Rakić M, Patrlj L, Kliček R, Kopljar M, Đuzel A, Čupurdija K, Bušić Ž. The laparoscopic liver resections—an initial experience and the literature review. *Hepatobiliary Surg Nutr* 2014;3(5):313-316. doi: 10.3978/j.issn.2304-3881.2014.09.10