

Case Report

CPT-11 Chemotherapy Rescued A Patient with Atypical Sclerosing Epithelioid Fibrosarcoma from Emergent Condition

Chun-hua Pan^{1#*}, Xi-qun Han^{2#}, Jian-sheng Li³

¹Department of Medical Oncology, Affiliated Tumor Hospital of Guangzhou Medical College, Guangzhou 510095, China

²Department of Pathology, School of Basic Medical Sciences, Southern Medical University, Guangzhou 510515, China

³Department of Image, Affiliated Tumor Hospital of Guangzhou Medical College, Guangzhou 510095, China

10.1007/s11670-012-0253-1

©Chinese Anti-Cancer Association and Springer-Verlag Berlin Heidelberg 2012

ABSTRACT

Sclerosing epithelioid fibrosarcoma (SEF) is a rare and poorly defined variant of fibrosarcoma, but generally insensitive to chemotherapy and progresses with poor prognosis. We report the marvelous effect of irinotecan hydrochloride (CPT-11) chemotherapy in rescuing a patient with atypical SEF from emergent condition, who underwent recurrences after several treatment methods. Small dose of CPT-11 was administered to the patient, with which, the size of superficial mass (cervical lymph node) gradually decreased observed by the naked eyes in 5 days. X-ray and CT image proved a marked reduction in the size of the tumor. CPT-11 is valuable for the treatment of this aggressive sarcoma. In condition of emergency caused by sarcoma oppression, administering a tolerable small dose of topoisomerase I-inhibiting drug could be a beneficial choice.

Key words: Sclerosing epithelioid fibrosarcoma; CPT-11; Chemotherapy

INTRODUCTION

Sclerosing epithelioid fibrosarcoma (SEF) is a rare and poorly defined variant of fibrosarcoma^[1]. Approximately 50% of patients with the tumor develop local recurrence and/or metastases in one year and about half died of disease in 16–86 months after diagnosis^[2]. For the general sarcomas, the median overall survival (OS) from commencing first- and second-line palliative chemotherapy is reported as 12 months^[3] and 8 months^[4], respectively. Establishing the effective regimen for patients with relapse or refractory sarcomas is an urgent problem to be solved. Here, we report a more severe and aggressive SEF. Immunohistochemistry supported the diagnosis of SEF. In clinic, the tumor showed rapid progress with aggressive recurrence and diffuse metastasis until to the emergent condition, but a small dose of irinotecan hydrochloride (CPT-11) marvelously decreased the size

of the tumor and significantly improved the condition of the patient.

CASE REPORT

A 28-year-old Chinese male patient presented with the chief complaint of right waist pain and abdominal uncomfotableness in July, 2007. Computed tomography (CT) demonstrated a retroperitoneal mass. Operational excision was performed on December 12, 2007 and a pathologic diagnosis of “malignant mesenchymal tumor, a possible sclerosing epithelioid fibrosarcoma (SEF)” was titled, followed by 6 cycles of chemotherapy of mesna, adriamycin, ifosfamide and dacarbazine (MAID) regimen, and partial response (PR) was achieved for 5 months. Then, the patient was introduced to variable treatments, including Chinese medical herbs, thermotherapy, I¹²⁵ ion therapy, Gleevec, gemcitabine, docetaxel, et al. in the following 20 months. The condition of the patient was unstable with deteriorated trend on the whole. On December 5, 2010, the patient was admitted to our hospital in emergent condition and Karnofsky performance score (KPS) was 30, accompanied with fatigue, uroschisis, dyspnoea and asthenia of both lower extremities, and was bedridden. A hard and immoveable enlarged cervical

Received 2012-02-13; Accepted 2012-07-13

This work was supported by a grant from Science and Technology Committee of Guangdong (No.2010B060900093) and a grant from Educational Commission of Guangzhou (No.10A196).

[#]Contributed equally to this study.

*Corresponding author.

E-mail: chhpan8@gmail.com; chhpan@yahoo.cn

lymph node (6 cm × 6 cm) on the right side could be touched and seen. X-ray image and CT demonstrated tumor metastasis to the clavicle lymph nodes in double sides of the neck, pleural, peritoneum, and the oppression of the tumor to the liver, mediastinum, and the lateral of spine. Infection in the lung of double sides and the pressure-induced skin ulceration in buttocks were prominent. Hematoxylin-eosin (HE) slides were reviewed. Microscopically, the tumor was distinctly demarcated in some areas with a fibrotic capsula, while some areas showed infiltrating into the wall of the capsula and adjacent fat and muscular tissues. The tumor cells were arranged in strands, acini, or sheets and embedded into a delicate lace-like collagenous eosinophilic matrix and some densely fibrous bands stranded the cells into nests or cords. Some areas were hypocellular with myxoid matrix and necrotic foci could be encountered. The tumor composed a polymorphism of atypical large and bland spindle-shaped cells, with prominent nuclei and indistinct nucleoli, or epithelioid cells with round, oval even bizarre nuclei. The nuclei were greatly hyperchromatic with moderate mitotic figures. Cytoplasm of the majority cells was scant and clear, some formed halo around the nuclei, while some showed abundant eosinophilic cytoplasm. Immunohistochemistry revealed the tumor cells were diffusely positive for vimentin and negative for anti-clusters of differentiation 34 (CD34), S-100, desmin, myoglobin (Myo), anti-clusters of differentiation 117 (CD117), smooth muscle actin (SMA), epithelial membrane antigen (EMA), pan-cytokeratin (pan-CK), muscle actin

(HHF-35), anti-clusters of differentiation 68 (CD68), monoclonal antibody against human melanoma black (HMB-45) and leukocyte common antigen (LCA) staining. Proliferation marker Ki-67 was quite low (5%) (Figure 1). Therefore, the exclusive diagnosis of “fibrosis of epithelioid sarcoma” was concluded.

The anti-infective, symptomatic and supporting treatments were applied immediately to the patient after the hospitalization. Since the major problem was critical to reduce the size of the tumor and relieve the oppression, but the standard chemotherapy couldn't be tolerated. A single and small dose of CPT-11 was prescribed with 200 mg/d (the patient was 170 cm in height 55 kg in weight, and 1.64 m² in body surface), once a day (only for 1 d). The condition of the patient was greatly improved within 3 d after the chemotherapy, especially, dyspnoea alleviated, the size of cervical lymph node decreased gradually and the mass disappeared macroscopically on the 5th day observed by the naked eyes. The bedside X-ray was performed on the 5th day before treatment [d (-5)], the 1st day before treatment [d (-1)], and the 5th day after treatment [d (+5)] of CPT-11 respectively for couldn't be out of bed. The images showed that the infection of the lungs alleviated on d (-1) but tumor masses were prominent, and the size of the tumor in cervical lymph nodes and pleura decreased significantly on d (+5) compared to d (-1) (Figure 2). CT [d (+21)] showed that the mass decreased in size, and the oppression of the tumor to the abdominal organs and mediastinum was alleviated compared with the CT images of d (-3) (Figure 3).

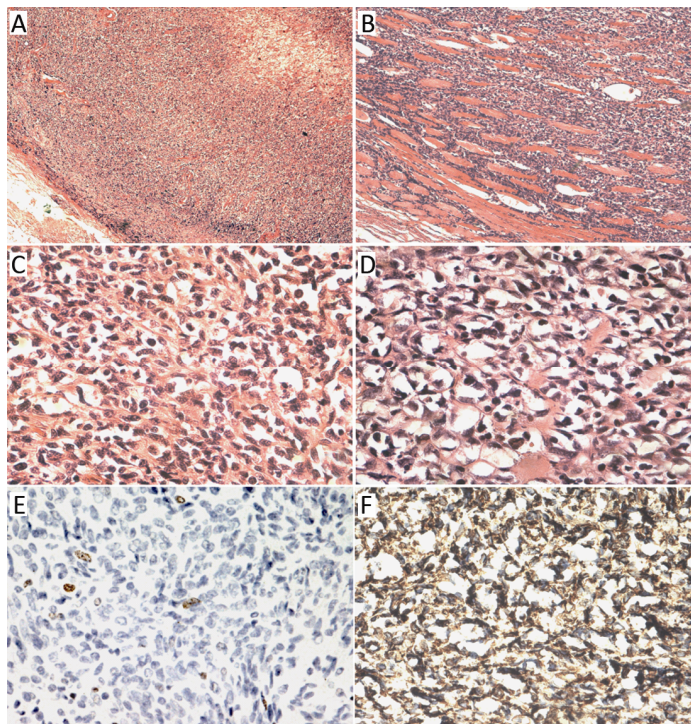


Figure 1. Pathology of the case. **A** and **B** (HE, ×4) show the distinct capsula of the tumor while in some areas, tumor cell infiltrated into the adjacent muscular tissue. **C** and **D** (HE, ×40) show the basic structure of the tumor, with relatively pleomorphic cells and hyperchromatic nuclei. **E** (immunohistochemical staining of Ki-67, ×40) shows the low proliferative index. **F** (immunohistochemistry, ×40) shows the strongly positive staining of vimentin.

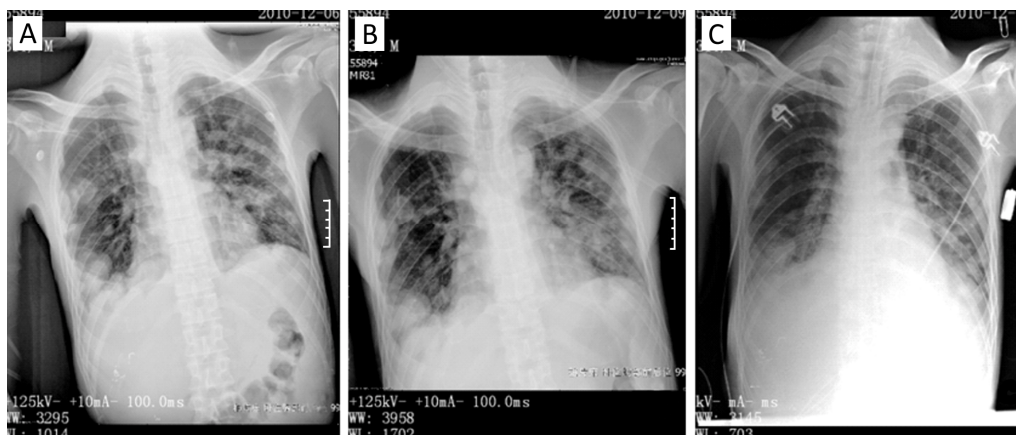


Figure 2. X-ray images of the chest before and after CPT-11 chemotherapy. The photos were taken on d (-5) (A), taken on d (-1) (B), and taken on d (+5) (C) after chemotherapy. The infection in double sides of the lung was alleviated on d (-1) than d (-5) after antibiotic and supportive treatment. The tumor size was reduced significantly on d (+5) after CPT-11 chemotherapy.

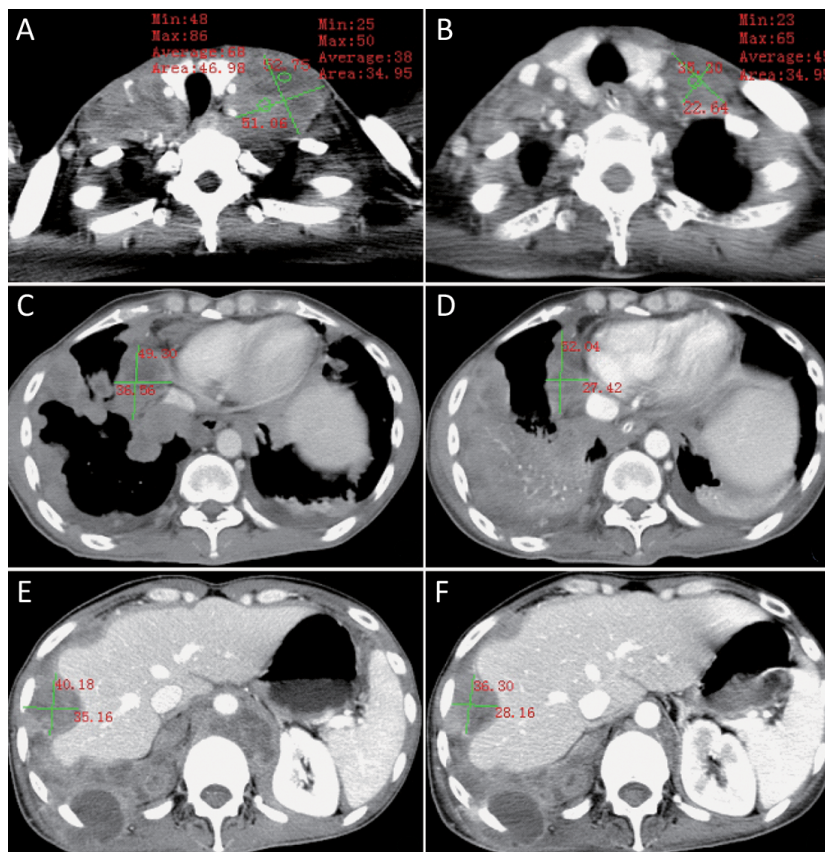


Figure 3. CT images before and after the treatment of CPT-11 [A, C, E, on d (-3); B, D, F, on d (+21)]. A, B: Tumor in the cervical lymph nodes; C, D: Tumor in thorax; E, F: Tumor in epigastrium.

Toxicity of CPT-11 was monitored timely. Infection appeared in d (+4), with white blood cell (WBC) count raised to $16.04 \times 10^9/L$. But on d (+9) the WBC count decreased to $1.31 \times 10^9/L$ and the platelet (PLT) count decreased to $52 \times 10^9/L$. A series of supportive treatments helped to restore. After application of another 200 mg of CPT-11 chemotherapy, the condition of the patient was further improved.

DISCUSSION

SEF is a very rare and indistinct fibrosarcoma variant in clinic and pathology, first described by Meis-Kindblom, et al. in 1995 with a wide age spectrum (median age 45 years) and no sex predilection^[5]. Most cases are located in the lower extremities and limb girdles, invariably deep-seated. Drug resistance is the

major obstacle to cure this tumor, especially in the developed and late stage of SEF.

In this case, the primary neoplasm arose from the deep site of retroperitoneum in a young male patient. Although histopathology supported the diagnosis of SEF, distinct pathologic characters in this case should be noticed. The prominent character was the great atypia of the nuclei, enlarged, variable in size and shape, and even bizarre nuclei presented in the tissue. The nuclei were greatly hyperchromatic while the nucleoli were inconspicuous, which lead to their dissimilarity to the feature of typical epithelioid cells. The second character was the moderate mitotic figures but accompanied with quite low Ki-67 labelling index. Thirdly, necrosis was more frequently encountered in this case than in a common SEF.

The low expression of Ki-67 is one of the character of SEF, generally, and does not related to the prognosis of SEF^[5]. The low proliferative index in this case was in consistent with the feature of common SEF, while the structural and cellular atypia in this case can explain its rapid progress.

Clinically, the tumor demonstrated a quite aggressive property, unlike that of the low-grade character of common SEF. The standard chemotherapy drug resistance and the emergent condition prompted us to apply small dose of chemotherapy drug to alleviate and resolve the emergent condition. CPT-11, a topoisomerase I (Topo I) inhibitor, was chosen to the chemotherapy of the tumor. CPT-11 applied in sarcoma chemotherapy is uncommon, and never reports about its application in SEF with emergent condition had been seen.

Topo I belongs to the DNA topoisomerase multimember family, which is essential for DNA topology modulation. This process is important during cell replication, translation, recombination, and repair^[6]. Topo I-inhibiting drugs and its derivatives can interfere with the function of Topo I by binding to its active site and preventing religation of the DNA strand^[7-9]. CPT-11 is converted into its active metabolite SN-38 by carboxylesterase in the liver^[10]. SN-38 has strong anti-tumor activity. However, SN-38 is not only associated with antitumor activity of CPT-11 but also with CPT-11-induced toxicity^[11]. The most significant adverse effects of the drug are severe diarrhea and bone marrow suppression. In this case, infection appeared on d (+4)

after CPT-11 application, leukocytopenia and thrombocytopenia appeared on d (+6) and continued to decrease in the following days until on d (+11), the WBC and PLT count restored when the supportive treatment functioned. The poor condition of the patient and the side effect of the drug limited the routine use of CPT-11 in this case, but the drug in this case is proved effective against aggressive fibrosarcoma, especially. Further, the outcome of this case confirmed that the Topo I inhibitor could be a challenging choice for sarcomas, even under emergent condition.

Disclosure of Potential Conflicts of Interest

No potential conflicts of interest were disclosed.

REFERENCES

1. Ossendorf C, Studer GM, Bode B, et al. Sclerosing epithelioid fibrosarcoma: case presentation and a systematic review. *Clin Orthop Relat Res* 2008; 466:1485–91.
2. Antonescu CR, Rosenblum MK, Pereira P, et al. Sclerosing epithelioid fibrosarcoma: a study of 16 cases and confirmation of a clinicopathologically distinct tumor. *Am J Surg Pathol* 2001; 25:699–709.
3. Karavasilis V, Seddon BM, Ashley S, et al. Significant clinical benefit of first-line palliative chemotherapy in advanced soft-tissue sarcoma: retrospective analysis and identification of prognostic factors in 488 patients. *Cancer* 2008; 112:1585–91.
4. Minchom A, Jones RL, Fisher C, et al. Clinical benefit of second-line palliative chemotherapy in advanced soft-tissue sarcoma. *Sarcoma* 2010; 2010:264360.
5. Meis-Kindblom JM, Kindblom LG, Enzinger FM. Sclerosing epithelioid fibrosarcoma. A variant of fibrosarcoma simulating carcinoma. *Am J Surg Pathol* 1995; 19:979–93.
6. Patro BS, Frohlich R, Bohr VA, et al. WRN helicase regulates the ATR-CHK1-induced S-phase checkpoint pathway in response to topoisomerase-I-DNA covalent complexes. *J Cell Sci* 2011; 124:3967–79.
7. Zhao H, Rybak P, Dobrucki J, et al. Relationship of DNA damage signaling to DNA replication following treatment with DNA topoisomerase inhibitors camptothecin/topotecan, mitoxantrone, or etoposide. *Cytometry A* 2012; 81:45–51.
8. Regairaz M, Zhang YM, Fu H, et al. Mus81-mediated DNA cleavage resolves replication forks stalled by topoisomerase I-DNA complexes. *J Cell Biol* 2011; 195: 739–49.
9. Manita D, Toba Y, Takakusagi Y, et al. Camptothecin (CPT) directly binds to human heterogeneous nuclear ribonucleoprotein A1 (hnRNP A1) and inhibits the hnRNP A1/topoisomerase I interaction. *Bioorg Med Chem* 2011; 19: 7690–7.
10. Slatter JG, Su P, Sams JP, et al. Bioactivation of the anticancer agent CPT-11 to SN-38 by human hepatic microsomal carboxylesterases and the in vitro assessment of potential drug interactions. *Drug Metab Dispos* 1997; 25:1157–64.
11. Ong SY, Clarke SJ, Bishop J, et al. Toxicity of irinotecan (CPT-11) and hepato-renal dysfunction. *Anticancer Drugs* 2001; 12:619–25.