



Aprepitant for gefitinib-induced refractory pruritus in Chinese malignancy population

Haifeng Qin^{1#}, Fang Wang^{1#}, Ke Wang², Hui Liu¹, Rui Guo¹, Zhen Zeng¹, Xin Pan¹, Xiaofeng Fu¹, Ting Zhang¹, Hongjun Gao¹

¹Department of Pulmonary Neoplasm Internal Medicine, 307 Hospital of PLA, Beijing 100000, China; ²Department of Integration Traditional Chinese and Western Medicine, Peking University Cancer Hospital, Beijing 100000, China

[#]These authors contributed equally to this work.

Correspondence to: Hongjun Gao. Department of Pulmonary Neoplasm Internal Medicine, 307 Hospital of PLA, Beijing 10000, China.

Email: hongjungao307@126.com.

Abstract: Targeted therapy is an important anti-cancer therapy in non-small cell lung cancer (NSCLC). Pruritus are the common side-effect with gefitinib, an anti-EGFR antibody and tyrosine-kinase inhibitor. We reported case reports to confirm the effects of aprepitant, a neurokinin receptor to management of refractory rash and pruritus in Chinese malignancy population. patients showed a rapid recovery from refractory pruritus, no adverse events occurred. Weekly follow-up visits showed the pruritus were stable and no further episodes was recorded.

Keywords: Aprepitant; rash; pruritus; gefitinib; non-small cell lung cancer (NSCLC)

Submitted Sep 19, 2018. Accepted for publication Jan 02, 2019.

doi: 10.21037/atm.2019.01.02

View this article at: <http://dx.doi.org/10.21037/atm.2019.01.02>

Introduction

Targeted medications have been showed significantly to improve the survival of patients with various malignancies (1). It is an important method for anti-cancer therapy. Its dermatologic adverse event (AE) may affect the majority of treated patients (2). Common dermatological AE associated with these medications are hair loss, skin rash, pruritus, mucositis, xerosis or fissures and paronychia, and hand and foot syndrome (3,4). Rash and Pruritus is an unpleasant feel (5), seriously affect the quality of life, even lead to medication reduction or withdrawal, and tumor progression. There is higher EGFR mutation in non-small cell lung cancer (NSCLC) in China, and it is commonly treated with gefitinib. It is reported that the highest incidence of rash and pruritus associated with gefitinib (6).

Substance P is an important neuro-mediator of pruritus. The keratinocytes of patients with chronic pruritus have an increased number of neurokinin 1 receptors (7). Targeted Medications might induce secretion of stem cell factors and increase the number of dermal mast cells in skin rashes (8).

Aprepitant is the world's first new generation of an oral

neurokinin 1 receptor antagonist that was approved in the United States in 2003, which is used in combination with other antiemetics to prevent chemotherapy-induced nausea and emesis (CINV), associated with initial and repeated treatment of highly emetogenic antitumor chemotherapy (HEC). Later it was approved to prevent post-operative nausea and vomiting (PONV) and nausea and vomiting associated with moderate emetic chemotherapy (MEC).

A few studies have found that pruritus caused by targeted medications have good response to aprepitant, an oral neurokinin 1 receptor antagonist that blocks mast-cell degranulation caused by neurokinin 1 receptor (9,10). It has been suggested that the effects of aprepitant are related to its preventing of mast-cell activation in the skin (11), however, the dosage and course of treatment is not uniform (12). Daniele reported aprepitant decreased severe pruritus induced by erlotinib (13), however there was none study reported the efficacy of aprepitant in treatment with pruritus induced by gefitinib which was widely used as the first treatment in NSCLC in China. This is our first report of aprepitant for refractory pruritus caused by targeted medication-gefitinib. Each patient provided

Table 1 Baseline characteristic

Characteristic	Pt 1	Pt 2	Pt 3	Pt 4
Age	45	61	49	56
Sex	Man	Man	Woman	Man
Tumor histology	Adenocarcinoma	Adenocarcinoma	Adenocarcinoma	Adenocarcinoma
Clinical stage	IV	IV	IV	IV
VAS score	8	8	7	7

VAS, Visual Analogue Scale.

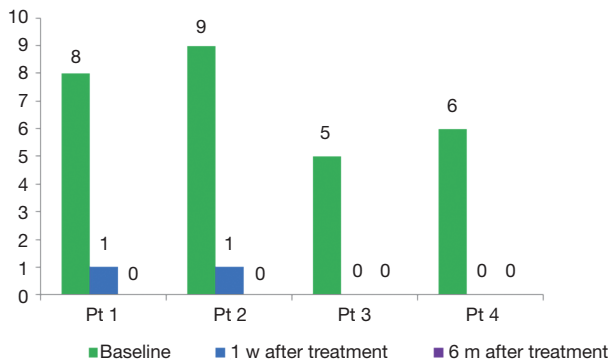


Figure 1 VAS score of individuals. The figure shows all the 4 patients benefit from the treatment, which can be judged by the reduction range of VAS score. VAS, Visual Analogue Scale.

written informed consent, and was previously treated with glucocorticoids without effect. We aim to evaluate the efficacy of aprepitant on pruritus, and explore the dosage and course of treatment with refractory rash and pruritus.

Case presentation

Between Jan 2017 and May 2017 in the 307th Hospital of Chinese PLA, we studied 4 NSCLC patients with severe skin rash and pruritus after resistance to standard treatment with steroids, antihistamines and Traditional Chinese Medicine. After informed consent, 4 patients took aprepitant (125 mg on day 1; 80 mg on day 2; 80 mg on day 3). Pruritus was assessed by VAS score in baseline, 7 days and 6 months after the first dose of aprepitant. Skin photos were compared baseline to 7 days after the first dose of aprepitant.

Table 1 shows characteristic of three males and one female, each of them with stage IV non-small cell lung cancer and receiving gefitinib at a dose of 250 mg daily, presented with rash and pruritus resistant to local application of glucocorticoids and to standard systemic

therapies.

A 61-year-old man, patient no.2, with lung adenocarcinoma (cT4M3N1b, stage IV, exon 19 deletion) was received gefitinib. He has no smoking history and no medication allergies. The severe rash and pruritus seriously influenced his life quality within the first week after taking gefitinib. He firstly received local application of glucocorticoids, but there is no effect on it. Then we adjust the treatment with oral aprepitant, day 1, 125 mg; day 2, 80 mg; day 3 80 mg. He showed a prompt recovery from rash and pruritus in 24 hours after the first administration of aprepitant. Three additional patients received aprepitant for pruritus resistant to local application of glucocorticoids, and only one time administration was able to control the pruritus. We assessed the efficacy of aprepitant for pruritus via Visual Analogue Scale (VAS) score in 1 week and 6 months after first dose of aprepitant (seen in *Figure 1*). The pruritus was recovered and was compared in *Figure 2*.

Patient 2's rash and pruritus recurred after two weeks, he took the next administration of aprepitant and rash and pruritus was completely recovered (seen in *Figure 3*). With 6 months follow-up visit from the first dose of aprepitant, there is no recurrence of pruritus.

Discussion

Pruritus is a common side effect of anti-EGFR antibodies and tyrosine kinase inhibitors used in cancer patients, primarily on the face, neck and upper torso. Studies showed that, including all levels of pruritus, the highest incidence of high-grade pruritus is gefitinib (6). Pruritus is an unpleasant skin AE, which seriously affecting the life quality of patients, chronic refractory pruritus also brings new challenges for cancer treatment, some patients with refractory pruritus has to stop targeted medication treatment, which increase the risk of tumor recurrence. Susan reported the results of a survey of 110 oncologists revealed that 76% of survey

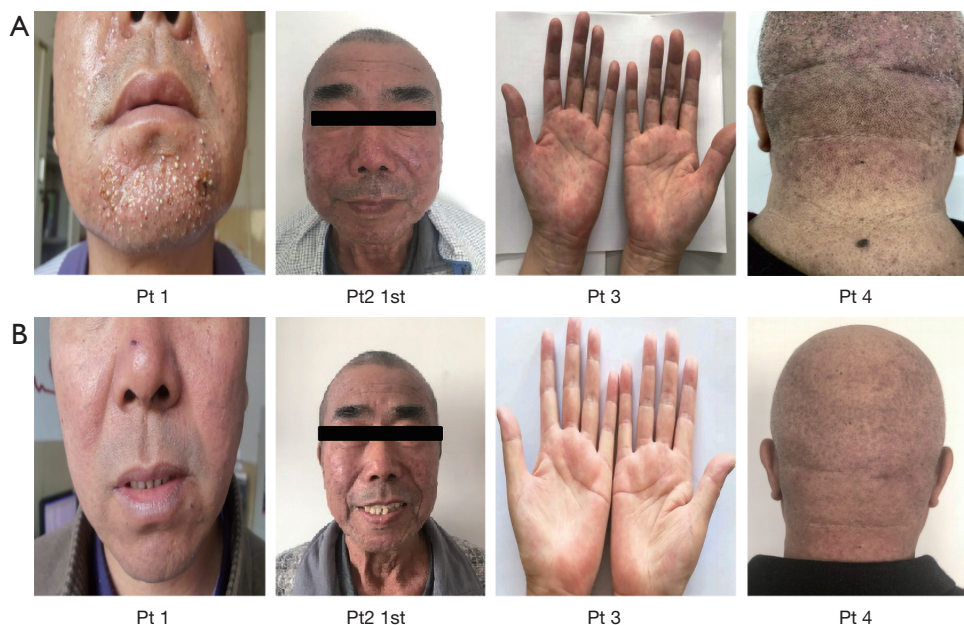

Figure 2 Benefit of aprepitant for gefitinib-induced rash and pruritus. (A) Baseline; (B) after 1 week treatment.

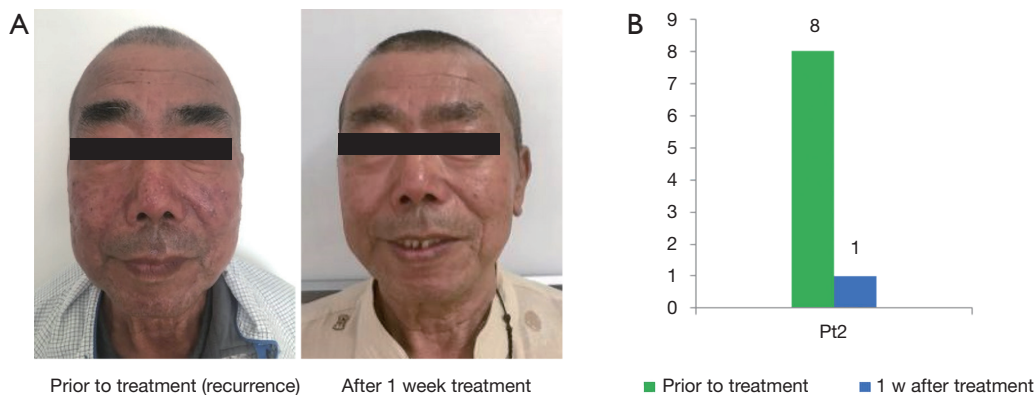


Figure 3 Oral 2nd treatment of aprepitant for recurred gefitinib-induced rash and pruritus in Pt2. (A) Pruritus; (B) VAS score.

oncologists had held the EGFR therapy owing to rash and pruritus, the drug was held up to 2–3 weeks (14).

As reported, EGFR tyrosine kinase inhibitors increase the number of dermal mast cells in skin rashes, which play an important role in pruritus. When activated the mast cells, the tryptase is released and to activated C fibres, which will transmit nerve impulse to central nervous system (15). There was crosstalk between C fibres and mast cell mediate by substance P, as known one kind of neuropeptides (16). Substance P participated in regulation of pruritus in two ways: first, mast cells will degranulation caused by high concentration of substance P bind to NK1 receptors

expressed in the surface of mast cells (10); second, the binding also lead mast cells to product of tumor necrosis factors (TNF)- α , which is known to sensitive C-fibre terminal (17).

Aprepitant is a new generation of NK-1 antagonist, its anti-pruritus activity can be explained: first, Aprepitant can block the substance P to bind with NK-1 receptor in Mast cells in skin rash site.; second, substance P is a regulatory peptide found in areas of the central nervous system. Aprepitant is a potent and CNS-penetrant antagonist, maybe it can block the nerve impulse of pruritus in CNS.

The efficacy of aprepitant with treatment of pruritus has

been confirmed. A few studies found the same conclusion: In 2009, Duval and Dubertret reported the first case of refractory pruritus treated with aprepitant of 80 mg, and the VAS score dropped from 8 to 2.33. All patients disappeared insomnia complain and had good sleep quality (18). Since then, treatment of aprepitant for refractory pruritus has been reported in the United States, South Korea, and Japan including cutaneous T-cell lymphoma, solid tumors, and many others indications. Many patients severely degrade their life quality due to pruritus-related side effects, insomnia, acne and so on. Most patients received routine treatment, but failed. However, almost all patients with aprepitant were relieved of pruritus symptoms including acne subsides, reduced insomnia, and VAS score dropped significantly (8,12,19).

Among these studies, there was limit data that aprepitant treated with pruritus induced by gefitinib in Asia population, especially in Chinese. Also there was no standard regimen of aprepitant in pruritus, the dosage and treatment cycle still to be investigated. Our study referenced to the standard treatment of aprepitant in CINV, we determined the regimen in this study: 125 mg on day 1; 80 mg on day 2; 80 mg on day 3, one cycle; the regimen will be repeated after pruritus relapse. We found that all the patients' VAS scores decreased and skin acne was visually relieved (seen in *Figure 2*) after treatment, and this medication program has a good effect on pruritus without significant side effects. Based on our reports, aprepitant is a reliable option for the treatment of refractory pruritus due to gefitinib therapy to improve life quality of the patients.

There are some limitations in our study. The samples were limit in our study and to further validate the efficacy of aprepitant for refractory pruritus, large scale, randomized controlled trials are still needed. We only investigated the pruritus induced by gefitinib, and need to explore more type pruritus, such as induced by anti-CTLA 4 antibody, anti PD-1/PD-L1 antibody. One of our patients experienced recurred pruritus, so it's important how to identify underlying pruritus in patients treated with EGFR inhibitors and select the patients with potential benefit be treated with aprepitant. These will be explored in our next study.

Conclusions

This is the first report of aprepitant for refractory pruritus caused by targeted medication in Chinese malignancy population. We confirmed the efficacy of aprepitant on

refractory rash and pruritus, the dosage (125 mg on day 1; 80 mg on day 2; 80 mg on day 3) was well tolerated and easy to apply to supportive treatment.

Acknowledgements

None.

Footnote

Conflicts of Interest: The authors have no conflicts of interest to declare.

Informed Consent: Written informed consent was obtained from the patients for publication of this manuscript and any accompanying images.

References

1. Ricciardi S, Tomao S, de Marinis F. Toxicity of targetedtherapy in non-small-cell lung cancer management. *Clin Lung Cancer* 2009;10:28-35.
2. Balagula Y, Lacouture ME, Cotliar JA. Dermatologic toxicitiesof targeted anticancer therapies. *J Support Oncol* 2010;8:149-61.
3. Lacouture ME, Anadkat MJ, Bensadoun RJ, et al. Clinical practice guidelines for the prevention and treatment of EGFR inhibitor-associated dermatologic toxicities. *Support Care Cancer* 2011;19:1079-95.
4. Chan A, Tan EH. How well does the MESTT correlate with CTCAE scale for the grading of dermatological toxicities associated with oral tyrosine kinase inhibitors? *Support Care Cancer* 2011;19:1667-74.
5. Liu T, Ji RR. New insights into the mechanisms of itch: are pain and itch controlled by distinct mechanisms? *Pflugers Arch* 2013;465:1671-85.
6. Santoni M, Conti A, Andrikou K, et al. Risk of pruritus in cancer patients treated with biological therapies: A systematic review and meta-analysis of clinical trials. *Crit Rev Oncol Hematol* 2015;96:206-19.
7. Yosipovitch PA. Pruritus. In: Lacouture ME, editor. *Dermatologic principles and practice in oncology*. Hoboken, NJ: John Wiley& Sons, Inc., 2014.
8. Gerber PA, Buhren BA, Homey B. More on Aprepitant for Erlotinib-Induced Pruritus. *N Engl J Med* 2011;364:486-7.
9. Ständer S, Siepmann D, Herrgott I, et al. The neurokinin receptor 1 with aprepitant: a novel antipruritic strategy.

- PLoS One 2010;5:e10968.
10. Gerber PA, Buhren BA, Cevikbas F, et al. Preliminary evidence for a role of mast cells in epidermal growth factor receptor inhibitor-induced pruritus. *J Am Acad Dermatol* 2010;63:163-5.
 11. Wallengren J. Neuroanatomy and neurophysiology of itch. *Dermatol Ther* 2005;18:292-303.
 12. He A, Alhariri JM, Sweren RJ, et al. Aprepitant for the Treatment of Chronic Refractory Pruritus. *Biomed Res Int* 2017;2017:4790810
 13. Santini D, Vincenzi B, Guida FM, et al. Aprepitant for management of severe pruritus related to biological cancer treatments: a pilot study. *Lancet Oncol* 2012;13:1020-4.
 14. Boone SL, Rademaker A, Liu D, et al. Impact and management of skin toxicity associated with anti-epidermal growth factor receptor therapy: survey results. *Oncology* 2007;72:152-9.
 15. Yosipovitch G, Greaves MV, Schmelz M. Itch. *Lancet* 2003;361:690-4.
 16. Suzuki R, Furuno T, McKay DM, et al. Direct neurite-mast cell communication in vitro occurs via the neuropeptide substance P. *J Immunol* 1999;163:2410-15.
 17. Cocchiara R, Lampiasi N, Albegiani G, et al. Mast cell production of TNF-alpha induced by substance P evidence for a modulatory role of substance P-antagonists. *J Neuroimmunol* 1999;101:128-36.
 18. Duval A, Dubertret L. Aprepitant as an antipruritic agent? *N Engl J Med* 2009;361:1415-6.
 19. Chang SE, Han SS, Jung HJ, et al. Neuropeptides and their receptors in psoriatic skin in relation to pruritus. *Br J Dermatol* 2007;156:1272-7.

Cite this article as: Qin H, Wang F, Wang K, Liu H, Guo R, Zeng Z, Pan X, Fu X, Zhang T, Gao H. Aprepitant for gefitinib-induced refractory pruritus in Chinese malignancy population. *Ann Transl Med* 2019;7(3):54. doi: 10.21037/atm.2019.01.02