

# Left video-assisted thoracic surgery thymectomy

Anee Sophia Jackson<sup>1</sup>, Chris Devulapalli<sup>1</sup>, Alexa Lowe<sup>1</sup>, Abigael Bragado<sup>2</sup>, Lorenzo De Marchi<sup>3</sup>, M. Blair Marshall<sup>1</sup>

<sup>1</sup>Division of Thoracic Surgery, Department of Surgery, <sup>2</sup>Clinical Nursing, Department of Surgery, <sup>3</sup>Department of Anesthesia, Medstar Georgetown University Hospital, Washington, DC, 20007, USA

*Contributions:* (I) Conception and design: MB Marshall; (II) Administrative support: A Bragado, B Marshall; (III) Provision of study materials or patients: B Marshall; (IV) Collection and assembly of data: AS Jackson, B Marshall, A Lowe; (V) Data analysis and interpretation: AS Jackson, B Marshall, A Lowe; (VI) Manuscript writing: All authors; (VII) Final approval of manuscript: All authors.

*Correspondence to:* Dr. Anee Sophia Jackson. Division of Thoracic Surgery, Department of Surgery, Medstar Georgetown University Hospital, Washington, DC, 20007, USA. Email: Anee.S.Jackson@gunet.georgetown.edu.

**Abstract:** Video-assisted thoracic surgery (VATS) for the management of non-thymomatous myasthenia gravis (MG) as well as the management of small thymomas and other benign thymic pathology has been gaining in acceptance and popularity as an alternative to the traditional median sternotomy approach. Although VATS thymectomy has been described in several variations, our current preference is a left sided VATS approach due to the exposure it provides in critical areas of dissection. Here we describe our technique for the left sided VATS thymectomy including patient selection, preoperative preparation, operative steps, and postoperative care. We also share pitfalls and tips to prevent them at each step of the procedure learned from our experience with this approach.

**Keywords:** Minimally invasive; thymectomy; myasthenia gravis (MG); left video-assisted thoracic surgery (VATS)

Received: 22 December 2016; Accepted: 25 December 2016; Published: 10 April 2017.

doi: 10.21037/jovs.2017.02.13

**View this article at:** <http://dx.doi.org/10.21037/jovs.2017.02.13>

## Introduction

Video-assisted thoracoscopic thymectomy for the management of non-thymomatous myasthenia gravis (MG), small thymomas, and other benign thymic pathology has become a progressively adopted approach. Traditionally thymectomies have been performed through a median sternotomy or open transcervical technique (1). Over the last several years, the minimally invasive video-assisted thoracic surgery (VATS) approach has evolved. A variety of VATS approaches have been described including from both the left or right side, bilateral and subxyphoid. These minimally invasive techniques are associated with shorter hospital stays, decreased postoperative pain, low procedural morbidity and mortality, and equivalent efficacy compared to open techniques (2). A recent randomized prospective study showed that a VATS approach significantly improved short-term postoperative pulmonary function contributing to faster recovery, compared to traditional thymectomy via

median sternotomy (3).

VATS approach also offers excellent views of the thymic bed from the diaphragm to the neck and the ability to provide magnification of critical dissection planes. Currently our preference is for a left sided VATS approach. Although some prefer a right sided approach to more easily view the junction of the innominate vein with the superior vena cava, we think this area is well visualized with a left sided approach. In addition, concern for adequate visualization of the thymic tissue draped over the aorto-pulmonary window has kept us from adopting the right sided approach. In our opinion, a bilateral or left sided approach gives the best exposure of the aortopulmonary window.

## Patient selection

Thymectomy is indicated in patients with nonthymomatous MG to increase the probability of symptomatic

improvement including remission, minimize exposure to adverse effects of immunotherapy, and for patients who are refractory to medical therapy (4). Uncertainty over the role of thymectomy for patients with purely ocular symptoms of MG and those with late onset of disease exists as the response to thymectomy in these patients is not always predictable. However, given the dramatic improvement in surgical morbidity with VATS thymectomy, we have expanded our selection criteria for MG patients to offer surgical intervention to all patients with acceptable risk. Currently, the morbidity of thymectomy is so low, even a small chance of remission appears to justify the procedure. In addition, patients with small (<2 cm) intrathymic thymoma meet criteria for VATS thymectomy although larger thymomas are not a complete contraindication. Some suggest that lesions of 6 or 4 cm are the limits of tumors that are suitable for a VATS approach (5). We have found this not to be the case. The thoracoscopic view, with the inherent magnification and an angled lens provides better visualization than an open technique. We routinely resect pericardium thoracoscopically if there is ever any question of invasion. In our opinion, the only current contraindication to a thoracoscopic approach is involvement of the vein, and this is even debatable. When the vein is involved, we prefer to reconstruct the vein when it needs to be resected. Simple ligation and resection of the vein can be done and is technically feasible with a VATS approach. An additional advantage of the thoracoscopic approach is identification of drop metastases not seen on preoperative imaging. Elderly patients with multiple co-morbidities or those with a previous sternotomy may have relative contraindications to minimally invasive surgery. Although, we have reported our experience on resection of anterior mediastinal masses in patients with previous sternotomy or other mediastinal procedures using the left sided VATS approach (6).

### Pre-operative preparation

In preparation for surgery, patients should have a computed tomography (CT) scan with intravenous contrast as well as an EKG and preoperative blood work. CT scan is important for evaluation of thymoma but also can uncover anatomic abnormalities. Operative planning should be done in a multidisciplinary nature including the patient's neurologist to plan for peri-operative intravenous immunoglobulin (IVIG) therapy if needed, as well as thoracic anesthesia. Patients should continue on their anti-cholinesterase

inhibitors prior to surgery including the morning of the procedure, the perioperative period and postoperatively. When needed, oral medication can be given in the operating room via an oral gastric tube.

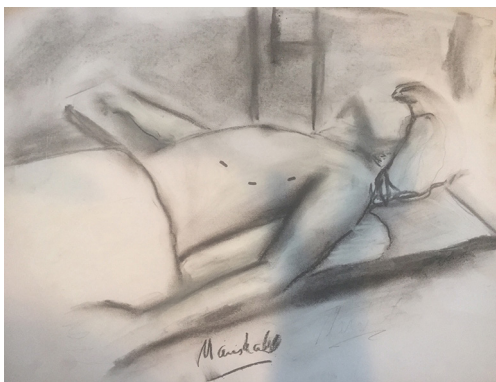
### Equipment preference card

- ❖ 5 mm 30 degree camera;
- ❖ Maryland laparoscopic graspers;
- ❖ Sealing device (Harmonic® Ethicon, Somerville, NJ, USA or LigaSure™ Medtronic, Minneapolis, MN, USA);
- ❖ 3–5 5 mm ports;
- ❖ Bovie extended hook;
- ❖ Insufflation tubing for CO<sub>2</sub>;
- ❖ Laparoscopic blunt dissection instrument;
- ❖ Laparoscopic scissors;
- ❖ Endocatch bag;
- ❖ Exparel® (Pacira Pharmaceuticals, Parsippany, NJ, USA).

### Anesthesia considerations

Patients with MG have always been considered a challenge from the anesthesiologist's perspective because of the risk of developing postoperative respiratory weakness and consequently a prolonged intubation requirement. The use of muscle relaxants that in many cases are necessary to facilitate endotracheal intubation and to allow a better surgical exposure can further complicate the scenario. The anesthesia plan for patients with MG is designed to minimize, or possibly completely avoid, the use of muscle relaxants facilitating a prompt recovery of full muscular function at the completion of the procedure. If necessary, muscle relaxants can be administered throughout the procedure but always utilizing a neuromuscular twitch monitor to titrate the dose to effect.

A thorough collection of information regarding the patient's medical history and medications can help in determining the grade of the disease and predict the likelihood of postoperative respiratory failure. The presence of three of the following criteria: (I) duration of the disease for 6 years or longer; (II) chronic comorbid pulmonary disease; (III) pyridostigmine dose >750 mg/d; (IV) preoperative use of steroids and/or; (V) previous episode of respiratory failure has been indicated as a predictor of increased risk of postoperative intubation and ventilation requirement (7). Our patients with MG scheduled for thymectomy are instructed to take their morning dose of



**Figure 1** Patient positioning and port placement. The patient is placed in a semi-supine position with the left anterior axillary line centered at the superior most position and the ipsilateral arm dropped below the chest wall. Three 5 mm ports are placed along the infra-mammary fold and lateral crease along the anterior axillary line

anticholinergic medication at their regular schedule. If that coincides with the intraoperative period we administer the drugs IV at 1/30 of the oral dose during the surgery at the schedule time.

We use a single lumen endotracheal tube along with CO<sub>2</sub> insufflation, therefore avoiding the need for endobronchial lung isolation. Carbon dioxide insufflation can mimic a tension pneumothorax in some instances causing respiratory and hemodynamic changes. To reduce this complication, CO<sub>2</sub> insufflation should be performed slowly and pressure limited to 10 mmHg (8). Excessive administration of intravenous fluids intra-operatively can cause increased shunting and lead to pulmonary edema of the dependent lung

In these procedures, good IV access (at least one large bore catheter) is imperative to be able to administer fluids for resuscitation in case of unexpected bleeding from one of the major thoracic vessels. Beside standard ASA monitoring the insertion of an arterial line catheter for invasive blood pressure monitoring is utilized since sudden hemodynamic collapse can occur with unexpected bleeding or also secondary due to the bilateral capnothoraces that often occurs during thymectomy. Careful closed loop communication should be used between the surgical and anesthesia teams on a continual basis during the procedure. We routinely discuss the respiratory rate, tidal volumes, and plans once the contralateral pleural space has been entered. Often, further decrease of the CO<sub>2</sub> insufflation pressure with an increase in the tidal volumes will ameliorate the

hypoxia and hypercarbia associated with this event.

### Procedure/operative steps

Following induction of anesthesia, the patient is placed in a semi-supine position with the left anterior axillary line centered at the superior most position (*Figure 1*). This modified positioning can be achieved with the assistance of a soft shoulder roll and a conforming beanbag device to hold the patient in position. The ipsilateral arm is dropped below the chest wall to maximally expose the sub-axillary intercostal spaces, and retract the arm out of the surgeon's field, in particular so that it does not interfere with the longer laparoscopic instruments. The left hemithorax is then prepped and draped, and the right hemithorax is also made easily accessible in case a bilateral VATS approach is deemed necessary for rare instances requiring more exposure.

To begin the operation, three 5 mm ports are placed along the infra-mammary fold and lateral crease along the anterior axillary line while ventilation is being held (*Figure 1*). We prefer to use standard laparoscopic 5 mm trocars for all port sites and will alter the trajectory of port placement during the operation to prevent excessive pressure on the nerves. The superior port is placed first as placement of the inferior ports without CO<sub>2</sub> insufflation could result in cardiac injury. These inferior ports are placed under thoroscopic visualization. A 5 mm, 30 degree angled camera is placed into the most lateral port and the pleura underlying the sternum is divided superiorly along the pericardium and inferiorly towards the diaphragm using a hook electrocautery device. Care is taken to avoid injury to the phrenic nerve and only sharp dissection with scissors is performed near the nerve. The left inferior horn is first freed from its attachments to the underlying pericardium using a combination of blunt dissection and the LigaSure™. There are often small vessels entering the gland from the pericardium below which are sealed with this device. The gland is then swept up off the underlying pericardium (*Figure 2*).

During the procedure, periodically we will move the dissection to other anatomic regions. We find it is better to work in one area until one starts to "dig a hole" and then move to another part of the dissection. Defining the venous anatomy should be done with great caution. This can be a tedious part of the dissection, in particular in obese patients with extra fatty tissue concealing the vessels. We will continue the dissection in one area, until progress is not being easily made and then move to another anatomic



**Figure 2** Left video assisted thoracoscopic thymectomy of non-thymomatous myasthenia gravis (MG) (9).

Available online: <http://www.asvide.com/articles/1439>

region again. Intermittently changing the bed of dissection keeps one's perspective fresh, allows one to re-evaluate the operation and continue to make progress. The "fresh" perspective goes a long way in avoiding injury. Despite the fact that the phrenic nerve may have been previously identified, we continually re-identify it throughout the operation.

Dissection of the junction of the left internal mammary vein where it enters the innominate vein is the initial strategy used to begin the dissection of the venous anatomy. We then work across the chest to the junction of the innominate with the right internal mammary and superior vena cava. However, typically we will have already dissected the right inferior horn up to this region in preparation. If needed, the right pleural space can be opened and identification of the right phrenic nerve performed. During the dissection of the innominate, the thymic veins are dissected and then ligated with a sealing device. We have not found it necessary to use clips.

During the dissection we continue along the anterior border of the thymus into the neck to fully dissect the superior horns. The lateral border of the left horn can be followed up from the chest and then dissection below the gland, on top of the vein, working all sides of the horn to reach the apex. Small lateral branches from the internal mammary are typically seen during this portion of the dissection. Once dissection of both superior horns is completed, just the right lateral border remains to be dissected. This is then bluntly dissected away from the pleura. The freed gland is placed in a bag. If there is no concern for thymoma, we extract the gland piece meal through a 10 mm port incision. Once the gland is extracted,

we use Exparel® as intercostal blocks for the maximal amount of pain relief it provides.

If the dissection has gone smoothly and there is no concern for drainage following surgery, the CO<sub>2</sub> needs to be evacuated; this may be one or both pleural spaces. For this, we use one of two strategies. We will place a small bore chest tube (20 Fr) through one of the ports, and then close the other ports. We remove the tube in the operating room under valsalva maneuver or as an alternative, in the recovery area. The other option is communicate with our anesthesia colleagues and have them hyperinflate the lungs and evacuate all of the CO<sub>2</sub> through the trocars. This latter approach minimizes pain and prepares the patient for early discharge.

### Role of team members

- ❖ Primary surgeon: Lead the operative team;
- ❖ Assistant surgeon/Trainee: He/She stands on the same side of the table as the primary surgeon. This allows them to operate the camera and have the same perspective as the primary surgeon during the surgery. This enhances teaching opportunities in both the view and in assisting the surgery;
- ❖ Scrub/Circulator: Positioning of the patient is key in maximizing exposure for the operation. In addition, as we use traditional laparoscopic instruments, their increased length can be obstructed by the arm. Positioning the arm below the chest allows for full range of motion of the instruments;
- ❖ Anesthesia: Intubation, anesthetic agents, analgesia and intraoperative anticholinesterase inhibitors when indicated (see additional comments under anesthesia considerations).

### Post-operative management

We have developed several strategies to minimize the negative impact of surgery on patients with MG undergoing thymectomy. Timing of acetylcholinesterase inhibitors during the pre and post operative period are a particular concern. Patients with MG, when hospitalized, are typically on a neurology unit. These nurses have experience with MG patients and the critical nature of timing of their medication. Our patients instead go to the thoracic unit where timing of medication is not as critical, thus it is not in the mind-set of the thoracic nurses. This is a safety issue for postoperative MG patients. We have our MG patients

bring their anticholinesterase inhibitors to the hospital and take their medication as per their routine, including up until the time of surgery, intra-operatively and postoperatively as inpatients. Patients are discharged on the same day of surgery or the next morning. The patients continue their medication following discharge as there is typically a significant delay in the effect of thymectomy. Patients should have close follow-up with their neurologist post operatively in addition to the surgeon.

Our patients frequently report adequate pain control from the intercostal blocks using liposomal bupivacaine (Exparel®). They are counseled on pain expectations for when the blocks wear off, typically around 72 hours, and they are discharged with adequate pain medication including narcotics as needed. We recommend patients follow up in thoracic surgery clinic for routine post-operative check approximately 2 weeks following surgery.

## Tips and pitfalls

### *Trocar insertion*

- ❖ Pitfall: Pain, intercostal nerve injury;
- ❖ Tip: We perform the surgery with 3–5 mm ports and avoid as much trauma to the intercostal nerves as possible by using graspers through these trocars at all times;
- ❖ Tip: Long trocars are useful in the obese patients;
- ❖ Tip: Insufflation of the hemithorax with CO<sub>2</sub> to a pressure of 10 mmHg can significantly improve exposure and enhance working space for instruments by depressing the diaphragm and lung out of the field.

### *Mobilization of pleura underlying sternum superiorly along pericardium and inferiorly to diaphragm*

- ❖ Pitfall: Injury to phrenic nerve;
- ❖ Tip: While mobilizing the pleura near the phrenic nerve, we use only sharp dissection with scissors to avoid any thermal injury to the phrenic nerve;
- ❖ Tip: Continual reassessment of the operative bed and altering perspective, allows one to at all times keep the location of the phrenic nerve in perspective.

### *Mobilization of inferior horns*

- ❖ Pitfall: Injury of right phrenic nerve;
- ❖ Tip: When mobilizing right sided portion of the thymus, the contralateral phrenic nerve can be injured during a

left sided VATS approach. A 30 degree camera can help to better visualize the path of the phrenic nerve on the contralateral side. If needed, the contralateral pleura can be opened to identify the underlying phrenic nerve and avoid injury.

### *Mobilization of superior horns*

- ❖ Pitfall: Bleeding from thymic veins;
- ❖ Tip: Thymic veins drain from the thymus gland directly into the innominate vein. These need to be carefully identified, dissected, and sealed (Harmonic® Ethicon or LigaSure™ Medtronic). We often start by identifying the junction of the left mammary vein with the innominate vein to delineate anatomy surrounding the superior horns. We then work along the innominate towards the right carefully dissecting the veins. The dissection should be performed meticulously with optimal visualization. If at any time, one does not have perfect visualization, we will add another trocar switch the camera to another port to optimize visualization;
- ❖ Pitfall: Violation of the right parietal pleura;
- ❖ Tip: The near proximity of the right sided pleura to the right superior horn of the thymus, at the junction of the innominate with the superior vena cava, can easily lead to its violation. During the dissection, this can lead to hypoxia or hypotension. We will lower the insufflation pressure or increase the peak airway pressures in order to maintain adequate oxygenation and ventilation. At the completion, the capnothorax can easily be managed by placing a small red rubber drainage catheter into the pleural space and removing it after an intraoperative valsalva maneuver. Postoperative thoracostomy tube placement is most often unnecessary;
- ❖ Pitfall: Being unable to dissect the cervical horns;
- ❖ Tip: When needed, a 4<sup>th</sup> trocar can be placed medially above the heart, to allow for a more direct access to the cervical region when needed. This most often depends on the size of the patient. In addition, the CO<sub>2</sub> insufflation helps expand the dissection in this region. Lastly, for those where the cervical dissection is impossible through the chest (rare) a small cervical incision can be made and the remainder of the cervical horns dissected;
- ❖ Tip: CO<sub>2</sub> insufflation of the left hemithorax is once again critical in dissecting the potential space in the cervical region and allowing maximal exposure to identify the apices of the bilateral superior horns removing all thymic tissue;
- ❖ Tip: As mentioned previously, an experienced surgeon is

always prepared to redirect their focus to other aspects of the operation when held up at one step without progressing effectively. The common surgical pitfall of, performing the same action and expecting a different outcome, cannot be overemphasized. Mobilization of the four horns of the thymus does not often adhere to a stringent step-wise progression, and frequent redirection to a different area can not only give the surgeon a fresh perspective of the surgical field but also allow improved exposure to a previously difficult dissection area (i.e., apices of superior horns).

### Rib blocks

- ❖ Pitfall: Inadequate block, pain control;
- ❖ Tip: We always perform multiple rib blocks under direct camera visualization with liposomal tagged bupivacaine (Exparel®) to ensure optimal postoperative pain control. We have found that this significantly improves patient's pain management and has also made this surgery an outpatient phenomenon at our institution.

### Conclusions

We have demonstrated a safe and minimally invasive approach with the left VATS thymectomy in patients with MG or other benign thymic conditions requiring removal of the gland. With careful patient selection, proper perioperative planning, and meticulous attention to surgical technique, this can be an excellent alternative to traditional approaches to thymectomy by significantly improving postoperative morbidity and even having potential to make this an outpatient procedure.

### Acknowledgements

None.

doi: 10.21037/jovs.2017.02.13

**Cite this article as:** Jackson AS, Devulapalli C, Lowe A, Bragado A, De Marchi L, Marshall MB. Left video-assisted thoracic surgery thymectomy. *J Vis Surg* 2017;3:47.

### Footnote

*Conflicts of Interest:* The authors have no conflicts of interest to declare.

### References

1. Whitson BA, Andrade RS, Mitiek MO, et al. Thoracoscopic thymectomy: technical pearls to a 21st century approach. *J Thorac Dis* 2013;5:129-34.
2. Ng CS, Wan IY, Yim AP. Video-assisted thoracic surgery thymectomy: the better approach. *Ann Thorac Surg* 2010;89:S2135-41.
3. Rückert JC, Walter M, Müller JM. Pulmonary function after thoracoscopic thymectomy versus median sternotomy for myasthenia gravis. *Ann Thorac Surg* 2000;70:1656-61.
4. Sanders DB, Wolfe GI, Benatar M, et al. International consensus guidance for management of myasthenia gravis: Executive summary. *Neurology* 2016;87:419-25.
5. Ye B, Tantai JC, Ge XX, et al. Surgical techniques for early-stage thymoma: video-assisted thoracoscopic thymectomy versus transsternal thymectomy. *J Thorac Cardiovasc Surg* 2014;147:1599-603.
6. Marshall MB, DeMarchi L, Emerson DA, et al. Video-assisted thoracoscopic surgery for complex mediastinal mass resections. *Ann Cardiothorac Surg* 2015;4:509-18.
7. Leventhal SR, Orkin FK, Hirsh RA. Prediction of the need for postoperative mechanical ventilation in myasthenia gravis. *Anesthesiology* 1980;53:26-30.
8. Brodsky JB, Cohen E. Video-assisted thoracoscopic surgery. *Current Opinion in Anaesthesiology* 2000;13:41-5.
9. Jackson AB, Devulapalli C, Lowe A, et al. Left video assisted thoracoscopic thymectomy of non-thymomatous myasthenia gravis (MG). *Asvide* 2017;4:131. Available online: <http://www.asvide.com/articles/1439>