



Autoimmune diseases associated with thymoma

Motoki Yano

Division of Chest Surgery, Department of Surgery, Aichi Medical University, Yazako-Karimata, Nagakute, Aichi, Japan

Correspondence to: Motoki Yano. Division of Chest Surgery, Department of Surgery, Aichi Medical University, 1-1 Yazako-Karimata, Nagakute, Aichi 480-1195, Japan. Email: yano.motoki.369@aichi-med-u.ac.jp.

Abstract: Thymoma is the most common neoplasm of the anterior mediastinum. This neoplasm is composed with neoplastic epithelial cells and non-neoplastic T lymphocytes with varying degrees. In the advanced stage of thymomas, recurrence is not uncommon, and treatment for recurrent lesions—especially disseminated lesions—is not easy. In addition, thymoma is often associated with autoimmune diseases. The representative disorder is myasthenia gravis (MG). Combined treatment for recurrence and complex autoimmune diseases is often difficult. The efficacy of thymectomy for early-onset MG without thymomas was demonstrated in a recent clinical trial, and it may be effective for MG patients associated with thymoma. However, thymectomy or thymomectomy usually does not affect other non-MG autoimmune diseases. Thymectomy has been performed via median sternotomy for many years, and thoracoscopic or mediastinoscopic thymectomy has been reported often. We established a subxiphoid approach to thoracoscopic thymectomy, and its usefulness and efficacy have been reported. In this section, the detailed procedures of thymectomy using this subxiphoid approach are introduced.

Keywords: Autoimmune diseases; thymoma; myasthenia gravis; thymectomy

Received: 03 September 2019; Accepted: 21 October 2019; Published: 06 January 2020.

doi: 10.21037/jovs.2019.10.04

View this article at: <http://dx.doi.org/10.21037/jovs.2019.10.04>

Thymoma and its associated autoimmune diseases

Thymoma is the most common neoplasm of the anterior mediastinum. This neoplasm is composed with neoplastic epithelial cells and non-neoplastic T lymphocytes with varying degrees (1). It behaves like a relatively benign tumor, growing slowly and seldom metastasizing. Surgical resection has been selected as the principal treatment, and completeness of resection is considered the most important determinant of the long-term survival in thymomas (2-4). However, in the advanced stage of thymomas, we often experience recurrence, and treatment for recurrent lesions—especially disseminated lesions—is not easy.

Thymoma is often associated with autoimmune diseases. The representative disorder is myasthenia gravis (MG). About 20% of the patients with thymoma have symptoms of MG (4,5) clinically. It is not easy to explain why autoimmune disorders are induced by thymomas. However, a brief explanation has been proposed (6). The negative selection of autoreactive T cells in the thymus is dependent on the presentation of

autoantigens by the medullary thymic epithelial cells and dendritic cells. Thymomas have a cortical epithelial cell function and contain a large number of immature T cells that usually reside in the thymic cortex. However, they lack the medullary epithelial cell function, which is the negative selection of the developing T cells. Immature T cells generated in the thymoma are then exported out of the thymus, which likely induces autoimmune disease in thymoma patients.

Treatment for autoimmune diseases associated with thymoma (Table 1)

Treatment for autoimmune diseases associated with thymoma is summarized in *Table 1*. As “autoimmune diseases” includes a number of different entities, the treatment approach is not uniform, and treatment for MG in particular is varied. Recently, eculizumab has been successfully used to manage treatment-resistant MG (7). Complication with MG does not generally worsen the prognosis of the thymoma patients. The tumor diameter in thymoma patients with MG has

Table 1 Autoimmune disorders associated with thymoma

Autoimmune disorders	Treatment
Myasthenia gravis (MG) (including taste disorder)	Acetylcholine esterase inhibitors (pyridostigmine, ambenonium chloride)
	Thymectomy
	Immunosuppression (prednisolone, tacrolimus)
	Treatment of acute exacerbations (plasmapheresis, immunoadsorption, intravenous immunoglobulin)
	Eculizumab
Anemia [aplastic anemia (PRCA); autoimmune hemolytic anemia]	Immunosuppression
	Transfusion
Good's syndrome	Intravenous immunoglobulin
	Antibiotic therapy
Nerve system (limbic encephalitis; Isaac's syndrome; stiff person syndrome; Morvan's syndrome)	Immunosuppression
Myocarditis and polymyositis	Immunosuppression
Thyroid disorders	Immunosuppression
	Hormonal therapy
Autoimmune hepatitis	Immunosuppression
Dermatitis (GVHD-like erythroderma; SLE; lichen planus)	Immunosuppression
	Symptomatic therapy

GVHD, graft-versus-host disease; SLE, systemic lupus erythematosus.

been reported to be relatively small compared with that in thymoma patients without MG.

However, other autoimmune diseases are often complicated in patients with advanced disease or recurrence (8). Despite thymectomy's tendency to improve the symptoms of MG, thymectomy or thymomectomy usually has no marked treatment effect on other autoimmune diseases. Complication with myocarditis and polymyositis often results in a critical state (9). In the advanced stage of thymomas, treatment for recurrent lesions or disseminated lesions is not easy. In addition, treatment for complex autoimmune diseases is often difficult.

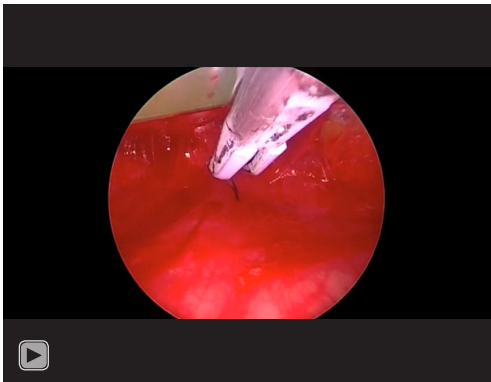
Extended thymectomy for MG associated with thymoma

Thymectomy for early-onset MG without thymoma has been performed for the past several decades, with its efficacy well known but not clearly demonstrated until a recent clinical trial. The efficacy of thymectomy in MG depends on the intensity of lymphoid follicular hyperplasia of the thymus. To increase the efficacy of thymectomy, extended thymectomy including resection of the ectopic thymus was proposed by Prof. Akira Masaoka (10). Extended thymectomy is usually selected for MG patients associated with thymoma as well as early-onset MG patients without thymoma. This is because germinal centers can be found in the thymic tissue surrounding thymomas in younger patients with MG associated with thymoma. Combined resection of surrounding organs showing tumor invasion should of course be added to thymectomy in necessary cases.

Procedures of thoracoscopic extended thymectomy for MG associated with thymoma

Thymectomy has been performed via median sternotomy for many years, and thoracoscopic or mediastinoscopic thymectomy has been recently reported. A subxiphoid approach can also be used, and its usefulness and efficacy have been reported (11). We herein report its procedure (*Video 1*).

Under general anesthesia with the patient in the open-leg or lithotomy position, thymectomy starts. A double-lumen tracheal tube can be selected depending on the necessity of single lung ventilation for the presence of tumor invasion. A 2- to 3-cm transverse skin incision is set 1cm below the lower edge of the xiphoid. We dissect on the reverse side of the xiphoid using a finger and recognize the smooth surface of the sternum. An access platform of single-port surgery (GelPOINT Mini[®], Applied Medical, Rancho Santa Margarita, CA, USA) is then inserted and fixed. A 5-mm thoracoscope angled with 30° is inserted through a port of the access platform. The view is rapidly extended immediately after carbon dioxide insufflation of 8 mmHg. A sealing device (LigaSure Maryland[®], Covidien, Mansfield, MA, USA) is inserted through the second port of the access platform and is mainly used for dissection of the tissues. After opening the right pleura, a thoracic port is inserted at the 5th or 6th intercostal space on the right anterior axillary line. This port is mainly used for the scope to obtain the optimal view. If there is difficulty in securing the view, an additional port at the 5th or 6th intercostal space on the left anterior axillary



Video 1 Thoracoscopic thymectomy for thymoma with myasthenia gravis (12). Wedge resection of the right lung was performed using a stapler initially. Then, the thymic tissue including the pericardial fat was dissected along the running of the phrenic nerve. From the bilateral edges of the thymus the brachiocephalic vein was exposed. The thymic arteries and veins were carefully dissected and cut.

line can be set. Dissection of the thymus is usually started from the right side. In this case, wedge resection of the right lung was performed initially because pulmonary invasion of thymoma was suspicious. A stapler (Endo GIA™, Covidien, Mansfield, MA, USA) was inserted from the subxiphoid port. Then, the thymic tissue is dissected. The milestone of the dissection is the running of the right phrenic nerve. The right and left brachiocephalic veins can be easily exposed following exposure of the superior vena cava. Dissection of the bilateral upper portions of the thymus is key in extended thymectomy. The thymic arteries and veins are then exposed and cut using the sealing device, after which the thymus and surrounding fat tissue can be removed via the subxiphoid incision.

Acknowledgments

Funding: None.

Footnote

Provenance and Peer Review: This article was commissioned by the Guest Editor (Meinoshin Okumura) for the series “Dedicated to the 36th Annual Conference of Japanese Association for Chest Surgery (JACS)” published in *Journal of Visualized Surgery*. The article has undergone external peer review.

Conflicts of Interest: The author has completed the ICMJE

uniform disclosure form (available at <https://jovs.amegroups.com/article/view/10.21037/jovs.2019.10.04/coif>). The series “Dedicated to the 36th Annual Conference of Japanese Association for Chest Surgery (JACS)” was commissioned by the editorial office without any funding or sponsorship. The author has no other conflicts of interest to declare.

Ethical Statement: The author is accountable for all aspects of the work in ensuring that questions related to the accuracy or integrity of any part of the work are appropriately investigated and resolved. Informed consent was obtained from the patient for publication of this manuscript and any accompanying images.

Open Access Statement: This is an Open Access article distributed in accordance with the Creative Commons Attribution-NonCommercial-NoDerivs 4.0 International License (CC BY-NC-ND 4.0), which permits the non-commercial replication and distribution of the article with the strict proviso that no changes or edits are made and the original work is properly cited (including links to both the formal publication through the relevant DOI and the license). See: <https://creativecommons.org/licenses/by-nc-nd/4.0/>.

References

1. Yokoyama T, Tanahashi M, Tateyama H, et al. Flow-cytometric diagnosis of thymoma using needle biopsy specimens. *Surg Today* 2003;33:163-8.
2. Masaoka A, Monden Y, Nakahara K, et al. Follow-up study of thymomas with special reference to their clinical stages. *Cancer* 1981;48:2485-92.
3. Blumberg D, Port JL, Weksler B, et al. Thymoma: a multivariate analysis of factors predicting survival. *Ann Thorac Surg* 1995;60:908-13; discussion 914.
4. Kondo K, Monden Y. Therapy for thymic epithelial tumors: a clinical study of 1,320 patients from Japan. *Ann Thorac Surg* 2003;76:878-84; discussion 884-5.
5. Nakajima J, Okumura M, Yano M, et al. Myasthenia gravis with thymic epithelial tumour: a retrospective analysis of a Japanese database. *Eur J Cardiothorac Surg* 2016;49:1510-5.
6. Fujii Y. Thymus, thymoma and myasthenia gravis. *Surg Today* 2013;43:461-6.
7. Howard JF Jr, Barohn RJ, Cutter GR, et al. A randomized, double-blind, placebo-controlled phase II study of eculizumab in patients with refractory generalized myasthenia gravis. *Muscle Nerve* 2013;48:76-84.

8. Moriyama S, Yano M, Haneda H, et al. Pure red cell aplasia associated with thymoma: a report of a single-center experience. *J Thorac Dis* 2018;10:5066-72.
9. Sasaki H, Yano M, Kawano O, et al. Thymoma associated with fatal myocarditis and polymyositis in a 58-year-old man following treatment with carboplatin and paclitaxel: A case report. *Oncol Lett* 2012;3:300-2.
10. Masaoka A, Monden Y. Comparison of the results of transsternal simple, transcervical simple, and extended thymectomy. *Ann N Y Acad Sci* 1981;377:755-65.
11. Yano M, Moriyama S, Haneda H, et al. Thymectomy using the subxiphoid approach. *J Thorac Cardiovasc Surg* 2016;152:278-9.
12. Yano M. Thoracoscopic thymectomy for thymoma with myasthenia gravis. *Asvide* 2019;6:315. Available online: <http://www.asvide.com/watch/33000>

doi: 10.21037/jovs.2019.10.04

Cite this article as: Yano M. Autoimmune diseases associated with thymoma. *J Vis Surg* 2020;6:6.