

Artificial urinary sphincter and female stress urinary incontinence over the past 50 years: a narrative review

Mariana Madanelo^{1^}, Emmanuel Chartier-Kastler^{2^}, Tamsin Greenwell^{3^}, Gary Gray⁴, Rose Khavari^{5^}, Gommert A. Van Koeveringe^{6^}, Frank Van Der Aa^{7^}, Benoit Peyronnet⁸

¹Department of Urology, Centro Hospitalar Universitário de Santo António, Porto, Portugal; ²Department of Urology, Pitié-Salpêtrière University Hospital, Paris Sorbonne University, Paris, France; ³Department of Urology, University College London Hospital, London, UK; ⁴Department of Urology, University of Alberta, Edmonton, Canada; ⁵Department of Urology, Houston Methodist Hospital, Houston, USA; ⁶Department of Urology, Maastricht University Medical Centre, Maastricht, The Netherlands; ⁷University Hospitals KU Leuven, Leuven, Belgium; ⁸Department of Urology, University of Rennes, Rennes, France

Contributions: (I) Conception and design: M Madanelo, B Peyronnet; (II) Administrative support: All authors; (III) Provision of study materials or patients: All authors; (IV) Collection and assembly of data: All authors; (V) Data analysis and interpretation: All authors; (VI) Manuscript writing: All authors; (VII) Final approval of manuscript: All authors.

Correspondence to: Dr. Benoit Peyronnet. Service d'Urologie, Hopital Pontchaillou, 2 rue Henri Le Guilloux, 35000 Rennes, France; Department of Urology, University of Rennes, Rennes, France. Email: peyronnetbenoit@hotmail.fr.

Background and Objective: The aim of the present report was to provide an overview of the use of the artificial urinary sphincter (AUS) in adult females with stress urinary incontinence (SUI) over the past 50 years.

Methods: A literature search was conducted in December 2022 and January 2023 using the MEDLINE and Embase databases, screening for randomized controlled trials (RCTs), prospective and retrospective series and reviews on AUS. Only articles published in English or French were included. The search strategy involved a free text protocol and the narrative review reporting checklist was completed.

Key Content and Findings: The AUS is a device used over the past 50 years for SUI caused by intrinsic sphincter deficiency (ISD). It has the theoretical ability to simulate the function of a biological urinary sphincter. Although the role of the AUS for females with ISD remains heterogeneous from one part of the world to the other, the existing literature demonstrates that AUS yields satisfactory functional outcomes in female SUI patients, comparable or better to what has been reported in male AUS series. Hence, the main barrier to its adoption has so far been the technical challenge of its implantation at the bladder neck. Regarding the results of AUS implantation in females, we included in this review 3 reviews, retrospective studies and 1 prospective study. In recent years, robotic techniques of female AUS implantation have spread significantly with promising outcomes including numerous reports suggesting that it may decrease its morbidity. In the near future, the development of electromechanical devices may further expand the role of AUS in the management of female SUI.

Conclusions: While the use of AUS in female patients provides excellent functional outcomes, it has been limited to scarce centers. However, due to the rise of minimally invasive approaches, it has started spreading again over the past few years. The future of AUS is likely to be bright, fed by technological advances of the device and robotic surgical system, high level of evidence studies and joint efforts of the urological community to facilitate its diffusion across the world.

[^] ORCID: Mariana Madanelo, 0000-0001-8429-7785; Emmanuel Chartier-Kastler, 0000-0003-4241-8125; Tamsin Greenwell, 0000-0002-9074-7604; Rose Khavari, 0000-0001-6713-1679; Gommert A. Van Koeveringe, 0000-0003-2328-8265; Frank Van der Aa, 0000-0002-4617-3666.

Keywords: Urinary sphincter; artificial; female; robotics

Submitted Jan 28, 2023. Accepted for publication Oct 07, 2023. Published online Nov 08, 2023.

doi: 10.21037/tau-23-58

View this article at: <https://dx.doi.org/10.21037/tau-23-58>

Introduction

Female stress urinary incontinence (SUI) is a public health problem associated with an enormous psychological and social burden (1). According to the 6th International Consultation on Incontinence (ICI), 25–45% have occasional leakage, with national prevalence studies of SUI reporting 9–29.5% in Europe and 23.1% in the US (2).

Two common mechanisms for female SUI have been described: urethral hypermobility and intrinsic sphincter deficiency (ISD) (3). However, these mechanisms may often overlap (3). Although midurethral sling (MUS) placement is considered as the gold standard surgical treatment for female patients with SUI due to urethral hypermobility in most countries, the management of women with SUI related to ISD is less clear (3). Moreover, with the current mesh controversy on SUI surgical treatment, the indication for the artificial urinary sphincter (AUS) may expand (4). The ISD mechanism is mostly seen in female patients in whom previous anti-incontinence surgical procedures failed or patients with neurogenic SUI (3). These patients are most likely not the ideal for MUS, due to the ISD or because they have a fixed urethra, which does not comply with the reestablishment of the vaginal hammock (5). There is still a lack of evidence in the management of recurrent or persistent stress incontinence after a failed MUS (6). Treatment options include injectable urethral bulking agents, insertion of a pubovaginal sling or external urethral compression devices (adjustable continence therapy and AUS) (6).

The AUS was first described 50 years ago (7) and has been used in women since then in several centers. Despite that, the literature on the results of the AUS in women remains scarce. The authors did not find any randomized controlled trial (RCT). Four reviews (4,8–10) were included.

Likely due to the absence of high level of evidence data and its challenging implantation, the AUS is still considered in most countries as a procedure for highly selected patients and not as a first line option. In the mid-1990s, female AUS was not approved by the US Food and Drug Administration (FDA) and from then was almost abandoned by US

urologists (4).

The aim of the present report was to provide a narrative review of the use of the AUS in adult females with SUI over the past 50 years. We present this article in accordance with the Narrative Review reporting checklist (available at <https://tau.amegroups.com/article/view/10.21037/tau-23-58/rc>).

Methods

A literature search was conducted in December 2022 and January 2023 using the MEDLINE and Embase databases, screening for RCTs, prospective and retrospective series and reviews on AUS. The search strategy involved a free text protocol with the following keywords (“artificial urinary sphincter” or “artificial sphincter”) AND (“female” or “women” or “male” or “men”) that were used alone or in combination. Only articles published in English or French and deemed relevant for the present review were included. The French articles were included given the fact that France is the only country whose national guidelines support AUS as a gold-standard treatment in female patients with SUI due to ISD. As a result, the use of AUS in female patients has historically been wider in France than in other countries, with more than 300 implantations per year (11).

Table 1 summarizes the methodology used for the review.

Key content and findings

Objective findings

Regarding the results of AUS implantation in females, we included in this review 4 reviews (4,8–10), retrospective case series (12–25) and 1 prospective case series (26) (*Table 2*). The authors did not find any RCT.

These series included AUS implantation using open abdominal approach, with dry rates ranging from 61% to 86% and explantation rates from 0% to 32%. The laparoscopic and robotic approaches series showed similar dry rates (51–84%) with fewer complications (explantation rates from 0% to 22%) (12–26) (*Table 2*).

Table 1 The search strategy summary

Items	Specification
Date of search	December 2022, January 2023
Databases searched	MEDLINE and Embase databases
Search terms	“artificial urinary sphincter” or “artificial sphincter” AND “female” or “women” or “male” or “men”
Timeframe	No limit
Inclusion criteria	Study types: randomized controlled trials, prospective and retrospective series and reviews Languages: English and French
Selection process	The search and selection of the studies were conducted by two different authors individually, with subsequent discussion and evaluation of the sources

Narrative findings/contents

The origins

Currently, the AUS is predominantly used in male patients with post-prostatectomy incontinence (41). However, the American Medical System (AMS; Minnetonka, MN, USA) AUS was initially designed mostly for women (7). In their initial report in 1973, Scott, Bradley and Timm reported a series of five patients including four women (7). This preceded the rise of radical prostatectomy and the prevalence of male SUI was therefore much lower. During the 1980s and 1990s, a few limited series were published, primarily hailing from North America, yet the adoption of the use of AUS in female patients did not gain substantial traction. Within these series, some described a vaginal approach, which saw a swift abandonment by most surgeons, likely due to unsatisfactory outcomes, although this assertion remains unverified due to the paucity of published data (42). In the mid-1990s, urologists in the United States ceased their pursuit of female AUS employment, largely due to its lack of approval by the US FDA (4). Over the preceding two decades, the use of female AUS has predominantly been observed in Europe, particularly within nations such as France, and in some tertiary referral centers in the United Kingdom, Belgium, Netherlands, Spain, Germany, and Australia (8,9,25).

Female AUS principles

The AUS is a silicone device made of three main pieces: a cuff, a pressure regulating balloon (PRB) and a pump connected with tubing (43). *Figure 1* shows an AMS 800™ AUS. In female patients, the cuff is usually placed around the bladder neck, the pump is placed in the labia majora and the PRB in the abdominal cavity, either intraperitoneal

or extraperitoneal (4). During storage, the cuff is filled with fluid which results in closure of the bladder neck and proximal urethral lumen. To void, the patient has to squeeze the pump located in the labia majora which will move the fluid to the PRB and result in opening of the bladder outlet.

This is a key difference between the AUS and most other anti-incontinence procedures: it has, theoretically, the ability to increase outlet resistance during storage and to maintain low outlet resistance during voiding, thereby mimicking the physiological function of the native striated sphincter (4).

Currently, there are different types of AUS systems available (7).

The AMS 800™ has been the most commonly used AUS device for the last decades. The AMS 800™ consists of a circumferential cuff, a pressure-regulating balloon and a control pump, all connected with tubing (44). This is the only AUS with a large body of evidence published on female patients.

Alternative AUS designs have been introduced in the market since then. The Zephyr ZSI 375 (Zephyr Surgical Implants, Geneva, Switzerland) works by occluding the urethra through hydraulic pressure, similar to the AMS 800™ mechanism. However, it does not have an abdominally implanted reservoir and it consists of only two components pre-connected *a priori*, reducing the operative time and potential abdominal intra-operative complications. The pressure can be increased to improve the patient's continence intra and postoperatively. There are no studies on the Zephyr in female SUI patients (44).

FlowSecure™ (Barloword Scientific Limited, Stone, UK) is another alternative to AMS 800™. This system contains four components: a PRB, a control pump, a

Table 2 Results found in case series of AUS in men and women

Study	Year	Study design	Surgical approach	Number of patients	Mean/median follow up (months)	0 pads/day (%)	≤1 pad/day (%)	Revision (%)	Explantation (%)
Female									
Chung (12)	2010	Retrospective case series	Abdominal open	47	162	71	NR	38	17
Revaux (13)	2011	Retrospective case series	Abdominal open	50	96	68	NR	32	24
Vayleux (14)	2011	Retrospective case series	Abdominal open	215	72	65	74	15	7
Costa (15)	2013	Retrospective case series	Abdominal open	344	115	86	95	NR	13
Phé (16)	2014	Retrospective case series	Abdominal open	34	204	61	88	35	30
Peyronnet (17)	2016	Retrospective case series	Abdominal open	16	28	69	75	13	19
Tricard (18)	2019	Retrospective case series	Abdominal open	63	168	75	NR	46	32
Rouprêt (19)	2010	Retrospective case series	Laparoscopic	12	12	83	91	0	0
Ferreira (20)	2017	Retrospective case series	Laparoscopic	49	38	78	NR	14	8
Bracchitta (21)	2019	Retrospective case series	Laparoscopic	74	45	78	NR	NR	22
Schroeder (22)	2021	Retrospective case series	Laparoscopic	49	48	51	NR	23	18
Fournier (23)	2014	Retrospective case series	Robot-assisted	6	14	83	100	0	0
Peyronnet (24)	2019	Retrospective case series	Robot-assisted	49	19	82	NR	6	2
Chartier-Kastler (25)	2020	Retrospective case series	Robot-assisted	41	19	84	NR	34	NR
Biardeau (26)	2015	Prospective case series	Robot-assisted	9	19	67	78	22	0
Male									
Imamoglu (27)	2005	Randomized controlled trial	Penoscrotal	22	60	81	NR	14	9
Lai (28)	2007	Retrospective case series	NR	218	39	NR	69	22 [†]	22 [†]
Ramsay (29)	2007	Retrospective case series	NR	38	NR	NR	100	13	10
Trigo Rocha (30)	2008	Retrospective case series	Perineal	40	53	50	40	20	2.5
Connor (31)	2008	Retrospective case series	NR	25	74	4	NR	12	16
Aaronson (32)	2008	Retrospective case series	Perineal	18	31	NR	69	38	28
Léon (33)	2015	Retrospective case series	NR	57	180	77	NR	NR	16
Linder (34)	2015	Retrospective case series	Perineal	1,082	49	NR	59	31	NR
Yafi (35)	2017	Retrospective case series	Perineal and penoscrotal	27,096	NR	NR	NR	38	52
Esquinas (36)	2021	Prospective case series	NR	27	35	NR	67	22	15
Nasri (37)	2021	Retrospective case series	Perineal	81	3	48	31	1	2
Deruyver (38)	2022	Retrospective case series	Perineal	263	73	NR	52	25	24
Dupuis ¹ (39)	2022	Retrospective case series	Perineal and penoscrotal	417	21	NR	62	NR	7
Dupuis ² (39)	2022	Retrospective case series	Perineal and penoscrotal	50	17	NR	54	NR	26
Plata (40)	2022	Retrospective case series	Perineal and penoscrotal	215	72	80	NR	5	23

¹, AUS after radical prostatectomy; ², AUS after surgery for benign prostate hypertrophy. [†], did not specify the rates of revision or explantation individually. AUS, artificial urinary sphincter; NR, not reported.

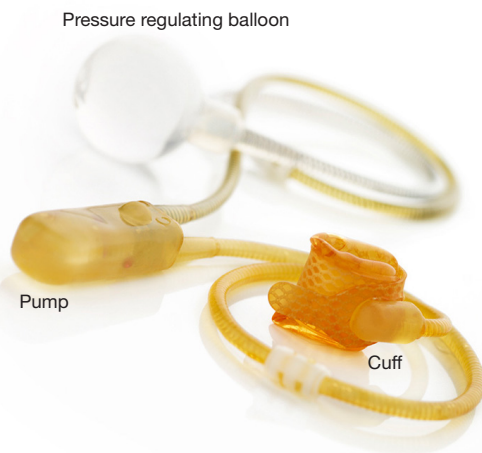

Figure 1 AMS 800™ artificial urinary sphincter.

urethral cuff and a stress release balloon, which is placed extra-peritoneally and has the ability to adapt to changes in the intra-abdominal pressure. This system also allows for pressure adjustment postoperatively without the need for a new surgery, like the Zephyr ZSI 375. The first implantation of the FlowSecure™ in the bladder neck of a female SUI patient with spina bifida showed successful results (44,45).

Table 3 summarizes the features of these three different devices.

Who are the candidates for female AUS?

As mentioned, AUS is almost exclusively used in female patients with SUI predominantly due to ISD (4,8,9). The two main mechanisms of SUI in women may often overlap. AUS is well suited to female SUI cases where ISD is predominant. However, these patients still remain a clinical challenge. The first reason starts in its imprecise clinical definition (3), which may explain the relative heterogeneity of patient populations in the female AUS series. Patients with ISD are known for having lack of urethral mobility. On physical examination, it is perceived by the physician as diminished mobility or fixed urethra during cough stress test or Valsalva test and this has been the cornerstone of female AUS indication (3). A negative Marshall/Bonney test or Pinch/Ulmsten test have been used as adjunct to visual urethral mobility in most French series (15,46).

Although the methods that have been evaluated to standardize the measurement of urethral mobility did not prove superior clinical relevance or prognostic performance compared to physician impression during physical examination, they still may have value as complementary diagnostic tools. These methods include the historical Q-tip test (47), videourodynamics and the perineal ultrasound. While videourodynamics was used by Blaivas to propose a classification of female SUI and an inherent therapeutic algorithm based on the bladder neck mobility during Valsalva on fluoroscopic images, its diagnostic performance

Table 3 Types of AUS systems

AUS system	Year of release	Components	Features
AMS 800	1972	Three components <ul style="list-style-type: none"> • Pressure-regulating balloon • Circumferential cuff • Control pump 	Most used and studied Requires surgery for revision
Zephyr ZSI 375*	2006	Two components: <ul style="list-style-type: none"> • Adjustable circular cuff • Pump with a pressure regulating tank 	Non-surgical pressure adjustment possible Reduced intraoperative time No studies in female patients
FlowSecure	2007	Four components <ul style="list-style-type: none"> • Pressure regulating balloon • Control pump • Urethral cuff • Stress release balloon 	Non-surgical pressure adjustment possible Adapts to changes in intra-abdominal pressure

*, only male studies. AUS, artificial urinary sphincter.

in identifying candidates for AUS implantation have never been evaluated. The perineal ultrasound advantages include its noninvasive character, its availability and the fact that it is relatively easy to perform. Although there is still a lack of data for it to be adopted in routine practice, it appears to be a valuable tool to measure urethral mobility (3,48).

The severity of SUI and the existence of previous anti-incontinence procedures are also clinical features that support the ISD diagnosis (49).

Although urodynamics studies are almost always performed prior to AUS implantation, the value of urethral resistance measurement, either through maximum urethral closure pressure (MUCP) or Valsalva leak point pressure (VLPP), remains largely debated. Thresholds of MUCP <30 cmH₂O and VLPP <60 cmH₂O are usually regarded as reinforcing the clinical suspicion of ISD and increasing the risk of synthetic MUS failure but cannot be regarded as strong arguments to elect AUS as the most appropriate therapeutic option (49,50).

In daily practice, ISD is mostly diagnosed in two populations: women with one or more failed MUS or any other SUI surgery and patients with neurogenic ISD (mostly spina bifida, spinal cord injury and cauda equina syndrome). Because AUS may potentially cause less bladder outlet obstruction than other surgical options traditionally offered to these patients (51), it may be of particular interest in those with detrusor underactivity although this is purely theoretical.

The only formal contraindication to AUS implantation in female patients is the inability to manipulate the pump, either due to abdominal obesity, lack of manual dexterity or cognitive dysfunction. However, AUS implantation in irradiated women has yielded poorer outcomes and should be considered only in very selected patients (4).

Similarities and differences in the use of AUS in male vs. female patients

Currently, the AUS is the gold standard for moderate to severe SUI in males (52,53), while in females it remains controversial (54). Even though the device and mechanisms are the same for both, there are some differences in the technique and in some outcomes.

The cuff is usually placed around the bulbar urethra in men and the bladder neck in women.

The surgical approach is also one of the main differences—it is usually placed by an abdominal approach in women and by a perineal approach in men. AUS efficacy and long-term complications rate reported in the literature

seem similar in men and women.

A systematic review (8) of the performance and safety of AUS in female patients showed continence rates (0 pads) of 61–100%. Regarding complications, the mechanical failure rate was 0–44% and explantation rate was 0–45%. This systematic review included both neurogenic and non-neurogenic cohorts. Another systematic review performed on exclusively non-neurogenic women reported 42–86% zero pad rates with lower explantation rates ranging from 2–27% (10).

A systematic review (53) reporting the results for men described a 0 pads rate of 4–86%, mechanical failure rate of 2–41% and reintervention rate of 14–44%.

Table 2 summarizes the results found in the studies of case series of the AUS in men and women.

In 2006, Petero *et al.* reported a head-to-head single center retrospective comparison of male vs. female AUS. In this series of 108 patients, they observed better functional outcomes for female AUS patients with 64% of female AUS patients being completely dry vs. 9% of male AUS patients (P=0.01). The median device survival was also longer in female patients (11.2 vs. 6.9 years, P=0.002) (55). More recently, a study compared the long-term overall survival of the device, defined as the absence of any repeated surgery (revision or explantation) between men and women. They found good AUS survival in women, with significantly lower explantation or revision rate in women at midterm (6 months to 8 years) (56).

There are some possible factors that could explain the good results in women. The size and the site of implantation of the cuff in women are two of them. The increased thickness of the bladder neck wall compared to the bulbar urethral wall may decrease the risk of atrophy and cuff erosion. Moreover, the bladder neck may be more protected from possible trauma than the bulbous urethra (56).

Finally, another difference may be the increased rate of female patients having difficulties to manipulate the pump in the labia majora which may be up to 14.9% of patients in some series (9).

Surgical approach

The theoretical technical complexity of AUS implantation lies in the placement of the cuff around the bladder neck owing to its location deep in the bony pelvis and the subtle dissection needed to find and follow the surgical plane between the bladder neck and the vaginal wall.

The vaginal approach was used in the 1980s but has long been abandoned for over three decades by most teams

likely due to high rates of device infections/exposure (8). Hence the open abdominal approach has since become the standard. While several high-volume implanting teams have reported satisfactory outcomes with open AUS implantation (8,14,15), this continues to be seen as a technically demanding procedure.

With the rise of minimally invasive surgery in urology in the 2000s, a few surgical teams started to develop laparoscopic techniques for AUS implantation with the following rationale: the pneumoperitoneum may decrease bleeding from vaginal wall veins which often hamper proper vision during the bladder neck dissection; videoscscopy may allow direct visualization during the dissection of the posterior aspect of the bladder neck; the overall better vision may decrease the risk of bladder neck/vaginal injury and the overall morbidity of the procedures and risk of device-related complications might be reduced (19,57).

The first series by Mandron (n=25 patients) and Roupret (n=12 patients) reported promising results with zero and one intraoperative complication respectively and 0% and 8% rate of explantation/erosion after median follow-up of 12 and 26 months, respectively (19,57). These encouraging findings were recently confirmed by two larger series with longer follow-up. Ferreira *et al.* (20) analyzed 49 patients after a median follow-up of 24 months, with rates of 77.6% of total continence (0 pads), 22% of revision and 8% of explantation. Schroeder *et al.* (22) analyzed 49 patients after a median follow-up of 4 years with a 14.3% rate of explantation and 83.6% of patients being socially continent at last follow-up.

On the basis of these promising laparoscopic experiences, several teams started to use a robotic approach in the early 2010s (17,23-26), with even fewer complications and offering more comfort to the surgeon. In the largest series published so far, Peyronnet *et al.* reported 49 cases across five centers with 85.7% having a history of previous anti-incontinence surgery and only one explantation (2%) with 81.6% of patients fully continent after a median follow-up of 18.5 months (25).

In the open approach, the dissection of the Retzius space is done until the endopelvic fascia is identified. Tension is created with the placement of one finger of the assistant surgeon in the vagina and the vesicovaginal plane is identified, dissecting on the tip of the finger with cold scissors. The posterior part of the bladder neck is dissected on both sides and the spaces are joined together to place the measuring tape all around the bladder neck. The cuff and the balloon are then inserted and the pump is placed

in the labia majora creating a subcutaneous space from the abdominal incision (4).

For the procedure employing robot-assisted approach, the patient assumes a Trendelenburg position tilted at an angle of 23 degrees. The technique is executed through a transperitoneal approach employing a 0-degree lens. The placement of ports involves positioning five ports: a 12-mm port for the camera at the umbilicus, along with three 8-mm robotic ports (one located on the right flank and the other two positioned at the lateral boundary of the right and left rectus abdominis muscles), in addition to an extra 12-mm port on the left flank designated for the assistant's role (8).

Most of the robotic female AUS series published so far used an "anterior" approach mimicking what was done in the historical open technique with an initial opening of the Retzius space to dissect the bladder neck "from above". A handful of teams have recently reported an alternative "posterior" robotic technique with dissection of the bladder neck being carried out "from below" which involves a dissection of the vesicovaginal space from the vaginal fornix to the posterior aspect of the bladder neck prior to reach the anterior aspect on each side (26,58). The outcomes reported were broadly similar with those of the anterior technique (58-60).

Figure 2 and *Figure 3* show two steps in a robot-assisted AUS implantation in a female patient: the dissection of the posterior aspect of the bladder neck and the position of the cuff and the PRB.

Female AUS outcomes in the literature

In 1996, at the American Urological Association (AUA) Annual Meeting, Richard *et al.* presented a series of 89 implanted AUS in female patients, from 1984 to 1995, with a mean follow-up of 50 months. There was an explantation rate of 17% and 88% of women were fully continent (60).

A systematic review of the literature published in 2019 (8) included 17 studies. Prospective comparative studies were not included, and most series reported open implantation (12/17). The vast majority of patients had undergone at least one anti-incontinence surgical procedure prior to AUS implantation (69.1–100%). The 61–70 cmH₂O PRB was the most commonly used, with the 51–60 and 71–80 cmH₂O being favored in two and one open series respectively. The median cuff size ranged from 60 to 80 mm. With mean follow-up from 5 to 204 months, the complete, social and improved continence rates ranged from 61.1% to 100%, from 71% to 100% and from 81.3% to 100%, respectively (8).

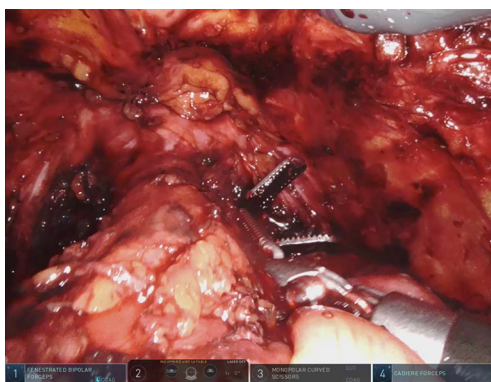

Figure 2 Robot-assisted AUS implantation in a female patient. Dissection of the posterior aspect of the bladder neck. AUS, artificial urinary sphincter.

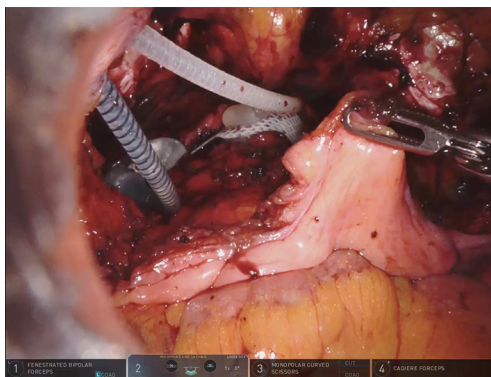


Figure 3 Robot-assisted AUS implantation in a female patient. Position of the cuff and the pressure regulating balloon. AUS, artificial urinary sphincter.

Costa *et al.* published the largest long-term analysis (15). They reported an open approach and included 376 AUS implanted in 344 women over a 20-year period. In the second largest series, Vayleux *et al.* reported an analysis of 215 women undergoing open AUS implantation over a 22-year period: 88% of women had undergone previous treatment for incontinence and the rate of continence (0 to 1 pad use) was 73.5% (14).

Overall, these results suggest that AUS yields satisfactory functional outcomes in female SUI patients and, as mentioned, comparable or better to what has been reported in male AUS series.

The morbidity of female AUS has long raised concerns and may have contributed to limit its use in some centers. In the aforementioned systematic review (8), the intraoperative

bladder neck injury rate ranged from 0% to 43.8% and the intraoperative vaginal injury rates ranged from 0% to 25%, respectively. The postoperative complications rates varied widely with the different approaches and ranged from 16.7% to 33.3% in robotic series and from 4.1% to 75% in open series (8).

In open cohorts, the explantation rate ranged from 0% to 45.3%, the extrusion/exposure from 0% to 14.3% and the mechanical failure from 0% to 44.1%, after mean follow-ups from 28.1 to 204 months. In laparoscopic series, the rates of explantation and extrusion/exposure varied from 0% to 8.1% and mechanical failure rate ranged from 0% to 12.2%, after mean follow-up periods of 12.1 and 37.5 months. In robotic cohorts (mean follow-up 5 to 18.9 months), the explantation and extrusion/exposure rates varied from 0% to 22.2%, with no reported mechanical failures (8). Interestingly, the two largest series reported the lowest rates of device explantation (7% and 12.8%) and mechanical failures (13.6% and 15.5%) (14,15).

In the Costa study (15), the 3-, 5- and 10-year device survival rates by Kaplan-Meier analysis were 92%, 88.6% and 69.2%. The mean mechanical survival time was 176 months (14.7 years).

The factors identified by the authors to be associated with the AUS survival included the number of previous incontinent procedures, the presence of associated neurogenic disease, and simultaneous augmentation procedure.

A systematic review (10) including only non-neurogenic patients reported 42–86% zero pad rates with lower explantation rates ranging from 2–27%.

These promising results in many published series may contribute to the further spread of AUS implantation in women.

Current role of female AUS according to national and international guidelines

According to the European Association of Urology guidelines, AUS should be implanted only as a procedure for complicated SUI in women and only in expert centers. Also, the patients should be informed of the high risk of complications; mechanical failure or need for explantation (level of evidence 3, grade of recommendations: weak) (61). The ICI of the International Continence Society (ICS) recommends that AUS should be limited only to highly selected individuals usually with recurrent SUI and only with appropriate counseling regarding the likely need for revision over time and the lack of long-term RCT data

Table 4 Recommendations on the use of AUS in female patients

Association	Recommendation
European Association of Urology (29)	Inform women receiving AUS device that, although cure is possible, even in expert centres, there is a high risk of complications, mechanical failure or a need for explantation (strong recommendation) Consider secondary synthetic sling, bulking agents, colposuspension, autologous sling or AUS as options for women with complicated SUI (weak recommendation)
American Urology Association (31)	Not mentioned
National Institute for Health and Care Excellence (30)	Do not offer women an artificial urinary sphincter to manage stress urinary incontinence unless previous surgery has failed
International Continence Society (2)	AUS for female SUI should be limited only to highly selected individuals usually with recurrent SUI and only with appropriate counseling regarding the likely need for revision over time and the lack of long-term RCT data (grade C)
French Urologic Association (21)	First-line AUS may have its place in case of ISD due to its good long-term clinical results and reduced morbidity compared to the implantation of an AUS as a second procedure. However, the patient must be fully informed and physically and intellectually able to use this implant
Canadian Urological Association (32)	When intrinsic urethral deficiency is the primary cause, treatment options include bulking agents (grade B), bladder neck slings (grade A)/retropubic MUS and artificial urinary sphincter (grade B)

AUS, artificial urinary sphincter; SUI, stress urinary incontinence; RCT, randomized controlled trial; ISD, intrinsic sphincter deficiency.

(Grade C recommendation) (2). The National Institute for Health and Care Excellence (NICE) guidelines recommend AUS as an option to manage female SUI only if previous surgery was unsuccessful (62). Because AUS in female patients is not approved by the FDA, it is not mentioned as an option in the AUA guidelines on SUI (63). The Canadian Urological Association include the AUS as a treatment option for ISD (grade of recommendation B) (64). In contrast with all these international guidelines, the French national guidelines recommend AUS as first-line treatment in case of SUI caused by ISD due to its good long-term clinical results and reduced morbidity compared to the implantation of an AUS after multiple previous procedures (23). *Table 4* summarizes these guidelines.

The results published so far and the future evidence from trials which are underway may contribute to provide stronger recommendations in guidelines in the near future.

Future perspectives

AUS is the only mechanical device that can simulate the function of a biological urinary sphincter by opening and closing the urethra during storage and voiding. Even though it has proven its safety and efficacy, AUS has a few limitations. One of the most important limitations is the need to activate the pump to void. Up to 14.9% of female

patients with AUS fail to manipulate the pump (9).

A handful of electromechanical artificial sphincters have been developed over the past decade (65-67). The electromechanical AUS may be remotely controlled, avoiding the labia majora pump, and they may allow adjustment of the pressure on the urethra, hypothetically reducing the risk of erosion and revision due to damage to the bladder neck tissue. Several teams and industry partners are currently working on electromechanical AUS prototypes. Recently, in November 2022, the French medical technology company UroMems announced the implantation of UroActive™ System in a male patient, at La Pitié-Salpêtrière University Hospital in Paris, France, as part of an initial clinical trial and with approval from the National Agency for the Safety of Medicines and Health Products (or ANSM, the French equivalent to the FDA). UroActive™ is the first smart active AUS to be powered by a Myoelectromechanical System. This innovative system is designed to automatically control the sphincter pressure based on the patient's activity, without the need for manual adjustments (68).

The technological advances that have been surging in the robotic surgery, such as the Da Vinci single port platform with its improved ergonomics, may also facilitate AUS implantation, increasing its popularity (69).

The new robotic devices such as HUGO™ RAS System from Medtronic (Dublin, Ireland), Versius® from CMR Surgical (Cambridge, UK) and Hinotori from Kawasaki (Tokyo, Japan), which are invested with freedom of port placement and flexibility, may represent a possible advantage in pelvic surgery and will certainly contribute to the expansion of robotic surgery worldwide, facilitating access to robotic platforms for functional urology procedures such as female AUS implantations (70-72).

The main weakness of female AUS is the lack of high level of evidence studies on its use, which should be overcome in upcoming years. There are two large prospective studies currently ongoing and recruiting: 1. the SUACT trial (clinicaltrials.gov identifier: NCT02490917), which is an RCT comparing adjustable continence therapy periurethral balloons to AUS in female patients with SUI due to ISD and 2. the VENUS study (clinicaltrials.gov identifier: NCT04114266), a prospective cohort study on female AUS involving 30 centers throughout Europe and conducted by the EAU Research Foundation.

Conclusions

Although the utilization of AUS in female patients yields favorable functional results, boasts an extensive historical background, and harbors the distinctive potential to reinstate both typical storage and voiding functions, its application has remained confined to a limited number of institutions for a considerable duration. Nonetheless, it has experienced a resurgence in recent years owing to the controversy surrounding mesh procedures and the ascent of less invasive methodologies that facilitate its integration, acquisition of skills, and are generating encouraging outcomes. Ongoing high-tier empirical research, coupled with advancements in the device's technology and robotic surgical systems, might very well, five decades after its inception, propel the AUS into a pivotal role within the arsenal of treatments for female SUI.

Acknowledgments

Funding: None.

Footnote

Provenance and Peer Review: This article was commissioned by the Guest Editor (Eric Chung) for the series “50 Years Anniversary of the Modern Artificial Urinary Sphincter”

published in *Translational Andrology and Urology*. The article has undergone external peer review.

Reporting Checklist: The authors have completed the Narrative Review reporting checklist. Available at <https://tau.amegroups.com/article/view/10.21037/tau-23-58/rc>

Peer Review File: Available at <https://tau.amegroups.com/article/view/10.21037/tau-23-58/prf>

Conflicts of Interest: All authors have completed the ICMJE uniform disclosure form (available at <https://tau.amegroups.com/article/view/10.21037/tau-23-58/coif>). The series “50 Years Anniversary of the Modern Artificial Urinary Sphincter” was commissioned by the editorial office without any funding or sponsorship. ECK, TG, RK, GAVK, FVDA and BP are consultants for Boston Scientific. BP is also a consultant for Intuitive Surgical, Medtronic, and IBSA and has received speakers' fees from Pierre Fabre, Abbvie, and IPSEN. GAVK has received payment for expert testimony from Solace Therapeutics. The authors have no other conflicts of interest to declare.

Ethical Statement: The authors are accountable for all aspects of the work in ensuring that questions related to the accuracy or integrity of any part of the work are appropriately investigated and resolved. Written informed consent was obtained from the patients for the publication of this study and accompanying images. A copy of the written consent is available for review by the editorial office of this journal.

Open Access Statement: This is an Open Access article distributed in accordance with the Creative Commons Attribution-NonCommercial-NoDerivs 4.0 International License (CC BY-NC-ND 4.0), which permits the non-commercial replication and distribution of the article with the strict proviso that no changes or edits are made and the original work is properly cited (including links to both the formal publication through the relevant DOI and the license). See: <https://creativecommons.org/licenses/by-nc-nd/4.0/>.

References

1. Gil KM, Somerville AM, Cichowski S, et al. Distress and quality of life characteristics associated with seeking surgical treatment for stress urinary incontinence. *Health Qual Life Outcomes* 2009;7:8.

2. Abrams P, Cardozo L, Wagg A, et al. editors. International Continence Society : 6th International Consultation on Incontinence. 2016. Available online: https://www.ics.org/publications/ici_6/Incontinence_6th_Edition_2017_eBook_v2.pdf
3. Osman NI, Li Marzi V, Cornu JN, et al. Evaluation and Classification of Stress Urinary Incontinence: Current Concepts and Future Directions. *Eur Urol Focus* 2016;2:238-44.
4. Peyronnet B, Greenwell T, Gray G, et al. Current Use of the Artificial Urinary Sphincter in Adult Females. *Curr Urol Rep* 2020;21:53.
5. Heesakkers J. Are Slings Still the Gold Standard for Female Stress Urinary Incontinence? *Eur Urol Focus* 2019;5:312-4.
6. Bakali E, Johnson E, Buckley BS, et al. Interventions for treating recurrent stress urinary incontinence after failed minimally invasive synthetic midurethral tape surgery in women. *Cochrane Database Syst Rev* 2019;9:CD009407.
7. Scott FB, Bradley WE, Timm GW. Treatment of urinary incontinence by implantable prosthetic sphincter. *Urology* 1973;1:252-9.
8. Peyronnet B, O'Connor E, Khavari R, et al. AMS-800 Artificial urinary sphincter in female patients with stress urinary incontinence: A systematic review. *NeuroUrol Urodyn* 2019;38 Suppl 4:S28-41.
9. Chartier-Kastler E, Van Kerrebroeck P, Ollianas R, et al. Artificial urinary sphincter (AMS 800) implantation for women with intrinsic sphincter deficiency: a technique for insiders? *BJU Int* 2011;107:1618-26.
10. Reus CR, Phé V, Dechartres A, et al. Performance and Safety of the Artificial Urinary Sphincter (AMS 800) for Non-neurogenic Women with Urinary Incontinence Secondary to Intrinsic Sphincter Deficiency: A Systematic Review. *Eur Urol Focus* 2020;6:327-38.
11. Peyronnet B, Hascoet J, Scailteux LM, et al. The Changing Face of Artificial Urinary Sphincter Use in France: The Future is Female. *Eur Urol Focus* 2020;6:1248-50.
12. Chung E, Cartmill RA. 25-year experience in the outcome of artificial urinary sphincter in the treatment of female urinary incontinence. *BJU Int* 2010;106:1664-7.
13. Revaux A, Rouprêt M, Seringe E, et al. Is the implantation of an artificial urinary sphincter with a large cuff in women with severe urinary incontinence associated with worse perioperative complications and functional outcomes than usual? *Int Urogynecol J* 2011;22:1319-24.
14. Vayleux B, Rigaud J, Luyckx F, et al. Female urinary incontinence and artificial urinary sphincter: study of efficacy and risk factors for failure and complications. *Eur Urol* 2011;59:1048-53.
15. Costa P, Poinas G, Ben Naoum K, et al. Long-term results of artificial urinary sphincter for women with type III stress urinary incontinence. *Eur Urol* 2013;63:753-8.
16. Phé V, Benadiba S, Rouprêt M, et al. Long-term functional outcomes after artificial urinary sphincter implantation in women with stress urinary incontinence. *BJU Int* 2014;113:961-7.
17. Peyronnet B, Vincendeau S, Tondut L, et al. Artificial urinary sphincter implantation in women with stress urinary incontinence: preliminary comparison of robot-assisted and open approaches. *Int Urogynecol J* 2016;27:475-81.
18. Tricard T, Jochum F, Bergerat S, et al. Outcomes of open artificial urinary sphincter in women with stress urinary incontinence: long-term follow up. *Ther Adv Urol* 2019;11:1756287219874676.
19. Rouprêt M, Misraï V, Vaessen C, et al. Laparoscopic approach for artificial urinary sphincter implantation in women with intrinsic sphincter deficiency incontinence: a single-centre preliminary experience. *Eur Urol* 2010;57:499-504.
20. Ferreira C, Brychaert PE, Menard J, et al. Laparoscopic implantation of artificial urinary sphincter in women with intrinsic sphincter deficiency: Mid-term outcomes. *Int J Urol* 2017;24:308-13.
21. Bracchitta D, Costa P, Borojeni S, et al. Laparoscopic artificial urinary sphincter implantation in women with stress urinary incontinence: update on 13 years' experience in a single centre. *BJU Int* 2019;123:E14-9.
22. Schroeder A, Munier P, Saussine C, et al. Outcomes of laparoscopic artificial urinary sphincter in women with stress urinary incontinence: mid-term evaluation. *World J Urol* 2021;39:3057-62.
23. Fournier G, Callerot P, Thoulouzan M, et al. Robotic-assisted laparoscopic implantation of artificial urinary sphincter in women with intrinsic sphincter deficiency incontinence: initial results. *Urology* 2014;84:1094-8.
24. Peyronnet B, Capon G, Belas O, et al. Robot-assisted AMS-800 Artificial Urinary Sphincter Bladder Neck Implantation in Female Patients with Stress Urinary Incontinence. *Eur Urol* 2019;75:169-75.
25. Chartier-Kastler E, Vaessen C, Rouprêt M, et al. Robot-assisted laparoscopic artificial urinary sphincter insertion in women with stress urinary incontinence: a pilot single-centre study. *BJU Int* 2020;126:722-30.
26. Biardeau X, Rizk J, Marcelli F, et al. Robot-assisted

- laparoscopic approach for artificial urinary sphincter implantation in 11 women with urinary stress incontinence: surgical technique and initial experience. *Eur Urol* 2015;67:937-42.
27. Imamoglu MA, Tuygun C, Bakirtas H, et al. The comparison of artificial urinary sphincter implantation and endourethral macropastique injection for the treatment of postprostatectomy incontinence. *Eur Urol* 2005;47:209-13.
 28. Lai HH, Hsu EI, Teh BS, et al. 13 years of experience with artificial urinary sphincter implantation at Baylor College of Medicine. *J Urol* 2007;177:1021-5.
 29. Ramsay AK, Granitsiotis P, Conn IG. The use of the artificial urinary sphincter in the West of Scotland: a single centre 10-year experience. *Scott Med J* 2007;52:14-7.
 30. Trigo Rocha F, Gomes CM, Mitre AI, et al. A prospective study evaluating the efficacy of the artificial sphincter AMS 800 for the treatment of postradical prostatectomy urinary incontinence and the correlation between preoperative urodynamic and surgical outcomes. *Urology* 2008;71:85-9.
 31. O'Connor RC, Lyon MB, Guralnick ML, et al. Long-term follow-up of single versus double cuff artificial urinary sphincter insertion for the treatment of severe postprostatectomy stress urinary incontinence. *Urology* 2008;71:90-3.
 32. Aaronson DS, Elliott SP, McAninch JW. Transcorporal artificial urinary sphincter placement for incontinence in high-risk patients after treatment of prostate cancer. *Urology* 2008;72:825-7.
 33. Léon P, Chartier-Kastler E, Rouprêt M, et al. Long-term functional outcomes after artificial urinary sphincter implantation in men with stress urinary incontinence. *BJU Int* 2015;115:951-7.
 34. Linder BJ, Rivera ME, Ziegelmann MJ, et al. Long-term Outcomes Following Artificial Urinary Sphincter Placement: An Analysis of 1082 Cases at Mayo Clinic. *Urology* 2015;86:602-7.
 35. Yafi FA, DeLay KJ, Stewart C, et al. Device Survival after Primary Implantation of an Artificial Urinary Sphincter for Male Stress Urinary Incontinence. *J Urol* 2017;197:759-65.
 36. Esquinas C, Ruiz S, de Sancha E, et al. Outcomes of a Series of Patients with Post-Prostatectomy Incontinence Treated with an Adjustable Transobturator Male System or Artificial Urinary Sphincter. *Adv Ther* 2021;38:678-90.
 37. Nasri J, Beraud F, Seguiet D, et al. Artificial urinary sphincter implantation in non-neurogenic men: a place for out-patient surgery. *World J Urol* 2021;39:3541-7.
 38. Deruyver Y, Schillebeeckx C, Beels E, et al. Long-term outcomes and patient satisfaction after artificial urinary sphincter implantation. *World J Urol* 2022;40:497-503.
 39. Dupuis HGA, Bentellis I, El-Akri M, et al. Early Efficacy and Safety Outcomes of Artificial Urinary Sphincter for Stress Urinary Incontinence Following Radical Prostatectomy or Benign Prostatic Obstruction Surgery: Results of a Large Multicentric Study. *Eur Urol Focus* 2022;8:1053-9.
 40. Plata M, Zuluaga L, Santander J, et al. Performance of the artificial urinary sphincter implantation in men with urinary incontinence: Results from a contemporary long-term real-world nationwide analysis. *Neurourol Urodyn* 2022;41:1573-81.
 41. Lee R, Te AE, Kaplan SA, et al. Temporal trends in adoption of and indications for the artificial urinary sphincter. *J Urol* 2009;181:2622-7.
 42. Appell RA. Techniques and results in the implantation of the artificial urinary sphincter in women with type III stress urinary incontinence by a vaginal approach. *NeuroUrol Urodyn* 1988;7:613-9.
 43. Marziale L, Lucarini G, Mazzocchi T, et al. Artificial Sphincters to Manage Urinary Incontinence: A Review. *Artif Organs* 2018;42:E215-33.
 44. Al Adem KM, Bawazir SS, Hassen WA, et al. Implantable Systems for Stress Urinary Incontinence. *Ann Biomed Eng* 2017;45:2717-32.
 45. García-Montes F, Vicens-Vicens A, Ozonas-Moragues M, et al. Surgical implantation of the new FlowSecure artificial urinary sphincter in the female bladder neck. *Urol Int* 2007;79:105-10.
 46. Petros PE, Ulmsten UI. An integral theory of female urinary incontinence. Experimental and clinical considerations. *Acta Obstet Gynecol Scand Suppl* 1990;153:7-31.
 47. Karram MM, Bhatia NN. The Q-tip test: standardization of the technique and its interpretation in women with urinary incontinence. *Obstet Gynecol* 1988;71:807-11.
 48. Chen Y, Peng L, Liu M, et al. Diagnostic value of transperineal ultrasound in patients with stress urinary incontinence (SUI): a systematic review and meta-analysis. *World J Urol* 2023;41:687-93.
 49. Cour F, Le Normand L, Lapray JF, et al. Intrinsic sphincter deficiency and female urinary incontinence. *Prog Urol* 2015;25:437-54.
 50. Hillary CJ, Osman N, Chapple C. Considerations in the modern management of stress urinary incontinence resulting from intrinsic sphincter deficiency. *World J Urol*

- 2015;33:1251-6.
51. Kraus SR, Lemack GE, Richter HE, et al. Changes in urodynamic measures two years after Burch colposuspension or autologous sling surgery. *Urology* 2011;78:1263-8.
 52. Sandhu JS, Breyer B, Comiter C, et al. Incontinence after Prostate Treatment: AUA/SUFU Guideline. *J Urol* 2019;202:369-78.
 53. Van der Aa F, Drake MJ, Kasyan GR, et al. The artificial urinary sphincter after a quarter of a century: a critical systematic review of its use in male non-neurogenic incontinence. *Eur Urol* 2013;63:681-9.
 54. Sussman RD, Syan R, Brucker BM. Guideline of guidelines: urinary incontinence in women. *BJU Int* 2020;125:638-55.
 55. Petero VG Jr, Diokno AC. Comparison of the long-term outcomes between incontinent men and women treated with artificial urinary sphincter. *J Urol* 2006;175:605-9.
 56. Cotte J, Dechartres A, Mozer P, et al. Long-term device survival after a first implantation of AMS800™ for stress urinary incontinence: Comparison between men and women. *Neurourol Urodyn* 2023;42:80-9.
 57. Mandron E, Bryckaert PE, Papatsoris AG. Laparoscopic artificial urinary sphincter implantation for female genuine stress urinary incontinence: technique and 4-year experience in 25 patients. *BJU Int* 2010;106:1194-8; discussion 1198.
 58. Gondran-Tellier B, Boissier R, Baboudjian M, et al. Robot-assisted implantation of an artificial urinary sphincter, the AMS-800, via a posterior approach to the bladder neck in women with intrinsic sphincter deficiency. *BJU Int* 2019;124:1077-80.
 59. Broudeur L, Loubersac T, Le Normand L, et al. New technique of robot-assisted laparoscopic artificial urinary sphincter implantation in female by a posterior approach with intraoperative cystoscopic monitoring. *World J Urol* 2021;39:4221-6.
 60. Richard F, Lefort JM, Bitker MO, et al. Female incontinence with primary sphincter deficiency: results of artificial urinary sphincter (AMS 800) with long-term follow-up. *J Urol* 1996;155:1568.
 61. EAU guidelines 2022 on management of non-neurogenic female LUTS. Available online: <https://uroweb.org/guidelines/non-neurogenic-female-luts>
 62. NICE Guidance - Urinary incontinence and pelvic organ prolapse in women: management: © NICE (2019) Urinary incontinence and pelvic organ prolapse in women: management. *BJU Int* 2019;123:777-803.
 63. Kobashi KC, Albo ME, Dmochowski RR, et al. Surgical Treatment of Female Stress Urinary Incontinence: AUA/SUFU Guideline. *J Urol* 2017;198:875-83.
 64. Bettez M, Tu le M, Carlson K, et al. 2012 update: guidelines for adult urinary incontinence collaborative consensus document for the canadian urological association. *Can Urol Assoc J* 2012;6:354-63.
 65. Valerio M, Jichlinski P, Dahlem R, et al. Experimental evaluation of an electromechanical artificial urinary sphincter in an animal model. *BJU Int* 2013;112:E337-43.
 66. Biardeau X, Hached S, Loutochin O, et al. Montreal electronic artificial urinary sphincters: Our futuristic alternatives to the AMS800™. *Can Urol Assoc J* 2017;11:E396-404.
 67. Ludwig TA, Reiss P, Wieland M, et al. The ARTUS device: the first feasibility study in human cadavers. *Can J Urol* 2015;22:8100-4.
 68. Breakthrough Solution: UroActive™ Therapy. Available online: <https://www.uromems.com/en/therapy>
 69. Gettman M, Rivera M. Innovations in robotic surgery. *Curr Opin Urol* 2016;26:271-6.
 70. Gueli Alletti S, Chiantera V, Arcuri G, et al. Introducing the New Surgical Robot HUGO™ RAS: System Description and Docking Settings for Gynecological Surgery. *Front Oncol* 2022;12:898060.
 71. Alkatout I, Salehiniya H, Allahqoli L. Assessment of the Versius Robotic Surgical System in Minimal Access Surgery: A Systematic Review. *J Clin Med* 2022;11:3754.
 72. Hinata N, Yamaguchi R, Kusuhara Y, et al. Hinotori Surgical Robot System, a novel robot-assisted surgical platform: Preclinical and clinical evaluation. *Int J Urol* 2022;29:1213-20.

Cite this article as: Madanelo M, Chartier-Kastler E, Greenwell T, Gray G, Khavari R, Van Koevinge GA, Van Der Aa F, Peyronnet B. Artificial urinary sphincter and female stress urinary incontinence over the past 50 years: a narrative review. *Transl Androl Urol* 2023. doi: 10.21037/tau-23-58