

# Combined HawkOne directional atherectomy and paclitaxel-coated balloon angioplasty for isolated calcified popliteal artery lesion: a no-stent approach to lower extremity endovascular revascularization

Romarc Loffroy, Olivier Chevallier, Nicolas Falvo, Sophie Gehin, Marco Midulla, Christophe Galland

Department of Vascular Medicine and Interventional Radiology, Center of Mini-Invasive Image-Guided Therapies, François-Mitterrand University Hospital, Dijon, France

*Correspondence to:* Prof. Romarc Loffroy, MD, PhD. Department of Vascular Medicine and Interventional Radiology, Center of Mini-Invasive Image-Guided Therapies, François-Mitterrand University Hospital, 14 Rue Paul Gaffarel, BP 77908, 21079 Dijon Cedex, France. Email: romarc.loffroy@chu-dijon.fr.

Submitted Dec 30, 2017. Accepted for publication Mar 23, 2018.

doi: 10.21037/qims.2018.03.10

View this article at: <http://dx.doi.org/10.21037/qims.2018.03.10>

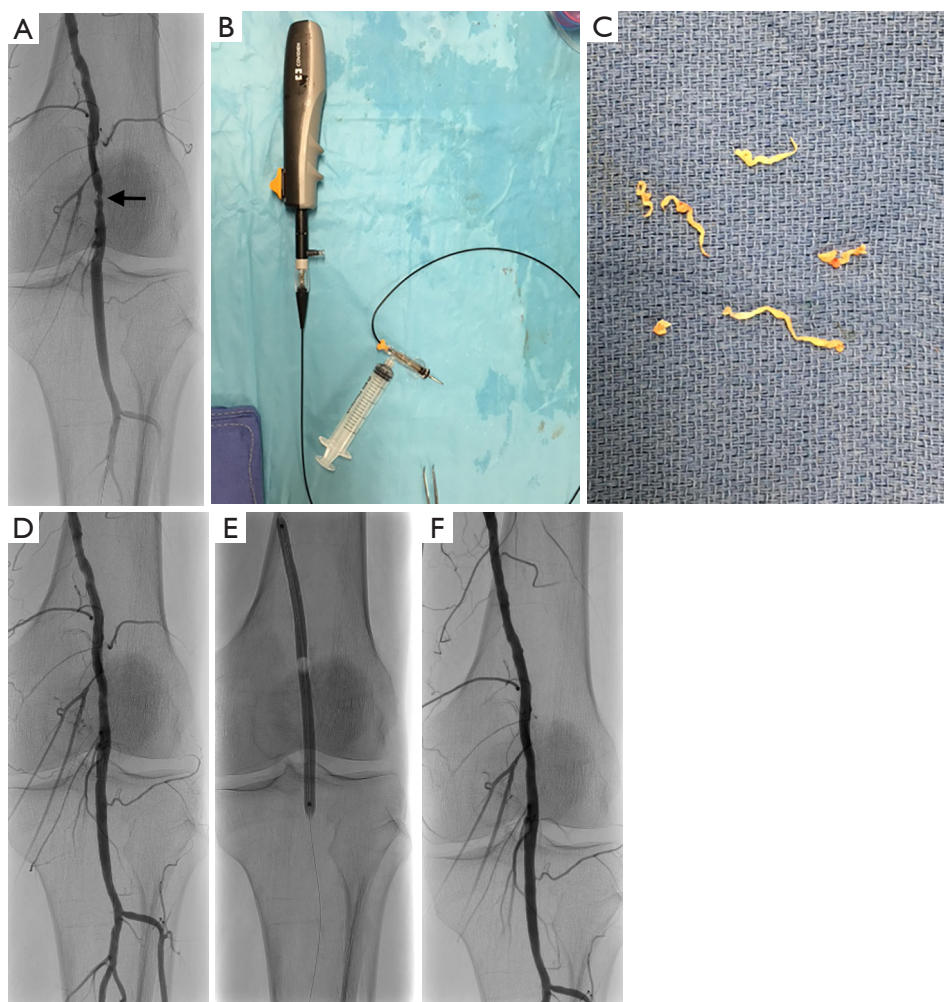
## Introduction

Restenosis rate after percutaneous transluminal angioplasty (PTA) of isolated calcified popliteal artery lesion makes this endovascular procedure still debated. Indeed, the presence of severe calcification of the atherosclerotic target lesion is responsible for a poor response to balloon dilation, due to significant acute vessel recoil and frequent dissection, limiting technical success rate and long-term patency (1-3). Directional atherectomy (DA) may be an alternative treatment modality that can improve procedural success by debulking fibrocalcific portion of the plaque, but provides benefits in terms of patency rate only when combined with angioplasty (3,4). The use of drug-coated balloons (DCB) for endovascular treatment of the popliteal artery has been demonstrated to reduce the rate of restenosis (4,5). However, no data exist regarding the use of DCB in heavy calcified lesions. In this case, we applied a new endovascular approach for the treatment of isolated calcified popliteal artery lesion, combining DA using the new generation of HawkOne catheter with paclitaxel-coated balloon angioplasty, to prevent long-term restenosis and to avoid the need of stenting.

## Case presentation

A 69-year-old man was referred to our interventional

radiology department to perform endovascular treatment of isolated calcified left popliteal artery lesion after the occurrence of disabling claudication. He had no other medical history. The patient underwent digital ambulatory subtraction angiography (DSA) under local anesthesia. Antegrade vascular access was performed via left ipsilateral common femoral artery through a short 7-Fr sheath (Terumo, Tokyo, Japan). Diagnostic angiography showed severe and focal calcified popliteal artery stenotic lesion (*Figure 1A*). Then, a 0.014-inch Nitrex™ soft guidewire (ev3, Plymouth, MN, USA) was navigated in the distal popliteal artery. No filter was used for distal protection. Intra-arterial heparin (5,000 units) was administered. With the new generation monorail-guided HawkOne™ directional atherectomy catheter (Covidien, Dublin, Ireland) (*Figure 1B*) proximal to the stenosis, the electric motor was started by retracting the positioning lever, which deflected the tip of the catheter so that the window with the rotating blade was placed against the vessel wall. The device was slowly advanced through the stenosis. The catheter was then pulled back, rotated about 45°, and directed toward a new area of stenosis. After 4 cutting passages through stenosed area, debris were collected in the reservoir and the catheter tip was emptied of atherectomized material (*Figure 1C*). Completion angiography confirmed successful recanalization of the vessel without any residual stenosis (*Figure 1D*). In order to minimize the risk of restenosis,



**Figure 1** Endovascular procedural steps in a 69-year-old man with isolated calcified left popliteal artery lesion responsible for disabling claudication. (A) DSA showing focal stenosis of the left popliteal artery (arrow); (B) new generation monorail-guided HawkOne™ directional atherectomy catheter; (C) atherectomized material collected from the reservoir after 4 cutting passages through stenosed area; (D) successful recanalization of the vessel after atherectomy alone without any residual stenosis; (E) post-atherectomy adjunctive angioplasty with drug-coated balloon; (F) improved results after paclitaxel-coated balloon angioplasty with no residual stenosis at final DSA. No stenting was necessary. DSA, digital ambulatory subtraction angiography.

post-atherectomy adjunctive angioplasty with DCB was performed anyway using a 5.0×120 mm in Pact™ Admiral™ Paclitaxel-eluting PTA Balloon Catheter (Medtronic, Santa Rosa, CA, USA) (Figure 1E). No residual stenosis was noted at final DSA (Figure 1F). No stenting was necessary. Vascular access was closed using an ExoSeal™ closure system (Cordis, Miami Lakes, FL, USA). Clopidogrel (75 mg/d) was given for 4 weeks after the procedure and aspirin (100 mg/d) indefinitely. No procedure related adverse events occurred (including puncture site hematoma, distal embolization of atherosclerotic debris, dissection

and perforation). The patient was discharge 6 h after intervention. Follow-up Doppler ultrasound scan at 3 and 6 months showed no restenosis, and clinical success based on improvement in the Rutherford classification was totally achieved without any residual symptoms.

## Discussion

The incidence of restenosis after endovascular peripheral procedures varies considerably depending of the vascular area but appears to be highest in the femoro-popliteal

arteries (1-4). These events may be even more frequent in presence of severe calcifications of the target lesions. High degree of calcifications represents a real limitation for femoro-popliteal procedures in terms of immediate results due to vessel recoil after balloon angioplasty, post-dilation dissection related to high pressure used, higher stent placement rate and higher stent compression and/or fractures rate (5-7).

Different debulking devices have been proposed to remove calcified portion of the arterial lesions. Among these, DA is one of the more commonly used (7-10). This helps to achieve a good angiographic success but has no effect on the restenosis rate. It has recently been demonstrated that the use of DCB reduces restenosis occurrence in the treatment of femoro-popliteal lesions (4). Studies investigating DCB in the femoro-popliteal artery did not enroll severe calcified lesions (4). The take home message of the present case is that the combined use of DA and DCB in the treatment of severely calcified lesions of the femoro-popliteal tract is a safe procedure associated with no restenosis on the mid-term.

Atherectomy alone in the present case was technically successful, but additional balloon dilation with DCB served to visually improve the angiographic appearance of the recanalized artery and to potentially reduce the risk of long-term restenosis (11-13). Additional stent implantation was avoided in this vascular area where the risk of fracture and intrastent restenosis is high. The treatment of this type of lesions represents the main indication for DA, in order to avoid stenting. Overall, paclitaxel seems to be effective for prevention of restenosis in the femoro-popliteal arteries. The underlying mechanism is related to disruption of the microtubule function, inhibiting smooth muscle cell migration and proliferation and extracellular matrix secretion. The elution of an antiproliferative drug in the arterial wall at the end of the endovascular procedure minimizes the development of neointimal hyperplasia and results into a low incidence of target lesion revascularization (4). Because the burden of intima-hyperplasia-associated restenosis in the peripheral arteries is quite considerable, especially in long lesions, the present case supports the approach of combining DA with DCB, thus avoiding additional stenting procedure.

From a technical standpoint, the catheter could easily be controlled in antegrade use, despite wire guidance of the monorail system over only a short distance. The atherectomy catheter may be successfully used even for lesions with a high degree of calcification. No peripheral

embolization of overly large volume of atherectomized material in the reservoir was noted. This new version of the reservoir has been engineered by the manufacturer so that atheroma components can no longer pass out the hole. Moreover, the modified tip makes flushing of the reservoir very simple. For these reasons, we did not place any filter for distal protection prior to the use of peripheral DA. Filter placement may be discussed in case of longer lesions to avoid embolization of atherosclerotic debris.

Further studies are needed to identify the best use of this new atherectomy device: atherectomy alone to avoid the barotrauma induced by the balloon or atherectomy combined with DCB angioplasty to achieve the best results. Additionally, a randomized controlled trial comparing DA, balloon angioplasty, DCB angioplasty, and stenting is necessary to find out if atherectomy has favorable long-term results.

### Acknowledgements

None.

### Footnote

*Conflicts of Interest:* The authors have no conflicts of interest to declare.

*Informed Consent:* Written informed consent was obtained from the patient for publication of this Case Report and any accompanying images.

### References

1. Rastan A, McKinsey JF, Garcia LA, Rocha-Singh KJ, Jaff MR, Noory E, Zeller T; DEFINITIVE LE Investigators. One-year outcomes following directional atherectomy of infrapopliteal artery lesions: subgroup results of the prospective, multicenter DEFINITIVE LE Trial. *J Endovasc Ther* 2015;22:839-46.
2. Garcia LA, Jaff MR, Rocha-Singh KJ, Zeller T, Bosarge C, Kamat S, McKinsey JF. A comparison of clinical outcomes for diabetic and nondiabetic patients following directional atherectomy in the DEFINITIVE LE Claudicant Cohort. *J Endovasc Ther* 2015;22:701-11.
3. Shammas NW, Shammas GA, Jerin M. Differences in patient selection and outcomes between SilverHawk atherectomy and laser ablation in the treatment of femoropopliteal in-stent restenosis: a retrospective analysis

- from a single center. *J Endovasc Ther* 2013;20:844-52.
4. Sixt S, Carpio Cancino OG, Treszl A, Beschorner U, Macharzina R, Rastan A, Krankenberg H, Neumann FJ, Zeller T. Drug-coated balloon angioplasty after directional atherectomy improves outcome in restenotic femoropopliteal arteries. *J Vasc Surg* 2013;58:682-6.
  5. Cioppa A, Stabile E, Popusoi G, Salemm L, Cota L, Pucciarelli A, Ambrosini V, Sorropago G, Tesorio T, Agresta A, Biamino G, Rubino P. Combined treatment of heavy calcified femoro-popliteal lesions using directional atherectomy and a paclitaxel coated balloon: One-year single centre clinical results. *Cardiovasc Revasc Med* 2012;13:219-23.
  6. Trentmann J, Charalambous N, Djawanscher M, Schäfer J, Jahnke T. Safety and efficacy of directional atherectomy for the treatment of in-stent restenosis of the femoropopliteal artery. *J Cardiovasc Surg (Torino)* 2010;51:551-60.
  7. Zeller T, Sixt S, Schwarzwälder U, Schwarz T, Frank U, Bürgelin K, Pochert V, Müller C, Noory E, Krankenberg H, Hauswald K, Neumann FJ, Rastan A. Two-year results after directional atherectomy of infrapopliteal arteries with the SilverHawk device. *J Endovasc Ther* 2007;14:232-40.
  8. Zeller T, Rastan A, Sixt S, Schwarzwälder U, Schwarz T, Frank U, Bürgelin K, Müller C, Rothenpieler U, Flügel PC, Tepe G, Neumann FJ. Long-term results after directional atherectomy of femoro-popliteal lesions. *J Am Coll Cardiol* 2006;48:1573-8.
  9. Zeller T, Rastan A, Schwarzwälder U, Frank U, Bürgelin K, Amantea P, Müller C, Flügel PC, Neumann FJ. Percutaneous peripheral atherectomy of femoropopliteal stenoses using a new-generation device: six-month results from a single-center experience. *J Endovasc Ther* 2004;11:676-85.
  10. Zeller T, Rastan A, Schwarzwälder U, Frank U, Bürgelin K, Amantea P, Müller C, Krankenberg H, Flügel PC, Neumann FJ. Midterm results after atherectomy-assisted angioplasty of below-knee arteries with use of the Silverhawk device. *J Vasc Interv Radiol* 2004;15:1391-7.
  11. Tarricone A, Ali Z, Rajamanickam A, Gujja K, Kapur V, Purushothaman KR, Purushothaman M, Vasquez M, Zalewski A, Parides M, Overbey J, Wiley J, Krishnan P. Histopathological evidence of adventitial or medial injury is a strong predictor of restenosis during directional atherectomy for peripheral artery disease. *J Endovasc Ther* 2015;22:712-5.
  12. Roberts D, Niazi K, Miller W, Krishnan P, Gammon R, Schreiber T, Shammam NW, Clair D; DEFINITIVE Ca<sup>++</sup> Investigators. Effective endovascular treatment of calcified femoropopliteal disease with directional atherectomy and distal embolic protection: final results of the DEFINITIVE Ca<sup>++</sup> trial. *Catheter Cardiovasc Interv* 2014;84:236-44.
  13. Stanley GA, Winscott JG. Maximizing lumen gain with directional atherectomy. *J Endovasc Ther* 2016;23:648-52.

**Cite this article as:** Loffroy R, Chevallier O, Falvo N, Gehin S, Midulla M, Galland C. Combined HawkOne directional atherectomy and paclitaxel-coated balloon angioplasty for isolated calcified popliteal artery lesion: a no-stent approach to lower extremity endovascular revascularization. *Quant Imaging Med Surg* 2018;8(3):364-367. doi: 10.21037/qims.2018.03.10