

High-speed real-time magnetic resonance imaging of fast tongue movements in elite horn players

Peter W. Iltis^{1,2}, Jens Frahm³, Dirk Voit³, Arun A. Joseph³, Erwin Schoonderwaldt², Eckart Altenmüller²

¹Department of Kinesiology, Gordon College, Wenham, MA, USA; ²University of Music, Drama and Media, Hannover, Germany; ³Biomedizinische NMR Forschungs GmbH am Max-Planck-Institut für biophysikalische Chemie, Göttingen, Germany

Correspondence to: Peter W. Iltis. Department of Kinesiology, Gordon College, Wenham, MA, USA. Email: peter.iltis@gordon.edu; Jens Frahm. Biomedizinische NMR Forschungs GmbH am Max-Planck-Institut für biophysikalische Chemie, Am Fassberg 11, 37077 Göttingen, Germany. Email: jfracm@gwdg.de.

Abstract: This paper describes the use of high-speed real-time (RT) magnetic resonance imaging (MRI) in quantifying very rapid motor function within the oropharyngeal cavity of six elite horn players. Based on simultaneous sound recordings, the efficacy of RT-MRI films at 30 and 100 frames per second (fps) was assessed for tongue movements associated with double tonguing performance. Serial images with a nominal temporal resolution of 10.0 and 33.3 ms were obtained by highly undersampled radial fast low-angle shot (FLASH) sequences (5 and 17 spokes, respectively) using complementary sets of spokes for successive acquisitions (extending over 9 and 5 frames, respectively). Reconstructions of high-speed images were obtained by temporally regularized nonlinear inversion (NLINV) as previously described. A customized MATLAB toolkit was developed for the extraction of line profiles from MRI films to quantify temporal phenomena associated with task performance. The analyses reveal that for the present setting, which required the use of a temporal median filter to optimize image quality, acquisition rates of 30 fps are inadequate to accurately detect tongue movements during double tonguing, but that rates of 100 fps do allow for a precise quantification of movement. These data for the first time demonstrate the extreme performance of elite horn players. High-speed RT-MRI offers so far unavailable opportunities to study the oropharyngeal movements during brass playing with future potential for teaching and the treatment of patients suffering from dystonia.

Keywords: Brass instrument players; tongue movements; oral cavity; real-time (RT) magnetic resonance imaging (MRI); tongue displacement

Submitted Jan 02, 2015. Accepted for publication Feb 27, 2015.

doi: 10.3978/j.issn.2223-4292.2015.03.02

View this article at: <http://dx.doi.org/10.3978/j.issn.2223-4292.2015.03.02>

Introduction

Human body movements often involve surprisingly high velocities that are inaccessible to conventional or even moderately accelerated magnetic resonance imaging (MRI) techniques. Because this particularly applies to the precise movements achieved by the tongue and throat, only few real-time (RT) MRI studies attempted to analyze human speech (1-3) or tongue movements of brass instrumentalists (4,5). The latter studies in trumpet players described velopharyngeal movements and changes in oropharyngeal

areas during several performance tasks (4) and presented a single case of dynamic phenomena associated with pharyngoceles (5). However, neither study utilized high-speed RT-MRI but relied on a maximum rate of only 10 frames per second (fps), i.e., measuring times of at least 100 ms, nor did they report any dynamic quantitative analyses. In fact, these data again support the notion that the ability to acquire RT-MRI films at high speed is vital for a proper visualization and quantification of very rapid human movement as, for example, accomplished by professional speakers, actors, singers and musicians. This may now

become available due to recent advances in RT-MRI which are based on a combination of highly undersampled radial gradient-echo MRI and serial image reconstruction by advanced parallel imaging using temporally regularized nonlinear inversion (NLINV), e.g., see (6,7). Respective developments at 20 ms image acquisition times (8) and their applications to cardiac function (9,10), quantitative blood flow (11,12), human speech (13) and swallowing mechanics (14,15) promise significant progress.

This work evaluates whether the now achievable acquisition rates are adequate in capturing the fastest human movements, i.e., tongue movements in professional brass instrumentalists. Musical performance is an area of human endeavor that generally requires very rapid and fine motor control. For example, the movement speeds (measured as inter-keystroke intervals) of a pianist playing a prescribed sequence of notes have been reported at 125 ms or faster (16). In a study of non-musicians investigating simple rapid sequential finger tapping (17), the duration of inter-finger tapping intervals was recorded below 40 ms. Using high-speed videography and motion capture systems, there is little difficulty in studying such kinematic phenomena. However, brass instrument performance involves movements that are not readily observable outside of the body. Some of these, like multiple tonguing techniques, occur at high speeds and may require acquisition rates that are even faster than those reported above. The experimental challenges therefore involve the necessary trade-off between achieving sufficient temporal resolution and maintaining adequate spatial resolution and image quality to unambiguously identify the relevant structures.

We recently studied dynamic movements of the tongue and oral cavity in brass players using RT-MRI with an acquisition rate of 30 fps or 33.3 ms image acquisition times and developed tools for conducting quantitative analyses during brass performance on the trumpet, French horn, trombone, and tuba (18). Despite some very promising results and the development of a relevant set of performance tasks, the study was limited in two respects. First, it was conducted on amateur musicians, so that it remains to be seen whether similar movement strategies are observed for more accomplished musicians who, for example, are capable of even faster tonguing rates. And second, based on MRI hardware improvements in radiofrequency coil design and gradient performance, the chosen RT-MRI method allowed for further advances toward a nominal temporal resolution of 10 ms or 100 fps. The purpose of this work was to apply such techniques to study elite French horn players

performing a double tonguing exercise at top speed. The specific aim was to compare the efficacy of RT-MRI films at 30 and 100 fps in obtaining valid quantitative measures of dynamic tongue movement.

Materials and methods

Subjects, performance device and testing protocol

Six elite horn players (age range 34 to 59) served as subjects for this study. All are horn players of international reputation, four currently performing with major U.S. or European symphony orchestras, and two having an active international solo career. Prior to MRI examination, all subjects gave written informed consent as approved by the recommendations of the local ethics committee.

Each performer was asked to perform two trials involving double tonguing, each trial using either an acquisition rate of 30 fps (corresponding to 33.3 ms per image) or 100 fps (10.0 ms). Double-tonguing requires the performer to execute tongue movements that produce the consonants “T-K” in a rapid cycle that repeats for as long as the effect is required. The exercise involved playing Eb4, using the fastest tonguing speed they could achieve with this technique, while inside the MRI scanner. To accomplish this, a custom-built MRI-compatible horn was utilized (R. Seraphinoff, Indiana University, USA). The horn was equipped with a plastic horn mouthpiece and graduated plastic tubing simulating actual horn diameters comprising most of the length of the horn. The tubing was attached to a non-ferromagnetic brass bell flare at a distance that created a horn pitched in Eb concert capable of producing tones throughout the entire harmonic series spanning three octaves from Eb2 up to Eb5. Prior to performing, subjects were allowed time to practice with the instrument to familiarize themselves with its performance characteristics.

Real-time MRI

All experiments were performed on a state-of-the-art 3 T MRI system (Magnetom Prisma Fit, Siemens Healthcare, Erlangen, Germany) with a maximum gradient strength of $80 \text{ mT} \cdot \text{m}^{-1}$ and a slew rate of $200 \text{ T} \cdot \text{m}^{-1} \cdot \text{s}^{-1}$. In practice, however, the speed of gradient switching is reduced to avoid peripheral nerve stimulation. Data acquisition was accomplished with the use of a 64-channel head coil. RT-MRI was based on highly undersampled radial fast low-angle shot (FLASH) acquisitions with NLINV

reconstruction as previously described (8).

All RT-MRI measurements were performed with the horn players performing in a supine position in the magnet. Typically, recordings were in a mid-sagittal orientation using an in-plane resolution of $1.5 \times 1.5 \text{ mm}^2$, a slice thickness of 10 mm, a FOV of $192 \times 192 \text{ mm}^2$ and a base resolution of 128 data samples per radial spoke. Acquisitions at 30 fps employed the following parameters: repetition time (TR) = 1.96 ms, echo time (TE) = 1.25 ms, flip angle = 5° , bandwidth $1,860 \text{ Hz pixel}^{-1}$, 17 radial spokes per image, and $n=5$ different sets of spatially complementary spokes for consecutive acquisitions. High-speed acquisitions at 100 fps used: TR = 2.00 ms, TE = 1.25 ms, flip angle = 5° , bandwidth $1,560 \text{ Hz pixel}^{-1}$, five radial spokes, and $n=9$ different sets of spokes for consecutive acquisitions. In the former case the temporal regularization of the NLINV reconstruction inherently benefits from a total of 85 different spokes carrying complementary spatial information, while in the latter case this number reduces to 45. Post-processing involved the application of a temporal median filter (see next subsection) to reduce residual streaking artifacts and ensure optimum image quality for quantitative analyses. Its length was adjusted to the number of frames with different sets of spokes, i.e., either $n=5$ or 9.

Online reconstruction and display of RT images with minimal delay was achieved by a parallelized version of the NLINV algorithm (19) and a bypass computer (sysGen/TYAN Octuple-GPU, 2x Intel Westmere E5620 processor, 48GB RAM, Sysgen, Bremen, Germany) which was fully integrated into the reconstruction pipeline of the commercial MRI system and equipped with two processors (CPUs, SandyBridge E5-2650, Intel, Santa Clara, CA, USA) and 8 graphical processing units (GPUs, GeForce GTX, TITAN, NVIDIA, Santa Clara, CA, USA).

Typically, RT-MRI acquisitions of horn playing tasks were recorded for a period of 30 s corresponding to 900 or 3,000 images depending on the chosen temporal resolution or frame rate. To allow for acoustic recordings, the bell of the French horn, which was placed at about the end of patient table outside the bore of the magnet, was equipped with an MR-compatible optical microphone (Dual Channel-FOMRI, Optoacoustics, Or Yehuda, Israel). Sound recording was triggered by the radial FLASH sequence and thus synchronized to image acquisition. For further details see (13).

Temporal accuracy

The temporal accuracy of the chosen RT-MRI method

has recently been evaluated for small objects moving with velocities of up to $30 \text{ cm}\cdot\text{s}^{-1}$ (20). The results confirm that the combined strategy of complementary radial acquisitions with reconstructions by temporally regularized NLINV, which is solved by an iteratively regularized Gauss-Newton method (8), ensures high image quality without compromising temporal resolution. In fact, temporal regularization to the immediately preceding image (and its coil sensitivities) does not merge any preceding data into the reconstruction of the actual frame, but only constrains the range of possible solutions to the mathematically ill-conditioned nonlinear inverse problem: maintaining data consistency during iterative optimization is ensured by dividing the amplitude of the regularization terms by a factor of two during each iteration. Thus, for six iterative steps as used here, any regularization is downsized by a factor of 64 relative to the data consistency term while reconstructing the final image.

The described NLINV algorithm achieves improved image quality whenever consecutive datasets provide complementary spatial information. However, as explained above, this is not accomplished by “adding” previous data but by “pushing” the iterative optimization into the correct direction and then gradually removing the regulative influence. Accordingly, when reconstructing a series of images the quality of consecutive frames gradually improves from the very first frame (no prior information) to at least the n th frame when n is the number of spatially complementary datasets.

On the other hand, post-processing by a temporal median filter, which was still required to minimize residual streaking artifacts, may affect the temporal acuity of fast moving objects (20). For 30 fps (i.e., a nominal temporal resolution of 33.3 ms) and a median filter extending over $n=5$ different datasets, the experimental assessment yielded an upper speed of about $10 \text{ cm}\cdot\text{s}^{-1}$ up to which small objects could reliably be visualized, while acquisitions at 18 ms temporal resolution demonstrated still excellent temporal fidelity at $15 \text{ cm}\cdot\text{s}^{-1}$ (20). For acquisitions at 100 fps (i.e., a nominal temporal resolution of 10.0 ms) with a median filter extending over $n=9$ different frames the accessible velocities range up to $25 \text{ cm}\cdot\text{s}^{-1}$.

Data analysis

The procedures used for obtaining quantitative information from RT-MRI films have been detailed previously (18), so only a brief description will be provided here. A custom

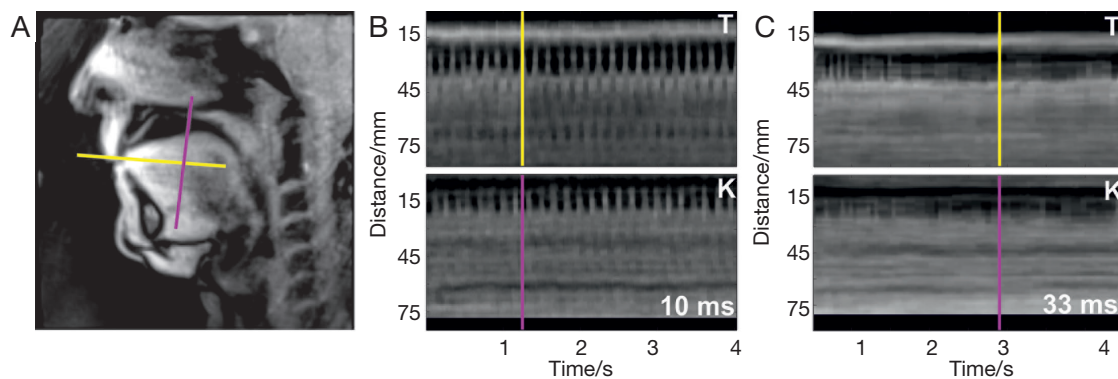


Figure 1 (A) Sagittal image selected from a real-time MRI movie at 100 fps indicating the position of the tongue tip for “T” (single subject). The two lines refer to the two major directions of tongue movement during double tonguing (repetitive “T”-“K” at top speed). Their signal intensity time courses are depicted for an image series at a nominal temporal resolution of (B) 10.0 ms and (C) 33.3 ms. MRI, magnetic resonance imaging; fps, frames per second.

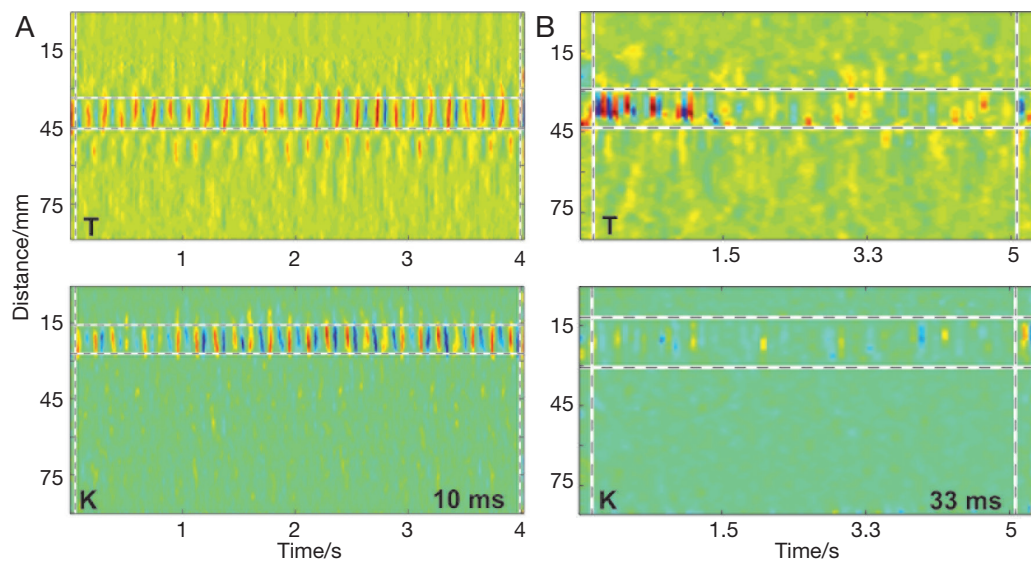


Figure 2 Temporal gradients calculated from the signal intensity time courses shown in *Figure 1* for real-time MRI acquisitions of double tonguing (“T”-“K”) at (A) 10.0 ms and (B) 33.3 ms nominal resolution. Dashed lines indicate the regions of interest selected for quantitative analyses. MRI, magnetic resonance imaging.

RT-MRI toolbox was developed for MATLAB (MATLAB R2014a, including the Image Processing and Signal Processing Toolbox) that allows for dynamic data analysis. First, grid lines were positioned by hand to be aligned with the direction of movement of the tip of the tongue (“T”) and the mid-tongue (“K”). Temporal profiles were obtained which quantify the signal intensities along these gridlines for the duration of each trial (see *Figure 1*). Second, the temporal gradients of both line profiles were calculated (see *Figure 2*). Third, the range of motion (ROM) of both parts

of the tongue was determined visually from inspection of the line and the gradient profiles in combination with the average and standard deviation (SD) curves with respect to time, i.e., the MRI signal intensity (mean, SD) and its rate of change (SD) along the respective lines. The latter curves allow for a better-informed decision, because they reveal the variability of signal intensities along the line (see *Figure 3*). Fourth, time series data were extracted by taking the average of the temporal gradient across the spatial dimension, including only the identified ROM. Finally,

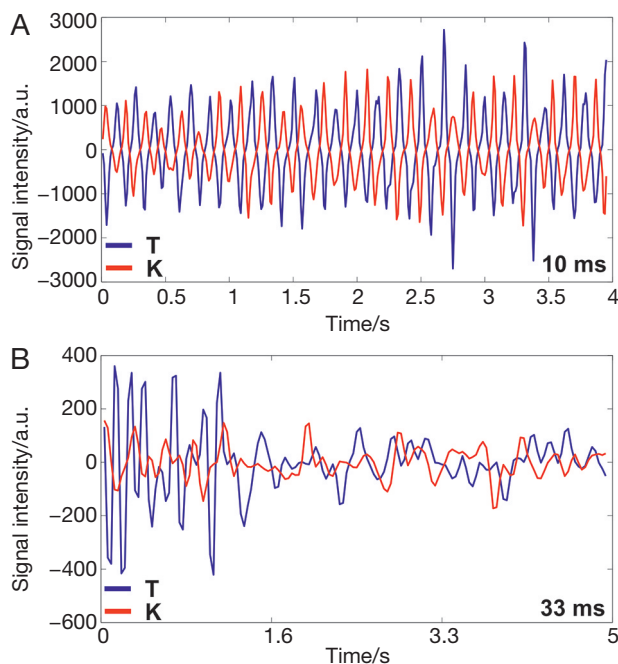


Figure 3 Time series data obtained from the regions of interest shown in *Figure 2* for real-time MRI acquisitions of double tonguing (“T”-“K”) at (A) 10.0 ms and (B) 33.3 ms nominal resolution. A rate of 100 fps clearly reveals a regular sinusoidal anti-phase pattern for the tongue tip and mid-tongue. MRI, magnetic resonance imaging; fps, frames per second.




Figure 5 Real-time MRI at 100 frames per second (i.e., a nominal resolution of 10 ms) of an elite horn player performing double tonguing (“T”-“K”) at top speed (21). Because the images were interpolated to a 256×256 matrix for data analysis, pixels along the X and Y axis refer to 0.75 mm. MRI, magnetic resonance imaging. Available online: <http://www.asvide.com/articles/478>

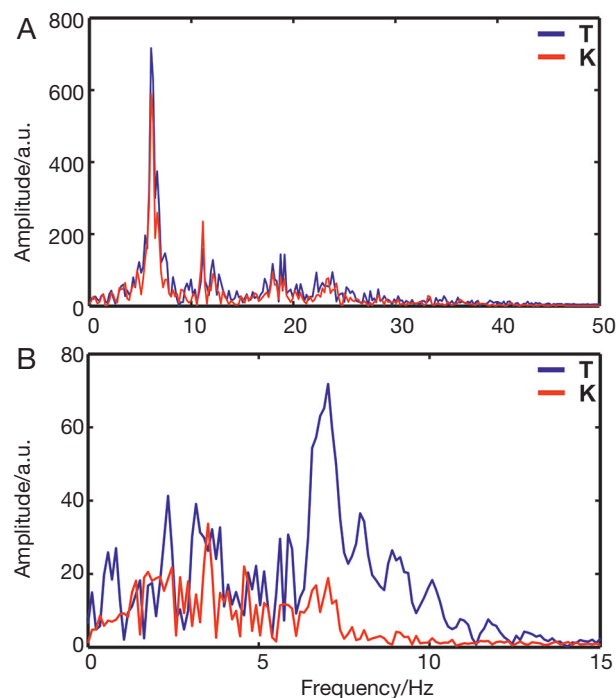


Figure 4 Frequency analysis of the data shown in *Figure 3* for real-time MRI acquisitions of double tonguing (“T”-“K”) at (A) 10.0 ms and (B) 33.3 ms nominal resolution. The higher frame rate reveals a dominant frequency of about 6 Hz for this subject. MRI, magnetic resonance imaging.

the time series data were used to calculate the correlation coefficient of the two movement components of the tongue (“T” and “K”), and the frequency of the movement was estimated from the peaks of the amplitude spectra obtained by Fourier transformation (see *Figure 4*). Differences between acquisition rates with respect to “T” and “K” ROM values and note rates were assessed using two-tailed, paired *t*-tests ($P < 0.05$).

Results and discussion

Figure 1 displays a selected sagittal 10 ms image of one of the performers at the moment of “T” articulation during double tonguing. A corresponding RT-MRI movie at 100 fps is available as *Figure 5*. The two profile lines in the image are chosen for quantitative analyses and represent directions along which movements of the tongue tip and mid tongue, respectively, are most prominent. The distal

Table 1 Quantitative results for real-time MRI of double tonguing (“T”-“K”)

Subject	100 frames per second					30 frames per second				
	ROM “T” (mm)	ROM “K” (mm)	r	Note rate (s ⁻¹)	Tempo (bpm)	ROM “T” (mm)	ROM “K” (mm)	r	Note rate (s ⁻¹)	Tempo (bpm)
#1	16.50	15.00	-0.92	10.7	161	16.50	15.75	-0.84	10.4	156
#2	12.00	12.00	-0.84	12.4	187	23.25	15.75	-0.02	7.6	114
#3	12.00	11.25	-0.81	12.6	189	14.25	18.75	-0.09	10.1	121
#4	12.75	12.75	-0.72	11.7	175	15.00	14.25	-0.81	9.7	145
#5	12.00	15.00	-0.85	11.9	179	13.50	7.50	-0.45	9.3	139
#6	15.00	12.75	-0.84	10.0	150	13.50	18.75	-0.72	9.4	141

r, pearson product-moment correlation coefficient. MRI, magnetic resonance imaging; ROM, range of movement; bpm, beats per minute.

ends of these lines intersect the back of the teeth (line 1—“T”) and the hard palate (line 2—“K”): at these points contact by the tongue is made. The middle and bottom panels of *Figure 1* display the line profiles across time, resolved at 100 fps (10 ms) and 30 fps (33 ms), respectively. The distance along each line is depicted in mm (Y axis), and the changes in signal intensity are shown as a function of time (X axis). These time courses are indicative of movement, and it is apparent that for the tongue tip “T” most movement occurs in positions between about 20 and 35 mm, while for the mid-tongue “K” most movement occurs between about 10 and 20 mm.

At 100 fps, numerous bright peaks can be identified, each representing the moment of contact between the tongue tip and the mid-tongue with its respective contact point. Every time this occurs, a note is produced, and thus, the trial depicted here consists of 52 notes (i.e., 26 “T”s and 26 “K”s). The vertical lines in the middle panel of *Figure 1* are synchronized with the moment of the “T” articulation, when the mid-tongue is farthest from its contact point for the articulation “K”; the movements are anti-phase with one another. The bottom panel of *Figure 1* shows the corresponding data of the same subject acquired at 30 fps, where the inferior temporal fidelity becomes obvious. The resulting line profiles fail to show regular peaks with each note as signal intensity changes are blurred across time.

The resulting temporal gradients are depicted in *Figure 2*. The dashed vertical lines contain the analyzed frame range, and the two horizontal lines show the region of interest (ROI) that was used in the various quantitative analyses. *Figure 2* again demonstrates that acquisitions at 100 fps yield superior fidelity for both the “T” and “K” articulation when compared to 30 fps. Time series data obtained from

the identified ROIs are depicted in *Figure 3*. A regular sinusoidal anti-phase pattern for the tongue tip and mid-tongue is readily observed at 100 fps, whereas no such consistency is seen for the 30 fps trial. When these data are subjected to a Fourier transform, the superiority of the 100 fps trial becomes even more obvious. The corresponding results in *Figure 4* clearly reveal a dominant frequency at about 6 Hz for the 100 fps data, whereas the lower temporal resolution leads to a more chaotic pattern with no unambiguously discernable main frequency.

Quantitative analyses of all six elite performers are depicted in *Table 1*. The characteristic anti-phase nature of double tonguing is illustrated by the correlation coefficient between the “T” and “K” components of tongue movement, and is consistently demonstrated across all subjects using data from the 100 fps trials. In contrast, data from the 30 fps trials failed to yield such consistency. Additionally, the calculated note rates across subjects were significantly higher using data obtained at 100 fps than at 30 fps, although the latter calculations represent only rough estimates based upon spatial range selections from poorly visible temporal gradients (compare *Figure 2B*). The corresponding tempos to these note rates (assuming four notes per beat) are consistently lower for the 30 fps data. Subsequent verification of these tempos was done using a metronome applied to the actual sound files of the trials, and in all cases, the 100 fps trials are precisely accurate, while the 30 fps trials always underestimate tonguing speed.

Closer examination of *Table 1* shows that in the cases where tonguing speed was fastest (i.e., subjects #2 and #3), the ability to properly discern the anti-phase nature of double tonguing was lost at 30 fps. On the other hand, for subjects with the slowest double-tonguing speeds and

the largest ROM values for “T” (i.e., subjects #1 and #6), the anti-phase nature was still detectable at 30 fps despite the inaccuracy of note rate calculations. In these cases the temporal gradients at 30 fps provided a large enough sample of distinct intensity changes to allow for a certain degree of accuracy in this part of the analysis.

Finally, ROM values obtained for the tongue tip and mid-tongue show no significant difference between 30 and 100 fps. However, the much larger standard deviation in the 30 fps data for both “T” and “K” tongue movements is readily apparent and is indicative of the difficulty of accurately determining the ROM from the temporal gradients at this slower acquisition rate.

With respect to the accuracy of determining the ROM of tongue movements using RT-MRI, caution must be urged in interpreting the reported values, as a degree of subjectivity in executing the analyses is unavoidable. The temporal gradients used to subjectively identify the ROI containing movement (i.e., the spatial range where signal intensity changes confirm movement) are much clearer at 100 fps than at 30 fps, and yet “edge-blurring” at the extremities makes precise identification difficult. Further, all exercises were performed in a supine position with subjects lying in the magnet. Although unavoidable and despite the fact that none of the performers complained about the unusual situation, this posture is not identical to a seated or standing position, and it cannot entirely be excluded that the obtained values may slightly differ compared to more typical performance conditions.

In conclusion, we have shown that for the present experimental conditions RT-MRI recordings at 100 fps (i.e., a nominal temporal resolution of 10 ms) allow for accurate quantitative analyses of small and rapid human movements such as those demonstrated during double tonguing in elite horn players. The temporal fidelity afforded at acquisition rates of 30 fps is not adequate for these purposes, at least not when using a temporal median filter for removing residual artifacts and improving the quality of respective image series (20). Thus, for RT-MRI studies of fine motor movements with velocities on the order of $25 \text{ cm}\cdot\text{s}^{-1}$ as found here for the protruding tongue tip (i.e., typically 15 mm in about 60 ms or six frames), future analyses should be conducted at sufficiently high acquisition rates.

Acknowledgements

We wish to acknowledge Stefan Dohr, Andrej Just, and Fergus McWilliam of the Berlin Philharmonic Orchestra

as well as Marie-Luise Neunecker, Jeff Nelsen, Eli Epstein, and Amanda Kleinbart for their enthusiastic support.

Disclosure: J Frahm holds a patent about the real-time MRI acquisition and reconstruction technique used here.

References

1. Engwall O. “A revisit to the Application of MRI to the Analysis of Speech Production-Testing our assumptions”. Proceedings of the Sixth International Seminar on Speech Production. Sydney, 2003.
2. Echternach M, Sundberg J, Arndt S, Breyer T, Markl M, Schumacher M, Richter B. Vocal tract and register changes analysed by real-time MRI in male professional singers—a pilot study. *Logoped Phoniatr Vocol* 2008;33:67-73.
3. Hagedorn C, Proctor M, Goldstein L, Gorno Tempini ML, Narayanan SS. Characterizing covert articulation in apraxic speech using real-time MRI. Available online: <http://sail.usc.edu/span/pdfs/hagedorn2012characterizing.pdf>
4. Schumacher M, Schmoor C, Plog A, Schwarzwald R, Taschner Ch, Echternach M, Richter B, Spahn C. Motor functions in trumpet playing—a real-time MRI analysis. *Neuroradiology* 2013;55:1171-81.
5. Traser L, Spahn C, Richter B, Baumann T, Schumacher M, Echternach M. Real-time and three-dimensional MRI for diagnosis of pharyngoceles. *J Magn Reson Imaging* 2014;40:55-7.
6. Uecker M, Zhang S, Voit D, Merboldt KD, Frahm J. Real-time MRI: recent advances using radial FLASH. *Imaging in Med* 2012;4:461-76.
7. Zhang S, Joseph AA, Voit D, Schaetz S, Merboldt KD, Unterberg-Buchwald C, Hennemuth A, Lotz J, Frahm J. Real-time magnetic resonance imaging of cardiac function and flow—recent progress. *Quant Imaging Med Surg* 2014;4:313-29.
8. Uecker M, Zhang S, Voit D, Karaus A, Merboldt KD, Frahm J. Real-time MRI at a resolution of 20 ms. *NMR Biomed* 2010;23:986-94.
9. Zhang S, Uecker M, Voit D, Merboldt KD, Frahm J. Real-time cardiovascular magnetic resonance at high temporal resolution: radial FLASH with nonlinear inverse reconstruction. *J Cardiovasc Magn Reson* 2010;12:39.
10. Voit D, Zhang S, Unterberg-Buchwald C, Sohns JM, Lotz J, Frahm J. Real-time cardiovascular magnetic resonance at 1.5 T using balanced SSFP and 40 ms resolution. *J Cardiovasc Magn Reson* 2013;15:79.
11. Joseph AA, Merboldt KD, Voit D, Zhang S, Uecker

- M, Lotz J, Frahm J. Real-time phase-contrast MRI of cardiovascular blood flow using undersampled radial fast low-angle shot and nonlinear inverse reconstruction. *NMR Biomed* 2012;25:917-24.
12. Joseph A, Kowallick JT, Merboldt KD, Voit D, Schaetz S, Zhang S, Sohns JM, Lotz J, Frahm J. Real-time flow MRI of the aorta at a resolution of 40 msec. *J Magn Reson Imaging* 2014;40:206-13.
 13. Niebergall A, Zhang S, Kunay E, Keydana G, Job M, Uecker M, Frahm J. Real-time MRI of speaking at a resolution of 33 ms: undersampled radial FLASH with nonlinear inverse reconstruction. *Magn Reson Med* 2013;69:477-85.
 14. Zhang S, Olthoff A, Frahm J. Real-time magnetic resonance imaging of normal swallowing. *J Magn Reson Imaging* 2012;35:1372-9.
 15. Olthoff A, Zhang S, Schweizer R, Frahm J. On the physiology of normal swallowing as revealed by magnetic resonance imaging in real time. *Gastroenterol Res Pract* 2014;2014:493174.
 16. Furuya S, Flanders M, Soechting JF. Hand kinematics of piano playing. *J Neurophysiol* 2011;106:2849-64.
 17. Arunachalam R, Weerasinghe VS, Mills KR. Motor control of rapid sequential finger tapping in humans. *J Neurophysiol* 2005;94:2162-70.
 18. Iltis PW, Schoonderwaldt E, Zhang S, Frahm J, Altenmüller E. Real-time MRI comparisons of brass players: A quantitative methodological pilot study. *Hum Movement Sci* 2015. In press.
 19. Schaetz S, Uecker M. A Multi-GPU Programming Library for Real-Time Applications. In: Xiang Y, Stojmenovic I, Aduhan BO, et al. eds. *Algorithms and Architectures for Parallel Processing*. Berlin: Springer Berlin Heidelberg, 2012:114-28.
 20. Frahm J, Schaetz S, Untenberger M, Zhang S, Voit D, Merboldt KD, Sohns JM, Lotz J, Uecker M. On the temporal fidelity of nonlinear inverse reconstructions for real-time MRI – The motion challenge. *The Open Med Imaging J* 2014;8:1-7.
 21. Iltis PW, Frahm J, Voit D, Joseph AA, Schoonderwaldt E, Altenmüller E. Real-time MRI at 100 frames per second (i.e., a nominal resolution of 10 ms) of an elite horn player performing double tonguing (“T”-“K”) at top speed. *Asvide* 2015;2:023. Available online: <http://www.asvide.com/articles/478>

Cite this article as: Iltis PW, Frahm J, Voit D, Joseph AA, Schoonderwaldt E, Altenmüller E. High-speed real-time magnetic resonance imaging of fast tongue movements in elite horn players. *Quant Imaging Med Surg* 2015;5(3):374-381. doi: 10.3978/j.issn.2223-4292.2015.03.02