

Antisynthetase syndrome: a case report

Mehwish Asif Qureshi¹, Edward Hoey², Timothy Fletcher³, Zubair Ahmed³

¹Registrar General Practice, Westmidlands, UK; ²Consultant Radiologist, ³Respiratory Physicians, Good Hope Hospital, Birmingham, UK

Correspondence to: Mehwish Asif Qureshi. Hazelwood Group Practice, Coleshill, Birmingham, B46 3LD, UK. Email: drmehwish@gmail.com.

Abstract: The case is about a 48-year-old man with one week history of progressively worsening shortness of breath and reduced exercise tolerance. Laboratory investigations revealed raised ESR, creatine kinase (CK) and positive anti-aminoacyl-transfer RNA synthetase. High resolution computed tomography (HRCT) chest showed prominent mediastinal lymph nodes and scattered lung nodules. These findings along with clinical features and investigations confirmed the diagnosis of antisynthetase syndrome (ASS). The radiological investigations proved to be the key step in diagnosis and management of this case.

Keywords: Antisynthetase syndrome (ASS); interstitial lung disease (ILD); high resolution computed tomography (HRCT)

Submitted Jun 09, 2015. Accepted for publication Jul 20, 2015.

doi: 10.21037/qims.2015.11.04

View this article at: <http://dx.doi.org/10.21037/qims.2015.11.04>

Introduction

Antisynthetase syndrome (ASS) is quite a rare condition and early diagnosis is the key in management (1-3).

Case presentation

A 48-year-old United Kingdom born Caucasian male with no significant past medical history was admitted to the respiratory ward with a 1-week history of worsening shortness of breath, fever and polyarthralgia. He also described left sided chest pain, worse on the deep inspiration. His exercise tolerance had significantly reduced from a normal active life style to being unable to brush his teeth or comb his hair. He was an ex-smoker (20 pack years history), no alcohol use, no known allergies and did not take any regular medications.

Physical examination revealed bilateral fine basal crepitation, oxygen saturations of 95% on room air and blood pressure 118/75 mmHg. Cardiovascular, abdominal and neurological system examinations were unremarkable. The metacarpo-phalangeal and proximal interphalangeal joints of both hands were swollen and tender to joint margin palpation.

Laboratory and investigative findings

Full blood count was normal. Routine biochemistry and liver function tests were normal. His erythrocyte sedimentation rate was 25 (0-15 mm/hr) and C-reactive protein was 63 (0-10 mg/L). Creatine kinase (CK) levels were elevated at 646 (0-20 mg/L). Urinalysis, hepatitis serology, HIV screen, and serum ferritin levels were unremarkable.

Rheumatology workup showed a negative rheumatoid factor (<20.0) but positive anti-aminoacyl-transfer RNA synthetase result with positivity for anti-Ro and anti-Jo-1 antibodies (negative for anti-La, anti-RNP and anti-Sm antibodies). Antiglomerular basement membrane and scl-70 were negative. Serum angiotensin converting enzyme, complement, and cryoglobulins levels were normal. There were also negative results for blood cultures, influenza A and B, Mycoplasma pneumoniae, Chlamydia, Q fever, respiratory syncytial virus, adenovirus, legionella pneumophila and pneumococcal antigen serology.

Electrocardiogram showed sinus tachycardia with no other changes. Dyspnoea precluded lung function testing and bronchoscopy. Chest radiograph showed subtle areas of opacification scattered throughout both lower lobes. A high resolution computed tomography (HRCT) scan showed

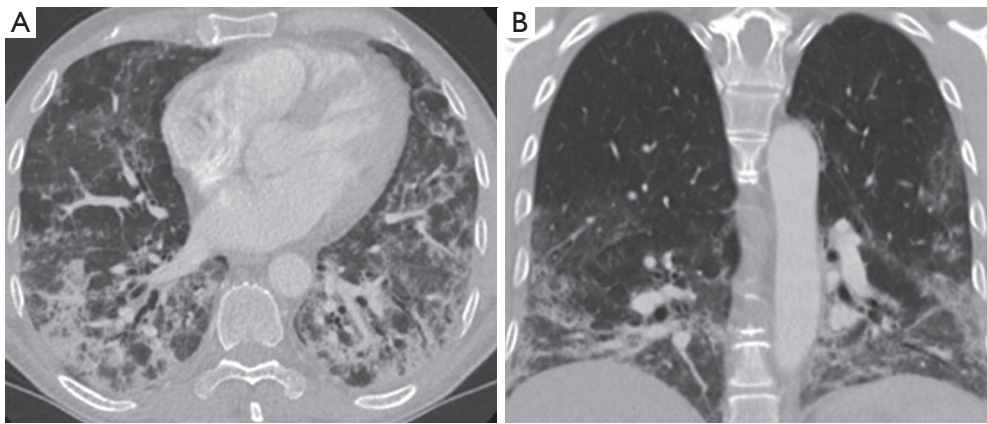


Figure 1 Coronal (A) and axial (B) high resolution computed tomography (HRCT) reconstructions showing a lower lobe predominant interstitial lung disease (ILD) with extensive ground glass infiltrates areas of peri-bronchial consolidation and architectural distortion. The pattern and distribution is most in keeping with non-specific interstitial pneumonitis (NSIP).

lower lobe predominant multi-focal ground glass and reticular infiltrates with scattered regions of peri-bronchial consolidation and a few small scattered sub-5 mm nodules (*Figure 1*). There was no honeycomb change, cavitating lesions and no effusion. A few mildly enlarged mediastinal lymph nodes were noted and considered reactive. The spleen was not enlarged and the bones unremarkable. Overall appearances were most in keeping with non-specific interstitial pneumonitis (NSIP).

The clinical features in conjunction with elevated CK and anti-Ro and anti-Jo-1 positivity and the HRCT findings lead to a presumptive diagnosis of ASS. The patient was commenced on oral corticosteroids and a cyclophosphamide infusion fortnightly for 3 months, ambulatory and nocturnal oxygen. His CK levels gradually reduced and there was a significant improvement in exercise tolerance, oxygen requirements and breathing during this period.

Discussion

ASS is a rare systemic autoimmune syndrome characterized by a combination of interstitial lung disease (ILD), myopathy, fever and polyarthralgia. It has a reported prevalence of 1.5 per 100,000 populations. The hallmark of ASS are antibodies against aminoacyl-transfer RNA synthetase of which the most frequent is the anti-Jo-1 antibody which is present in approximately 80% of cases (1). Less commonly encountered antibodies in ASS are including anti-PL-7 and anti-EJ (2).

ILD is the most frequently occurring manifestation

of ASS being reported in 80-90% of cases and as such lung involvement is considered to be the most important prognostic indicator. Indeed it has been suggested that ASS antibodies should be routinely tested in all patients with ILD, as the clinical presentation of ASS is frequently non-specific in the early stages (3). ILD in ASS is usually apparent on plain chest radiographs but high resolution CT is the imaging technique of choice to characterize the pattern and distribution of disease. Reported HRCT findings in ASS are regions of diffuse patchy ground-glass opacification with a lower lobe and sub-pleural predominance, peri-bronchial consolidations, reticular change and fine nodularity. HRCT is also helpful to exclude the presence of cavitating lesions which are more suggestive of a vasculitic process as well as signs of infective change. NSIP is the most frequently reported histological pattern in ASS and the presence of fibrosis (as opposed to cellular infiltrates) is an adverse predictor for response to immunosuppressive therapies (1-3).

Joint symptoms are reported in around 60% of patients with ASS and are more common in anti-Jo-1 positive ASS patients however they are non-specific and often mimic more common inflammatory arthropathies such as rheumatoid arthritis (1). Myositis is reported in 30-60% of ASS patients and anti-Jo-1 positivity can pre-date clinical myositis (1). Most treatment regimens for ASS describe a combination of glucocorticosteroids and other immunosuppressant such as cyclophosphamide with pulmonary disease response dictating treatment duration (1).

In summary ASS is a rare systemic autoimmune

condition characterized by a combination of ILD, myopathy, fevers and polyarthralgia. HRCT typically shows an NSIP pattern and may help to suggest the diagnosis in a patient presenting with appropriate clinical features.

Acknowledgements

None.

Footnote

Conflicts of Interest: The authors have no conflicts of interest

Cite this article as: Qureshi MA, Hoey E, Fletcher T, Ahmed Z. Antisynthetase syndrome: a case report. Quant Imaging Med Surg 2016;6(2):207-209. doi: 10.21037/qims.2015.11.04

to declare.

References

1. Katzap E, Barilla-LaBarca ML, Marder G. Antisynthetase syndrome. Curr Rheumatol Rep 2011;13:175-81.
2. Solomon J, Swigris JJ, Brown KK. Myositis-related interstitial lung disease and antisynthetase syndrome. J Bras Pneumol 2011;37:100-9.
3. Mielnik P, Wiesik-Szewczyk E, Olesinska M, et al. Clinical features and prognosis of patients with idiopathic inflammatory myopathies and anti-Jo-1 antibodies. Autoimmunity 2006;39:243-7.