

Laparoscopic total gastrectomy with spleen-preserving splenic hilar (No. 10) lymph nodes dissection

Guoxin Li, Tingyu Mou, Yanfeng Hu, Jiang Yu, Hao Liu, Yanan Wang

Department of General Surgery, Nanfang Hospital, Southern Medical University, Guangzhou 510515, China

Corresponding to: Guoxin Li, M.D. Department of General Surgery, Nanfang Hospital, Southern Medical University, No. 1838, North Guangzhou Avenue, Guangzhou 510515, China. Email: gzliguoxin@163.com.

Abstract: Laparoscopic total gastrectomy with spleen-preserving splenic hilar (No. 10) lymph nodes dissection is challenging due to the tortuous splenic vessels and possibility of parenchymal injury to the spleen or pancreas. Based on our anatomical understanding of peripancreatic structures, we combined the characteristics of laparoscopic surgery and developed a strategy using retro-pancreatic approach for laparoscopic spleen-preserving No. 10 lymph nodes dissection.

Key Words: Stomach neoplasm; laparoscopy; lymph node excision; splenic hilar



Submitted May 11, 2013. Accepted for publication May 29, 2013.

doi: 10.3978/j.issn.2224-4778.2013.05.33

Scan to your mobile device or view this article at: <http://www.amepc.org/tgc/article/view/2063/2845>



Guoxin Li

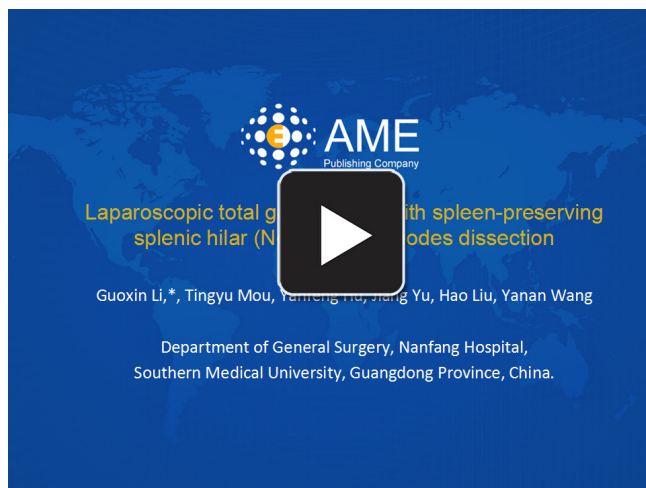
Splenic hilar (No. 10) lymph nodes (LN) metastasis was identified as an important prognostic factor in previous studies for gastric carcinomas (1,2). Dissection of No. 10 LN should be conducted in laparoscopic total gastrectomy with D2 lymphadenectomy for treatment of advanced proximal gastric cancer (3). Traditional No. 10 LN dissection was mainly achieved through combined resection of pancreas and/or spleen. However, due to the increased postoperative morbidity and mortality, spleen-preserving gastrectomy was subsequently suggested (4). In laparoscopic total gastrectomy, spleen-preserving No. 10 LN dissection is challenging and technically demanding and was only reported by a small number of skilled laparoscopic surgeons in high-volume specialized centers (5).

In 2012, a 54-year old male patient with upper abdominal pain was incharged in our department. Gastrofiberoscopy with biopsy identified an adenocarcinoma with a diameter of 9.5 cm located at the middle-third of the stomach near the lesser curvature. Abdominal high-resolution multi-directional computed tomography (CT) showed no distant metastasis, gross involvement of the gastrosplenic ligament or LN number 4sb, at the splenic hilar or along the splenic artery (SA).

The surgery was performed with laparoscopic ultrasonic shears [Laparoscopic Coagulation Shears (LCS); Ethicon Endo-Surgery, Cincinnati, OH] (*Video 1*).

Under general anesthesia, the patient was placed in the supine position with legs set apart in a reverse Trendelenburg position. The surgeon stood on the patient's left side; the assistant surgeon took the patient's right side; and the camera operator stood between the patient's legs. After pneumoperitoneum was established with carbon dioxide insufflated at a pressure of 12 mmHg, five working ports were introduced (6). Exploration of abdominopelvic cavity was conducted to exclude distant metastasis and carcinomatosis.

In this video, the greater omentum was divided along the border of the transverse colon



Video 1 Laparoscopic total gastrectomy with spleen-preserving splenic hilar (No. 10) lymph nodes dissection

toward the inferior pole of the spleen and then rightward toward the duodenum. By dividing the gastrocolic ligament, the lesser sac was entered. The stomach was then overturned cephalad, the right gastroepiploic vein was identified by dissecting the mesogastrium inferior to the gastric antrum off the transverse mesocolon, which was then ligated and divided at its origin. The right gastroepiploic artery was usually identified next to the vein, which was also divided to allow the removal of LN 4d and 6. The gastropancreatic fold could be exposed, and the gastroduodenal artery was located in the groove between duodenum and pancreatic head, which served as a clue to trace the celiac trunk and its branches. By pressing the top of the pancreatic arch, the left gastric vein and artery could be identified, which were both ligated at origin. By following the common hepatic artery, the proper hepatic artery could be traced. The right gastric artery was located in the hepatoduodenal ligament as a small branch running from the proper hepatic artery to supra-pylorus. By ligating the right gastric artery and dissecting the tissues around the proper hepatic, common hepatic artery and celiac trunk, the right side of supra-pancreatic LN (5, 7, 8a, 9, 12a) were removed en-block.

By retracting the pancreas meticulously in the caudal direction, the soft tissue was dissected off the superior margin of the pancreatic body and tail in order to enter the retropancreatic space, thus uncovering the proximal SA. By opening the artery and vein sheath and skeletonizing the SA from proximal portion towards the distal portion, LN 11p could be removed. When the bifurcation was reached, two

secondary branches of the SA could be seen. The superior branch coursed towards the superior pole of the spleen and the inferior one coursed directly towards the splenic hilar. The pancreatic tail was mobilized using the infra-pancreatic approach to re-enter the retropancreatic space. The superior and inferior branches of the SA were then skeletonized until they reached the spleen parenchyma. Meanwhile, the left gastroepiploic vessels and the short gastric vessels originating from the SA were ligated and divided. By skeletonizing the SA, fatty tissues bearing LN 10, 11d, 4sa and 4sb were removed and all vessels in the splenic hilar area were saved with the preservation of the spleen.

The duodenum was transected 2 cm distal to the pylorus using an endoscopic linear stapler (Echelon 60 Endopath Stapler; Ethicon Endo-surgery, LLC, Guaynabo, Puerto Rico 00969, USA). Subsequently, the phrenoesophageal and both vagus nerves were divided and the LN 1 and 2 was dissected. The Roux-en-Y esophagojejunostomy and jejunojunostomy were carried out extracorporeally through a 4-5 cm midline minilaparotomy just below the xiphoid process using a circular stapler and hand-sewing.

The operating time was 201 min and estimated blood loss was 80 mL. Pathological findings suggested the TNM stage was T4aN3M0 (IIIC) according to AJCC cancer staging manual-7th edition. The numbers of total retrieved LN and No. 10 LN were 40 and 4 respectively. The number of total metastatic LN was 15 and there was 0 positive No. 10 LN. Postoperatively, the patient experienced the first flatus on day 4, began oral intake of liquid diet on day 4, semi-liquid diet on day 5 and discharged on day 6. Within 30 days after surgery, no complication was observed. At the last follow-up of 8 months, the patient didn't experience recurrent disease.

In conclusion, laparoscopic total gastrectomy with spleen-preserving splenic hilar lymph nodes dissection through retro-pancreatic approach could be technically safe and feasible. The procedure might be helpful for experienced laparoscopic surgeons to extend the surgical indication to advanced proximal gastric cancers.

Acknowledgements

Disclosure: The authors declare no conflict of interest.

References

1. Yu W, Choi GS, Chung HY. Randomized clinical trial of splenectomy versus splenic preservation in patients with

- proximal gastric cancer. *Br J Surg* 2006;93:559-63.
2. Ohno M, Nakamura T, Ajiki T, et al. Procedure for lymph node dissection around splenic artery in proximal gastric cancer. *Hepatogastroenterology* 2003;50:1173-7.
 3. Japanese Gastric Cancer Association. Japanese gastric cancer treatment guidelines 2010 (ver. 3). *Gastric Cancer* 2011;14:113-23.
 4. Cuschieri A, Weeden S, Fielding J, et al. Patient survival after D1 and D2 resections for gastric cancer: long-term results of the MRC randomized surgical trial. *Surgical Co-operative Group. Br J Cancer* 1999;79:1522-30.
 5. Hyung WJ, Lim JS, Song J, et al. Laparoscopic spleen-preserving splenic hilar lymph node dissection during total gastrectomy for gastric cancer. *J Am Coll Surg* 2008;207:e6-11.
 6. Li GX, Zhang C, Yu J, et al. A new order of D2 lymphadenectomy in laparoscopic gastrectomy for cancer: live anatomy-based dissection. *Minim Invasive Ther Allied Technol* 2010;19:355-63.

Cite this article as: Li G, Mou T, Hu Y, Yu J, Liu H, Wang Y. Laparoscopic total gastrectomy with spleen-preserving splenic hilar (No. 10) lymph nodes dissection. *Transl Gastrointest Cancer* 2013;2(S1):10-12. doi: 10.3978/j.issn.2224-4778.2013.05.33