



# Outcomes after arthroscopic surgery for femoroacetabular impingement with global pincer: a systematic review

Ryan P. Coughlin<sup>1</sup>, Muzammil Memon<sup>1</sup>, Jeffrey Kay<sup>1</sup>, Nicole Simunovic<sup>2</sup>, Andrew Duong<sup>1</sup>, Olufemi R. Ayeni<sup>1,3</sup>

<sup>1</sup>Division of Orthopaedic Surgery, Department of Surgery, <sup>2</sup>Department of Health Research Methods, Evidence and Impact, McMaster University, Hamilton, Ontario, Canada; <sup>3</sup>McMaster University Medical Centre, Hamilton, Ontario, Canada

**Contributions:** (I) Conception and design: OR Ayeni, RP Coughlin, J Kay; (II) Administrative support: All authors; (III) Provision of study materials or patients: All authors; (IV) Collection and assembly of data: RP Coughlin, J Kay, M Memon; (V) Data analysis and interpretation: All authors; (VI) Manuscript writing: All authors; (VII) Final approval of manuscript: All authors.

**Correspondence to:** Olufemi R. Ayeni. McMaster University Medical Centre, 1200 Main St West, 4E15, Hamilton, Ontario L8N 3Z5, Canada. Email: ayenif@mcmaster.ca.

**Abstract:** The purpose of this systematic review was to evaluate the clinical and radiological outcomes, and complications for arthroscopic management of global pincer-type femoroacetabular impingement (FAI). Three databases, PubMed, MEDLINE, and EMBASE, were searched from database inception until September 21, 2017 by two independent reviewers. The inclusion criteria were English language studies that investigated arthroscopic management of global pincer-type FAI, and reported clinical and radiographic outcomes. The Methodologic quality of the studies was assessed using the MINORS (Methodological Index for Non-Randomized Studies) tool. The results are presented in a narrative summary. The search identified 3,176 studies, of which 5 studies (101 patients; mean age, 35.0 years) were included for assessment. We found 1 case report, 2 case series, and 2 retrospective comparative studies, each having level of evidence of IV, IV, and III, respectively. The most commonly reported outcomes were the Modified Harris Hip Score (mHHS), and Non-Arthritic Hip Score (NAHS), which showed mean improvements in pre-operative scores from 53.9 to 80.7, and 50.5 to 79.1, respectively. In studies reporting radiographic correction of lateral center-edge angle (LCEA), the mean improvement from pre- to post-surgery was 48.9° to 37.9°, respectively. There was a 9.3% conversion rate to total hip arthroplasty (THA) at a mean time of 13.1 months post-operatively (mean age of 40.9 years). In conclusion, short-term data suggests that patients with global pincer-type FAI managed with arthroscopic surgery may expect significant improvement in pain and function. Rapid conversion to THA was seen in a notable proportion of patients. While the degree of clinical improvement appears to be of lower magnitude compared to patients with focal overcoverage, this type of osseous deformity is still correctable with arthroscopic treatment by the experienced surgeon.

**Keywords:** Femoroacetabular impingement (FAI); hip arthroscopy; systematic review

Received: 22 December 2017; Accepted: 15 January 2018; Published: 02 March 2018.

doi: 10.21037/aoj.2018.01.05

**View this article at:** <http://dx.doi.org/10.21037/aoj.2018.01.05>

## Introduction

Femoroacetabular impingement (FAI) is a condition in which atypical collision between the proximal femur and acetabulum is caused by abnormal morphology of the hip joint (1). While FAI can be caused by an isolated

deformity to either the acetabulum (Pincer) or the femoral head and neck junction (Cam), the majority of patients present with elements of both structural abnormalities (2). Pincer-type FAI can occur in focal or global forms, each having varying amounts of acetabular overcoverage. Global overcoverage is more generalized affecting both

the anterior and posterior acetabular rims, and can be associated with radiographic signs of a deep hip socket represented by coxa profunda or protrusio acetabuli (3). Protrusio acetabuli is an extreme form of overcoverage in which the femoral head protrudes into the true pelvis (4,5). This condition is defined radiographically as the femoral head extending to or projecting medial to the ilioischial line on an anteroposterior radiograph of the pelvis (6). The acetabulum usually presents with an increased size of the articular surface (7), which is reflected by a lateral center-edge angle (LCEA) classically greater than 39 degrees (8). Protrusio acetabuli with global overcoverage can predispose the young adult to develop hip pain and early osteoarthritis (OA) (9).

Global pincer-type FAI has traditionally been treated with an intertrochanteric valgus osteotomy and medialization of the proximal femur (5,9,10). This procedure acts to reduce the static pressure on the medial joint surface. Biomechanically, however, the dynamic problem of impingement in these hips can remain (4,10). This may explain the limited post-operative success seen with early and midterm surveillance (8,9). Open acetabuloplasty has been attempted to normalize the amount of coverage (10). However, the clinical value of open surgical correction of severe global overcoverage and protrusio has not demonstrated a convincing benefit to patients (11).

Open and arthroscopic management of FAI are equally effective, with the latter showing reduced rates of post-operative complications (12,13). However, the utility for treating global acetabular overcoverage is less understood. Advancement of instrumentation and techniques have broadened the applications of hip arthroscopy to treat complex bony deformities conventionally managed with open surgery (14). There has been no systematic review that has summarized the existing clinical literature on arthroscopic treatment of global pincer-type FAI. Therefore, the purpose of this study was to systematically assess the arthroscopic management of global pincer-type FAI, including clinical and radiological outcomes and complications associated with this procedure. It was hypothesized that arthroscopic treatment of global pincer could provide improvement in pain and function in the short term with minimal rates of complications.

## Materials and methods

The Preferred Reporting Items for Systematic Reviews

and Meta-Analyses (PRISMA) guidelines were followed to evaluate and assess study selection using methodology previously employed by our institution for conducting systematic reviews (15,16).

### Search strategy

A comprehensive literature search on arthroscopic management of global pincer-type FAI was performed using three online databases, PubMed, EMBASE, and Ovid (MEDLINE), from database inception until September 21<sup>st</sup>, 2017. Medical Subject Headings (MeSH) terms and designated free-text terms were incorporated for “arthroscopy”, “femoroacetabular impingement”, “global pincer”, “profunda acetabulae”, “coxa profunda”, “protrusio acetabula”, and “acetabular protrusion” (*Figure S1*).

### Study screening

Two authors (M.M. and J.K.) independently assessed the titles, abstracts, and full-text articles identified by the search strategy. Any disagreements were discussed between reviewers. If no consensus was reached, the senior author (O.R.A.) was available to make the final decision regarding study inclusion. We performed additional citation tracking by screening the reference lists of the eligible studies.

### Assessment of study eligibility

The research question and eligibility criteria were determined a priori. Original articles were included if (I) full text were available in English; (II) studies were conducted on live human subjects; (III) studies were on arthroscopic management of global pincer-type FAI; and (IV) studies of all levels of evidence reported any outcomes including subjective outcomes, radiographic outcomes, complications, and outcome scores. Imaging studies, animal studies, anatomic and histologic studies, surgical technical reports, book chapters and review articles were excluded.

### Data abstraction

Data from original articles were extracted by two reviewers (M.M. and J.K.) into a customized database using a Microsoft Excel spreadsheet (Version 2007, Microsoft, Redmond, WA, USA). Data extraction disagreements were discussed between the two reviewers. If any disagreement was still present, the senior author (O.R.A.) was utilized

to resolve any continued disagreements. Data elements included were year of publication, author, study design, age, gender, number of participants, follow up duration, level of evidence, and outcomes.

### *Quality assessment*

The MINORS (methodological index for non-randomized studies) checklist was used to assess the methodologic quality of the included studies (17). The two reviewers (M.M. and J.K.) thoroughly reviewed the guidelines for grading studies using this index. By use of the MINORS checklist, comparative studies can obtain a maximum score of 24, whereas non-comparative studies can be given a maximum score of 16. A score of 0–8 or 0–12 was considered poor quality for non-comparative and comparative studies, respectively, while a score of 9–12 or 13–18 was considered fair quality, and a score of 13–16 or 19–24 was considered excellent quality. Any disagreements were discussed between the reviewers and a senior author until consensus was reached.

### *Assessment of agreement*

Inter-reviewer agreement for the title, abstract, and full-text articles was calculated with the  $\kappa$  statistic. An intra-class correlation coefficient (ICC) was calculated for the quality assessment using the MINORS criteria. The values were categorized a priori as follows:  $\kappa$ /ICC of 0.61 or greater was considered substantial agreement;  $\kappa$ /ICC of 0.21 to 0.60, moderate agreement; and  $\kappa$ /ICC of 0.20 or less, slight agreement (18).

### *Statistical analysis*

Given the non-uniform nature of the studies included in this systematic review in terms of techniques and outcome reporting, the results are presented in a narrative summary fashion. Descriptive statistics including means, proportions, ranges, kappa values, and ICC values were calculated using Minitab® statistical software (Version 17, Minitab Inc., State College, USA).

## **Results**

### *Search strategy*

The initial search of three databases resulted in 3,176 titles

for screening. A total of 1,270 studies were removed as duplicates, resulting in 1,906 studies available for screening. A systematic screening approach removed articles failing to meet inclusion criteria and resulted in 5 available full-text articles for review (*Figure 1*). There was substantial agreement among reviewers at the title ( $\kappa = 0.827$ ; 95% CI, 0.777 to 0.877), abstract ( $\kappa = 0.843$ ; 95% CI, 0.795 to 0.891), and full-text ( $\kappa = 1.00$ ) screening stages.

### *Study characteristics*

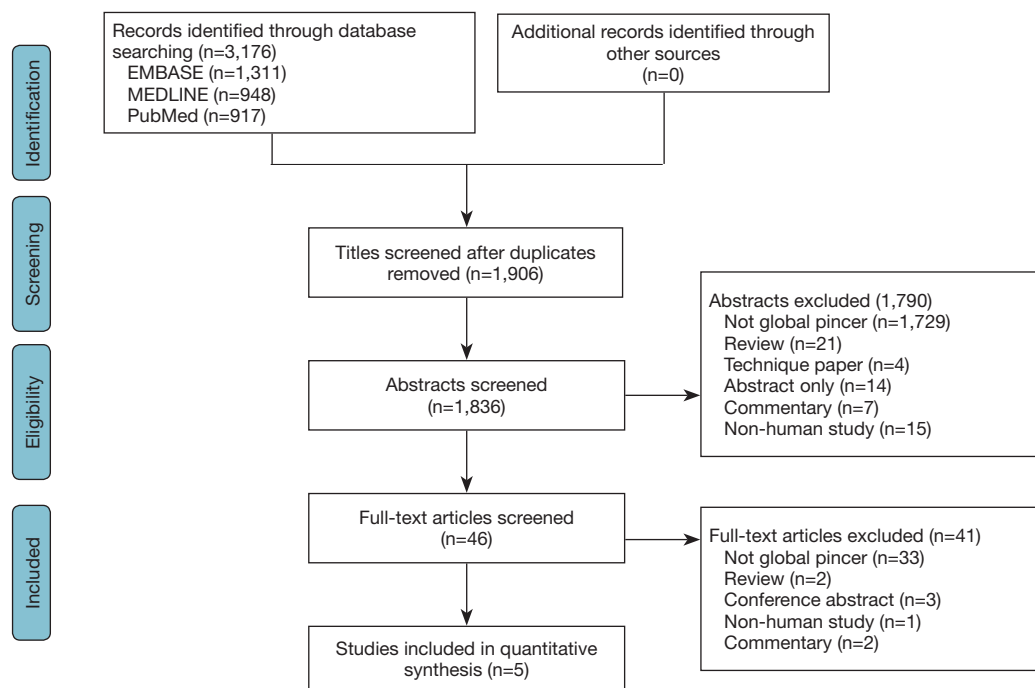
In total, 101 patients (106 hips) with a mean age of 35.0 (range, 15.9 to 55.2) years underwent hip arthroscopy for the management of global pincer-type FAI. Of the included cases, 55.7% were female and they were followed up for a mean of 30.5 (range, 12 to 63) months (*Table 1*).

### *Study quality*

We identified 1 case report, 2 case series, and 2 comparative studies, which had a level of evidence of IV, IV, and III, respectively (*Table 1*). The median MINORS score for the non-comparative studies was 7 out of 16 (range, 6 to 8) demonstrating low quality evidence. Further, the median MINORS score for the comparative studies was 15.5 out of 24 (range, 15 to 16) demonstrating fair quality evidence. Overall, 100% of studies had a clearly stated aim and loss of follow up less than 5%. However, only 40% of studies had unbiased assessment of study endpoints. Overall, there was substantial inter-rater agreement for the MINORS score with an ICC of 0.798 (95% CI, 0.749 to 0.847).

### *Pre-operative diagnoses and management*

Of the 106 cases included in this systematic review, 100 (94.3%) were diagnosed with coxa profunda, while 6 (5.7%) were diagnosed with protrusio acetabula (*Table S1*). Two studies reported a LCEA  $>40^\circ$  as inclusion criteria for global overcoverage (19,20), one study used LCEA  $>35^\circ$  with radiographic signs of coxa profunda (21), one study used LCEA  $\geq 50^\circ$  with radiographic signs of protrusio acetabuli (22), and one case report was of a 33-year-old male with bilateral coxa profunda with a LCEA of  $56^\circ$  on the right hip and  $46^\circ$  on the left hip (23). Plain radiographs were obtained pre-operatively for all 106 cases, including the anteroposterior view,  $45^\circ$  Dunn view, false profile view, and cross-table lateral or frog leg lateral view. Magnetic resonance imaging was obtained in two studies for 48 cases



**Figure 1** PRISMA flow diagram demonstrating the systematic review of the literature for arthroscopic management of global pincer in femoroacetabular impingement.

to assess for the status of the articular cartilage and labrum (21,23). Non-operative measures were reported by 1 study including 4 cases, which included image-guided local anesthetic injections (22).

### Operative procedures and findings

Of the 106 cases included in this review, 106 (100%) underwent acetabuloplasty; 91 (85.9%) underwent femoroplasty; 35 (33.0%) underwent labrum repair; 5 (4.7%) underwent labrum reconstruction; 19 (17.9%) underwent partial or complete labrectomy; 33 (31.1%) underwent chondroplasty, of which 21 (19.8%) were specified as acetabular chondroplasty and 10 (9.4%) were specified as femoral head chondroplasty; 2 (1.9%) underwent acetabular microfracture; 1 (0.9%) underwent femoral head microfracture; 24 (22.6%) underwent ligamentum teres treatment, 10 (9.4%) underwent iliopsoas release; 1 (0.9%) underwent trochanteric bursectomy; and 7 (6.6%) underwent removal of a loose body. Of the 36 cases for which capsular treatment was reported, 20 (55.6%) underwent capsular repair and 16 (44.4%) underwent capsular release. Intraoperative findings were reported by three studies for 42 cases, and they included

the degree of acetabular and femoral head chondral lesions, as graded by the Outerbridge criteria and the acetabular labrum articular disruption grading system. Additionally, the location and sizes of labral injuries were described by these studies. The details are summarized in *Table S1*.

### Outcomes

#### Standardized outcome scores

Of the 3 studies including 86 cases (19,21,22), which reported on Modified Harris Hip Score (mHHS) outcomes, the mean improvement from pre-operative to post-operative scores was 53.9 to 80.7 (*Table S2*). Of the 3 studies including 56 cases (19,20,23), which reported on Non-Arthritic Hip Score (NAHS) outcomes, the mean improvement from pre-operative to post-operative scores was 50.5 to 79.1. With regards to the single study including 36 cases (19), which reported on the Hip Outcome Score Sports-Specific Subscale and Activities of Daily Living Subscale, the mean post-operative scores were 46.0 and 66.3, respectively. With regards to the single study including 46 cases (21), which reported on the Activity of Daily Living Score (ADL), Activity of Daily Living Rating (ADLR), Sports Score, Sports Rating, level of function, and International Hip

**Table 1** Characteristics of included studies and patients

Author (years)	Study design (level of evidence)	MINORS score (mean)	Sample size (patients/hips, n)	Affected side (right/left, n)	Males/females (n)	Age (years, mean, range or SD)	Follow-up time (months, mean, range or SD)
Chandrasekaran 2017	Retrospective Comparative Study, III	16	36/36	23/13	18/18	31.2 (15.9–49.6)	31.5 (21.5–46.2)
Matsuda 2012	Retrospective Case Report, IV	6	1/2	1/1	2/0	33	12
Matsuda 2015	Retrospective Comparative Study, III	15	15/18	NR	12/6	37.2 (18.1–55.2)	Max 60
Safran 2013	Retrospective Case Series, IV	7	3/4	3/1	0/4	31 (26.0–37.0)	48.5 (32.0–63.0)
Sanders 2017	Retrospective Case Series, IV	8	46/46	NR	15/31	42.4 (SD 13.9)	30 (SD 6)

Outcome Tool (IHOT), the mean post-operative scores were 81.5, 81.8, 65.3, 65.9, 14.0, and 69.7, respectively.

### Subjective outcomes

Two studies including 54 cases (19,20), reported on patient satisfaction. In one study, the mean satisfaction at 24 months post-operatively for both the global and focal pincer groups was 4.2 (5-point Likert scale) (20). In another comparative study, the global pincer group has significantly lower patient satisfaction scores compared to the control group with focal pincer: 6.61 versus 7.91 (scale out of 10), respectively ( $P=0.019$ ) (19). Additionally, 2 other studies including 6 cases reported that patients were highly satisfied with their post-operative outcomes (22,23). One study including 36 cases reported a post-operative visual analogue score (VAS) of 5.84 (range 0–10) (19). Additionally, one study including 4 cases reported that all patients returned to work post-operatively (22).

### Radiographic outcomes

One study on global pincer treated arthroscopically reported a mean post-operative LCEA correction of  $28.8\pm 5.3^\circ$  (19). Sanders *et al.* showed a mean pre-operative LCEA of  $39.9\pm 2.4^\circ$  and obtained a mean post-operative correction of  $30.8\pm 1.8^\circ$  (21). Of the 4 studies including 60 cases (19,21–23), which reported on LCEA outcomes, the mean improvement from the pre-operative to post-operative period was  $48.9^\circ$  to  $37.9^\circ$ . Of the 2 studies including 82 cases (19,21), which reported on alpha angle outcomes, the mean improvement from the pre-operative to post-operative radiographs were  $62.3^\circ$  to  $48.1^\circ$ . Of the 2 studies including 82 cases (19,21), which reported on radiographic crossover sign outcomes, the mean prevalence from the pre-operative to post-operative period was 37.8% to 8.5%. One study including 36 cases reported that the percentage of crossover improved from 16.1% preoperatively to 5.0% postoperatively (19). Further, 1 study including 46 studies reported Tönnis angles (21), which improved from  $0.5^\circ$  preoperatively to  $2.3^\circ$  postoperatively. Additionally, 1 study including 36 cases reported acetabular inclination (19), which improved from  $-1.19^\circ$  preoperatively to  $4.46^\circ$  postoperatively. The same study reported that 17 (47.2%) cases had a positive ischial spine sign preoperatively, while 7 (19.4%) cases had a positive ischial spine sign postoperatively.

### Revision procedures and complications

Of the 2 studies including 54 cases (19,22), which reported

on the number of revision arthroscopic procedures, 2 (3.7%) cases underwent revision arthroscopic procedures by a mean time of 6.67 months post-operatively at a mean age of 29 years. Both patients were found to have new labral tears that were repaired and one patient had a full-thickness acetabular cartilage defect treated with microfracture. Of the 2 studies including 54 cases (19,20), which reported on the number of conversions to total hip arthroplasty (THA), 5 (9.3%) cases were converted to THA by a mean time of 13.1 months post-operatively (mean age of 40.9 years). A comparative study between 15 global pincer patients and 125 focal pincer patients showed no significant differences in THA conversion rates (5.5% and 6.2%, respectively) (20). In contrast, Chandrasekaran *et al.* reported that patients undergoing hip arthroscopic surgery for symptomatic global overcoverage and profunda (n=39) had a significantly higher incidence of conversion to THA than the matched cohort with normal coverage (n=39) (4 versus 0 patients) (P=0.040) (19). Of the 106 cases included in this review, there was 1 complication (0.9%), which included transient pudendal neurapraxia lasting 3 months before complete spontaneous resolution.

## Discussion

### Key findings

Overall, five studies evaluating the arthroscopic management of global pincer-type FAI were identified in the literature. Two studies showed significant post-operative improvement in patient-reported outcomes (19,20). Sanders *et al.* only reported mean post-operative functional outcome scores at 2.5 years (21). While there were no pre-operative scores for comparison, the values were similar to previously reported scores for traditional FAI (24-26). It is difficult to know whether the results are generalizable to protrusio acetabuli, the most severe form of global pincer-type FAI. Previous work has suggested that it may act via a different pathomechanism than the much more prevalent coxa profunda (10). A case report and small case series on arthroscopic treatment of protrusio acetabuli have reported successful short-term outcomes (22,23). However, it is important to be mindful that arthroscopic treatment of global acetabular overcoverage presents technical challenges that need to be appreciated by the experienced surgeon.

Sanders *et al.* found that an increased Tönnis OA score was associated with worse functional outcomes following arthroscopically corrected global overcoverage (21). This

is similar to a study of open acetabular rim resection that compared patients with and without protrusio acetabuli (11). The authors found that having a Tönnis OA score  $\geq 1$  was a significant predictor for failure, defined as conversion to THA, progression of OA, and a Merle d'Aubigne-Postel score  $< 15$  at latest follow-up (P=0.001). A recent systematic review concluded that the presence of OA was a strong predictor of poor outcomes following hip arthroscopy (27).

The rate of conversion to THA was poorly reported in studies of arthroscopic global pincer correction. With respect to open procedures, the survival of globally over-covered hips was found to be markedly inferior to focal FAI (11). However, it is important to emphasize that this study only included protrusio acetabuli, thus preventing generalized conclusions. A recent review by Nwachukwu *et al.* comparing open and arthroscopic treatments of classic FAI at a minimum 36-month follow-up reported that the heterogeneity of outcome measures made it difficult to compare treatment groups (28). However, the rates of conversion to THA were 7% and 9.5% for open and arthroscopic groups, respectively (P=0.06). A study of open and arthroscopic treatments of symptomatic global pincer-type FAI is required to facilitate comparisons between both treatment arms.

### Strengths

This was the first paper to systematically review this novel arthroscopic approach to the management of globally over-covered hips. While this paper serves to bring awareness to the rising innovation and new frontiers of hip arthroscopy, it highlights the importance of maintaining evidence-based practice. Our expansive search strategy across multiple databases and broad inclusion criteria ensured that all relevant articles were included. Furthermore, the excellent agreement amongst the two reviewers at all screening stages and quality assessment suggests that a thorough methodology was employed in the preparation of this review.

### Limitations

The methodologic quality in this review is limited by the quantity and quality of studies available on arthroscopic treatment of global pincer-type FAI. The paucity of comparative studies on arthroscopic versus open management of global pincer-type FAI precludes definitive conclusions on their respective indications and relative efficacy. The reporting of data within the studies was

inconsistent, including information regarding pre-operative diagnosis, arthroscopic technique, and clinical outcome scores. Given the difficult learning curve for arthroscopic global pincer correction, there may be expertise bias underlying the favorable outcomes in some studies. Thus, results may not be generalizable to surgeons who are not as familiar with this condition and surgical techniques.

### **Future directions**

There is a current lack of consensus on the radiographic definitions of global and focal pincer morphology. The crossover sign may be seen in both dysplasia (29) and global pincer deformities with some degree of acetabular retroversion (6). Additionally, the relative position of the acetabular fossa to the pelvis may not be indicative of acetabular coverage. One study detected no difference in the LCE angle or acetabular index between hips with and without coxa profunda (30). Future research is needed to improve our understanding of the complex 3-dimensional morphology of acetabular overcoverage, and apply this knowledge to the operating room setting. The lowest recommended limit for anterolateral rim reduction during focal pincer resection is generally a LCEA of 20° (31). However, the amount of surgical correction that should be achieved for the treatment of global overcoverage is not known. A recent CT-based analysis of asymptomatic patients reported a normal CEA of 31°, which offers some idea as to an acceptable target for correction (32). However, there is likely an individualized LCEA value that is needed to maintain proper hip health, with an associated interplay between parameters of acetabular morphology (e.g., coverage, depth, version) and spinopelvic orientation, all of which mutually influence the impact of dynamic loading of the joint. Future directions will define the ideal candidate and the surgical strategies needed to achieve optimal success.

### **Conclusions**

The clinical relevance of this study is that patients with global pincer-type FAI who are managed with arthroscopic surgery may expect significant short-term improvement in pain and function. While the degree of clinical improvement appears to be of lower magnitude and survivorship compared to patients with focal overcoverage, this type of osseous deformity is still correctable with arthroscopic treatment by the experienced surgeon. High

quality studies are needed to better ascertain the ideal indications and methods of achieving successful outcomes.

### **Acknowledgments**

*Funding:* None.

### **Footnote**

*Provenance and Peer Review:* This article was commissioned by the editorial office, *Annals of Joint* for the series “Future Perspectives in Hip Preservation and Arthroscopy”. The article has undergone external peer review.

*Conflicts of Interest:* All authors have completed the ICMJE uniform disclosure form (available at <http://dx.doi.org/10.21037/aoj.2018.01.05>). The series “Future Perspectives in Hip Preservation and Arthroscopy” was commissioned by the editorial office without any funding or sponsorship. RPC served as the unpaid Guest Editor of the series. ORA served as the unpaid Guest Editor of the series and serves as an unpaid editorial board member of *Annals of Joint* from Aug 2017 to Jul 2019. ORA reports that he is a member of the Speakers bureau for Conmed. The authors have no other conflicts of interest to declare.

*Ethical Statement:* The authors are accountable for all aspects of the work in ensuring that questions related to the accuracy or integrity of any part of the work are appropriately investigated and resolved.

*Open Access Statement:* This is an Open Access article distributed in accordance with the Creative Commons Attribution-NonCommercial-NoDerivs 4.0 International License (CC BY-NC-ND 4.0), which permits the non-commercial replication and distribution of the article with the strict proviso that no changes or edits are made and the original work is properly cited (including links to both the formal publication through the relevant DOI and the license). See: <https://creativecommons.org/licenses/by-nc-nd/4.0/>.

### **References**

1. Ganz R, Parvizi J, Beck M, et al. Femoroacetabular impingement: a cause for osteoarthritis of the hip. *Clin Orthop Relat Res* 2003;(417):112-20.
2. Clohisy JC, Baca G, Beaulé PE, et al. Descriptive epidemiology of femoroacetabular impingement: a North

- American cohort of patients undergoing surgery. *Am J Sports Med* 2013;41:1348-56.
3. Larson CM. Arthroscopic management of pincer-type impingement. *Sports Med Arthrosc Rev* 2010;18:100-7.
  4. Liechti EF, Ferguson SJ, Tannast M. Protrusio acetabuli: joint loading with severe pincer impingement and its theoretical implications for surgical therapy. *J Orthop Res* 2015;33:106-13.
  5. Verburg A, Elzenga P. Intertrochanteric valgization osteotomy for treatment of primary protrusion of the acetabulum (Otto-Chrobak pelvis). *Arch Chir Neerl* 1978;30:207-15.
  6. Tannast M, Siebenrock KA, Anderson SE. Femoroacetabular impingement: radiographic diagnosis-what the radiologist should know. *AJR Am J Roentgenol* 2007;188:1540-52.
  7. Steppacher SD, Lerch TD, Gharanizadeh K, et al. Size and shape of the lunate surface in different types of pincer impingement: theoretical implications for surgical therapy. *Osteoarthritis Cartilage* 2014;22:951-8.
  8. Hooper JC, Jones EW. Primary protrusion of the acetabulum. *J Bone Joint Surg Br* 1971;53:23-9.
  9. McBride MT, Muldoon MP, Santore RF, et al. Protrusio acetabuli: diagnosis and treatment. *J Am Acad Orthop Surg* 2001;9:79-88.
  10. Leunig M, Nho SJ, Turchetto L, et al. Protrusio acetabuli: new insights and experience with joint preservation. *Clin Orthop Relat Res* 2009;467:2241-50.
  11. Hanke MS, Steppacher SD, Zurmühle CA, et al. Hips With Protrusio Acetabuli Are at Increased Risk for Failure After Femoroacetabular Impingement Surgery: A 10-year Followup. *Clin Orthop Relat Res* 2016;474:2168-80.
  12. Botser IB, Smith TW Jr, Nasser R, et al. Open surgical dislocation versus arthroscopy for femoroacetabular impingement: a comparison of clinical outcomes. *Arthroscopy* 2011;27:270-8.
  13. Matsuda DK, Carlisle JC, Arthurs SC, et al. Comparative systematic review of the open dislocation, mini-open, and arthroscopic surgeries for femoroacetabular impingement. *Arthroscopy* 2011;27:252-69.
  14. Matsuda DK, Gupta N, Hanami D. Hip arthroscopy for challenging deformities: global pincer femoroacetabular impingement. *Arthrosc Tech* 2014;3:e197-204.
  15. Kay J, de Sa D, Memon M, et al. Examining the Role of Perioperative Nerve Blocks in Hip Arthroscopy: A Systematic Review. *Arthroscopy* 2016;32:704-15.e1.
  16. Moher D, Shamseer L, Clarke M, et al. Preferred reporting items for systematic review and meta-analysis protocols (PRISMA-P) 2015 statement. *Syst Rev* 2015;4:1.
  17. Slim K, Nini E, Forestier D, et al. Methodological index for non-randomized studies (minors): development and validation of a new instrument. *ANZ J Surg* 2003;73:712-6.
  18. Landis JR, Koch GG. The measurement of observer agreement for categorical data. *Biometrics* 1977;33:159-74.
  19. Chandrasekaran S, Darwish N, Chaharbakshi EO, et al. Minimum 2-Year Outcomes of Hip Arthroscopic Surgery in Patients With Acetabular Overcoverage and Profunda Acetabulae Compared With Matched Controls With Normal Acetabular Coverage. *Am J Sports Med* 2017;45:2483-92.
  20. Matsuda DK, Gupta N, Burchette RJ, et al. Arthroscopic surgery for global versus focal pincer femoroacetabular impingement: are the outcomes different? *J Hip Preserv Surg* 2015;2:42-50.
  21. Sanders TL, Reardon P, Levy BA, et al. Arthroscopic treatment of global pincer-type femoroacetabular impingement. *Knee Surg Sports Traumatol Arthrosc* 2017;25:31-5.
  22. Safran MR, Epstein NP. Arthroscopic management of protrusio acetabuli. *Arthroscopy* 2013;29:1777-82.
  23. Matsuda DK. Protrusio acetabuli: contraindication or indication for hip arthroscopy? And the case for arthroscopic treatment of global pincer impingement. *Arthroscopy* 2012;28:882-8.
  24. Gupta A, Redmond JM, Stake CE, et al. Does Primary Hip Arthroscopy Result in Improved Clinical Outcomes?: 2-Year Clinical Follow-up on a Mixed Group of 738 Consecutive Primary Hip Arthroscopies Performed at a High-Volume Referral Center. *Am J Sports Med* 2016;44:74-82.
  25. Philippon MJ, Briggs KK, Yen YM, et al. Outcomes following hip arthroscopy for femoroacetabular impingement with associated chondrolabral dysfunction: minimum two-year follow-up. *J Bone Joint Surg Br* 2009;91:16-23.
  26. Sansone M, Ahldén M, Jonasson P, et al. Good Results After Hip Arthroscopy for Femoroacetabular Impingement in Top-Level Athletes. *Orthop J Sports Med* 2015;3:2325967115569691.
  27. Kemp JL, MacDonald D, Collins NJ, et al. Hip arthroscopy in the setting of hip osteoarthritis: systematic review of outcomes and progression to hip arthroplasty. *Clin Orthop Relat Res* 2015;473:1055-73.
  28. Nwachukwu BU, Rebolledo BJ, McCormick F, et al. Arthroscopic Versus Open Treatment of Femoroacetabular Impingement: A Systematic Review of Medium- to Long-



- Term Outcomes. *Am J Sports Med* 2016;44:1062-8.
29. Troelsen A, Rømer L, Jacobsen S, et al. Cranial acetabular retroversion is common in developmental dysplasia of the hip as assessed by the weight bearing position. *Acta Orthop* 2010;81:436-41.
  30. Anderson LA, Kapron AL, Aoki SK, et al. Coxa profunda: is the deep acetabulum overcovered? *Clin Orthop Relat Res* 2012;470:3375-82.
  31. Espinosa N, Beck M, Rothenfluh DA, et al. Treatment of femoro-acetabular impingement: preliminary results of labral refixation. Surgical technique. *J Bone Joint Surg Am* 2007;89 Suppl 2 Pt.1:36-53.
  32. Larson CM, Moreau-Gaudry A, Kelly BT, et al. Are normal hips being labeled as pathologic? A CT-based method for defining normal acetabular coverage. *Clin Orthop Relat Res* 2015;473:1247-54.

doi: 10.21037/aoj.2018.01.05

**Cite this article as:** Coughlin RP, Memon M, Kay J, Simunovic N, Duong A, Ayeni OR. Outcomes after arthroscopic surgery for femoroacetabular impingement with global pincer: a systematic review. *Ann Joint* 2018;3:14.

## Supplementary

Medline: 948 studies		EmBase: 1,311 studies		PubMed: 917 studies	
Strategy	Studies	Strategy	Studies	Strategy	Studies
1. Arthroscopy/or arthroscop.mp.	32,993	1. Arthroscopic surgery/ or arthroscopy/ or arthroscop.mp.	39,508	1. Arthroscop	32,127
2. Femoroacetabular impingement.mp. or Femoroacetabular Impingement/	2,132	2. Femoroacetabular impingement.mp. or femoroacetabular impingement/	2,832	2. Femoroacetabular impingement	1,923
3. Global pincer.mp.	9	3. Global pincer.mp.	8	3. Global pincer	32
4. Profunda acetabulae.mp.	1	4. Profunda acetabulae.mp.	1	4. Profunda acetabulae	1
5. Coxa profunda.mp.	57	5. Coxa profunda.mp.	75	5. Coxa profunda	114
6. Protrusio acetabula.mp.	7	6. Protrusio acetabula.mp.	5	6. Protrusio acetabula	222
7. Acetabular protrusion.mp.	135	7. Acetabular protrusion.mp.	130	7. Acetabular protrusion	221
8. 2 or 3 or 4 or 5 or 6 or 7	2,282	8. 2 or 3 or 4 or 5 or 6 or 7	2,980	8. 2 or 3 or 4 or 5 or 6 or 7	2,394
9. 1 and 8	948	9. 1 and 8	1,311	9. 1 and 8	917

**Figure S1** Detailed search strategy.

**Table S1** Pre-operative findings and arthroscopic management

Author (years)	History findings	Clinical examination findings, (mean or n, range or SD or %)	Diagnostic imaging modalities	Pre-operative diagnosis	Conservative management	Arthroscopic procedures performed (n, %)	Intra-operative findings (n, %)
Chandrasekaran 2017	NR	Flexion =117.4° (SD=18.5); abduction =44.4° (SD=13.0); internal rotation =44.4° (SD=13.0); external rotation =52.8° (SD=16.8); anterior impingement, n (%) =34 (94.4); posterior impingement, n (%) =12 (33.3); lateral impingement, n (%) =25 (69.4)	Radiographs = anteroposterior pelvic view, 45° Dunn view, false profile view	Coxa Profunda	NR	Labral treatment repair =26 (72.2), debridement =8 (22.2), reconstruction =2 (5.6); capsular treatment repair =20 (55.6), release =16 (44.4); acetabuloplasty =36 (100.0); acetabular microfracture =2 (5.6); acetabular chondroplasty =21 (58.3); acetabular subchondral cyst removal =0 (0.0); femoroplasty =36 (100.0); femoral head microfracture =1 (2.8); femoral head chondroplasty =10 (27.8); ligamentum teres treatment =24 (66.7); iliopsoas release =10 (27.8); trochanteric bursectomy =1 (2.8); removal of loose body =7 (19.4)	Seldes tear: Type 1 =9 (25.0), Type 2 =18 (50.0), Types 1 and 2 =9 (25.0); labral tear size, mean ± SD =3.70±1.24; most posterior clockface location of labral tear, mean ± SD =11.5±1.14; most anterior clockface location of labral tear, mean ± SD =3.0±0.366; acetabular chondral lesion: ALAD Grade 0 =3 (8.3), Grade 1 =10 (27.8), Grade 2 =13 (36.1), Grade 3 =8 (22.2), Grade 4 =2 (5.6); acetabular chondral lesion: outerbridge Grade 0 =4 (11.1), Grade 1 =15 (41.7), Grade 2 =13 (36.1), Grade 3 =2 (5.6), Grade 4 =2 (5.6); femoral head chondral lesion: outerbridge Grade 0 =28 (77.8), Grade 1 =2 (5.6), Grade 2 =3 (8.3), Grade 3 =2 (5.6), Grade 4 =1 (2.8); ligamentum teres tear: intact =2 (5.6), torn =34 (94.4)
Matsuda 2012	Four years of atraumatic, gradually progressive deep anterior groin pain, which was greater on the right side than on the left side, exacerbated by prolonged sitting. Subjective report of inability to fully flex either hip	right hip: flexion =90°, FABER test =3 fist-breadths from the lateral knee to the examination tabletop; left hip: flexion =85°, FABER test =4 fist-breadths from the lateral knee to the examination tabletop; bilateral anterior impingement tests with 0° of internal rotation	Radiographs = AP pelvic; magnetic resonance imaging	Protrusio acetabuli	NR	Right hip: subtotal acetabuloplasty, labral reconstruction, and femoroplasty; left hip: global acetabuloplasty, labral refixation, and femoroplasty	Anterior-to-posterosuperior labrum injury
Matsuda 2015	NR	NR	Plain radiographs	Coxa Profunda	NR	Rim trim =18 (100.0%); labral debridement =8 (44%); labral refixation =8 (44%); labral reconstruction =2 (11%); femoroplasty =17 (94%)	NR
Safran 2013	Hip/groin pain for 2 to 5 years.	Hip flexion range =90° to 110°; internal rotation to only 10°; positive scour sign/labral stress test (n=4); positive impingement test (n=4)	Radiographs = anteroposterior pelvis and cross-table lateral	Protrusio acetabuli	Image-guided local anesthetic injections	Pt 1: acetabuloplasty, chondroplasty, and partial labrectomy; Pt 2: acetabuloplasty, chondroplasty, and partial labrectomy; Pt 3: labrectomy, acetabuloplasty, cheilectomy and osteoplasty of the head-neck junction	Pt 1 right hip: anterior labrum gone. Grade IV chondral damage along anterolateral acetabular rim. Grade III damage along weight-bearing zone and posteroinferior femoral head and acetabulum; Pt 1 left hip: anterior labral tearing. Grade I chondromalacia along anterior and posterior rim but not along weight-bearing portions; Pt 2: anterior and posterior labral tearing. Grade I circumferential chondromalacia extending 2 to 3 mm in from acetabular rim. Grade II posteroinferior acetabular lesion; Pt 3: anterior labral tear. Grade IV chondromalacia of anterolateral and posterolateral femoral head. Grade I chondromalacia of acetabular rim from anterior to posterolateral
Sanders 2017	NR	NR	Radiographs = anterior-posterior pelvis and either a cross table lateral or frog leg lateral view; MRI to assess the status of the articular cartilage and labrum	Coxa profunda	NR	Acetabuloplasty =46; femoroplasty =35; labrum repair	NR

NR, not reported; Pt, patient.

**Table S2** Outcomes following arthroscopic management of global pincer in femoroacetabular impingement

Author (years)	Standardized outcome scores (mean, range or SD)	Subjective outcomes (mean, range or SD)	Radiographic outcomes (mean or n, range or SD or %)
Chandrasekaran 2017	mHHS, post-op =65.8 (SD=15.3); HOS-ADL, post-op =66.3 (SD=21.4); HOS-SSS, post-op =46.0 (SD=26.5); NAHS, post-op =61.3 (SD=22.8)	Satisfaction =6.61/10 (SD=2.95); VAS, post-op =5.84 (SD=2.41)	Pre-op Tonnis, n (%): 0 =27 (75), 1 =6 (17), 2 =3 (8); LCEA: pre-op =45.0° (SD=4.69), post-op =28.8° (SD=5.31); ACEA: pre-op =35.0° (SD=7.52), post-op =34.0° (SD=8.51); acetabular inclination: pre-op =-1.19° (SD=6.29), post-op =4.46° (SD=3.65); crossover sign, n (%): pre-op =18 (50.0), post-op =7 (19.4); ischial spine sign, n (%): pre-op =17 (47.2), post-op =7 (19.4); percentage of crossover: pre-op =16.1 (SD=18.0), post-op =5.0 (SD=14.5); alpha angle: pre-op =63.7° (SD=17.3), post-op =44.6° (SD=23.0)
Matsuda 2012	Pre-op NAHS =34 (right) and 66 (left); post-op NAHS =88 (right hip, at 2 years post-op) and 93 (left hip, at 1 year post-op)	High satisfaction with the clinical outcomes for both hip surgeries; right hip: insignificant improvement in pain and function until 6 months post-op; left hip: improvement in pain and function by 3 months	Preoperative CEA =56° (right) and 46° (left), post-operative CEA =42° (right) and 38° (left); improved anterior femoral offset; no progressive joint narrowing or femoral head medialization; reduction of anterior, posterior, and superior overcoverage
Matsuda 2015	Pre-op NAHS (SD) =51.5 (22.7); 3-month NAHS (SD) =64.2 (19.0); 12-month NAHS (SD) =66.0 (26.4); 24-month NAHS (SD) =74.1 (16.6); 24-month change in NAHS (SD) =22.2 (26.9)	24-month satisfaction (SD) =4.2/5 (1.2)	Pre-op Tonnis, n (%): Tonnis 1 =3 (17%), Tonnis 2 =3 (17%), Tonnis 3 =0 (0.0%); Pre-op outerbridge, n (%): outerbridge class 0 =0 (0.0%), outerbridge class 1 =3 (18%), outerbridge class 2 =1 (6%), outerbridge class 3 =11 (65%), outerbridge class 4 =2 (12%)
Safran 2013	mHHS, pre-op (range) =53.9 (39.6–68); mHHS, post-op (range) =96.75 (87.0–100.0)	All patients returned to work—Pt 1: by 3 weeks after this hip surgery, the patient was extremely happy. Returned to softball and working as a surgical physician's assistant; Pt 2: returned to hiking and technical rock climbing; Pt 3: complained of mild pain after work and with extended activity. Patient was able to bike and use the elliptical trainer for cardiovascular fitness but was not able to run or walk for significantly long periods	Pre-operative CEA (range) =57.75 (50.0–67.0); post-operative CEA (range) =49.75 (42.0–60.0)
Sanders 2017	mHHS, post-op (SD) =79.5 (±20.2); ADL score, post-op (SD) =81.5 (±19.0); ADL rating, post-op (SD) =81.8 (±19.4); sport score, post-op (SD) =65.3 (±31.9); sport rating, post-op (SD) =65.9 (±34.1); level of function, post-op (SD) =14.0 (±12.0); IHOT, post-op (SD) =69.7 (±28.3)	Subjective hip function rating: normal =17, nearly normal =12, abnormal =14, severely abnormal =3	Preoperative CEA (SD) =39.9 (±2.4), post-operative CEA (SD) =30.8 (±1.8); preoperative Tonnis angle (SD) =0.5 (±2.9), post-operative Tonnis angle (SD) =2.3 (±2.7); preoperative Tonnis OA grade =1.0, post-operative Tonnis OA grade =1.0; preoperative alpha angle =60.8° (range: 52–73), post-operative alpha angle =51.5° (range: 43–63); preoperative radiographic crossover sign =25, post-operative radiographic crossover sign =5; preoperative ischial spine sign =20; preoperative coxa profunda =100%; preoperative isolated pincer =11, preoperative pincer and cam-type FAI =35

mHHS, modified Harris Hip Score; NAHS, Non-Arthritic Hip Score; ADL, Activity of Daily Living Score; IHOT, International Hip Outcome Tool; HOS, hip outcome score; VAS, visual analog score; LCEA, lateral center edge angle; ACEA, anterior center edge angle.