



# Pure laparoscopic donor right hepatectomy: brightening the dark side of the moon in the era of space travel

Suk Kyun Hong, Kwang-Woong Lee, Nam-Joon Yi, Kyung-Suk Suh

Department of Surgery, Seoul National University College of Medicine, Seoul, Korea

Correspondence to: Kwang-Woong Lee, MD, PhD. Department of Surgery, Seoul National University College of Medicine, 101 Daehak-ro, Jongno-gu, Seoul 110-744, Korea. Email: kwleegs@gmail.com.

Response to: Pravisani R, Takatsuki M, Baccarani U, *et al.* Pure laparoscopic donor right hepatectomy: exploring the dark side of the moon. *Laparosc Surg* 2018;2:37.

Received: 14 November 2018; Accepted: 27 November 2018; Published: 28 November 2018.

doi: 10.21037/ls.2018.11.07

View this article at: <http://dx.doi.org/10.21037/ls.2018.11.07>

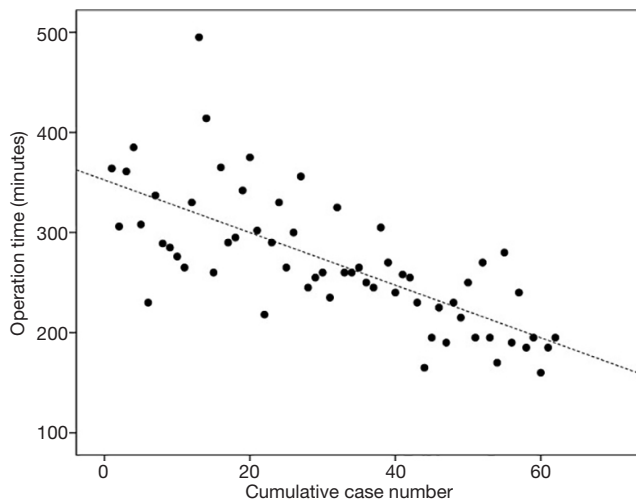
We thank Pravisani *et al.* for their valuable comments on our recent article and for reviewing current perspectives in pure laparoscopic donor right hepatectomy (PLDRH) (1). Our responses to the issues raised are outlined below.

In our center, we have overcome several of the challenges associated with conventional laparoscopic hepatectomy by introducing a 3-dimensional scope system, which provides greater depth perception, and a flexible scope, which enables better space utilization (2-5). An indocyanine green near-infrared fluorescence camera was also used to transect the exact midplane of the liver, providing clear demarcation and optimal bile duct division by real-time cholangiography (6,7). However, obstacles to successful PLDRH remain, such as the caudal view and the use of a fixed port (3). The caudal view may provide an unfamiliar view to surgeons who are accustomed to open hepatic surgery, and the fixed port may restrict movement. It is important to understand these limitations to minimize the learning curve. By June 2018, over 200 PLDRH procedures had been performed in our center by two surgeons. The surgical duration was seen to decrease as the surgeons became accustomed to the caudal view and as the procedure became standardized. This learning curve is illustrated in *Figure 1* (2-4). By the 200<sup>th</sup> PLDRH procedure, the time required to remove the liver and the total surgery time were 90 and 160 minutes, respectively.

For new surgical techniques to become accessible and widely used, and ultimately to be adopted as a new standard of practice, they must be associated with notable benefits and tolerable adverse effects compared with existing

approaches. For donors, the advantages of PLDRH are primarily cosmetic, as the small 1 cm holes at the upper abdomen are hardly visible and suprapubic incision for liver retrieval can be hidden by underwear. Although there are no direct benefits for the recipients, it will be reassuring for them to know that their donors will have good cosmetic and functional outcomes compared with conventional donor right hepatectomy (CDRH).

Prior to the initiation of pure laparoscopic donor hepatectomy in November 2015, we had performed two hand-assisted laparoscopic living donor right hepatectomies, 60 laparoscopy-assisted right hepatectomies, and over 200 procedures with minimal incision (upper midline or transverse incision only). As previously reported, donor satisfaction levels were greater in those undergoing minimal incision versus those undergoing conventional incision (8). Our ongoing study also indicates that donor satisfaction relating to the wound was greater in donors who underwent PLDRH than in those who underwent right hepatectomy under upper midline incision and conventional inverted 'L' incision (9). Moreover, when compared with CDRH, the  $\Delta$ hemoglobin (Hb)% {calculated as  $\Delta$ Hb% = [(preoperative Hb - postoperative Hb)/preoperative Hb] × 100} was significantly lower in the PLDRH group, reflecting a lower degree of blood loss (4). The length of hospital stay, rate of complications, re-hospitalization, and recipient outcomes were similar in both groups. However, the graft quality associated with PLDRH is poorer than that of CDRH; stapling during PLDRH inevitably shortens the length of the graft's hepatic vein and portal vein, and the incidence



**Figure 1** Correlation of operation time and cumulative case number for a single surgeon (Kwang-Woong Lee) ( $\rho=-0.720$ ,  $P<0.001$ ).

of multiple bile duct openings of the graft is higher in PLDRH than CDRH. There were also two cases of hepatic artery thrombosis in recipients, related to problems at the graft side hepatic artery, which were resolved by surgery. A poor quality graft can be salvaged during bench surgery and recipient surgery by an experienced transplant team and is a prerequisite for PLDRH.

Recently, almost 90% of donor hepatectomies (primarily right hepatectomies) undertaken in the Seoul National University Hospital (SNUH) have been performed using the pure laparoscopic method. Increasingly, new potential live donors and potential living donor liver transplant recipients from other centers are requesting a consultation or second opinion from SNUH regarding PLDRH. The proportion of transplant centers performing PLDRH also continues to increase in Korea, as well as other parts of the world. It is, however, important to consider the PLDRH learning curve, which exists even for experienced surgeons (2-4). While we do not consider that prior experience of many hundreds of hepatectomies and transplantations is always required, the key is to shorten the learning curve and ensure the safety of the donor; our recommendations to achieve this are as follows. First, it is important to practice laparoscopic hepatectomy, particularly right hepatectomy for tumor removal, and to simulate the entire PLDRH procedure while considering the differences between right hepatectomy for tumor removal and donor hepatectomy. The main difference is the location and timing of hilar

division, which is more challenging in PLDRH (2,3). Secondly, it is important to select good candidates; in our center, PLDRH was initially performed only in selected donors with no anomalies of the bile duct or portal vein. Accumulated experience and individual procedural standardization is required before the selection criteria can be expanded. Thirdly, we suggest visiting an active laparoscopic donor hepatectomy center where the protocol and procedure will have been standardized; the port insertion site, patient position, and sequence of procedures may differ between centers. It is then possible to observe, learn, and adopt standard practice accordingly.

In conclusion, cosmetic and functional benefits mean that the use of laparoscopic donor hepatectomy is increasing. PLDRH can be widely adopted by minimizing the learning curve of each surgeon and introducing center-specific standardized protocols. In this era of space travel, it is indeed time to brighten the dark side of the moon.

## Acknowledgments

*Funding:* None.

## Footnote

*Provenance and Peer Review:* This article was commissioned by the editorial office, *Laparoscopic Surgery*. The article did not undergo external peer review.

*Conflicts of Interest:* The authors have completed the ICMJE uniform disclosure form (available at <http://dx.doi.org/10.21037/ls.2018.11.07>). The authors have no conflicts of interest to declare.

*Ethical Statement:* The authors are accountable for all aspects of the work in ensuring that questions related to the accuracy or integrity of any part of the work are appropriately investigated and resolved.

*Open Access Statement:* This is an Open Access article distributed in accordance with the Creative Commons Attribution-NonCommercial-NoDerivs 4.0 International License (CC BY-NC-ND 4.0), which permits the non-commercial replication and distribution of the article with the strict proviso that no changes or edits are made and the original work is properly cited (including links to both the formal publication through the relevant DOI and the license).

See: <https://creativecommons.org/licenses/by-nc-nd/4.0/>.

## References

1. Pravisani R, Takatsuki M, Baccarani U, et al. Pure laparoscopic donor right hepatectomy: exploring the dark side of the moon. *Laparosc Surg* 2018;2:37.
2. Lee KW, Hong SK, Suh KS, et al. One Hundred Fifteen Cases of Pure Laparoscopic Living Donor Right Hepatectomy at a Single Center. *Transplantation* 2018;102:1878-84.
3. Hong SK, Lee KW, Choi Y, et al. Initial experience with purely laparoscopic living-donor right hepatectomy. *Br J Surg* 2018;105:751-9.
4. Suh KS, Hong SK, Lee KW, et al. Pure laparoscopic living donor hepatectomy: Focus on 55 donors undergoing right hepatectomy. *Am J Transplant* 2018;18:434-43.
5. Suh KS, Hong SK, Yi NJ, et al. Pure 3-dimensional laparoscopic extended right hepatectomy in a living donor. *Liver Transpl* 2016;22:1431-6.
6. Hong SK, Lee KW, Kim HS, et al. Optimal bile duct division using real-time indocyanine green near-infrared fluorescence cholangiography during laparoscopic donor hepatectomy. *Liver Transpl* 2017;23:847-52.
7. Hong SK, Suh KS, Kim HS, et al. Pure 3D laparoscopic living donor right hemihepatectomy in a donor with separate right posterior and right anterior hepatic ducts and portal veins. *Surg Endosc* 2017;31:4834-5.
8. Suh SW, Lee KW, Lee JM, et al. Clinical outcomes of and patient satisfaction with different incision methods for donor hepatectomy in living donor liver transplantation. *Liver Transpl* 2015;21:72-8.
9. Lee JM, Lee KW, Hong SK, et al. Donor wound satisfaction after living donor liver transplantation in the era of pure laparoscopic donor hepatectomy. *Transplantation* 2018;102:S896.

doi: 10.21037/ls.2018.11.07

**Cite this article as:** Hong SK, Lee KW, Yi NJ, Suh KS. Pure laparoscopic donor right hepatectomy: brightening the dark side of the moon in the era of space travel. *Laparosc Surg* 2018;2:67.