

©2004, Acta Pharmacologica Sinica
Chinese Pharmacological Society
Shanghai Institute of Materia Medica
Chinese Academy of Sciences
<http://www.ChinaPhar.com>

Inhibitory effect of tea polyphenols on transforming growth factor- β 1 expression in rat with cyclosporine A-induced chronic nephrotoxicity

Shao-hua SHI¹, Shu-sen ZHENG, Chang-ku JIA, You-fa ZHU², Hai-yang XIE³

Department of Hepatobiliary Surgery, the First Affiliated Hospital, Medical College, Zhejiang University; ²Department of Pathology, Medical College, Zhejiang University; ³Institute of Surgery, Zhejiang University, Hangzhou 310003, China

KEY WORDS tea; cyclosporine A; transforming growth factor- β ; kidney; polymerase chain reaction; immunohistochemistry; Western blotting

ABSTRACT

AIM: To investigate the inhibitory effect of tea polyphenols (TP) on the transforming growth factor- β 1 (TGF- β 1) expression in rat model of cyclosporine A (CsA)-induced chronic nephrotoxicity. **METHODS:** The rat model of CsA-induced chronic nephrotoxicity was used, 4 groups of rats were respectively treated with vehicle (0.1 mL \cdot kg⁻¹·d⁻¹ sc), TP (80 mg \cdot kg⁻¹·d⁻¹ ig), CsA (15 mg \cdot kg⁻¹·d⁻¹ sc) and TP plus CsA (CsA 15 mg \cdot kg⁻¹·d⁻¹ sc+TP 80 mg \cdot kg⁻¹·d⁻¹ ig). At the end of day 28 of treatment, serum and urine are analyzed for creatinine clearance, kidney tissue for pathologic analysis. The TGF- β 1 mRNA and its protein expression were detected by RT-PCR, immunohistochemistry, and Western blot. **RESULTS:** CsA-treated rats had increased renal expression of TGF- β 1 mRNA and its protein, compared with the vehicle- or TP- treated controls. The renal function and interstitial fibrosis were ameliorated and renal expression of TGF- β 1 mRNA and its protein was decreased in animals treated with CsA plus TP, compared with animals treated with CsA alone ($P < 0.05$). **CONCLUSION:** TP significantly inhibits renal expression of TGF- β 1 in rat model of cyclosporine-induced chronic nephrotoxicity, suggesting that the decreased renal expression of TGF- β 1 exerted by TP is one of mechanisms to protect renal function and tissue structure.

INTRODUCTION

Cyclosporine A (CsA) is the main immunosuppressive agent in the organ transplantation, and its clinical impact is much enormous. Short-term (ex:1-year) kidney, heart, liver, lung, and pancreas allograft survival rates have been greatly improved since the clinical use of CsA. One-year hepatic allograft survival rates now approach or surpass 80 %, when compared with

the survival rates of 30 %-50 % before clinical CsA use. However, the long-term viability of both renal and nonrenal allograft has not shown similar improvement. At present five-year liver allograft survival rates are 60 % or less^[1-3]. Clinical retrospective analysis has indicated that calcineurin inhibitor-based immunosuppressant such as CsA and FK506 treatment is associated with a variety of side effects, especially their chronic nephrotoxicity that can shorten the long-term survival rates of allografts and patients^[1,2]. The mechanisms leading to chronic nephrotoxicity of calcineurin inhibitor are not clear. The following factors are associated with chronic nephrotoxicity: transforming growth factor- β 1 (TGF-

¹ Correspondence to Dr Shao-hua SHI.

Phn 86-571-8723-6570.

Received 2002-10-16

Accepted 2003-05-12

β 1), angiotensin II, nitric oxide (NO), reactive oxygen species (ROS), thromboxane A₂ (TXA₂), and leukotriene (LT). TGF- β 1 plays an important role in the progressive interstitial fibrosis in the chronic CsA nephrotoxicity^[2]. CsA increases free radical formation in the process of CsA nephrotoxicity. Vitamin E significantly suppresses CsA-induced lipid peroxidation and improves glomerular filtration rate and reduces renal fibrosis^[4]. The treatment of adenovirus to express superoxide dismutases significantly blocks formation of ROS and minimizes pathological alterations and inhibition of renal function caused by CsA^[5]. Tea polyphenols (TP), as potent antioxidant, can neutralize free oxygen radicals such as O₂^{·-}, OH[·] *in vitro* and *in vivo*^[6]. TP effectively attenuates the acute nephrotoxicity induced by CsA, which is contributed to the antioxidant properties of TP^[7]. The purpose of this study was to determine whether TP could reduce the chronic CsA nephrotoxicity, and the expression of TGF- β 1 in tubular and interstitial cells in the rat model of CsA-induced chronic nephrotoxicity.

MATERIALS AND METHODS

Experimental design Forty adult male Sprague-Dawley rats weighing (200-230 g) were obtained from the Center of Experimental Animals, Zhejiang University. They were housed in individual cages and received a low-salt diet (0.049 % sodium, measured by flame photometer in the Zhejiang Provincial Center of Disease Control and Prevention). After one week on the low-salt diet, weight-matched pairs of rats were randomly divided into 4 groups. Group 1: rats ($n=10$) were administered vehicle olive oil 1.5 mL·kg⁻¹·d⁻¹ sc (subcutaneous injection). Group 2: rats ($n=10$) were gavaged with TP 80 mg·kg⁻¹·d⁻¹. Group 3: rats ($n=10$) were received CsA 15 mg·kg⁻¹·d⁻¹ sc. Group 4: rats ($n=10$) were treated with CsA 15 mg·kg⁻¹·d⁻¹ sc plus TP 80 mg·kg⁻¹·d⁻¹ ig. TP was gifted by YANG Xian-Qiang (Institute of Tea Science, Zhejiang University). CsA was purchased from Sandoz Company. Body weight was recorded daily. Ten rats of each group were treated for 28 d. At the end of treatment period, 24-h urine samples were collected in metabolic cages. After opening the abdomen through a middle incision under the anesthesia with ketamine, 2 mL blood was taken from inferior vein cava and serum was harvested immediately by centrifugation at 4 °C and stored at -70 °C until use. The aorta was cannulated retrogradely below the renal arteries with a

9-gauge needle. After the left renal aorta was occluded by ligation and the right renal veins were opened by a small incision for outflow, the kidneys were perfused with 20 mL of cold and heparinized saline (contained heparin 500 IU). The kidneys were removed. The cortex was carefully dissected from the medulla. The TGF- β 1 mRNA and its protein expression was assayed by RT-PCR, immunohistochemistry, and Western blot.

Functional studies Creatinine of urinary and serum, were measured by Biochemical Autoanalyzer (model 7170, HITACHI). The creatinine clearance (Ccr) was calculated using standard formulae. CsA blood levels after 4-h administration were determined in whole blood by monoclonal radioimmunoassay.

Morphology Tissue samples were fixed in 10 % buffered formalin and embedded in paraffin. Sections at 4 μ m were stained with hematoxylin and eosin, and Masson trichrome. Findings ascribed to tubular injury included cellular vacuolization, tubular collapse, tubular distention, and hyalinization of afferent arterioles. For tubular injury, the following semiquantitative score was utilized^[8]: 0=no tubular injury, 0.5=<5% of tubules injured, 1=5 % to 20 %, 1.5=21 % to 35 %, 2=36 % to 50 %, 2.5=51 % to 65 %, and 3=>65 %. The findings of interstitial fibrosis consisted of matrix-rich expansion of the interstitium with distortion, collapse of the tubules, and thickening of the tubular basement membranes. Interstitial fibrosis was estimated by counting the percentage of injured areas per field and was scored semiquantitatively using the following^[8]: 0=normal interstitium, 0.5=<5 % of areas injured, 1=5 % to 15 %, 1.5=16 % to 25 %, 2=26 % to 35 %, 2.5=36 % to 45 %, and 3=>45 %.

TGF- β 1 mRNA expression by RT-PCR The primers were designed by computer assistance according to the gene bank. TGF- β 1: forward, 5'-ACTGATACGCCTGAGTGGCTGT-3'; reverse, 5'-CTCTGTGGA-GCTGAAGCAGTAG-3', the size of amplified fragment is 303 bp. Internal control GAPDH: forward, TGGCAGTCAAGGCTGAGA; reverse, CTTCTGAGTGGCAGTGATGG; the size of amplified fragment is 387 bp. Total RNA from each sample was isolated using TRIzol solution (Gibco Inc, USA). Total RNA was quantified with the ratio of absorption values of RNA samples at 260 nm and 280 nm. For each sample, 4 μ g of total RNA was reverse transcribed into first strand of cDNA in 20- μ L reaction system at 37 °C for 50 min. Then polymerase chain reaction was performed from the synthesized cDNA in a 50 μ L solution containing 3

μL of cDNA, 1 μL of 25 mmol primers (up-stream and down-stream) of TGF-β1, 0.5 μL of 25 mmol primers (up-stream and down-stream) of GAPDH, 10 mmol dNTP 1 μL, 25 mmol MgCl₂ 4 μL, 10×buffer 5 μL, 0.3 μL of *Taq* DNA polymerase (Promega). Amplification was performed in a thermal cycler (MJ Research Co, USA) under the following conditions: 26 cycles of denaturation at 94 °C for 50 s, annealing at 59 °C for 45 s, extension at 70 °C for 40 s, followed by a final extension for 5 min. PCR product 10 μL was electrophoresed on a 1.5 % agarose gel, and stained with EB. The TGF-β1 mRNA level in each sample was semi-quantified by comparing the intensities of TGF-β1 mRNA band with those of the internal control GAPDH band.

Immunohistochemistry Formalin-fixed tissues were paraffin-embedded and cut into 4-μm sections. The sections were deparaffinized in xylene and rehydrated in graded ethanol to PBS. After blocking endogenous peroxidase activity with 3 % H₂O₂/methanol (1/32 vol/vol) for 10 min. Tissue sections was boiling for the antigen epitope retrieval in 0.1 mol/L citrate buffer (pH 6.0) for 10 min, the tissue sections were then interacted overnight at 4 °C with the 1:200 diluted primary rabbit anti-rat TGF-β1 antibodies (Santa Cruz Biotechnology), controls were incubated with the normal rabbit serum and the PBS instead of primary antibodies. After ample washings with PBS, the slides were incubated for 30 min with EnVision+horseradish peroxidase-labeled secondary antibody goat anti-rabbit IgG (Dako Company) at room temperature, again washed extensively in PBS. The slides were then developed in diaminobenzidine for 2-5min and rinsed with water. The slides were then counterstained with haematoxylin. A minimum of 20 randomly selected areas per sample were observed at ×400 magnification. The intensity of staining for the glomerular, tubulointerstitial, and vascular compartments was evaluated by an observer blinded to the treatment groups using the following semiquantitative scale: 0=diffuse, very weak, or absent staining, 1=staining involving less than 25 %, 2=25 %-50 %, 3=50 %-75 %, 4=70 %-100 %. Photographs were obtained at identical exposure and development time intervals.

Western blot analysis Protein extracts were prepared by homogenizing the 500 mg renal cortex or 500 mg medulla respectively in cold 1.5 mL RIPA buffer containing 1 % Nonidet P-40 (Amaresco), 0.5 % sodiumdeoxycholate (Sigma), 0.1 % sodium dodecyl sulfate (Amaresco), 15 μg phenylmethylsulfonyl fluo-

ride (Sigma), and 45 U aprotinin (Sigma) with a glass tissue homogenizer. The tissue homogenates were centrifuged at 10000×g 4 °C for 10 min. The supernatants were collected and centrifuged at 10000×g, 4 °C for 10 min again. Protein concentration in the supernatant was determined by Bradford method. 2×Loading buffer (Tris HCl 42 mmol/L, 10 % glycerol, 2.3 % sodium dodecyl sulfate, 5 % 2-mercaptoethanol, and 0.002 % bromophenol blue) was then added to each supernatant with equal volume containing equal amounts of protein, which was subsequently boiled for 3 min and then electrophoresed on a SDS-polyacrylamide gel. Proteins were transferred to nitrocellulose and incubated sequentially with rabbit anti-rat TGF-β1 (Santa Cruz Biotechnology), and then with peroxidase-conjugated secondary antibody (Santa Cruz Biotechnology) in the second reaction. Detection was performed with enhanced chemiluminescence reagent (Santa Cruz Biotechnology).

Statistical analysis Results are presented as mean±SD. Analysis of variance (ANOVA), Kruskal-Wallis test, and Tukey method were used by SAS8.0 statistical software. The level of statistical significance was chosen as $P<0.05$.

RESULTS

Physiologic studies Animals treated with CsA and CsA plus TP failed to gain body weight when compared with those receiving vehicle and TP at d 28 ($P<0.05$). The glomerular filtration rate (C_{cr}) was lower in the CsA-treated rats compared with (CsA+TP)-treated group at d 28 ($P<0.05$, Tab 1). There was no statistical difference in whole blood CsA level between CsA-treated animals and (CsA+TP)-treated animals (Tab 1).

Histological changes CsA-treated rats had characteristic morphologic changes similar to the chronic human lesion, mostly evident at 15 mg·kg⁻¹·d⁻¹ for 28 d. Tubular injury consisted of cellular and intercellular vacuolization, tubular collapse, and tubular dilation. Striped interstitial fibrosis was present with thickening of the tubular basement membranes and Bowman's capsule. Both tubular injury and tubulointerstitial fibrosis were improved in (CsA+TP)-treated group when compared with CsA-treated group at d 28 ($P<0.05$, Tab1).

Expression of TGF-β1 mRNA by RT-PCR TGF-β1 mRNA was markedly increased by d 28 ($P<0.05$) in the CsA-treated rats when compared with con-

Tab 1. Changes in cyclosporine A (CsA) whole blood level, serum creatinine clearance, and semiquantitative scores of tubular injury and tubulointerstitial fibrosis in the experimental groups at d 28. ^b*P*<0.05 vs (CsA+TP)-treated group.

| Groups | CsA whole blood level/ $\mu\text{g}\cdot\text{L}^{-1}$ | Creatinine clearance/ $\text{mL}\cdot\text{min}^{-1}\cdot\text{kg}^{-1}$ | Tubular injury (0-3+) | Interstitial fibrosis (0-3+) |
|--------|---|---|--------------------------|---------------------------------|
| VH | | 3.0 ± 0.8 | 0.55 ± 0.21 | 0.30 ± 0.11 |
| TP | | 2.9 ± 0.5 | 0.45 ± 0.21 | 0.35 ± 0.14 |
| CsA | 2418 ± 210 | 1.2 ± 0.3^b | 2.3 ± 0.4^b | 2.83 ± 0.20^b |
| CsA+TP | 2370 ± 245 | 2.2 ± 0.2 | 1.42 ± 0.26 | 1.46 ± 0.19 |

VH: vehicle olive oil $1.5 \text{ mL}\cdot\text{kg}^{-1}\cdot\text{d}^{-1}$ sc; TP: tea polyphenols $80 \text{ mg}\cdot\text{kg}^{-1}\cdot\text{d}^{-1}$ ig; CsA: cyclosporine A $15 \text{ mg}\cdot\text{kg}^{-1}\cdot\text{d}^{-1}$ sc; CsA+TP: CsA $15 \text{ mg}\cdot\text{kg}^{-1}\cdot\text{d}^{-1}$ sc+TP $80 \text{ mg}\cdot\text{kg}^{-1}\cdot\text{d}^{-1}$ ig.

trol vehicle and TP-treated rats. But expression of TGF- β 1 mRNA in both cortex and medulla in (CsA+TP) group was lower than that in CsA-treated group by d 28 (*P*<0.05, Fig 1).

Expression of TGF- β 1 by immunohistochemistry Expression of TGF- β 1 by immunohistochemistry was mainly present at tubular cells, interstitial cells, and Bowman's capsule. The total amount of TGF- β 1 expression was reduced in the kidneys of (CsA+TP)-treated rats as compared to CsA-treated rats at d 28 (*P*<0.05, Fig 2). In the control groups the expression of TGF- β 1 protein was very weak.

Expression of TGF- β 1 by Western blot analysis The total amount of TGF- β 1 protein expression in both cortex and medulla was inhibited in CsA plus TP-treated group by 28 d (*P*<0.05), when compared with the CsA-treated group. In the control group the expression of TGF- β 1 protein was very weak (Fig 3).

DISCUSSION

We examined an experimental model of chronic CsA nephrotoxicity with pathologic features similar to the human lesion characterized by tubular atrophy, progressive striped interstitial fibrosis with loss of cellularity in areas of fibrosis, afferent arteriole hyalinization and glomerulosclerosis^[2,8]. In our experiment CsA promoted the total protein expression of renal tissue TGF- β 1 which was mainly expressed in tubular and interstitial cells. Antioxidant TP inhibited the CsA-induced TGF- β 1 expression and interstitial fibrosis. Bioprotic tis-

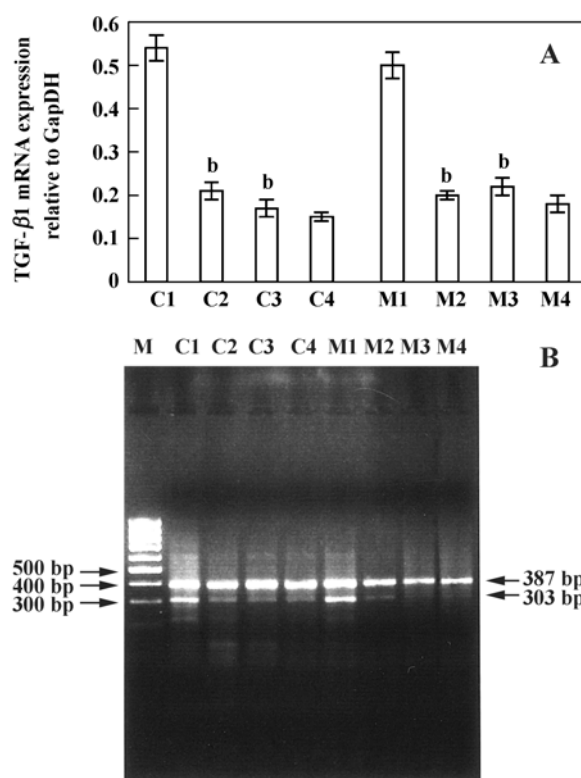


Fig 1. TGF- β 1 mRNA expression in the kidney. A) The expression of TGF- β 1 mRNA relative to GAPDH detected by RT-PCR in vehicle, tea polyphenols (TP), cyclosporine A (CsA), and (CsA+TP)-treated rats. B) Quantitation of mRNA expression of TGF- β 1. C and M are representative of cortex and medulla, respectively. C1-C4 indicates tissues taken from cortex of rats treated by CsA, CsA+TP, TP, and vehicle respectively. M1-M4 indicates tissues taken from medulla of rats treated by CsA, CsA+TP, TP, and vehicle, respectively. The expression of mRNA was significantly increased in both cortex and medulla in the CsA group by d 28. ^b*P*<0.05 vs CsA+TP group.

sues taken from renal allografts with CsA nephrotoxicity are detected by immunohistochemistry that TGF- β 1 expression is also mostly concentrated in tubular cells^[9]. CsA in a dose-dependent manner stimulates expression of TGF- β 1 protein and steady-state mRNA levels in both proximal tubular cells and tubulointerstitial fibroblasts^[10]. TGF- β 1 mimics and anti-TGF- β 1 antibody or soluble TGF- β II receptor abrogates the chronic nephrotoxicity of CsA *in vivo*. TGF- β 1 promotes fibronectin and collagen synthesis^[11,12]. These data suggest that TGF- β 1 play an important role in mediating CsA chronic nephrotoxicity.

The mechanisms by which antioxidant TP inhibits the TGF- β 1 expression in CsA-induced chronic nephrotoxicity may be the following: (1) TP increases tissue

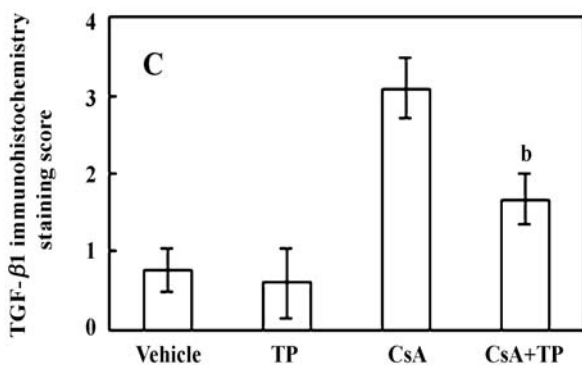
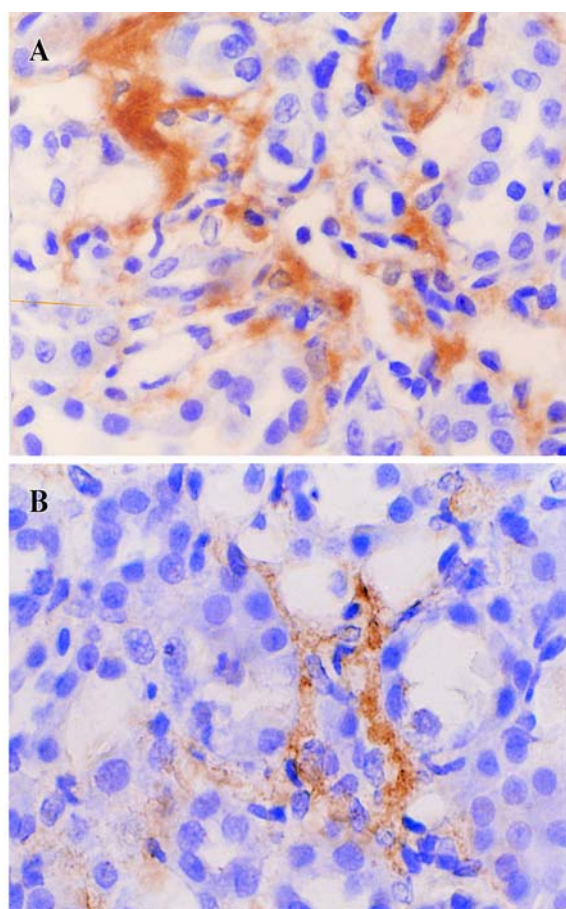


Fig 2. Expression of transforming growth factor- β 1 (TGF- β 1) by immunohistochemistry assay. Photomicrograph (A) showed that cyclosporine A (CsA) 15 mg·kg⁻¹·d⁻¹ sc induced great expression of TGF- β 1. (B) In rats treated with CsA 15 mg·kg⁻¹·d⁻¹ sc+TP 80 mg·kg⁻¹·d⁻¹ ig showed mild to moderate staining ($\times 600$). (C) Pathological semiquantitative scores for TGF- β 1 expression. ^b*P*<0.05 vs the CsA-treated group.

bioactivity of superoxide dismutase and glutathione peroxidase which can inactivate free oxygen radicals such as O₂⁻. Because O₂⁻ can react with NO by forming ONOO₂⁻ to lose bioactivity of NO, TP may reduce nitric oxide (NO) loss and maintain NO physical func-

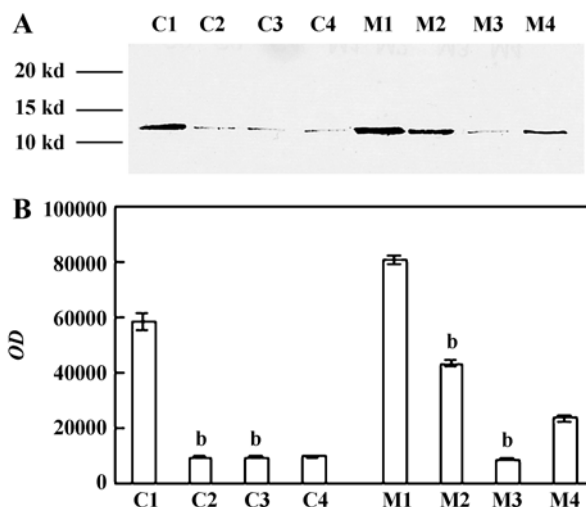


Fig 3. TGF- β 1 expression in the kidney by Western blot. A) TGF- β 1 expression in cortex and medulla of rat kidneys. B) Quantitative scoring of TGF- β 1 expression. C and M are representative of cortex and medulla, respectively. C1-C4 indicates tissues taken from cortex of rats treated by CsA, CsA+TP, TP, and vehicle, respectively. M1-M4 indicates tissues taken from medulla of rats treated by CsA, CsA+TP, TP, and vehicle, respectively. ^b*P*<0.05 vs the CsA-treated group.

tion^[7,13]. In the experiment of chronic CsA nephrotoxicity, *N*-nitro-*L*-arginine-methyl ester (*L*-NAME) as the NO synthase inhibitor, strikingly worsens the glomerular filtration rate and the CsA-induced fibrosis, and up-regulates expression of TGF- β 1, plasminogen activator inhibitor-1 (PAI-1); *L*-arginine, as the substrate for NO synthase, has the opposite beneficial effect^[14]. (2) TP may inhibit the synthesis of TXA₂ and LT which are mediated by CsA-induced lipid peroxidation. CsA induces the glomerular synthesis of O₂⁻, H₂O₂, malondialdehyde. Vitamin E minimizes the adverse effects of CsA on kidney function and the glomerular synthesis of these compounds^[15]. The treatment of adenovirus to express superoxide dismutase significantly blocks formation of ROS and minimizes pathological alterations and inhibition of renal function caused by CsA^[5]. CsA can promote the expression of cyclooxygenase I (COX I), which was completely inhibited by vitamin E in chronic CsA nephrotoxicity^[16]. COX I can promote the synthesis of TXA₂. F₂-isoprostane produced by a noncyclooxygenase mechanism involving lipid peroxidation, as a potent preglomerular vasoconstrictor acting principally through the interaction with TXA₂ receptor, also may be involved in the CsA nephrotoxicity by CsA lipid peroxidation^[17]. The synthesis of leukotrienes (LT)

which are produced by the 5-lipoxygenase pathway is caused by the CsA-induced lipid peroxidation. Peptidoleukotriene as one kind of LT can stimulate fibroblast proliferation and extracellular matrix synthesis. LT receptor antagonist can largely block the CsA-induced renal vasoconstriction and morphological impairment^[18]. Treatment with TXA₂ receptor antagonist GR32191 has a similar effect as thromboxane inhibitors in CsA nephrotoxicity^[19]. (3) The potent vasoconstriction effects of TXA₂ and LT contribute to the activation of the renin-angiotensin system. Angiotensin II can cause the excessive expression of TGF-β1 and osteopontin which are associated with renal interstitial fibrosis. Osteopontin is also a macrophage chemoattract^[20]. There are intrarenal angiotensin II deposits and excessive expression of angiotensin II type I receptor in renal medulla^[21]. Angiotensin II type I receptor antagonist losartan can markedly reduce the degree of CsA-induced tubulointerstitial fibrosis, and the expression of TGF-β1 and osteopontin^[22].

These data suggested that antioxidant TP significantly ameliorated CsA-induced chronic nephrotoxicity and inhibited the expression of TGF-β1 in CsA-induced chronic nephrotoxicity.

REFERENCES

- Shihab FS. Cyclosporine nephropathy: pathophysiology and clinical impact. *Semin Nephrol* 1996; 16: 536-47.
- Campistol JM, Sacks SH. Mechanisms of nephrotoxicity. *Transplantation* 2000; 69: S5-10.
- Wayne-Flye M. Principles of organ transplantation. In: Shaw BW, Starzl TE, Zwatsuki S, *et al*. An overview of orthotopic transplantation of the liver. Saunders WB Company; 1989. p 347-363.
- Wang C, Salahudeen AK, McClain M, Whitehead J. Lipid peroxidation accompanies cyclosporine nephrotoxicity: effects of vitamin E. *Kidney Int* 1995; 47: 927-34.
- Zhong Z, Connor HD, Yin M, Wheeler MD, Mason RP, Thurman RG. Viral delivery of superoxide dismutase gene reduces cyclosporine A-induced nephrotoxicity. *Kidney Int* 2001; 59:1397-404.
- Zhao BL, Liu SL, Chen YS, Xin WJ. Scavenging effect of catechin on free radicals studied by molecular orbital calculation. *Acta Pharmacol Sin* 1992; 13: 9-13.
- Shi SH, Zheng SS, Xie HY. Tea polyphenols protect against cyclosporine-induced acute nephrotoxicity in rats. *Chin J Organ Transplant* 2001; 22: 271-3.
- Shihab FS, Andoh TE, Tanner AM, Noble NA, Border WA, Franceschini N, *et al*. Role of transforming growth factor-beta1 in experimental chronic cyclosporine nephropathy. *Kidney Int* 1996; 49: 1141-51.
- Pankewycz OG, Miao L, Isaacs R, Guan J, Pruett T, Haussman G, *et al*. Increased renal tubular expression of transforming growth factor beta in human allografts correlates with cyclosporine toxicity. *Kidney Int* 1996; 50: 1634-40.
- Wolf G, Thaiss F, Stahl RA. Cyclosporine stimulates expression of transforming growth factor-beta in renal cells. Possible mechanism of cyclosporine antiproliferative effects. *Transplantation* 1995; 60: 237-41.
- Khanna AK, Cairns VR, Becker CG, Hosenpud JD. Transforming growth factor (TGF)-beta mimics and anti-TGF-beta antibody abrogates the *in vivo* effects of cyclosporine: demonstration of a direct role of TGF-beta in immunosuppression and nephrotoxicity of cyclosporine. *Transplantation* 1999; 67: 882-9.
- Jernigan S, Wing D, Schnaper HW. Effects of chronic blockade with soluble TGF-β II receptor in rats with overload proteinuria. *J Am Soc Nephrol* 1999; 10: 537A (abstract).
- Wolin MS. Interactions of oxidants with vascular signaling systems. *Arterioscler Thromb Vasc Biol* 2000; 20: 1430-42.
- Shihab FS, Yi H, Bennett WM, Andoh TF. Effect of nitric oxide modulation on TGF-beta1 and matrix proteins in chronic cyclosporine nephrotoxicity. *Kidney Int* 2000; 58: 1174-85.
- Parra T, de Arriba G, Conejo JR, Cantero M, Arribas I, Rodriguez-Puyol D, *et al*. Cyclosporine increases local glomerular synthesis of reactive oxygen species in rats: effect of vitamin E on cyclosporine nephrotoxicity. *Transplantation* 1998; 66: 1325-29.
- Jenkins JK, Huang H, Ndebele K, Salahudeen AK. Vitamin E inhibits renal mRNA expression of COX II, HO I, TGFbeta, and osteopontin in the rat model of cyclosporine nephrotoxicity. *Transplantation* 2001; 71: 331-4.
- Takahashi K, Nammour TM, Fukunaga M, Ebert J, Morrow JD, Roberts LT, *et al*. Glomerular actions of a free radical-generated novel prostaglandin, 8-epi-prostaglandin F2 alpha, in the rat. Evidence for interaction with thromboxane A2 receptors. *J Clin Invest* 1992; 90: 136-41.
- Butterly DW, Spurney RF, Ruiz P, Griffiths R, Albrightson C, Coffman TM. A role for leukotrienes in cyclosporine nephrotoxicity. *Kidney Int* 2000; 57: 2586-93.
- Perico N, Rossini M, Imberti O, Malanchini B, Cornejo RP, Gaspari F, *et al*. Thromboxane receptor blockade attenuates chronic cyclosporine nephrotoxicity and improves survival in rats with renal isograft. *J Am Soc Nephrol* 1992; 2: 1398-404.
- Giachelli CM, Pichler R, Lombardi D, Denhardt DT, Alpers CE, Schwartz SM, *et al*. Osteopontin expression in angiotensin II-induced tubulointerstitial nephritis. *Kidney Int* 1994; 45: 515-24.
- del Moral RG, Andujar M, Ramirez C, Gomez-Morales M, Masseroli M, Aguilar M, *et al*. Chronic cyclosporin A nephrotoxicity, P-glycoprotein overexpression, and relationships with intrarenal angiotensin II deposits. *Am J Pathol* 1997; 151: 1705-14.
- Noble NA, Border WA. Angiotensin II in renal fibrosis: should TGF-beta rather than blood pressure be the therapeutic target? *Semin Nephrol* 1997; 17: 455-66.