

Multimodal imaging in best vitelliform macular dystrophy

Enrico Borrelli, Riccardo Sacconi, Francesco Bandello, Giuseppe Querques

Department of Ophthalmology, Vita-Salute San Raffaele University, IRCCS Ospedale San Raffaele, Milan, Italy

Correspondence to: Prof. Giuseppe Querques, Department of Ophthalmology, Vita-Salute San Raffaele University, IRCCS Ospedale San Raffaele, Via Olgettina 60, 20132 Milan, Italy. Email: giuseppe.querques@hotmail.it.

Received: 01 August 2019; Accepted: 19 August 2019; Published: 12 September 2019.

doi: 10.21037/aes.2019.08.04

View this article at: <http://dx.doi.org/10.21037/aes.2019.08.04>

We applaud Lima de Carvalho and colleagues for their well-powered study entitled “Multimodal Imaging in Best Vitelliform Macular Dystrophy” (1).

In this paper, the authors performed a comprehensive multimodal imaging description of patients with Best vitelliform macular dystrophy. In detail, they employed quantitative fundus autofluorescence (qAF), near-infrared fundus autofluorescence (NIR-AF), and structural optical coherence tomography (OCT) to characterize affected eyes at different stages. This paper nicely demonstrated that a multimodal imaging approach may be useful to further characterize these patients and that each stage is featured by peculiar imaging characteristics.

Although we really enjoyed reading this paper, we have some concerns regarding the imaging descriptions proposed by the authors. In detail, 1 out of 28 eyes in their series was affected by the pre-vitelliform stage and, in this case, the authors asserted that OCT was not able to show any abnormalities. Since 2008, using structural OCT, Querques *et al.* (2-4) demonstrated that the pre-vitelliform stage is characterized by a thicker and more reflective appearance of the layer between a normal-appearing retinal pigment epithelium (RPE) and ellipsoid zone (EZ) interface. In the latter study, the authors speculated that this attribute may represent, at least in part, unphagocytized photoreceptor outer segments that accumulate above the RPE. In our opinion, this OCT feature is also evident in the pre-vitelliform eye enrolled in the study by Lima de Carvalho *et al.* (1), as it may be observed in *Figure 1*. In addition, the authors nicely identified a foveal hypofluorescence on the NIR-AF image from the pre-vitelliform stage eye. Assuming that NIR-AF is considered as a surrogate of melanin autofluorescence from the RPE

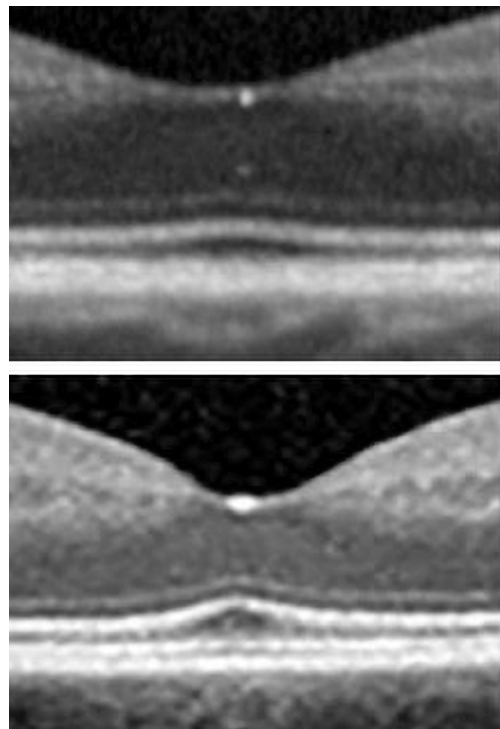


Figure 1 Highlight of images presented in Lima de Carvalho *et al.*' study (1). In comparison with a control eye [highlight of the Figure 1 in Lima de Carvalho *et al.*' study (1)], the eye affected by best vitelliform macular dystrophy in the pre-vitelliform stage [highlight of the Figure 2 in Lima de Carvalho *et al.*' study (1)] displays a thicker and more reflective appearance of the layer between the RPE and ellipsoid zone layer. RPE, retinal pigment epithelium.

and choroid, we speculate that this foveal hypofluorescence might be actually secondary to a “blocking effect” due to the presence of unphagocytized photoreceptor outer segments

at the foveal level. We would claim that the authors did not appropriately identify this as a possible explanation to the early foveal hypofluorescence on NIR-AF. In addition, this “blocking effect” could also, at least in part, account for the foveal hypofluorescence identified in the other stages of the disease.

Furthermore, the authors concluded that the vitelliform lesion is composed of outer segment debris which accumulate because of separation of photoreceptor cells from the RPE, rather than an intrinsic defect of the RPE to phagocytose this material. This separation may be ascribable to the accumulation of fluid secondary to an impaired fluid transport (5). Although we agree that the exact mechanisms leading to the accumulation of vitelliform material in Best vitelliform macular dystrophy are still matter of debate, we would argue that the pre-vitelliform stage is characterized by an accumulation of material over the RPE, rather than a collection of subretinal fluid. The latter aspect highlights the point that we still need imaging evidence of this theory.

In conclusion, we certainly recognize the high value of the data reported in this paper. However, we believe that the authors failed to appropriately comment on an important OCT feature characterizing the pre-vitelliform stage, as well as they did not highlight that—at least with an imaging approach—there is no evidence that the accumulation of subretinal fluid might be the first pathogenic step in eyes affected by Best vitelliform macular dystrophy. We believe that these aspects of this study deserve a further explanation and therefore the authors’ feedback in this regard would be greatly appreciated.

Acknowledgments

Funding: None.

Footnote

Provenance and Peer Review: This article was a standard submission to the journal. The article did not undergo external peer review.

Conflicts of Interest: All authors have completed the ICMJE uniform disclosure form (available at <http://dx.doi.org/10.21037/aes.2019.08.04>). Francesco Bandello is a consultant for: Alcon (Fort Worth, Texas, USA), Alimera Sciences (Alpharetta, Georgia, USA), Allergan Inc. (Irvine,

California, USA), Farmila-Thea (Clermont-Ferrand, France), Bayer Shering-Pharma (Berlin, Germany), Bausch And Lomb (Rochester, New York, USA), Genentech (San Francisco, California, USA), Hoffmann-La-Roche (Basel, Switzerland), Novagali Pharma (Évry, France), Novartis (Basel, Switzerland), Sanofi-Aventis (Paris, France), Thrombogenics (Heverlee, Belgium), Zeiss (Dublin, USA). Giuseppe Querques is a consultant for: Alimera Sciences (Alpharetta, Georgia, USA), Allergan Inc (Irvine, California, USA), Amgen (Thousand Oaks, USA), Bayer Shering-Pharma (Berlin, Germany), Heidelberg (Germany), KBH (Chengdu; China), LEH Pharma (London, UK), Lumithera (Poulsbo; USA), Novartis (Basel, Switzerland), Sandoz (Berlin, Germany), Sifi (Catania, Italy), Sooft-Fidea (Abano, Italy), Zeiss (Dublin, USA). The other authors have no conflicts of interest to declare.

Ethical Statement: The authors are accountable for all aspects of the work in ensuring that questions related to the accuracy or integrity of any part of the work are appropriately investigated and resolved.

Open Access Statement: This is an Open Access article distributed in accordance with the Creative Commons Attribution-NonCommercial-NoDerivs 4.0 International License (CC BY-NC-ND 4.0), which permits the non-commercial replication and distribution of the article with the strict proviso that no changes or edits are made and the original work is properly cited (including links to both the formal publication through the relevant DOI and the license). See: <https://creativecommons.org/licenses/by-nc-nd/4.0/>.

References

1. Lima de Carvalho JR Jr, Paavo M, Chen L, et al. Multimodal Imaging in Best Vitelliform Macular Dystrophy. *Invest Ophthalmol Vis Sci* 2019;60:2012-22.
2. Querques G, Regenbogen M, Quijano C, et al. High-definition optical coherence tomography features in vitelliform macular dystrophy. *Am J Ophthalmol* 2008;146:501-7.
3. Querques G, Zerbib J, Santacroce R, et al. The spectrum of subclinical Best vitelliform macular dystrophy in subjects with mutations in BEST1 gene. *Invest Ophthalmol Vis Sci* 2011;52:4678-84.
4. Querques G, Zerbib J, Georges A, et al. Multimodal

analysis of the progression of best vitelliform macular dystrophy. *Mol Vis* 2014;20:575-92.

5. Edelman JL, Lin H, Miller SS. Acidification stimulates

chloride and fluid absorption across frog retinal pigment epithelium. *Am J Physiol* 1994;266:C946-56.

doi: 10.21037/aes.2019.08.04

Cite this article as: Borrelli E, Sacconi R, Bandello F, Querques G. Multimodal imaging in best vitelliform macular dystrophy. *Ann Eye Sci* 2019;4:31.