doi: 10.3978/j.issn.2095-6959.2018.01.037
View this article at: http://dx.doi.org/10.3978/j.issn.2095-6959.2018.01.037

额骨 Rosai–Dorfman 病 1 例并文献复习

丘木水，于晓洁，武净净，刘纬驰，郑杰，张舵

(吉林大学第一医院整形美容外科，长春 130021)

[摘　要]　对1例额骨Rosai-Dorfman病(Rosai-Dorfman disease，RDD)进行病理学观察及免疫组织化学分析，并复习相关文献。病理检查可见组织细胞吞噬淋巴细胞、浆细胞、红细胞或中性粒细胞；免疫组织化学示：S-100蛋白阳性，CD68阳性，CD1a阴性。额骨RDD除头皮及额部麻木外缺乏特异性临床表现，确诊有赖于病理学检查，早期手术切除病灶预后良好。

[关键词]　Rosai-Dorfman病；骨；诊断；治疗

Rosai-Dorfman disease of frontal bone: A case report and literature review

QIU Mushui, YU Xiaojie, WU Jingjing, LIU Weichi, ZHENG Jie, ZHANG Duo

(Department of Plastic and Reconstructive Surgery, First Bethune Hospital, Jilin University, Changchun 130021, China)

Abstract　A case of Rosai-Dorfman disease (RDD) of frontal bone was treated with clinical pathological analysis and immunohistochemistry, and literatures were reviewed. Histopathologically, the disease demonstrated that histiocytes phagocytized lymphocytes, plasma cells, erythrocytes, or polymorphonuclear leukocytes; immunohistochemical analysis demonstrated that S-100 protein and CD68 were positive, CD1a was negative. RDD of frontal bone is lack of specific clinical manifestations but numbness of the scalp and forehead. The diagnosis depends on pathological examination. Early surgical resection of the lesion has a good prognosis.

Keywords　Rosai-Dorfman disease; bone; diagnosis; treatment

Rosai-Dorfman病(Rosai-Dorfman disease，RDD)，又称窦组织细胞增生伴巨淋巴结病(sinus histiocytosis with massive lymphadenopathy，SHML)，是一种罕见的良性组织细胞增生性疾病，最早由Rosai和Dorfman于1969年详细报道[1]。RDD主要发生于淋巴结内，发生在淋巴结以外的RDD少见，累及骨的更为少见。本研究纳入1例经手术病理证实的额骨RDD，分析总结其特点及术中注意事项，并复习相关文献，旨在提高对额骨RDD的临床认识。

1 临床资料

患者男性，25岁，以“发现左额部肿物1年

收稿日期 (Date of reception)：2017–10–31
通信作者 (Corresponding author)：张舵，Email: zhangduo2002@hotmail.com

余”为主诉入院。入院体格检查：左侧额部可扪及一大小约3.0 cm × 2.5 cm的近椭圆形皮下肿物，肿物略凸起于周围皮肤(图1)，表面皮肤颜色与周围正常皮肤未见明显差异，触之质硬，无明显压痛，与周围组织界限尚清，移动度差。左侧额部及头皮麻木。入院后于局麻下行左额部肿物切除术。术中在左侧眉上缘设计切口(图2)，切开皮肤至皮下，可见包膜不清晰的灰白色肿物，质中偏硬，骨膜剥离子剥离颅骨面，可见颅骨被肿物侵蚀(图3)，病变处颅骨破溃，剥离至眶上缘，沿眶上缘切断肿物，完整切除之。病理切片示：胞质丰富的多边形组织细胞内吞噬形态完整的淋巴细胞、浆细胞及中性粒细胞(图4)。免疫组织化学示：S-100(+)(图5)，CD68(+)，SMA(+)，CD1a(−)，CD34(−)。诊断：Rosai-Dorfman病。手术后未给予特殊治疗，随访11个月未见复发(图6)。本文资料已获得患者知情同意。

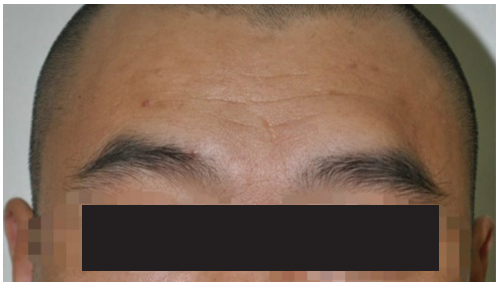

图1 左侧额部肿物略凸起于周围皮肤

Figure 1 Tumor at the left side of the forehead slightly protrudes from the surrounding skin

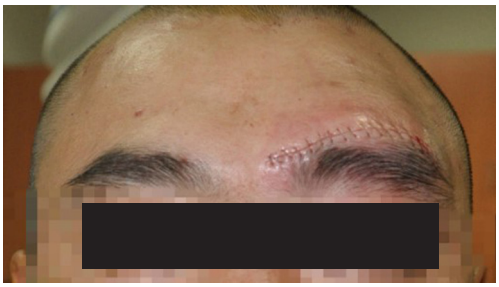

图2 手术切口位置及术后即刻效果

Figure 2 Position of surgical incision and postoperative appearance

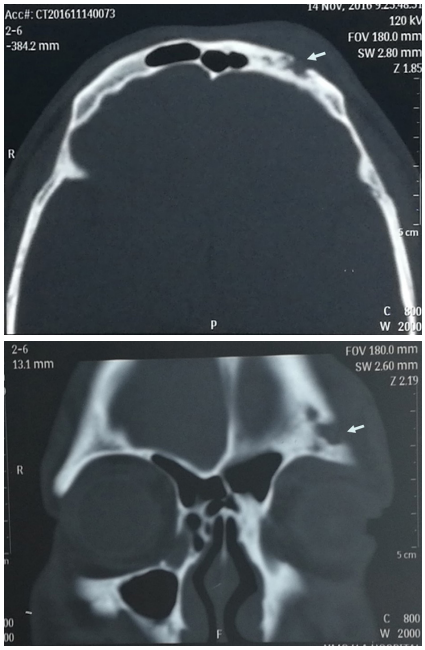

图3 额骨溶骨性骨质破坏

Figure 3 Osteolysis of the frontal bone

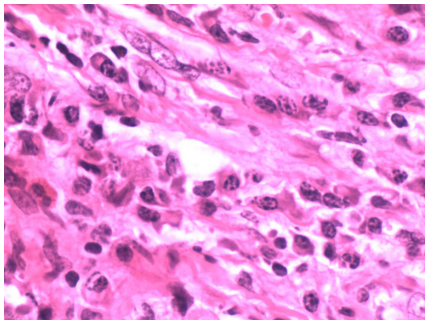

图4 RDD的病理改变(伸入运动)(HE，×400)

Figure 4 RDD presenting as the emperipolesis (HE, ×400)

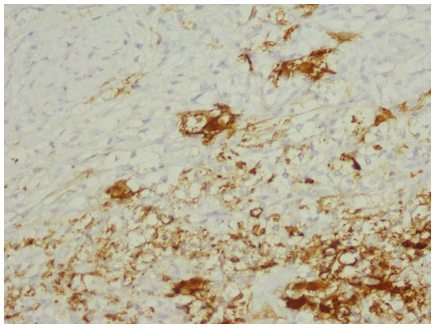

图5 RDD的免疫组织化学反应[S-100(+)](En Vision，×400)

Figure 5 Immunohistochemical reactions of RDD [S-100 (+)] (En Vision, ×400)

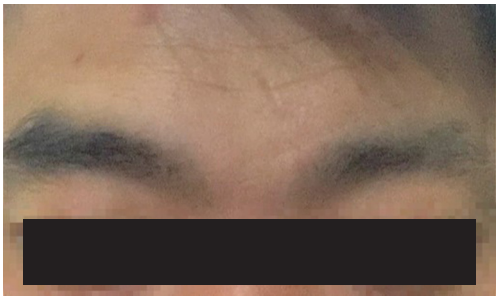

图6 术后11个月外观

Figure 6 Appearance of the patient 11 months after surgery

2 讨论

RDD好发于儿童及青少年，平均年龄约20岁，以男性居多。患者通常表现为块状、无痛性淋巴结肿大、发热、焦虑、夜间盗汗、中性粒细胞升高、红细胞沉降率加快及多克隆性高丙种球蛋白血症[2]。

目前RDD的病因和发病机制尚不明确，其假说主要包括免疫调节紊乱与感染[3]。本病可发生于任何部位。文献中最早的骨RDD报道[4]见于2010年，至今共报道[4-9]骨RDD 6例。经PubMed检索主题词Rosai-dorfman和bone，共检索英文文献161篇，其中不伴有其他淋巴结外累及的原发性骨RDD至今共24篇文献，可获取全文的12篇[10-21]。Foucar等[22]对423例RDD患者进行临床与病理特征研究，发现结外受累在这一人群中最常见的部位是皮肤、上呼吸道、骨，也可在其它部位出现，包括泌尿生殖系统、下呼吸道、口腔软组织。

RDD的诊断主要依靠组织病理检查及免疫组织化学染色结果。病理检查可见典型的“伸入运动”，即组织细胞吞噬淋巴细胞、浆细胞、红细胞或中性粒细胞，但黄色肉芽肿性疾病中所能见到的Touton巨细胞以及恶性肿瘤中所具有的细胞异型性在RDD中均不可见[23]。免疫组织化学示S-100蛋白阳性，CD68阳性，及典型的CD1a阴性[24]，并以此来区分CD1a呈阳性的朗格汉斯组织细胞增生症[25]。此外，Erdheim-Chester病，另一种见于成人的组织细胞增多症，免疫组织化学S-100蛋白一般呈阴性[26]。

RDD颌面部额骨侵犯国内相似病例仅见个案报道[8]。本例患者除局部占位性病变外，主要表现为额骨侵蚀和额部及头皮麻木。在额骨侵蚀方面，可见病变局部额骨呈溶骨性骨质破坏，边界尚清、不规则，无明显骨硬化及骨膜反应，需注意与嗜酸性肉芽肿、转移性肿瘤等相鉴别[8]。而额部及头皮发麻是由于病变组织位于左眉上，有眶上血管神经束等在此走行。眶上神经是额神经的一个分支，为感觉神经，分支分布于额顶部皮肤，结合术后随访患者额部及头皮发麻症状有所缓解的情况，本研究认为该患者额部及头皮发麻应为眶上神经被肿物压迫、浸润或局部炎症刺激所致。

目前尚无明确指南对RDD进行指导治疗，但文献中已有多种方法被报道，主要包括皮质类固醇、化学治疗、放射治疗、手术治疗等，病情允许的话，也可采取保守治疗[27]。也可应用干扰素治疗[28]。Karajgikar等[29]认为由于该病具有一定的自限性，大约有20%的患者可自行消退，若未出现临床症状或没有重要器官受累，可采取保守治疗；而在危及生命的情况下，不管是淋巴结内还是淋巴结外，均应采取手术切除或减瘤和/或放射治疗及甾类激素治疗。如上所述，大约80%的RDD患者都是无法自行消退的，故即便在未危及生命的情况下，一旦发现RDD，仍应积极地采取治疗措施，而在上述的治疗方案中，可优先考虑早期手术切除。早期手术切除，一方面可以直接去除病灶，送检病理，从而明确临床诊断，制定相应的修复方案；另一方面，在肿物发现早期，体积较小，对周围组织破坏及侵袭也相应较少，早期切除肿物，可减少手术切除难度，同时也使手术切口缩小，减少术后切口瘢痕。有相关报道[30-31]称在RDD完整切除或在附着于周围重要组织次全切除后，可有效缓解临床症状，使病情稳定，并建议术后行保守治疗，无需其他特殊处置。

本例患者虽未出现远处转移及危及生命，但仍采取手术切除的方法进行治疗，其主要原因除以上所述普遍因素外，还存在特殊性：首先，肿物生长于患者颜面部，且出现局部隆起，早期手术切除不仅可以改善患者外观，还可减少延期手术残留的瘢痕长度。值得注意的是，虽然肿物于体表触及时仅3.0 cm × 2.5 cm，但肿物实际范围远比触及时广，所以为了保证有充分的术野，切口应适当增大。手术切除病灶后，虽可减少局部软组织堆积，但由于肿物长期占位，肿物切除后，应充分分离周围皮下，用周围的肌肉及皮下组织填补肿物切除后残留的空腔，防止术后额部皮肤与颅骨粘连及局部凹陷的发生，影响术后愈合效果及患者的生活质量。其次，肿物已向周围眶上血管神经束等重要神经血管组织浸润，压迫神经，出现头皮发麻等临床症状，影响患者日常生活。手术切除肿物，可解除其对眶上神经的负面

影响，缓解临床症状，由于病灶处有眶上血管神经束、滑车上动脉等在此走行，解剖结构较为复杂，术中操作时应轻柔，建议尖刀切开皮下后，用文氏钳或显微文氏钳进行钝性分离，防止重要血管神经的损伤。再者，肿物已侵蚀额骨，若不及早切除，任由其发展，可能会向颅内侵袭，引起严重临床症状，甚至危及生命。在颅骨面剥离时，应注意骨膜剥离子使用的力度及方向，由于肿物侵袭颅骨，局部颅骨可有破溃，防止骨膜剥离子误入颅内；同时术中应用咬骨钳和刮勺适当去掉额骨骨质破坏区的边缘，以减少肿物复发的概率及防止骨坏死的发生。术后未作放射、化学治疗，在随访中发现，患者面部外观恢复良好，未见明显局部凹陷及牵拉畸形，无明显瘢痕残留，手术部位肿物未见复发。

综上所述，早期手术干预治疗额骨RDD预后良好。

参考文献

1. Rosai J, Dorfman RF. Sinus histiocytosis with massive lymphadenopathy. A newly recognized benign clinicopathological entity[J]. Arch Pathol, 1969, 87(1): 63-70.
2. Bernácer-Borja M, Blanco-Rodríguez M, Sanchez-Granados JM, et al. Sinus histiocytosis with massive lymphadenopathy (Rosai-Dorfman disease): clinico-pathological study of three cases[J]. Eur J Pediatr, 2006, 165(8):536-539.
3. Ha H, Kim KH, Ahn YJ, et al. A rare case of Rosai-Dorfman disease without lymphadenopathy[J]. Korean J Intern Med, 2016, 31(4): 802-804.
4. 王智园, 石灵春, 杨海峰, 等. 发生在指骨的Rosai-Dorfman病1例[J]. 实用医学杂志, 2010, 26(23): 4404.
   WANG Zhiyuan, SHI Lingchun, YANG Haifeng, et al. One case of Rosai-Dorfman disease occurred in the phalange[J]. The Journal of Practical Medicine, 2010, 26(23): 4404.
5. 刘春华, 徐杰, 黄惠梅, 等. 胫骨Rosai-Dorfman病一例报告[J]. 中国修复重建外科杂志, 2012, 26(6): 765-766.
   LIU Chunhua, XU Jie, HUANG Huimei, et al. A report of Rosai-Dorfman disease of shin[J]. Chinese Journal of Reparative and Reconstructive Surgery, 2012, 26(6): 765-766.
6. 王蔚, 陈炳旭, 陈晓东, 等. 累及骨和软骨Rosai-Dorfman病2例报告并文献复习[J]. 国际病理科学与临床杂志, 2012, 32(2): 124-129.
   WANG Wei, CHEN Bingxu, CHEN Xiaodong, et al. Rosai-Dorfman disease of bone and cartilage: two case reports and review of the literature[J]. International Journal of Pathology and Clinical Medicine, 2012, 32(2): 124-129.
7. 张良运, 郭莉, 罗小平, 等. 颅骨Rosai-Dorfman病的病理诊断临床分析[J]. 中南医学科学杂志, 2014, 42(4): 367-369.
   ZHANG Liangyun, GUO Li, LUO Xiaoping, et al. Clinical analysis of pathologic diagnosis of skull Rosai-Dorfman disease[J]. Journal of Nanhua University. Medical Edition, 2014, 42(4): 367-369.
8. 江朝根, 邱菊生, 杨小军, 等. Rosai-Dorfman病颅骨侵犯1例[J]. 中国骨伤, 2012, 25(6): 523-524.
   JIANG Chaogen, QIU Jusheng, YANG Xiaojun, et al, A case of cranial invasion of Rosai-Dorfman disease[J]. China Journal of Orthopaedics and Traumatology, 2012, 25(6): 523-524.
9. 吴博, 席珊珊, 刘衡, 等. 股骨Rosai-Dorfman病一例并文献复习[J]. 临床放射学杂志, 2016, 35(4): 510-511.
   WU Bo, XI Shanshan, LIU Heng, et al. A case of Rosai-Dorfman disease of femur: a literature review[J]. Journal of Clinical Radiology, 2016, 35(4): 510-511.
10. Li S, Yan Z, Jhala N, et al. Fine needle aspiration diagnosis of Rosai-Dorfman disease in an osteolytic lesion of bone[J]. Cytojournal, 2010, 7: 12.
11. Dean EM, Wittig JC, Vilalobos C, et al. A 16-year-old boy with multifocal, painless osseous lesions[J]. Clin Orthop Relat Res, 2012, 470(9): 2640-2645.
12. Park YK, Kim YW, Choi WS, et al. Sinus histiocytosis with massive lymphadenopathy. Multiple skull involvements. Sinus histiocytosis with massive lymphadenopathy. Multiple skull involvements[J]. J Korean Med Sci, 1998, 13(4): 423-427.
13. Patel MH, Jambhekar KR, Pandey T, et al. A rare case of extra nodal Rosai-Dorfman disease with isolated multifocal osseous manifestation[J]. Indian J Radiol Imaging, 2015, 25(3): 284-287.
14. Paryani NN, Daugherty LC, O'Connor M, et al. Extranodal rosai-dorfman disease of the bone treated with surgery and radiotherapy[J]. Rare Tumors, 2014, 6(4): 5531.
15. Mannelli L, Monti S, Love JE, et al. Primary Rosai-Dorfman disease of the bone in a patient with history of breast cancer: appearance on 99mTc-MDP scintigraphy, CT, and X-ray[J]. Clin Nucl Med, 2015, 40(3): 247-249.
16. Efared B, Mazti A, Chaibou B, et al. Bone pathologic fracture revealing an unusual association: coexistence of Langerhans cell histiocytosis with Rosai-Dorfman disease[J]. BMC Clin Pathol, 2017, 17: 5.
17. Mantilla JG, Goldberg-Stein S, Wang Y. Extranodal Rosai-Dorfman disease: clinicopathologic series of 10 patients with radiologic correlation and review of the literature[J]. Am J Clin Pathol, 2016, 145(2): 211-221.
18. Miniello TG, Araujo JP, Sugaya NN, et al. Rosai-Dorfman disease affecting the maxilla[J]. Autops Case Rep, 2016, 6(4): 49-55.

19. Kim DY, Park JH, Shin DA, et al. Rosai-Dorfman disease in thoracic spine: a rare case of compression fracture[J]. Korean J Spine, 2014, 11(3): 198-201.
20. Xu J, Liu CH, Wang YS, et al. Extranodal Rosai-Dorfman disease as isolated lesion of the tibia diagnosed by fine-needle aspiration cytology: a case report[J]. Medicine (Baltimore), 2015, 94(47): e2038.
21. Igrutinovic Z, Medovic R, Markovic S, et al. Rosai-Dorfman disease of vertebra: case report and literature review[J]. Turk J Pediatr, 2016, 58(5): 566-571.
22. Foucar E, Rosai J, Dorfman R. Sinus histiocytosis with massive lymphadenopathy (Rosai-Dorfman disease): review of the entity[J]. Semin Diagn Pathol, 1990, 7(1): 19-73.
23. Tan JJ, Narang S, Purewal B, et al. Extranodal Rosai-Dorfman disease of the orbit: clinical features of 8 cases[J]. Ophthal Plast Reconstr Surg, 2016, 32(6): 458-461.
24. Zaveri J, La Q, Yarmish G, et al. More than just Langerhans cell histiocytosis: a radiologic review of histiocytic disorders[J]. Radiographics, 2014, 34(7): 2008-2024.
25. O'Malley DP, Duong A, Barry TS, et al. Co-occurrence of Langerhans cell histiocytosis and Rosai-Dorfman disease: possible relationship of two histiocytic disorders in rare cases[J]. Mod Pathol, 2010, 23(12): 1616-1623.
26. Kenn W, Eck M, Allolio B, et al. Erdheim-Chester disease: evidence for a disease entity different from Langerhans cell histiocytosis? Three cases with detailed radiological and immunohistochemical analysis[J]. Hum Pathol, 2000, 31(6): 734-739.
27. Demicco EG, Rosenberg AE, Björnsson J, et al. Primary Rosai-Dorfman disease of bone: a clinicopathologic study of 15 cases[J]. Am J Surg Pathol, 2010, 34(9): 1324-1333.
28. Palomera L, M Domingo J, Soria J, et al. Long term survival in a patient with aggressive Rosai-Dorfman disease treated with interferon alpha[J]. Med Clin (Barc), 2001, 116(20): 797-798.
29. Karajgikar J, Grimaldi G, Friedman B, et al. Abdominal and pelvic manifestations of Rosai-Dorfman disease: a review of four cases[J]. Clin Imaging, 2016, 40(6): 1291-1295.
30. Dalia S, Sagatys E, Sokol L, et al. Rosai-Dorfman disease: tumor biology, clinical features, pathology, and treatment[J]. Cancer Control, 2014, 21(4): 322-327.
31. Cooper SL, Jenrette JM. Rosai-Dorfman disease: management of CNS and systemic involvement[J]. Clin Adv Hematol Oncol, 2012, 10(3): 199-202.

本文引用： 丘木水, 于晓洁, 武净净, 刘纬驰, 郑杰, 张舵. 额骨Rosai-Dorfman病1例并文献复习[J]. 临床与病理杂志, 2018, 38(1): 219-223. doi: 10.3978/j.issn.2095-6959.2018.01.037

Cite this article as: QIU Mushui, YU Xiaojie, WU Jingjing, LIU Weichi, ZHENG Jie, ZHANG Duo. Rosai-Dorfman disease of frontal bone: A case report and literature review[J]. Journal of Clinical and Pathological Research, 2018, 38(1): 219-223. doi: 10.3978/j.issn.2095-6959.2018.01.037