doi: 10.3978/j.issn.2095-6959.2018.10.037
View this article at: http://dx.doi.org/10.3978/j.issn.2095-6959.2018.10.037

5– 氨基酮戊酸光动力疗法联合 CO_2 激光长期间断治疗乳房外 Paget 病 1 例

周细平，黄进华，鲁建云，陈静，左成忻，杨盛波，向亚平，谭丽娜，康健，丁澍

(中南大学湘雅三医院皮肤科，长沙 410013)

[摘　要] 患者，女，78岁，外阴部皮损14年余。依据典型的临床表现和组织病理诊断为乳房外Paget病(extramammary Paget's disease，EMPD)。该病病程缓慢，晚期可发生转移，其首选治疗方法为手术切除。患者拒绝手术治疗，因此采用5-氨基酮戊酸光动力疗法(5-aminolevulinic acid-photodynamic therapy，ALA-PDT)联合CO_2激光治疗。经长期随访发现多次治疗后表面皮损基本消退，但难以防止肿瘤复发，复发后该治疗方法仍有效。

[关键词] 乳房外Paget病；光动力疗法；CO_2激光；5-氨基酮戊酸

5-Aminolevulinic acid-photodynamic therapy in combination with CO_2 laser therapy for a case report of long-term extramammary Paget's disease

ZHOU Xiping, HUANG Jinghua, LU Jianyun, CHEN Jing, ZUO Chengxin, YANG Shengbo, XIANG Yaping, TAN Lina, KANG Jian, DING Shu

(Department of Dermatology, Third Xiangya Hospital, Central South University, Changsha 410013)

Abstract A 78-year-old female presented with lesions of the vulva for more than 14 years. The diagnosis of extramammary Paget's disease (EMPD) was established according to the typical clinical manifestations and histopathological exemination. The disease has a slow course and metastasis can occur in the late stage. The preferred treatment is surgical resection. Because the patient refused to surgical treatment, we used 5-aminolevulinic acid-photodynamic therapy (ALA-PDT) in combination with CO_2 laser therapy. After a long-term follow-up, we found the lesion gradually subsided with multiple treatment, but it was difficult to prevent tumor recurrence, and the treatment is still effective after recurrence.

Keywords extramammary Paget's disease; photodynamic therapy; CO_2 laser; 5-aminolevulinic acid

乳房外Paget病(extramammary Paget's disease，EMPD)又称乳房外湿疹样癌，好发于女阴、阴囊、会阴等大汗腺丰富的部位，皮损主要表现为红色斑片或斑块，表面呈湿疹样糜烂、渗出或结痂，伴有痒痛感[1]。因皮损无明显特异性，易误诊为湿疹、皮炎或真菌感染，延误治疗。笔者

收稿日期 (Date of reception)： 2018–07–22
通信作者 (Corresponding author)： 鲁建云，Email: 1010739024@qq.com

报告1例延误诊断，因年龄大、皮损范围广而采用5-氨基酮戊酸光动力疗法(5-aminolevulinic acid-photodynamic therapy，ALA-PDT)联合CO_2激光治疗并长期随访的EMPD病例。

1 临床资料

患者，女，78岁，外阴部皮损14年余。患者2003年无明显诱因外阴出现红斑，未予重视并治疗；后皮损范围逐渐扩大，部分增厚形成斑块，表面出现糜烂、渗出伴瘙痒疼痛(图1)，在当地医院经反复抗感染及外用药治疗后皮损无明显好转，为求进一步治疗于2013年6月到中南大学湘雅三医院皮肤科门诊就诊，行皮损活检病理检查诊断为“乳房外Paget病”(图2A，2B)。患者因年龄较大，皮损范围较广拒绝行手术治疗，于2013年6月9日开始多次住院，行ALA-PDT联合CO_2激光治疗，其中丘疹结节及厚斑块皮损先予以CO_2激光烧灼处理再联合光动力治疗，至同年9月中旬共连续完成6次治疗后表面皮损逐渐消退(图1B~1F)。之后门诊随诊观察。

2016年患者原皮损复发，再次到中南大学湘雅三医院住院治疗。复发住院治疗前经系统检查未见明显异常。复发治疗前专科查体：左侧外阴可见约6 cm×4 cm大小赘生物，皮损主要为红色斑块，散在丘疹结节，表面粗糙，部分皮损表面糜烂渗出(图3A)。既往有慢性胃炎病史。实验室检查：三大常规、肝肾功能、电解质、凝血功能、输血前4项、心肌酶无异常。心电图无明显异常。影像学检查：胸片、腹部及盆腔彩超均无明显异常。入院诊断为EMPD复发，未发现明显肿瘤转移表现。遂再次行ALA-PDT联合CO_2激光治疗，至2017年6月共间断行5次治疗，皮损明显缓解(图3B，3C)，原计划继续治疗，后因意外骨折中断治疗在家休养，电话随访。随访得知患者2017年10月因肺部感染在外院住院治疗，常规检查发现肝多发转移瘤，考虑EMPD转移所致，以中医药姑息治疗为主，未行放射和化学治疗，于2017年底因肿瘤恶化多器官功能衰竭死亡。

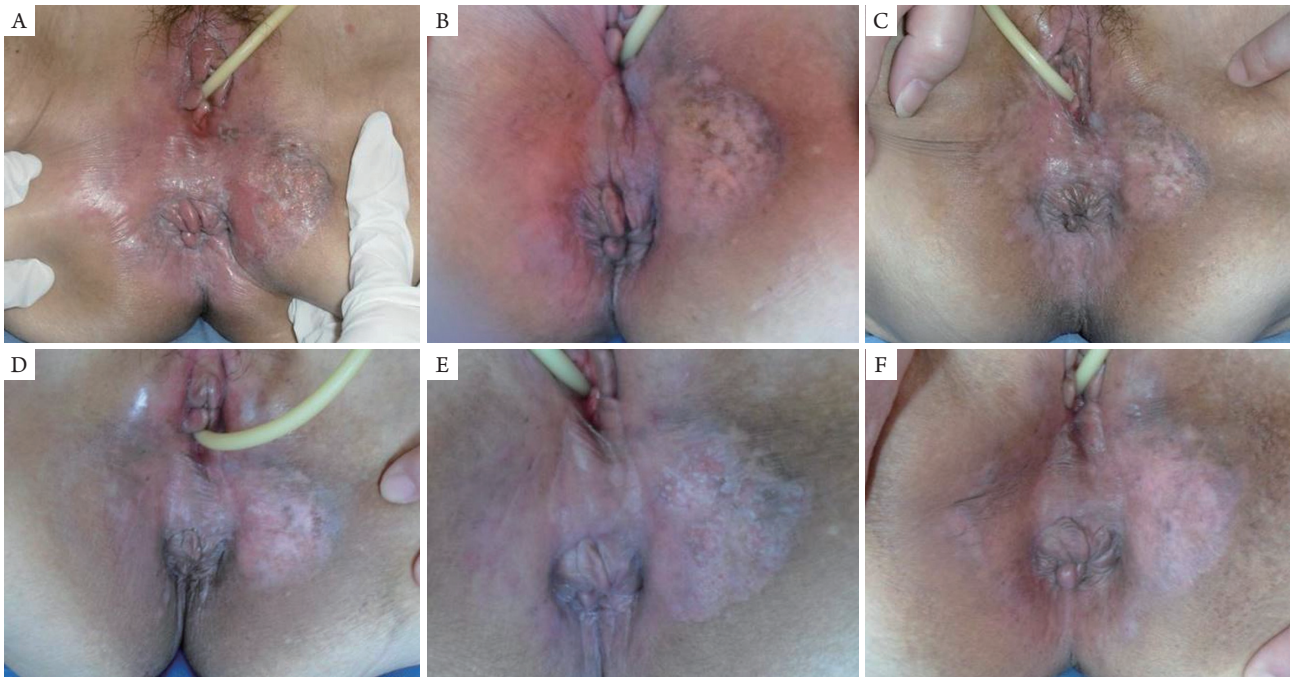

图1 ALA-PDT联合CO_2激光初次治疗EMPD前后的皮损图片

Figure 1 Skin lesions before and after the initial treatment of EMPD by ALA-PDT combinated with CO_2 laser

(A)初次治疗前，皮损主要为红色斑块，散在丘疹结节，部分皮损表面糜烂渗出；(B~F)分别为第1~5次治疗后皮损图片，可见肿瘤逐渐消退，至第5次治疗后基本缓解。

(A) Before the initial treatment, the skin lesions were mainly red plaques, scattered papules, nodules, erosion and exudation; (B–F) The lesions after the 1st to the 5th treatment respectively. The tumor gradually subsided after the 5th treatment.

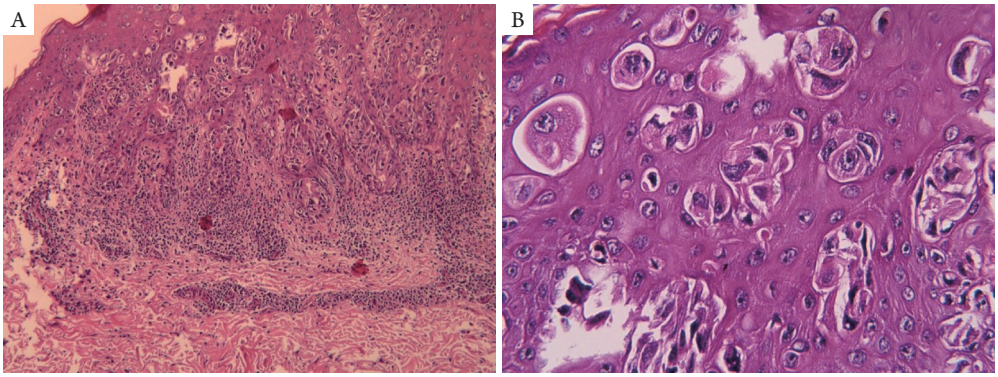

图2 EMPD皮损组织病理(HE染色)，表皮全层可见单个及巢状排列的Paget细胞，胞体大，胞质丰富而淡染，胞核大而深染，异型性明显。真皮浅层较多炎性细胞浸润

Figure 2 Histopathology of EMPD skin lesions (HE staining). Within the epidermis, there were single and nested Paget cells with large body, abundant cytoplasm and light staining, large and deep stained nuclei and obvious atypia. There were many inflammatory cells in the superficial dermis

(A) × 100; (B) × 400.

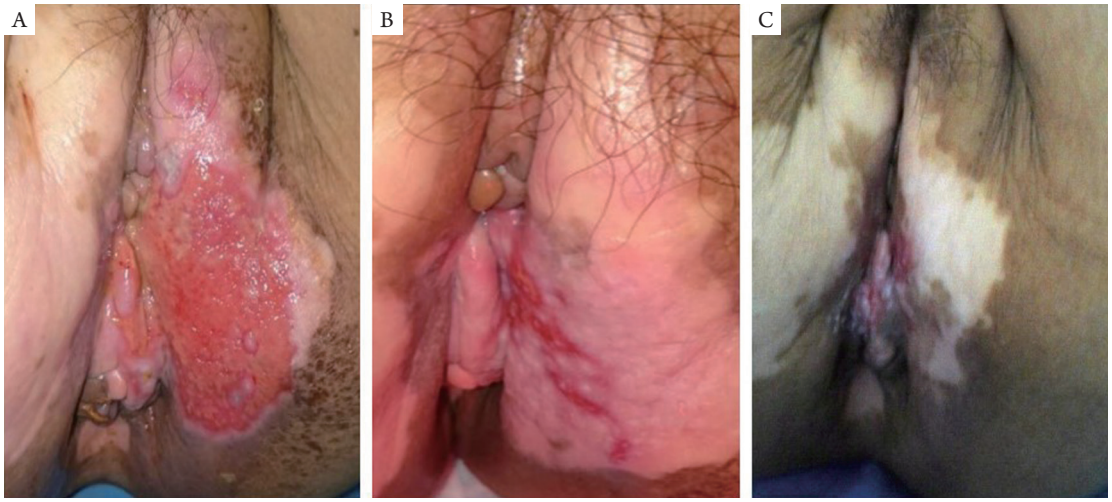

图3 EMPD复发后ALA-PDT联合CO_2激光治疗再次治疗前后的皮损图片

Figure 3 Recurrent lesions of EMPD before and after the re-treatment of ALA-PDT combinated with CO_2 laser

(A)肿瘤复发治疗前，皮损为大片红色斑块，散在丘疹，表面糜烂渗出；(B)第2次治疗后，皮损好转；(C)第5次治疗后，残留小片状红斑皮损，原皮损区出现色素脱失。

(A) Before the treatment of tumor recurrence, the skin lesions were red plaques, scattered papules, erosion and exudation; (B) After the 2nd treatment, the skin lesion was improved; (C) After the 5th treatment, only small erythematous lesions were displayed, with depigmentation on the original skin lesions.

2 讨论

EMPD是一种少见的皮肤恶性肿瘤，按肿瘤细胞来源可分为原发性和继发性。原发性EMPD好发于50~80岁老年人，其中欧美患者女性较多，而亚洲患者男性较多[2]。本例患者为女性，较为少见；患者2003年即出现原发皮损，14年后才出现转移性肿瘤，考虑为原发性EMPD，而继发性EMPD多来源于邻近的消化道或泌尿系统腺癌扩展至表皮所致。依据肿瘤细胞浸润深度EMPD可分为2种类型：一种类型肿瘤细胞局限于表皮内，另一种则肿瘤细胞累及附属器上皮或真皮。该病随侵袭深度越深，预后越差，复发率也随之增加[3-4]。本例患者初次诊断病理标本中Paget细胞局限于表皮

内，真皮及附属器未见受累，遗憾的是，患者皮损治疗后复发未再取组织行病理检查，未能观察到肿瘤细胞是否已突破基底层。EMPD治疗方法较多，手术切除是首选治疗方法，包括传统的扩大切除术及Mohs手术，仍有一定复发率；ALA-PDT可作为EMPD的单一治疗手段或术后的辅助治疗，适用于老年、复发以及皮损较大的患者[5-6]。有研究[7]对32例患者应用ALA-PDT，3个疗程后，皮损面积明显减小，大部分患者症状得到缓解。本研究患者因年龄较大，皮损范围较广，拒绝接受手术治疗，采用了ALA-PDT联合CO_2激光治疗，经6次治疗后表面皮损基本消退，随访3年后出现复发，提示ALA-PDT联合CO_2激光由于治疗深度有限，可能对于肿瘤细胞累及附属器上皮或真皮的EMPD类型容易导致复发，而手术后联合ALA-PDT可能疗效更佳[8]，这些需要进一步的研究证实。EMPD皮损复发后再次行ALA-PDT联合CO_2激光治疗，清除皮损疗效良好，但肿瘤细胞可侵袭性生长并逐渐发生远隔器官转移[9]。本例患者在发病14年后出现肝转移肿瘤，因未发现其他原发肿瘤灶，考虑由EMPD转移所致，但缺乏转移灶病理证实。

参考文献

1. Kang Z, Zhang Q, Zhang Q, et al. Clinical and pathological characteristics of extramammary Paget's disease: report of 246 Chinese male patients[J]. Int J Clin Exp Pathol, 2015, 8(10): 13233-13240.
2. 张韡, 曾学思, 孙建方. 乳房外Paget病的病理学研究进展[J]. 中华皮肤科杂志, 2015, 48(12): 897-898.
ZHANG Wei, ZENG Xuesi, SUN Jianfang. Advances in the pathology of extramammary Paget's disease[J]. Chinese Journal of Dermatology, 2015, 48(12): 897-898.
3. Hatta N, Yamada M, Hirano T, et al. Extramammary Paget's disease: treatment, prognostic factors and outcome in 76 patients[J]. Br J Dermatol, 2008, 158(2): 313-318.
4. 郭亮侬, 刘小青, 李航, 等. 乳房外Paget病75例临床病理特点分析[J]. 中华医学杂志, 2015, 95(22): 1751-1754.
GUO Liangnong, LIU Xiaoqing, LI Hang, et al. Clinicopathological features of extramammary Paget's disease: a report of 75 cases[J]. National Medical Journal of China, 2015, 95(22): 1751-1754.
5. Hendi A, Brodland DG, Zitelli JA. Extramammary Paget's disease: surgical treatment with Mohs micrographic surgery[J]. J Am Acad Dermatol, 2004, 51(5): 767-773.
6. 徐莹莹, 王焱, 方方. 乳房外Paget病的治疗进展[J]. 国际皮肤性病学杂志, 2017, 43(1): 10-13.
XU Yingying, WANG Yan, FANG Fang. Treatments of extramammary Paget's disease[J]. International Journal of Dermatology and Venereology, 2017, 43(1): 10-13.
7. Fontanelli R, Papadia A, Martinelli F, et al. Photodynamic therapy with M-ALA as non-surgical treatment option in patients with primary extramammary Paget's disease[J]. Gynecol Oncol, 2013, 130(1): 90-94.
8. Gao Y, Zhang XC, Wang WS, et al. Efficacy and safety of topical ALA-PDT in the treatment of EMPD[J]. Photodiagnosis Photodyn Ther, 2015, 12(1): 92-97.
9. 马东来, 徐凯峰, 王家璧, 等. 乳房外Paget病伴多脏器转移1例[J]. 临床皮肤科杂志, 2001, 30(5): 325-327.
MA Donglai, XU Kaifeng, WANG Jiabi, et al. Extramammary Paget's disease metastasized to multiple organs: a case report[J]. Journal of Clinical Dermatology, 2001, 30(5): 325-327.

本文引用：周细平, 黄进华, 鲁建云, 陈静, 左成忻, 杨盛波, 向亚平, 谭丽娜, 康健, 丁澍. 5-氨基酮戊酸光动力疗法联合CO_2激光长期间断治疗乳房外Paget病1例[J]. 临床与病理杂志, 2018, 38(10): 2274-2277. doi: 10.3978/j.issn.2095-6959.2018.10.037

Cite this article as: ZHOU Xiping, HUANG Jinghua, LU Jianyun, CHEN Jing, ZUO Chengxin, YANG Shengbo, XIANG Yaping, TAN Lina, KANG Jian, DING Shu. 5-Aminolevulinic acid-photodynamic therapy in combination with CO_2 laser therapy for a case report of long-term extramammary Paget's disease[J]. Journal of Clinical and Pathological Research, 2018, 38(10): 2274-2277. doi: 10.3978/j.issn.2095-6959.2018.10.037