

# Soft tissue tumors of the anorectum: rare, complex and misunderstood

Mohammed O. Nassif<sup>1,2</sup>, Nora H. Trabulsi<sup>2,3</sup>, Kelli M. Bullard Dunn<sup>4</sup>, Ayoub Nahal<sup>5</sup>, Ari-Nareg Meguerditchian<sup>3</sup>

<sup>1</sup>Division of Experimental Surgery, McGill University, 845 Sherbrooke Street West Montreal, Quebec, Canada H3A 2T5; <sup>2</sup>Department of Surgery, King Abdulaziz University, P.O. Box 80205, Zip Code 21589, Jeddah, Saudi Arabia; <sup>3</sup>Department of Surgery, McGill University, 687 Pine Avenue West, Room S7.30 Montreal QC (Canada) H3A 1A1; <sup>4</sup>Department of Surgery, University of Louisville, Louisville KY 40292, USA; <sup>5</sup>Department of Pathology, McGill University, 1650 Cedar Avenue, Room D3-257 Montreal, QC (Canada) H3G 1A4

Corresponding to: Ari Meguerditchian. Department of Surgery, McGill University, 687 Pine Avenue West, Room S7.30 Montreal QC (Canada) H3A 1A1. Email: ari.meguerditchian@mcgill.ca.

**Abstract:** Anorectal soft tissue tumors are uncommon and often present both diagnostic and therapeutic challenges. Although many of these tumors are identified with imaging performed for unrelated reasons, most present with nonspecific symptoms that can lead to a delay in diagnosis. Historically, radical surgery (abdominoperineal resection) has been the mainstay of treatment for both benign and malignant anorectal soft tissue tumors. However, a lack of proven benefit in benign disease along with changes in technology has called this practice into question. In addition, the role of radiation and/or chemotherapy remains controversial. In this manuscript, we review the history and current status of anorectal soft tissue tumor management, with a particular focus on challenges in optimizing survival.

**Key Words:** Soft tissue neoplasms; anus; rectum; surgery; sarcoma



Submitted Jan 13, 2012. Accepted for publication Aug 27, 2012.

doi: 10.3978/j.issn.2078-6891.2012.042

Scan to your mobile device or view this article at: <http://www.thejgo.org/article/view/545/html>

## Introduction

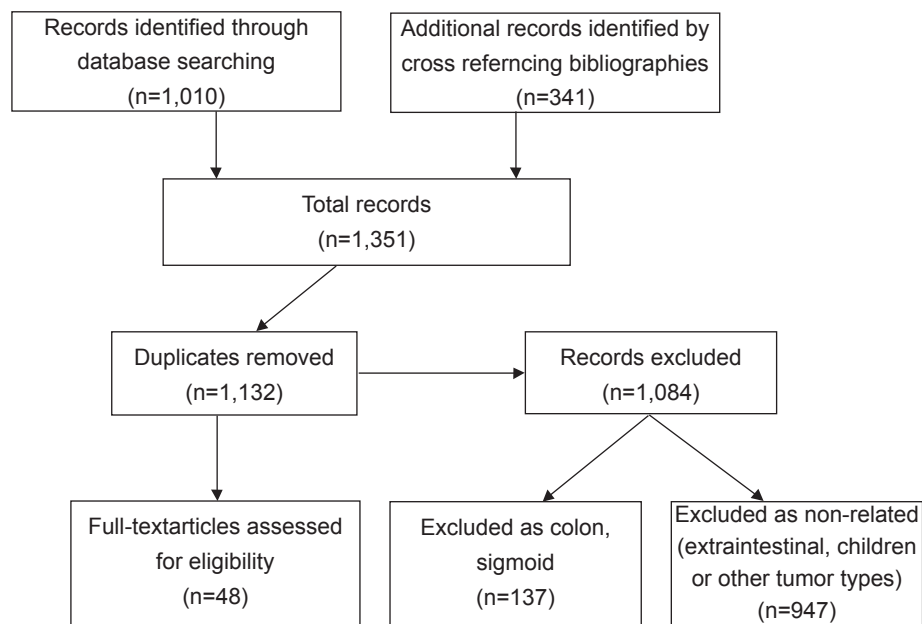
Anorectal soft tissue tumors (ARST) are a heterogeneous group of uncommon neoplasms that range from aggressive malignancies to benign but symptomatic lesions located in an anatomically complex site. ARSTs account for approximately 1% of all small and large bowel tumors (1), and constitute less than 0.1% of colon and rectal malignancies (2). Since the first case report in 1881 (3), a number of isolated case reports and small, single institution series have been published. The majority of cases described are gastrointestinal stromal tumors, and only a few papers address the rarer ARSTs. Due to the rarity of these cases, there is an obvious lack of randomized trials and well-defined practice guidelines for treating these patients. However, with the ever-increasing use of abdominopelvic imaging (computed tomography and magnetic resonance), it might be expected that an increasing number of ARSTs will be diagnosed. As such, we set out to review the current understanding of diagnosis and treatment of these lesions.

## Methods

A literature search was conducted using Pubmed and

Embase electronic databases. The following MESH terms were used for disease location: “rectum” “anus”, “perianal”. “Colon” and “sigmoid” were included in our search, to avoid missing anorectal cases reported in broad under “colon” or “sigmoid” series. In addition to “soft tissue neoplasms”, MESH terms of the following more frequent types of soft tissue disease were used: “leiomyosarcoma”, “angiosarcoma”, “liposarcoma”, “dermatofibrosarcoma protuberans”, “malignant fibrous histiocytoma”, “rhabdomyosarcoma”, “neurilemmoma”, “solitary fibrous tumor”, “gastrointestinal stromal tumor” and “desmoid tumor”.

All articles related to humans and published in English between 1980 and 2011 in peer-reviewed journals were considered. The articles retrieved were reviewed independently by two of the authors (MON and ANM). To ensure that all relevant publications were captured, we performed a second literature search by cross-referencing bibliographies of all previously retained articles. Duplicate articles as well as those without a specific anorectal focus were then discarded. A total of 48 articles were retained from an initial list of 1,351 publications (*Figure 1*), based on



**Figure 1** Literature search and review algorithm

**Table 1** Summary of published literature on ARSTs

|                                | Case reports | Case series | Number of patients | Average age (in years) | Sex ratio (male/female) | Average size (in cm) |
|--------------------------------|--------------|-------------|--------------------|------------------------|-------------------------|----------------------|
| Leiomyosarcoma                 | 0            | 1           | 480                | 50-69                  | 1.43 to 1               | 5-9                  |
| Rhabdomyosarcoma               | 9            | 2           | 12                 | 37                     | 1 to 1                  | 6                    |
| Angiosarcoma                   | 9            | 2           | 12                 | 57                     | 1 to 2                  | 5.4                  |
| Malignant fibrous histocytoma  | 8            | 0           | 8                  | 51                     | 3 to 1                  | 6                    |
| Dermatofibrosarcomaprotuberans | 2            | 0           | 2                  | NA                     | 2 males                 | NA                   |
| Shwannoma                      | 9            | 1           | 11                 | 62                     | 1.2 to 1                | 4.3                  |
| Solitary fibrous tomur         | 4            | 1           | 5                  | 45                     | 4 to 1                  | 10                   |
| Total                          | 41           | 7           | 530                | -                      | -                       | -                    |

NA, Not applicable

abstract review. These 48 papers then underwent complete manuscript review and data extraction to be included in this report (*Table 1*).

## Findings

### *Leiomyosarcoma*

Leiomyosarcomas (LMS) are malignant soft tissue neoplasms arising from smooth muscle tissue located within the muscularis mucosa, muscularis propria and blood or lymphatic vessels (4). LMSs are rare, but are the most common histological type of ARST, making up over 90% of reported cases (5). In a 2000 review by Hatch *et al.*, 480 anorectal LMS cases were identified in the literature (6). They found the peak incidence of cases occurred at 50-

69 years of age and only 6.4% of them were located to the anus. There seems to be a male predominance for LMSs of the rectal region and a female predominance for tumors occurring within the anal canal (7). Anal lesions are often plaque-like protrusions arising intra-murally or sub-mucosally from the posterior aspect of the anorectum, with areas of pressure ulceration (8-10).

Histologically, LMSs feature spindle cells with elongated, blunt-ended nuclei in an eosinophilic cytoplasm. These cells exhibit a fascicular growth pattern originating from vascular tissue or muscularis mucosa (11). LMS frequently exhibit high mitotic activity, often greater than 50 mitosis per 50 high-powered fields (HPF) (12). Immunohistochemically, these tumors are positive for vimentin, actin, smooth muscle myosin and desmin, but

are CD34, CD117 and K-RAS negative (12-15). Because of histological similarities, LMSs are often misdiagnosed as leiomyomas. K-RAS negativity, high mitotic activity, large tumor size, nuclear and cellular atypia as well as large size of the tumor and the presence of extensive necrosis are useful in confirming the diagnosis of LMS (16).

Almost all the cases of anorectal LMS reported in the literature were treated with surgical excision (abdominoperineal resection (APR) or wide local excision). Operative choice was most often dictated by high cellularity and tumor size rather than anatomic location (6). Higher rates of recurrence have been reported with local excision (67%) compared to APR (19%) in some series (17). In contrast, other series report similar outcomes regardless of surgical approach (18,19). Anorectal LMSs were traditionally thought of as resistant to both chemotherapy and radiation. However, this notion is largely based on sporadic case reports (19) or publications predating the advent of megavolt radiotherapy. More recent experience suggests a possible role for pre-operative chemotherapy and/or radiotherapy in sphincter preserving surgeries, but the relatively small series do not allow definitive conclusions (10,20,21).

LMSs rarely metastasize through lymphatics and are more likely to spread through the lungs and liver through hematogenous spread (22-24). Recurrence rates for anorectal LMS are associated with high histological grade, large tumor size and incomplete surgical resection (16). Five year survival reported as varying between 20-25% with poor prognosis overall in rectal leiomyosarcomas (25-28).

### ***Rhabdomyosarcoma***

Rhabdomyosarcoma (RMS) is one of the most common childhood soft tissue tumors, but represents less than 5% of malignant soft tissue lesions in adults (29-31). Anorectal presentation is extremely rare and is seen in less than 2% of cases (32). In this location, these tumors are thought to arise from the muscular layers of the bowel and the genitourinary tract. Most of the data on this disease originates from studies conducted between 1972 and 1997 by the Intergroup RMS Society for the RMS population aged 0-21 years (33). In these studies, cases with anorectal involvement were analyzed separately and a practice guideline has been developed (discussed below) (34). Although, designed originally for children, it is also used for adults, due to the small number of RMS cases in this population (35). It has been postulated that perineal RMS occurring at a younger age may have a genetic predisposition and is related to other genetic syndromes such as Nijmegen breakage syndrome (36). No similar syndromic associations have been observed in adults.

RMS is described as a grossly unencapsulated lesion with multiple areas of spherical growth, often resembling a “bunch of grapes” that is soft in consistency. Histologically, it is divided into three major types: embryonal, including spindle and botryoid subtypes, alveolar and undifferentiated (37). As a result of its mesodermal/muscle tissue origin, RMSs tend to show multiple areas of muscle tissue at different stages of development. Embryonal type shows a spindle shape pattern often arranged in patches of highly cellular areas alternating with sparsely cellular areas containing mucoid cytoplasm which is often a hallmark of the diagnosis (38). Immunohistochemically, these tumors react positively to a number of stains, including myogenin, myoD1, sarcomeric actin, myosin, desmin and vimentin; however alpha actinin, z-protein and titin are more specific to the condition (39-41). The alveolar subtype has a gross appearance of more circumscribed edges and a firmer, more rounded consistency. Microscopically, these tend to contain rounded, small acidophilic cells separated by collagen tissue with a broken off appearance with occasional giant cell formation. They tend to have larger nuclei and heavier chromatin patterns than embryonal types. Immunohistochemical profiling is the same as embryonal but staining for anti-skeletal muscle antibody and S100 protein was also documented (42,43). A study of 24 RMS of different types, showed all cases staining positively for Ankyrin-Repeated Proteins “Arpp/Carp” (44).

RMS is harder to diagnose in adults, with more advanced disease at presentation (34). This may be due to the fact that symptoms (tenesmus, pain on defecation or fever along with mild leukocytosis in some cases) tend to present later, probably because of a larger space for the tumor to grow. There is also a higher risk of misdiagnosis with diseases of infectious or inflammatory origin, such as perianal abscesses (45-47). In addition, younger patients and especially infants tend to be examined more often by parents during diaper changes possibly explaining why RMS is picked up earlier (34).

The mainstay of RMS treatment is resection to negative margins and a combination of chemotherapy and radiation therapy. Pediatric RMS guidelines state that microscopically negative margins should be obtained and ipsilateral lymph node basins (inguinal, retroperitoneal) should be excised in patients older than 10 years. Although unproven, these guidelines have been used for treating adults as well. The use of chemotherapy combining Vincristine, Actinomycin D, Cyclophosphamide and Adriamycin in conjunction with external beam radiotherapy for patients with positive margins, and local node involvement has also been advocated (34). However, radiotherapy is often associated with dermatopathy, anal stenosis and genitourinary

complications (48). Because aggressive surgery often results in sacrificing the function of the anorectum, sporadic attempts have been made at neoadjuvant chemotherapy to reduce tumor size and improve resectability. Intraoperative radiation therapy also has been sporadically used.

Twelve adult cases of anorectal RMS have been reported (45-47,49-56), ranging between the ages of 18 and 71. Seven patients had radical surgery (APR or anterior resection), three had local excision and two never underwent an operation (patient refusal and bony metastasis at presentation). Half the patients had adjuvant chemoradiation with a combination of Vincristine, Actinomycin-D, Adriamycin and/or ifosfamide. Neoadjuvant therapy was used in two patients. Ten of the twelve cases had follow up data reported. Among these, 3 patients recurred within 6 months of surgery. There were 5 deaths, including the 2 patients that never underwent operation. The longest disease-free follow up period was 12 years (54). Interestingly, the patient having undergone transanal excision was reported to be disease free 7 years post resection (55).

More recently, these efforts appear to have reduced perioperative morbidity and mortality (35,57). Watanabe *et al.* reported that patients given neoadjuvant chemotherapy followed by local excision had better tumor free survival and lower local recurrence rates than that of those treated by APR without neoadjuvant chemotherapy in addition to the anal function preservation. Nevertheless, we had decided to exclude this series because it was based on personal communications and cases reported in the Japanese language literature.

It is thought that because of the delays in diagnosis discussed above, the prognosis of RMS in adults is worse than the younger age groups. The 5-year disease free survival (DFS) is 18% in adults versus 65% in children and the overall survival (OS) of 20% in Adults versus 71% in children (34). Other factors influencing survival include regional lymph node involvement (5 year DFS of patients without lymph node involvement was 63% versus 32% for node positive cases), evidence of distant metastasis and primary tumor size (5 year DFS of 71% in tumors less than 5 cm compared to 31% in those greater).

### *Angiosarcoma*

Angiosarcoma (AS) accounts for 4.1% of all soft tissue malignancies. This disease has undergone numerous name changes (hemangioendothelioma, hemangiosarcoma, malignant angioendothelioma and lymphangiosarcoma), reflecting progressive growth in our understanding of tumors originating from

vascular and lymphatic walls (58). AS is more frequent in Caucasians and males (59), is associated with radiation exposure (60) and has been linked with chemotoxins such as vinyl chloride, arsenic, thorium dioxide as well as long-term exposure to drugs such as androgens (61,62). Four of the anorectal AS cases we identified (25%) had prior history of pelvic irradiation supporting the association of radiation with AS incidence (63-66). One patient had a longstanding foreign body in the pelvis from previous surgery (67) while another had previous history of chronic rectal ulceration from recurrent abscess and fistulae. Both these cases support the suggestion that some sarcomas originate from sites with chronic inflammation (68).

ASs present as firm, highly vascular lesions that may be mistaken for carcinoma or melanoma on gross pathological examination. Microscopically, hematoxylin and eosin (H & E) staining alone can be difficult in yielding a positive diagnosis of malignancy as it will show vascular channels lined with only subtly abnormal endothelial cells, often mimicking benign hemangiomas (69). Because of this relative lack of specific morphology, and the frequent absence of the diagnostic abnormal vascular channels in the poorly differentiated forms, immunohistochemical stains are often employed to confirm the diagnosis and they include vimentin, CD 31, CD 34 and BNH9 (an endothelial marker). Epithelial markers such as CAM 5.2 are used to confirm the presence of an epithelioid variant of AS (70-72).

There are no clear guidelines on the management of anorectal AS. We know from other sites that surgery and radiation therapy have an important role. For example, in a retrospective review of 67 patients with non-anorectal AS, Mark *et al.* showed a 5-year disease-free survival of 43% in patients who underwent surgery and radiation as opposed to 17% in patients who underwent surgery without radiation (73). The role for chemotherapy on the other hand is still under investigation, with some response reported with Paclitaxel, Docetaxel, Doxorubicin and Daunorubicin (74).

There are 12 cases of AS of the rectum reported in the literature and none of the anus (63-68,75-79). Among these, one had metastasis to bone and two had lymph node involvement at the time of diagnosis (66,67,76). Average age at presentation was 57 years (range, 30-79) and 75% of patients were women. Tumor size ranged between 2 and 16.5 cm (average: 5 cm).

Eight patients underwent surgical excision: 6 radical resections (APR or anterior resection) and 2 local excisions. Of these, 6 also received adjuvant radiation therapy. Of the four non-surgical cases published, 2 were treated with radiotherapy and no treatment details were provided for the remaining 2. Seven of these publications reported follow up

data. The longest disease-free survival was 27 months in a young patient treated by posterior exenteration followed by chemotherapy and radiation. Three patients were reported to have died of their disease, all within 8 months. Raising questions about the appropriateness of their preoperative staging (66,67,79).

There are too few anorectal AS cases to support prognostic associations, however, a recent review of colon AS has shown that tumor size (>5 cm), node positivity and distant metastasis all correlated with poor prognosis (80). At the moment, two phase II trials are studying the use of bevacizumab with radiation in the treatment of AS (74). Although these trials do not specifically target anorectal AS, it is hoped that positive findings would translate into easier treatment planning for AS of the anus and rectum.

### *Dermatofibrosarcoma protruberans*

Dermatofibrosarcoma protruberans (DFSP) is thought to arise as a result of the chromosomal translocation t[17;22] in 90% of cases. As a result, the COL1A1 gene fuses with a platelet derived growth factor (PDGF) gene in fibroblasts, leading to over production of PDGF, which is a growth stimulant, thinking it is a structural protein. Fibroblasts contain the receptor for PDGF and thus further stimulating release, growth and mitosis (81,82). DFSP has a 0.4% incidence of distant metastasis, but close to 25% local recurrence rate (83,84). This is attributed to the tentacle-like projections of the tumor into the subcutaneous tissue, making the assurance of adequate negative margins one of the key prognostic factors in the management of DFSP (85).

The incidence of DFSP is thought to be 4.2 per million people annually in North America, with the vast majority of cases (42%) occurring in the truncal area and the remainder in the upper extremity, lower extremity, head and neck (83).

DFSP appears as a solid, nodular polypoid tumor almost always arising from the dermis, with invasion into the subcutaneous tissue. Microscopically, it is characterized by a whorl-like spindle cell pattern of monomorphic fibroblast growth, accompanied usually by a low mitotic activity. In cases where the subcutaneous layer is invaded there is often evidence of entrapment of adipose tissue between extending "limbs" of fibroblast growth. Immunohistochemically, DFSP lesions often exhibit vimentin and CD34 reactivity with occasional focal actin staining and are often negative for factor XIIIa, keratin and S-100 proteins (86).

The treatment of DFSP is surgical and the standard is wide local excision with at least 2 cm margins (87). Given the high recurrence rate, a negative margin is of utmost importance but is hard to achieve in areas close to critical

perineal structures such as the anal sphincters and therefore MMS should be considered, especially for small, distal and superficial lesions (88). There have been numerous analyses comparing wide excision to MMS for other disease sites, most with small patient numbers and varying outcomes. A retrospective review comparing the two in 48 patients concluded that although MMS provided fewer incidences of positive margins, it also required longer operative time, higher cost and a higher incidence of complex closure requiring graft or flap (89).

Given that 90% of DFSP cases have a t[17;22] chromosomal translocation and over expression of the (PDGF) gene explained previously, clinical trials with imatinib mesylate have recently been conducted. In a pool of 24 cases from two phase II trials in which daily imatinib was given to patients with locally advanced or metastatic DFSP, 45.9% of the patients showed at least partial response (90). These trials and other reports set the ground for the use of imatinib in the neoadjuvant setting and a phase II trial of 21 patients with positive fusion gene "COL1A1 & PDGF" (91). Eight patients (31%) had complete or partial response with a median 20% decrease in size. This limited data opens the possibility of considering imatinib mesylate preoperatively for anorectal DFSP, in cases where the extent of excision is an issue.

There are only two reported cases of DFSP involving the anorectal region (92,93). One was a four year old child with no co-morbidities and a background history of trauma to the region. The tumor initially involved the right scrotum and then extended onto the anal margin. The lesion was excised using Mohs micrographic surgery (MMS) (92). The second was a 67 year old man who presented with a 3-cm irregular, mobile, elevated, red, polypoid lump at the edge of the anus. MRI of the pelvis showed the mass extending into the ischioanal space with no sphincter involvement. The patient underwent wide excision, however margins were involved and re-excision with wider margins using skin rotation flaps was required. In both cases sphincter preservation and long term follow up were not reported (93).

### *Malignant fibrous histiocytoma*

Malignant fibrous histiocytoma (MFH) was first described in 1963 by Ozello and Stout (94,95). Its existence as a distinct entity started being questioned in 1987 by Fletcher (96,97). By 2008 it was generally agreed that MFH was not a distinct disease (98). In fact It has been shown with immunohistochemistry that 63% of these tumors are other histological types "mainly liposarcomas" and the remainder were classified as myxofibrosarcoma, angiomatoid fibrous histiocytoma and undifferentiated pleomorphic sarcoma (99).



Nevertheless prior to this change in disease classification, eight cases of anorectal MFH were reported (100-107). When confronted with this pathological diagnosis the appropriate course of action should be to request further immunohistochemistry for more accurate diagnosis.

### *Solitary fibrous tumors*

Various terms have been used to describe solitary fibrous tumors (SFT), since their initial description in 1931 (108), including localized fibrous mesothelioma, fibrous tumor of the pleura, fibromyxoma and submesothelioma (109). SFT has been described in many non-pleural sites (110-114). Little is known about the natural history and malignant potential of these; however the literature suggests that the majority (78-88%) are histologically benign (115).

Morphologically, SFTs are well-circumscribed, non-encapsulated, yellow or grey-white lesions, with a firm consistency. They rarely show cystic degeneration or necrosis upon imaging (116). Microscopically, SFTs form spindle cells which may be arranged in a storiform pattern or haphazardly along with fibroblast-like cells arranged in a "patternless pattern". There are variations in cellularity and cytoplasmic volume. The fibroblast-like cells and spindle cells appear between collagen fibers in a keloid-like formation with blood vessels arranged in a hemangiopericytoma-like pattern. Lipomatous and lymphatic tissue may also be present within the tumor sections (117-120). The presence of necrosis, hemorrhage, increased atypia and high mitotic rate (greater than 1 per 10 HPF) are considered signs of malignant potential (120). On immunohistochemical staining, SFTs are CD 34, vimentin and Bcl-2 positive and negative for keratin and S100 (121,122). They occasionally exhibit desmin positivity, suggesting that combined CD 34 and Bcl-2 staining would yield a definitive diagnosis in borderline cases where similarity to other tumors such as fibrosarcomas and giant cell angiofibromas makes a definitive diagnosis problematic (122).

The principles of management of SFTs are based on how pleural SFTs are treated. Surgical excision with pathological negative margins is the norm. The addition of adjuvant radiotherapy has been reported in select cases, when there is incomplete resection of the tumor especially for the malignant variety. Although ifosafamide and doxorubicin have been reported beneficial for recurrent or inoperable SFT, repeat surgical resection should be sought first. Also, neoadjuvant radiation therapy or brachytherapy have been described for large malignant tumors although this is not supported by evidence (123).

Generally SFTs carry a good prognosis, with low

recurrence and metastasis rates. In fact, systemic spread is described in only 8% of cases reported in the literature (115). Higher rates of local recurrence are generally reported for extra-pleural SFTs probably due to smaller excision margins in relation to the anatomic localization of the tumor (118). Positive margins, tumors size greater than 10 cm or malignant histology, are risk factors for local failure for extra-pleural SFTs (118). One study found that the rate of local recurrence is 8 fold greater in cases with malignant features (115). The metastatic potential of extra-pleural SFTs appears to be low (124).

There are only 5 reported cases of anorectal SFT (124-128). Two cases occurred within the ischioanal fossa, one was of rectal origin and reoccurred in the perineum, one originated in the mesorectum and one involved both the rectum and uterus. Four out of 5 patients were male and mean age at diagnosis was 45. Average tumor size was 10 cm (range, 7-13 cm). All cases were treated surgically. Two patients had excision of the tumor through an abdominal approach, with sparing of the rectum (126,127); two patients underwent an APR (124,128), one underwent a perineal extra-peritoneal procedure. None of the patients received adjuvant chemotherapy or radiation.

Follow up data was available in only 3 out of the 5 cases, and ranged from 6 months to 13 years. Both patients who underwent APR had local recurrence, at 6 months (124) and 13 years (128) and received radiotherapy with embolization of the internal pudendal arteries to reduce the tumors size prior to re-excision. No systemic metastasis has been reported from any of the anorectal SFT cases.

Excision with clear margins should always be the goal for anorectal SFT, however, optimal margin size remains unknown. Radiotherapy should be reserved for cases with malignant features, positive margins, unresectability or preoperatively in the case of recurrence (115). However, radiation does not replace proper negative margin surgical technique. Similar to SFT of the pleura, systemic therapy with ifosfamide or doxorubicin may be considered in recurrent cases or those that show malignant features (123).

### *Schwannoma*

While historically viewed as a subtype of gastrointestinal autonomic nerve tumors (GANTs), schwannomas are now regarded as a separate entity due to their unique immunohistochemical characteristics (129-131). These tumors are thought to be benign with little risk of malignant transformation (132). They arise from neural crest cells and can therefore occur in any anatomical region (133). Von Reckelhausen's disease, familial adenomatous polyposis and

multiple endocrine neoplasia type 2b have all been reported as risk factors for the condition (134).

Grossly these tumors often appear as firm yellow or brown colored lesions which may be pedunculated or sessile. They are almost always restricted to the sub-mucosa, extending from the lamina propria with an aggregate band or surrounding coating of white lymphoid tissue and can vary in size between 1.5-12 cm owing to their largely benign slow growing nature (135). Histologically, they can be divided into 3 subclasses plexiform, epithelioid and spindle cell. Spindle cell schwannomas are characterized by spindle cells arranged in a trabecular pattern with septations by fibrovascular tissue, no verocay bodies and weak nuclear palissading and are often encapsulated by a discontinuous cuff of lymphoid hyperplasia. Mitotic activity rarely exceeds 5 per 50 HPF and nuclear atypia with hyperchromasia is almost always a feature of these tumors (133,135). Epithelioid schwannomas feature epithelioid cells arranged in a sheet or cord like pattern with vacuolar spaces in a pseudoglandular pattern with no verocay bodies or palissading but with evidence of lymphoid infiltration with hyaline changes in bigger tumors (133,135). Without special staining, many schwannomas were previously misdiagnosed as gastrointestinal stromal tumors (GISTS) and GANTs, which raises questions as to its true incidence (131,135). Schwannomas are uniformly S-100 positive (133-135), and almost always positive for vimentin reactivity however they are rarely CD 34 positive and almost always negative for GFAP, Desmin, Alpha smooth muscle actin and C-kit. In this context theoretically the use of CD 117 (C-Kit) and S-100 staining should be enough to differentiate schwannomas from GISTS (131,135).

The management of anorectal schwannomas is surgical excision. A variety of surgical approaches have been reported, from abdominoperoneal resection to transrectal micro-surgical approaches, however the most appropriate procedure has not yet been defined. Controversy exists because of the submucosal nature of these lesions, making obtaining a definitive tissue diagnosis challenging and in the context of a high suspicion of malignancy wide excision is often undertaken without positive pathology. More recent studies suggest that because of the low chance of malignant transformation, the slow growing nature of these tumors and reported disease-free survival of up to 18 years, local excision with surveillance is the best course of action without adjuvant treatment if a preoperative biopsy is definitive (135,136).

Only eleven cases of anorectal schwannoma have been reported (135-144). Three of these were schwannoma cases classified as a subtype of GANT (136,140,142). There were no malignant anorectal schwannomas reported in the

English literature, however, we did find two such cases in German and Italian (145,146).

Symptoms most commonly reported included constipation and tenesmus, however most schwannomas were found incidentally during imaging for unrelated reasons. These cases tended to occur later in life, with an average age of 62, although one patient was diagnosed with a schwannoma at 28. There was no gender predilection and no deaths from anorectal schwannoma were reported.

### Guiding principles and outlook

ARSTs represent a rare condition. LMSs are the most commonly identified histological type, representing 90.7% of the cases reported in this systematic review, confirming previous findings (5). Rhabdomyosarcomas are the second most common ARST in adults and the first in children (34). We did not identify a single case of liposarcoma originating from the anorectum, although there were a few retroperitoneal pelvic case reports.

Overall, we found a slightly higher incidence of ARSTs in males than in females (1.13:1), with an average age of 50.9 years and the average size at diagnosis of 5.8 cm. This is similar to the sex, age of incidence and size found in the leiomyosarcoma group and may in fact represent their numerical predominance in the cohort of patients we report (6). It is possible that more accurate diagnostic characterization of GISTS will decrease this relative predominance of LMSs. There has been significant interest in GISTS in the past decade and thoroughly documented reviews detail many aspects of this disease separately.

ARSTs present with a range of symptoms none of which are specific: constipation, diarrhea, rectal pain, tenesmus, weight loss and rectal bleed. In most cases however, ARSTs are an incidental finding on imaging done for other reasons. A complete history and physical with a rectal exam and rectoscopy is always warranted in these situations. Adequate imaging is essential and should provide specific details about location, size, homogeneity and proximity to visceral, vascular and neurological structures. A CT scan of the abdomen and pelvis is essential. Previous studies have proven that CT scans and MRI are equally adequate for soft tissue sarcomas and doing both does not improve accuracy (147). MRI should be considered if there is diagnostic uncertainty. Sigmoidoscopy or colonoscopy with a biopsy is mandatory and all patients should get a complete evaluation of the rest of their colon as many reports have been published of synchronous tumors including adenocarcinomas (148). Rectal endoscopic ultrasound (EUS) is a useful tool for biopsy if the initial sample is inconclusive, as many of these tumors are submucosal and

**Table 2** Soft tissue tumors and commonly associated immunohistochemical (IHC) markers

|                                 | Positive IHC markers  | Negative IHC markers        |
|---------------------------------|---|-----------------------------|
| Leiomyosarcoma                  | vimentin, actin, myosin, desmin, H-caldesmon  | CD34, CD117, K-RAS          |
| Rhabdomyosarcoma embryonal      | Myogenin, myoD1, Sarcomeric actin, myosin, desminvimentin, but alpha actinin, z-protein and titin are more specific                                       |                             |
| Rhabdomyosarcoma alveolar       | As embryonal type plus antiskeletal muscle antibodies, both have ankyrin-repeated protein Arpp/Carp   |                             |
| Angiosarcoma                    | CD31, CD34, CAM 5.2 (epithelioid variant), vWF, Factor VIII, BNH9   |                             |
| Malignant fibrous histiocytoma  | according to IHC markings should be categorized/regrouped under any of the other type-specific sarcoma groups and if not then labeled as Undifferentiated |                             |
| Dermatofibrosarcoma protuberans | Vimentin, CD34, Focal actin   | Factor XIIIa, keratin, S100 |
| Solitary fibrous tumor          | CD34, vimentin, Bcl2, occasionally desmin   | Keratin, S100               |
| Shwannoma                       | S100, vimentin, rarely CD34   | Actin, desmin, CD117, GFAP  |

IHC, Immunohistochemical; CD, Cluster differentiation molecule; myoD1, myogenic differentiation 1; Arpp, ankyrin-repeated protein with PEST and proline rich region; Carp, Cardiac ankyrin repeated protein; CAM, Cell Adhesion Molecule; vWF, von Willebrand Factor; BNH9, Monoclonal antibody BNH9; K-RAS, Kristen Rat Sarcoma viral oncogene homolog; Bcl2, B-Cell lymphoma2; GFAP, Glial Fibrillary Acidic Protein

hard to biopsy with colonoscopy. EUS can also help in distinguishing mucosal from submucosal lesion and soft tissue tumors from rectal carcinoma (149). If the mass is identified as a malignant sarcoma on pathology, a CT scan of the chest should be added. As in other locations, in case of angiosarcoma or alveolar soft part sarcoma (ASPS); cerebral metastasis is common and a CT scan of the head is also warranted (150).

Management of these cases should preferably be done in centers with expertise in both colorectal and soft tissue surgery. The rarity of these diseases warrants full imaging, pathological review (*Table 2*) and discussion at multidisciplinary tumor board. Some cases may require consideration of neoadjuvant radio and chemotherapy, however, the literature is scant on high quality evidence to support this. Most reviews agree that post operative radiation is a relevant if margins are positive and margin resections are not possible or if margins are less than 1cm, although there are no clinical trials to support this approach and the use of post-operative radiation therapy should not justify poor surgery or predictable positive margins. If neoadjuvant therapy is chosen then a positron emission tomography (PET) scan would be useful in monitoring the response to chemotherapy in these patients (151).

The standard curative approach for ARSTs is surgical excision, with wide local excision (WLE) and APR being the most frequently performed interventions. Endoscopic and transanal excision should be reserved for the tumors with benign features and low local recurrence rates but are expected to play an increasing role in the future management of ARST as they become widely available and

more refined. Curative resection remains the major determinant of recurrence and survival. Follow up of ARST patients should be similar to that of sarcomas of other sites with physical exam and CT imaging every 3-6 months for the first 2-3 years then every 6 months for 2 years then annually (152). Because this is a rare disease we do not expect large scale multicentre studies in the near future therefore it is advisable these patients be treated in multidisciplinary fashion in centers with colorectal and surgical oncology expertise.

### Acknowledgements

Dr Meguerditchian is supported by research grants from the Cedars Cancer Institute and the Fonds de la Recherche en Santé du Québec.

*Disclosure:* The authors declare no conflict of interest.

### References

1. Horowitz J, Spellman JE Jr, Driscoll DL, et al. An institutional review of sarcomas of the large and small intestine. *J Am Coll surg* 1995;180:465-71.
2. Walsh TH, Mann CV. Smooth muscle neoplasms of the rectum and anal canal. *Br J Surg* 1984;71:597-9.
3. Carlier. Myoide du Rectum: Extraction. *J Med Chir Pharmacol* 1881;12:140-3.
4. Anderson PA, Dockerty MB, Buie LA. Myomatous tumors of the rectum (leiomyomas and myosarcomas). *Surgery* 1950;28:642-50.
5. Meijer S, Peretz T, Gaynor JJ, et al. Primary colorectal



- sarcoma. A retrospective review and prognostic factor study of 50 consecutive patients. *Arch Surg* 1990;125:1163-8.
6. Hatch KF, Blanchard DK, Hatch GF 3rd, et al. Tumors of the rectum and anal canal. *World J Surg* 2000;24:437-43.
  7. Wang TK, Chung MT. Anorectal leiomyosarcomas. *J Gastroenterol* 1998;33:402-7.
  8. Feldtman RW, Oram-Smith JC, Teears RJ, et al. Leiomyosarcoma of the rectum: the military experience. *Dis Colon Rectum* 1981;24:402-3.
  9. Hishida Y, Ishida M. Smooth-muscle tumors of the rectum in Japanese. *Dis Colon Rectum* 1974;17:226-34.
  10. Minsky BD, Cohen AM, Hajdu SI, et al. Sphincter preservation in rectal sarcoma. *Dis Colon Rectum* 1990;33:319-22.
  11. Dahl I, Hagmar B, Angervall L. Leiomyosarcoma of the soft tissue. A correlative cytological and histological study of 11 cases. *Acta Pathol Microbiol Scand A* 1981;89:285-91.
  12. Miettinen M, Furlong M, Sarlomo-Rikala M, et al. Gastrointestinal stromal tumors, intramural leiomyomas, and leiomyosarcomas in the rectum and anus: a clinicopathologic, immunohistochemical, and molecular genetic study of 144 cases. *Am J Surg Pathol* 2001;25:1121-33.
  13. Brooks JJ. Immunohistochemistry of soft tissue tumors: progress and prospects. *Hum Pathol* 1982;13:969-74.
  14. Donner L, de Lanerolle P, Costa J. Immunoreactivity of paraffin-embedded normal tissues and mesenchymal tumors for smooth muscle myosin. *Am J Clin Pathol* 1983;80:677-81.
  15. Tsukada T, McNutt MA, Ross R, et al. HHF35, a muscle actin-specific monoclonal antibody. II. Reactivity in normal, reactive, and neoplastic human tissues. *Am J Pathol* 1987;127:389-402.
  16. Berridge DC. Leiomyosarcoma of the rectum. Report of two cases illustrating an unusual presentation and the need for repeated biopsy. *Dis Colon Rectum* 1987;30:721-2.
  17. Khalifa AA, Bong WL, Rao VK, et al. Leiomyosarcoma of the rectum. Report of a case and review of the literature. *Dis Colon Rectum* 1986;29:427-32.
  18. Quan SH, Berg JW. Leiomyoma and leiomyosarcoma of the rectum. *Dis Colon Rectum* 1962;5:415-25.
  19. Randleman CD Jr, Wolff BG, Dozois RR, et al. Leiomyosarcoma of the rectum and anus. A series of 22 cases. *Int J Colorectal Dis* 1989;4:91-6.
  20. Minsky BD, Cohen AM, Hajdu SI. Conservative management of anal leiomyosarcoma. *Cancer* 1991;68:1640-3.
  21. Minsky BD, Mies C, Rich TA. Leiomyosarcoma of the anus treated with sphincter-preserving surgery and radiation therapy. *J Surg Oncol* 1986;32:89-91.
  22. Lee YT. Leiomyosarcoma of the gastro-intestinal tract: general pattern of metastasis and recurrence. *Cancer Treat Rev* 1983;10:91-101.
  23. Adachi M, Wellmann KF, Garcia R. Metastatic leiomyosarcoma in brain and heart. *J Pathol* 1969;98:294-6.
  24. Lopez FF, Mangi A, Mylonakis E, et al. Atrial fibrillation and tumor emboli as manifestations of metastatic leiomyosarcoma to the heart and lung. *Heart Lung* 2000;29:47-9.
  25. Kusminsky RE, Bailey W. Leiomyomas of the rectum and anal canal: report of six cases and review of the literature. *Dis Colon Rectum* 1977;20:580-99.
  26. Mindich B, Tykot H, Littman L, et al. Leiomyosarcoma of the rectum: report of a case. *Dis Colon Rectum* 1975;18:233-6.
  27. Nemer FD, Stoeckinger JM, Evans OT. Smooth-muscle rectal tumors: a therapeutic dilemma. *Dis Colon Rectum* 1977;20:405-13.
  28. Neuman Z. Leiomyosarcoma of the rectum, developing from benign leiomyoma. *Ann Surg* 1952;135:426-30.
  29. Hicks J, Flaitz C. Rhabdomyosarcoma of the head and neck in children. *Oral Oncol* 2002;38:450-9.
  30. Sandberg AA, Stone JF, Czarnecki L, et al. Hematologic masquerade of rhabdomyosarcoma. *Am J Hematol* 2001;68:51-7.
  31. Stindl R, Fiegl M, Regele H, et al. Alveolar rhabdomyosarcoma in a 68-year-old patient identified by cytogenetic analysis of bone marrow. *Cancer Genet Cytogenet* 1998;107:43-7.
  32. Raney RB Jr, Crist W, Hays D, et al. Soft tissue sarcoma of the perineal region in childhood. A report from the Intergroup Rhabdomyosarcoma Studies I and II, 1972 through 1984. *Cancer* 1990;65:2787-92.
  33. Neville HL, Andrassy RJ, Lobe TE, et al. Preoperative staging, prognostic factors, and outcome for extremity rhabdomyosarcoma: a preliminary report from the Intergroup Rhabdomyosarcoma Study IV (1991-1997). *J Pediatr Surg* 2000;35:317-21.
  34. Blakely ML, Andrassy RJ, Raney RB, et al. Prognostic factors and surgical treatment guidelines for children with rhabdomyosarcoma of the perineum or anus: a report of Intergroup Rhabdomyosarcoma Studies I through IV, 1972 through 1997. *J Pediatr Surg* 2003;38:347-53.
  35. Watanabe Y, Yamaguchi A, Isogai M, et al. Treatment strategies for perianal rhabdomyosarcoma: report of two cases. *Surg Today* 2004;34:719-24.
  36. Meyer S, Kingston H, Taylor AM, et al. Rhabdomyosarcoma in Nijmegen breakage syndrome: strong association with perianal primary site. *Cancer Genet Cytogenet* 2004;154:169-74.
  37. Newton WA Jr, Gehan EA, Webber BL, et al. Classification of rhabdomyosarcomas and related

- sarcomas. Pathologic aspects and proposal for a new classification--an Intergroup Rhabdomyosarcoma Study. *Cancer* 1995;76:1073-85.
38. Cho KR, Olson JL, Epstein JL. Primitive rhabdomyosarcoma presenting with diffuse bone marrow involvement: an immunohistochemical and ultrastructural study. *Mod Pathol* 1988;1:23-8.
  39. Kahn HJ, Yeger H, Kassim O, et al. Immunohistochemical and electron microscopic assessment of childhood rhabdomyosarcoma. Increased frequency of diagnosis over routine histologic methods. *Cancer* 1983;51:1897-903.
  40. Mukai M, Iri H, Torikata C, et al. Immunoperoxidase demonstration of a new muscle protein (Z-protein) in myogenic tumors as a diagnostic aid. *Am J Pathol* 1984;114:164-70.
  41. Osborn M, Hill C, Altmannsberger M, et al. Monoclonal antibodies to titin in conjunction with antibodies to desmin separate rhabdomyosarcomas from other tumor types. *Lab Invest* 1986;55:101-8.
  42. Seidal T, Mark J, Hagmar B, et al. Alveolar rhabdomyosarcoma: a cytogenetic and correlated cytological and histological study. *Acta Pathol Microbiol Immunol Scand A* 1982;90:345-54.
  43. Om A, Ghose T. Use of Anti-Skeletal Muscle Antibody from Myasthenic Patients in the Diagnosis of Childhood Rhabdomyosarcomas. *Am J Surg Pathol* 1987;11:272-6.
  44. Ishiguro N, Baba T, Ishida T, et al. Carp, a cardiac ankyrin-repeated protein, and its new homologue, Arpp, are differentially expressed in heart, skeletal muscle, and rhabdomyosarcomas. *Am J Pathol* 2002;160:1767-78.
  45. Bacon HE, Herabat T, Koohdary A, et al. Pararectal rhabdomyosarcoma: report of a case. *Dis Colon Rectum* 1974;17:365-9.
  46. Sasajima K, Okawa K, Sasamoto Y, et al. Pararectal rhabdomyosarcoma: report of a case. *Dis Colon Rectum* 1980;23:576-7.
  47. Ali R, Ozkalemkas F, Ozan U, et al. Rhabdomyosarcoma of the perianal region presenting as acute leukemia. *Ann Hematol* 2004;83:729-30.
  48. Haisfield-Wolfe ME, Rund C. A nursing protocol for the management of perineal-rectal skin alterations. *Clin J Oncol Nurs* 2000;4:15-21.
  49. Pack GT, Miller TR, Trinidad SS. Pararectal rhabdomyosarcoma: report of two cases. *Dis Colon Rectum* 1963;6:1-6.
  50. Fisher ER, Gruhn J. Perianal rhabdomyosarcoma. *AMA Arch Surg* 1958;77:230-4.
  51. Becker V, Gaa J, Ott K, et al. A rare case of primary rectal rhabdomyosarcoma in an adult. *Z Gastroenterol* 2006;44:1149-52.
  52. Roncaroli F, Montironi R, Feliciotti F, et al. Sarcomatoid carcinoma of the anorectal junction with neuroendocrine and rhabdomyoblastic features. *Am J Surg Pathol* 1995;19:217-23.
  53. Kessler KJ, Kerlakian GM, Welling RE. Perineal and perirectal sarcomas: report of two cases. *Dis Colon Rectum* 1996;39:468-72.
  54. Grobmyer SR, Clary B, Lewis JJ, et al. Adult perineal sarcomas. *J Surg Oncol* 2001;77:101-4.
  55. Marnewick J, Hulme-Moir M. Embryonal rhabdomyosarcoma of the rectum: report of a case and possible treatment option. *Colorectal Dis* 2010;12:e170-1.
  56. Meng MV, Grossfeld GD, Sudilovsky D, et al. Fine needle aspiration cytology of adult perineal rhabdomyosarcoma: a case report. *Acta Cytol* 2006;50:88-92.
  57. Okamura K, Yamamoto H, Ishimaru Y, et al. Clinical characteristics and surgical treatment of perianal and perineal rhabdomyosarcoma: analysis of Japanese patients and comparison with IRSG reports. *Pediatr Surg Int* 2006;22:129-34.
  58. Fedok FG, Levin RJ, Maloney ME, et al. Angiosarcoma: current review. *Am J Otolaryngol* 1999;20:223-31.
  59. Toro JR, Travis LB, Wu HJ, et al. Incidence patterns of soft tissue sarcomas, regardless of primary site, in the surveillance, epidemiology and end results program, 1978-2001: An analysis of 26,758 cases. *Int J Cancer* 2006;119:2922-30.
  60. Mery CM, George S, Bertagnolli MM, et al. Secondary sarcomas after radiotherapy for breast cancer: sustained risk and poor survival. *Cancer* 2009;115:4055-63.
  61. Falk H, Thomas LB, Popper H, et al. Hepatic angiosarcoma associated with androgenic-anabolic steroids. *Lancet* 1979;2:1120-3.
  62. Popper H, Thomas LB, Telles NC, et al. Development of hepatic angiosarcoma in man induced by vinyl chloride, thorotrast, and arsenic. Comparison with cases of unknown etiology. *Am J Pathol* 1978;92:349-76.
  63. Ahmad A, Jamieson T, Balsitis M, et al. Radiation-induced angiosarcoma of the rectum: a case report and review of literature. *Colorectal Dis* 2008;10:847-8.
  64. Jahn SW, Liegl B, Leskowschek H, et al. Angiosarcoma at the anastomotic site mimicking local recurrence of rectal adenocarcinoma. *Endoscopy* 2011;43 Suppl 2 UCTN:E293-4.
  65. Lee JY, Oh SR, Yang BJ, et al. A Case of Angiosarcoma in Rectum. *The Korean Study of Intestinal Disease* 2011;9:57-60.
  66. Tardío JC, Nájera L, Alemany I, et al. Rectal angiosarcoma after adjuvant chemoradiotherapy for adenocarcinoma of the rectum. *J Clin Oncol* 2009;27:e116-7.
  67. Ben-Izhak O, Kerner H, Brenner B, et al. Angiosarcoma of the colon developing in a capsule of a foreign body. Report

- of a case with associated hemorrhagic diathesis. *Am J Clin Pathol* 1992;97:416-20.
68. Lo YM, Gillett MB, Vina M, et al. Hemangiosarcoma of the rectum after chronic anorectal ulceration. *J Clin Gastroenterol* 1989;11:77-81.
  69. Meis-Kindblom JM, Kindblom LG. Angiosarcoma of soft tissue: a study of 80 cases. *Am J Surg Pathol* 1998;22:683-97.
  70. Fletcher CD, Beham A, Bekir S, et al. Epithelioid angiosarcoma of deep soft tissue: a distinctive tumor readily mistaken for an epithelial neoplasm. *Am J Surg Pathol* 1991;15:915-24.
  71. Alles JU, Bosslet K. Immunocytochemistry of angiosarcomas. A study of 19 cases with special emphasis on the applicability of endothelial cell specific markers to routinely prepared tissues. *Am J Clin Pathol* 1988;89:463-71.
  72. Weiss SW, Enzinger FM. Epithelioid hemangioendothelioma: a vascular tumor often mistaken for a carcinoma. *Cancer* 1982;50:970-81.
  73. Mark RJ, Poen JC, Tran LM, et al. Angiosarcoma. A report of 67 patients and a review of the literature. *Cancer* 1996;77:2400-6.
  74. De Yao JT, Sun D, Powell AT, et al. Scalp Angiosarcoma Remission with Bevacizumab and Radiotherapy without Surgery: A Case Report and Review of the Literature. *Sarcoma* 2011;2011:160369.
  75. Allison KH, Yoder BJ, Bronner MP, et al. Angiosarcoma involving the gastrointestinal tract: a series of primary and metastatic cases. *Am J Surg Pathol* 2004;28:298-307.
  76. Hinterseher I, Pistorius S, Zietz C, et al. Epithelioid hemangiosarcoma of the rectum. *Int J Colorectal Dis* 2005;20:385-7.
  77. Morgan CN. Endothelioma of the Rectum. *Proc R Soc Med* 1932;25:1020-1.
  78. Norbury LE. Specimen of Endothelioma of Rectum. *Proc R Soc Med* 1932;25:1021-2.
  79. Gentry RW, Dockerty MB, Glagett OT. Vascular malformations and vascular tumors of the gastrointestinal tract. *Surg Gynecol Obstet* 1949;88:281-323.
  80. Brown CJ, Falck VG, MacLean A. Angiosarcoma of the colon and rectum: report of a case and review of the literature. *Dis Colon Rectum* 2004;47:2202-7.
  81. Patel KU, Szabo SS, Hernandez VS, et al. Dermatofibrosarcoma protuberans COL1A1-PDGFB fusion is identified in virtually all dermatofibrosarcoma protuberans cases when investigated by newly developed multiplex reverse transcription polymerase chain reaction and fluorescence in situ hybridization assays. *Hum Pathol* 2008;39:184-93.
  82. McArthur G. Molecularly targeted treatment for dermatofibrosarcoma protuberans. *Semin Oncol* 2004;31:30-6.
  83. Criscione VD, Weinstock MA. Descriptive epidemiology of dermatofibrosarcoma protuberans in the United States, 1973 to 2002. *J Am Acad Dermatol* 2007;56:968-73.
  84. Bowne WB, Antonescu CR, Leung DH, et al. Dermatofibrosarcoma protuberans: A clinicopathologic analysis of patients treated and followed at a single institution. *Cancer* 2000;88:2711-20.
  85. Lindner NJ, Scarborough MT, Powell GJ, et al. Revision surgery in dermatofibrosarcoma protuberans of the trunk and extremities. *Eur J Surg Oncol* 1999;25:392-7.
  86. Haycox CL, Odland PB, Olbricht SM, et al. Immunohistochemical characterization of dermatofibrosarcoma protuberans with practical applications for diagnosis and treatment. *J Am Acad Dermatol* 1997;37:438-44.
  87. Farma JM, Ammori JB, Zager JS, et al. Dermatofibrosarcoma protuberans: how wide should we resect? *Ann Surg Oncol* 2010;17:2112-8.
  88. Voth H, Landsberg J, Hinz T, et al. Management of dermatofibrosarcoma protuberans with fibrosarcomatous transformation: an evidence-based review of the literature. *J Eur Acad Dermatol Venereol* 2011;25:1385-91.
  89. Meguerditchian AN, Wang J, Lema B, et al. Wide excision or Mohs micrographic surgery for the treatment of primary dermatofibrosarcoma protuberans. *Am J Clin Oncol* 2010;33:300-3.
  90. Rutkowski P, Van Glabbeke M, Rankin CJ, et al. Imatinib mesylate in advanced dermatofibrosarcoma protuberans: pooled analysis of two phase II clinical trials. *J Clin Oncol* 2010;28:1772-9.
  91. Kérob D, Porcher R, Verola O, et al. Imatinib mesylate as a preoperative therapy in dermatofibrosarcoma: results of a multicenter phase II study on 25 patients. *Clin Cancer Res* 2010;16:3288-95.
  92. Buche S, Delasalle EM, Coindre JM, et al. Atypical presentation of giant cell fibroblastoma. *Ann Dermatol Venereol* 2010;137:381-5.
  93. Mc Cormack O, Heaslip IS, Abdulrahim M, et al. Perianal dermatofibrosarcoma protuberans: a case report. *Cutis* 2011;87:85-8.
  94. Ozzello L, Stout AP, Murray MR. Cultural characteristics of malignant histiocytomas and fibrous xanthomas. *Cancer* 1963;16:331-44.
  95. O'Brien JE, Stout AP. Malignant Fibrous Xanthomas. *Cancer* 1964;17:1445-55.
  96. Fletcher CD. Pleomorphic malignant fibrous histiocytoma: fact or fiction? A critical reappraisal based on 159 tumors diagnosed as pleomorphic sarcoma. *Am J Surg Pathol* 1992;16:213-28.
  97. Fletcher CD. Malignant fibrous histiocytoma?

- Histopathology 1987;11:433-7.
98. Al-Agha OM, Igbokwe AA. Malignant fibrous histiocytoma: between the past and the present. *Arch Pathol Lab Med* 2008;132:1030-5.
  99. Nahal A. Malignant Fibrous Histiocytoma: From Popularity to Obsolescence. *Can J Pathol* 2010;2:30-8.
  100. Verma P, Chandra U, Bhatia PS. Malignant histiocytoma of the rectum: report of a case. *Dis Colon Rectum* 1979;22:179-82.
  101. Levinson MM, Tsang D. Multicentric malignant fibrous histiocytomas of the colon. Report of a case and review of the subject. *Dis Colon Rectum* 1982;25:327-31.
  102. Spagnoli LG, Dell'Isola C, Sportelli G, et al. Primary malignant fibrous histiocytoma of storiform-pleomorphic type: a case report of an ano-rectal localization. *Tumori* 1984;70:567-70.
  103. Flood HD, Salman AA. Malignant fibrous histiocytoma of the anal canal. Report of a case and review of the literature. *Dis Colon Rectum* 1989;32:256-9.
  104. Singh DR, Aryya NC, Sahi UP, et al. Malignant fibrous histiocytoma of the rectum. *Eur J Surg Oncol* 1999;25:447-8.
  105. Kim BG, Chang IT, Park JS, et al. Transanal excision of a malignant fibrous histiocytoma of anal canal: a case report and literature review. *World J Gastroenterol* 2008;14:1459-62.
  106. Nakayama Y, Minagawa N, Torigoe T, et al. Malignant fibrous histiocytoma originating from the mesorectum: a case report. *World J Surg Oncol* 2011;9:15.
  107. Azizi R, Mahjoubi B, Shayanfar N, et al. Malignant fibrous histiocytoma of rectum: Report of a case. *Int J Surg Case Rep* 2011;2:111-3.
  108. Klemperer P, Coleman BR. Primary neoplasms of the pleura. A report of five cases. *Am J Ind Med* 1992;22:1-31.
  109. Hasegawa T, Hirose T, Seki K, et al. Solitary fibrous tumor of the soft tissue. An immunohistochemical and ultrastructural study. *Am J Clin Pathol* 1996;106:325-31.
  110. Bainbridge TC, Singh RR, Mentzel T, et al. Solitary fibrous tumor of urinary bladder: report of two cases. *Hum Pathol* 1997;28:1204-6.
  111. Kelly PM, Baxter GM. Solitary fibrous tumour of the prostate. *Br J Radiol* 1998;71:1086-8.
  112. Kim KA, Gonzalez I, McComb JG, et al. Unusual presentations of cerebral solitary fibrous tumors: report of four cases. *Neurosurgery* 2004;54:1004-9; discussion 9.
  113. Ng HK, Choi PC, Wong CW, et al. Metastatic solitary fibrous tumor of the meninges. Case report. *J Neurosurg* 2000;93:490-3.
  114. Vallat-Decouvelaere AV, Dry SM, Fletcher CD. Atypical and malignant solitary fibrous tumors in extrathoracic locations: evidence of their comparability to intra-thoracic tumors. *Am J Surg Pathol* 1998;22:1501-11.
  115. Robinson LA. Solitary fibrous tumor of the pleura. *Cancer Control* 2006;13:264-9.
  116. Yousem SA, Flynn SD. Intrapulmonary localized fibrous tumor. Intraparenchymal so-called localized fibrous mesothelioma. *Am J Clin Pathol* 1988;89:365-9.
  117. England DM, Hochholzer L, McCarthy MJ. Localized benign and malignant fibrous tumors of the pleura. A clinicopathologic review of 223 cases. *Am J Surg Pathol* 1989;13:640-58.
  118. Gold JS, Antonescu CR, Hajdu C, et al. Clinicopathologic correlates of solitary fibrous tumors. *Cancer* 2002;94:1057-68.
  119. Moran CA, Suster S, Koss MN. The spectrum of histologic growth patterns in benign and malignant fibrous tumors of the pleura. *Semin Diagn Pathol* 1992;9:169-80.
  120. Witkin GB, Rosai J. Solitary fibrous tumor of the mediastinum. A report of 14 cases. *Am J Surg Pathol* 1989;13:547-57.
  121. Hasegawa T, Matsuno Y, Shimoda T, et al. Frequent expression of bcl-2 protein in solitary fibrous tumors. *Jpn J Clin Oncol* 1998;28:86-91.
  122. Renshaw AA, Pinkus GS, Corson JM. Cd34 and Ael/Ae3-Diagnostic Discriminants in the Distinction of Solitary Fibrous Tumor of the Pleura from Sarcomatoid Mesothelioma. *Appl Immunohistochem* 1994;2:94-102.
  123. de Perrot M, Fischer S, Brundler MA, et al. Solitary fibrous tumors of the pleura. *Ann Thorac Surg* 2002;74:285-93.
  124. Hasegawa T, Matsuno Y, Shimoda T, et al. Extrathoracic solitary fibrous tumors: their histological variability and potentially aggressive behavior. *Hum Pathol* 1999;30:1464-73.
  125. Dudkiewicz M, Deschenes JL, Bloom C, et al. Solitary fibrous tumor of the ischioanal fossa: report of a case and review of the literature. *Dis Colon Rectum* 2004;47:535-7.
  126. Joe BN, Bolaris M, Horvai A, et al. Solitary fibrous tumor of the male pelvis: findings at CT with histopathologic correlation. *Clin Imaging* 2008;32:403-6.
  127. Mourra N, Lewin M, Sautet A, et al. Epithelioid solitary fibrous tumor in the ischioanal fossa. *Virchows Arch* 2005;446:674-6.
  128. Yoshida R, Takada H, Iwamoto S, et al. A solitary fibrous tumor in the perianal region with a 13-year follow-up: report of a case. *Surg Today* 1999;29:642-5.
  129. Kindblom LG, Remotti HE, Aldenborg F, et al. Gastrointestinal pacemaker cell tumor (GIPACT): gastrointestinal stromal tumors show phenotypic characteristics of the interstitial cells of Cajal. *Am J Pathol* 1998;152:1259-69.
  130. Sarlomo-Rikala M, Kovatich AJ, Barusevicius A, et al.



- CD117: a sensitive marker for gastrointestinal stromal tumors that is more specific than CD34. *Mod pathol* 1998;11:728-34.
131. Miettinen M, Lasota J. Gastrointestinal stromal tumors - Definition, clinical, histological, immunohistochemical, and molecular genetic features and differential diagnosis. *Virchows Arch* 2001;438:1-12.
  132. Chen KT, Latorraca R, Fabich D, et al. Malignant schwannoma: a light microscopic and ultrastructural study. *Cancer* 1980;45:1585-93.
  133. Herrera GA, Pinto de Moraes H, Grizzle WE, et al. Malignant small bowel neoplasm of enteric plexus derivation (plexosarcoma). Light and electron microscopic study confirming the origin of the neoplasm. *Dig Dis Sci* 1984;29:275-84.
  134. Weiss SW, Langloss JM, Enzinger FM. Value of S-100 protein in the diagnosis of soft tissue tumors with particular reference to benign and malignant Schwann cell tumors. *Lab Invest* 1983;49:299-308.
  135. Miettinen M, Shekitka KM, Sobin LH. Schwannomas in the colon and rectum: a clinicopathologic and immunohistochemical study of 20 cases. *Am J Surg Pathol* 2001;25:846-55.
  136. Hsu KF, Lin CT, Wu CC, et al. Schwannoma of the rectum: report of a case and review of the literature. *Rev Esp Enferm Dig* 2010;102:289-91.
  137. Abel ME, Nehme Kingsley AE, Abcarian H, et al. Anorectal neurilemmomas. *Dis Colon Rectum* 1985;28:960-1.
  138. Kakizoe S, Kuwahara S, Kakizoe K, et al. Local excision of benign rectal schwannoma using rectal expander-assisted transanal endoscopic microsurgery. *Gastrointest Endosc* 1998;48:90-2.
  139. Murakami N, Tanaka T, Ohmori Y, et al. A case report of rectal schwannoma. *Kurume Med J* 1996;43:101-6.
  140. Maciejewski A, Lange D, Wloch J. Case report of schwannoma of the rectum--clinical and pathological contribution. *Med Sci Monit* 2000;6:779-82.
  141. Bhardwaj K, Bal MS, Kumar P. Rectal schwannoma. *Indian J Gastroenterol* 2002;21:116-7.
  142. Mulchandani MH, Chattopadhyay D, Obafunwa JO, et al. Gastrointestinal autonomic nerve tumours - Report of a case and review of literature. *World J Surg Oncol* 2005;3:46.
  143. Pescatori M, Bruscianno L, Binda GA, et al. A novel approach for perirectal tumours: the perianal intersphincteric excision. *Int J Colorectal Dis* 2005;20:72-5.
  144. Lee SH, Kim TO, Hwang SY, et al. A case of rectal schwannoma presenting with hematochezia. *Korean J Gastroenterol* 2006;48:195-9.
  145. Reinhold WD, Hillemanns A, Seesko H, et al. Malignant schwannoma of the rectum. *Radiologe* 1996;36:663-6.
  146. Catania G, Puleo C, Cardi F, et al. Malignant schwannoma of the rectum: a clinical and pathological contribution. *Chir Ital* 2001;53:873-7.
  147. Panicek DM, Gatsonis C, Rosenthal DI, et al. CT and MR imaging in the local staging of primary malignant musculoskeletal neoplasms: Report of the Radiology Diagnostic Oncology Group. *Radiology* 1997;202:237-46.
  148. Alfonso AE, Hertz RE. Synchronous leiomyosarcoma and adenocarcinoma of the rectum: report of a case and review of the literature. *Dis Colon Rectum* 1975;18:228-32.
  149. Wolf O, Glaser F, Kuntz C, et al. Endorectal ultrasound and leiomyosarcoma of the rectum. *Clin Investig* 1994;72:381-4.
  150. Naka N, Ohsawa M, Tomita Y, et al. Angiosarcoma in Japan. A review of 99 cases. *Cancer* 1995;75:989-96.
  151. Schuetz SM, Rubin BP, Vernon C, et al. Use of positron emission tomography in localized extremity soft tissue sarcoma treated with neoadjuvant chemotherapy. *Cancer* 2005;103:339-48.
  152. Kane JM 3rd. Surveillance strategies for patients following surgical resection of soft tissue sarcomas. *Curr Opin Oncol* 2004;16:328-32.

**Cite this article as:** Nassif MO, Trabulsi NH, Bullard Dunn KM, Nahal A, Meguerditchian AN. Soft tissue tumors of the anorectum: rare, complex and misunderstood. *J Gastrointest Oncol* 2013;4(1):82-94. doi: 10.3978/j.issn.2078-6891.2012.042