

# Sarcoid reaction: a rare occurrence associated to colon adenocarcinoma (case report and literature review)

Cristina Díaz del Arco, M. Jesús Fernández Aceñero

Department of Surgical Pathology, Hospital Clínico San Carlos, Madrid, Spain

Correspondence to: Dr. Cristina Díaz del Arco, C/Profesor Martín Lagos s/n, MD. Department of Surgical Pathology, Hospital Clínico San Carlos, 28040, Madrid, Spain. Email: crisdelarco@gmail.com.

**Abstract:** Granulomatous reactions are related to infectious and non infectious diseases, but more rarely, granulomas may occur in association to malignancies. The presence of sarcoid-like granulomas in lymph nodes draining malignant tumors is an uncommon but well known occurrence. However, their presence in the stroma of malignant tumors is much rarer. We have only found two previous cases reported in the Japanese and English literature. In this study we report a well differentiated adenocarcinoma of the right colon associated to a stromal granulomatous sarcoid-like reaction. Lymph nodes were not involved. The patient had a clinical history of tuberculosis treated 15 years ago, but there was no clinical, histomorphological, immunohistochemical or molecular evidence of disease at the moment of these findings. We have reviewed the literature to find the keys and the diagnostic challenges posed by granulomatous sarcoid-like reaction occurring in lymph nodes draining malignant neoplasms, peritumoral stroma and in other organs far from the primary tumor. The diagnosis of granulomatous sarcoid-like reactions associated to malignancies can be challenging and it can only be made after ruling out specific infectious and non infectious causes of granulomatous inflammation. The mechanisms involved in granuloma formation, their relationship with demographic and histopathological features, their possible association with autoimmune disorders, their cytokine profile and, more importantly, their prognostic significance in each type of tumor are still unclear and require studies with larger number of patients.

**Keywords:** Sarcoid reaction; colon carcinoma; granuloma

Submitted Dec 23, 2015. Accepted for publication Jan 18, 2016.

doi: 10.21037/jgo.2016.03.07

View this article at: <http://dx.doi.org/10.21037/jgo.2016.03.07>

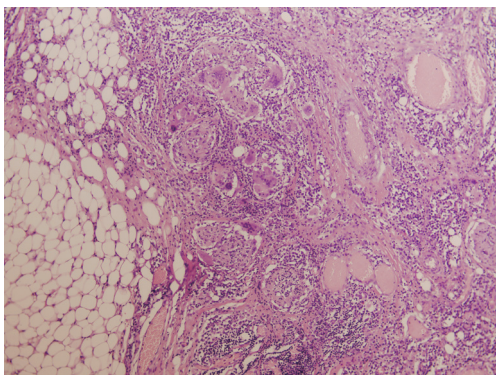
## Introduction

Granulomatous inflammation is a common finding in pathology. It is related to infectious and non infectious diseases, such as mycobacteriosis, Crohn disease and sarcoidosis. It is rare to find granulomas in association to malignant tumors and we must exclude all possible specific etiologies before a diagnosis of “sarcoid-like reaction” or “sarcoid reaction” can be established. The distinction between a tumor-related sarcoid-like reaction and a sarcoidosis can be specially difficult. This reaction can be related to different types of tumors. It occurs with an average frequency of 4.4%, being relatively frequent in Hodgkin disease and non-Hodgkin lymphomas and very rare in sarcomas (1). In most instances, granulomas appear

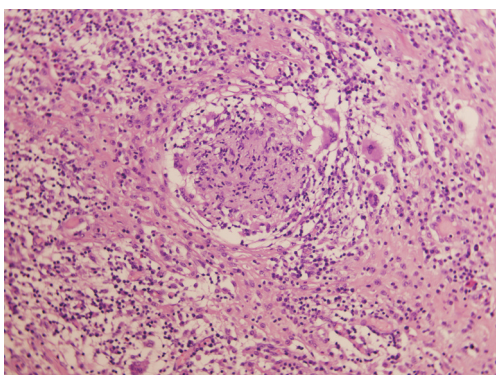
in lymph nodes draining tumors (1-3), but sometimes they occur within the stroma of malignancies like renal, breast and hepatocellular carcinomas, or in other organs (4). We herein report a case of a colonic carcinoma with stromal granulomatous sarcoid-like reaction, from which we have only found two previous cases in a thorough literature review (5,6).

## Case presentation

A 55-year-old man was assessed for abdominal distension, weight loss, hyporexia, and pain in the right iliac fossa. His medical history revealed smoking and drinking habits, a gastric ulcer intervention 30 years ago and an episode



**Figure 1** Low power view of the sarcoid reaction at the periphery of the tumor (H&E  $\times 40$ ).



**Figure 2** High power view of one of the epithelioid granulomas (H&E  $\times 200$ ).

of pulmonary tuberculosis treated for 9 months 15 years before. Computed tomography (CT) revealed a mass in the right colon and he underwent colonoscopy. Colonoscopy revealed an exrescent mass in the cecum and ileocecal valve with partial stenosis of the lumen. Biopsies showed a well differentiated adenocarcinoma. A right hemicolectomy was subsequently performed. Postoperative course was complicated by fever due to a possible dehiscence of the anastomosis with air bubbles near the ileal loop, but the patient evolved well and was finally discharged and is currently being followed in the surgery outpatient clinics.

The surgical specimen consisted of ileum, caecum and right colon measuring 26 cm in length. In the ascending colon there was an exrescent lesion with well defined high borders and a central concavity. It was circumferential and obliterated 90% of the colonic lumen. It measured 7 cm  $\times$  4.5 cm and infiltrated through the wall into the adjacent fat.

Microscopic examination confirms an infiltrating

moderately differentiated colonic carcinoma extending into the subserosal fat. It shows an infiltrative leading edge without budding or desmoplasia and a moderate intratumoral and peritumor lymphocytic response. Metastases were found in 1 of 36 lymph nodes examined. Immunohistochemistry for mismatch repair proteins showed intact nuclear positivity.

There was a granulomatous reaction within the stroma adjacent to the carcinoma, mainly in the deepest areas of the tumor (*Figure 1*). There were non-caseating epithelioid granulomas composed of epithelioid cells and frequent giant cells, as well as lymphocytes. No necrosis or malignant cells were seen within the granulomas (*Figure 2*). Acid-fast staining did not show any microorganisms. We performed a PCR to detect *Mycobacterium tuberculosis*, which was negative too.

## Discussion

The sarcoid-like reaction has been well documented in lymphomas, where the granuloma may be the dominant presentation of the primary disease, even leading to misdiagnosis (7). It has also been described in lymph nodes draining malignant tumors, mainly in cervical and breast carcinomas (2,8). Rarely, it can be found simultaneously within lymph node metastasis. This phenomenon has been described in metastatic lung and nasopharyngeal carcinoma, seminoma and malignant melanoma (9).

The presence of sarcoid-like granulomas in the stroma surrounding carcinomas has been uncommonly reported. It has been mainly described in breast, renal cell and hepatocellular carcinomas, but there are exceptional descriptions in seminomas, nasopharyngeal carcinoma and ovarian dysgerminoma (8,10).

Few cases of colorectal carcinoma associated with a stromal granulomatous sarcoid-like reaction have been reported in the literature. We have only found two cases, one corresponding to a poorly differentiated colonic adenocarcinoma in the ascending colon and the second in the sigmoid colon (5,6).

Sarcoid-like granulomas have also been described to coexist with tumors, but affecting other organs far from the primary neoplasm, such as spleen, bone marrow and skin (11). Therefore, it has been suggested to include tumors in the list of differential diagnosis of granulomatous inflammation of unknown origin (12,13).

As for etiology, the granulomatous reaction may be idiopathic, a foreign body reaction to necrotic material or

a previous procedure, and may be associated to therapy, systemic illnesses or metastasis. However, in most cases the specific cause cannot be found. It is necessary to exclude all possible etiologies using the available methods to be able to link the carcinoma with the sarcoid-like reaction. The distinction between a tumor-related sarcoid like reaction and a true sarcoidosis can be problematic, and in some cases can be an unsolved issue. In those situations, clinical history, clinicopathologic correlation and imaging techniques can be useful (4).

Four main etiopathogenic theories have been considered for sarcoid reaction associated to tumors. First, some authors suggest a possible relation between sarcoid-like granulomas and true sarcoidosis. Hojo *et al.* in their study in 2000 observed more CD4 positive cells in the central area of granuloma and more CD8 positive cells in the external area, the same pattern seen in sarcoidosis (14). Kurata *et al.*, in 2005, studied immunohistochemical markers to lymphocytes, MRP-8 and MRP14, CD143 and mature or immature dendritic cells, concluding that sarcoid-like reactions have a cell distribution similar to sarcoidosis and other granulomatous conditions (11).

The second etiopathogenic possibility is immunological, with the granulomatous response within draining lymph nodes representing a response to soluble tumor related antigens, and the stromal reaction representing a T cell mediated immunological response to cell surface antigens. It can be explained by the production of interferon gamma by local natural killer cells and gammadelta T cells infiltrating the tumor, which further activate the dendritic cells. Antigen-loaded dendritic cells produce interleukin 12 (IL-12) and present the antigen to naive CD4+ T cells, which differentiate into T helper 1 cells, resulting in further maturation of macrophages and granuloma formation. So, this reaction suggests the active involvement of the host immune system against tumors. However, the exact mechanism involved and the precise antigens which play a role in granuloma formation in each type of tumor are not known (15-17).

The third possibility is sarcoid-like granulomas representing a foreign body reaction to persistence of a nondegradable product, that is, necrotic material in the tumor or material secondary to some previous procedure (5). Some treatments may cause granulomatosis, such as BCG therapy for treatment of bladder cancer, interferon alfa and beta for treatment of malignant melanoma, IL-2 for renal cell carcinoma, or methotrexate (18).

The last possible mechanism is a simple tissue reaction to a tumor embolism in the lymphatic system or capillaries, or by the mere presence of tumor cells (6).

Some authors are analyzing the potential role of cytokines in the formation of sarcoid-like granulomas. The malignant tumors microenvironment is rich in cytokines, and this prevents the body from inducing anti-tumor immune responses. The existence of tumor-induced granulomas indicates that the mononuclear macrophage system has certain abilities to recognize and kill tumor cells. Mustafa *et al.* in 2006 studied mycobacterial lymphadenitis, revealing increased expression of IL-10 and TGF-beta and decreased expression of TNF-alfa and IFN-gamma. However, tumor-induced granulomas haven't been analyzed. It would be interesting to study the cytokine profile of tumor-induced granulomas and compare it to the profile of "benign" granulomas (19,20).

The differential diagnosis between lymphadenopathy caused by a sarcoid reaction and metastatic lymph nodes is very important clinically. However, only the histopathological examination can distinguish lymphadenopathy caused by a sarcoid reaction from metastatic lymph nodes (4).

Microscopic examination of these sarcoid-like granulomas shows non-necrotizing epithelioid granulomas characterized by a nodular accumulation of epithelioid histiocytes and multinucleated giant cells. Some of these granulomas may have in their central area nests or isolated tumor cells. So, when found in draining lymph nodes, a close scrutiny of such granulomas is necessary to avoid under diagnosis of metastatic disease. It may be difficult to identify the tumor cells, and immunostaining with cytokeratin may be required for recognizing these (15,21).

Another interesting issue in sarcoid-like granulomas related to malignant tumors is their prognostic significance. Tomimaru *et al.* in 2006 studied 22 patients with sarcoid reaction in the regional lymph nodes of lung cancer and found no statistically significant difference in the overall survival. Other studies had the same results. There was no association between the presence of sarcoid-like granulomas and the age of the patients, the histological type of tumor or the histological grade. However, they found that 36% of their patients suffered from immunological complications, four with autoimmune diseases and five with severe multi-drug allergy. They couldn't perform statistical analysis, but these findings let a door open to the evaluation of possible immunological mechanisms common to autoimmune or allergic diseases (13,22).

In other malignancies, such as Hodgkin's disease and gastric cancer, patients with sarcoid reactions in the regional lymph nodes have been reported to have a good prognosis. In fact, this reaction commonly occurs in lymph nodes without metastases. A study with larger number of patients is essential to clarify the connection between sarcoid-like granulomas and prognosis (23,24).

In summary, we report a rare histopathological finding associated to a colon carcinoma. At present it is not possible to guess what the biological meaning of this finding is and whether it can influence outcome of the patients. It would be interesting to gather larger series of cases to settle this matter.

### Acknowledgments

None.

### Footnote

*Conflicts of Interest:* The authors have no conflicts of interest to declare.

*Informed Consent:* Written informed consent was obtained from the patient for publication of this case report and any accompanying images.

### References

1. Brincker H. Sarcoid reactions in malignant tumours. *Cancer Treat Rev* 1986;13:147-56.
2. Gregorie HB Jr, Othersen HB Jr, Moore MP Jr. The significance of sarcoid-like lesions in association with malignant neoplasms. *Am J Surg* 1962;104:577-86.
3. Gorton G, Linell F. Malignant tumours and sarcoid reactions in regional lymph nodes. *Acta radiol* 1957;47:381-92.
4. Pisciole I, Donato S, Morelli L, et al. Renal cell carcinoma with sarcomatoid features and peritumoral sarcoid-like granulomatous reaction: report of a case and review of the literature. *Int J Surg Pathol* 2008;16:345-8.
5. Coyne JD. Colonic carcinoma with granulomatous (sarcoid) reaction. *J Clin Pathol* 2002;55:708-9.
6. Fujii T, Tabe Y, Yajima R, et al. Adenocarcinoma of Ascending Colon Associated with Sarcoid Reaction in Regional Lymph Nodes. *Case Rep Gastroenterol* 2010;4:118-23.
7. Daly PA, O'Briain DS, Robinson I, et al. Hodgkin's disease with a granulomatous pulmonary presentation mimicking sarcoidosis. *Thorax* 1988;43:407-9.
8. Oberman HA. Invasive carcinoma of the breast with granulomatous response. *Am J Clin Pathol* 1987;88:718-21.
9. Coyne JD, Banerjee SS, Menasce LP, et al. Granulomatous lymphadenitis associated with metastatic malignant melanoma. *Histopathology* 1996;28:470-2.
10. Campbell F, Douglas-Jones AG. Sarcoid-like granulomas in primary renal cell carcinoma. *Sarcoidosis* 1993;10:128-31.
11. Kurata A, Terado Y, Schulz A, et al. Inflammatory cells in the formation of tumor-related sarcoid reactions. *Hum Pathol* 2005;36:546-54.
12. Wei H, Hou J, Pan J, et al. A sarcoidosis-like granuloma reaction in the lymph nodes of a patient with lung squamous cancer: from stasis to the invasive phase with FGFR1 gene amplification. *Clin Respir J* 2016;10:530-4.
13. Tomimaru Y, Higashiyama M, Okami J, et al. Surgical results of lung cancer with sarcoid reaction in regional lymph nodes. *Jpn J Clin Oncol* 2007;37:90-5.
14. Hojo H, Suzuki S, Kikuta A, et al. Sarcoid reaction in primary neuroblastoma: case report. *Pediatr Dev Pathol* 2000;3:584-90.
15. Bhatia A, Kumar Y, Anjali S. Granulomatous inflammation in lymph nodes draining cancer: A coincidence or a significant association. *Int J Med Med Sci* 2009;1:13-6.
16. Chen CL, Su IJ, Hsu MM, et al. Granulomatous nasopharyngeal carcinoma: with emphasis on difficulty in diagnosis and favorable outcome. *J Formos Med Assoc* 1991;90:353-6.
17. Sneller MC. Granuloma formation, implications for the pathogenesis of vasculitis. *Cleve Clin J Med* 2002;69 Suppl 2:SII40-3.
18. Marzouk K, Saleh S, Kannass M, et al. Interferon-induced granulomatous lung disease. *Curr Opin Pulm Med* 2004;10:435-40.
19. Ioachim HL, Medeiros LJ, editors. *Ioachim's Lymph Node Pathology*. Fourth Edition. Philadelphia: Lippincott Williams & Wilkins, 1995:252-4.
20. Mustafa T, Mogga SJ, Mfinanga SG, et al. Immunohistochemical analysis of cytokines and apoptosis in tuberculous lymphadenitis. *Immunology* 2006;117:454-62.
21. Syrjanen KJ. Epithelioid cell granulomas in the lymph nodes draining human cancer: ultrastructural findings of a breast cancer case. *Diagn Histopathol* 1981;4:291-4.

22. Kamiyoshihara M, Hirai T, Kawashima O, et al. Sarcoid reactions in primary pulmonary carcinoma: report of seven cases. *Oncol Rep* 1998;5:177-80.
23. O'Connell MJ, Schimpff SC, Kirschner RH, et al. Epithelioid granulomas in Hodgkin disease. A favorable prognostic sign? *JAMA* 1975;233:886-9.
24. Sacks EL, Donaldson SS, Gordon J, et al. Epithelioid granulomas associated with Hodgkin's disease: clinical correlations in 55 previously untreated patients. *Cancer* 1978;41:562-7.

**Cite this article as:** Díaz del Arco C, Fernández Aceñero MJ. Sarcoid reaction: a rare occurrence associated to colon adenocarcinoma (case report and literature review). *J Gastrointest Oncol* 2016;7(4):E72-E76. doi: 10.21037/jgo.2016.03.07