

An unusual foreign body aspiration requiring an unusual retrieval technique

Gabriel Farkas¹, Debra Lederman¹, Tana Pradhan², Kassem Harris³

¹Department of Anesthesiology, ²Department of Gynecology, ³Department of Medicine, Interventional Pulmonology Section, New York Medical College, Westchester Medical Center, Valhalla, NY, USA

Correspondence to: Kassem Harris, MD, FCCP. Westchester Medical Center, 100 Woods Road, Valhalla, NY 10595, USA. Email: Kassemharris@gmail.com.

Abstract: Foreign body aspiration during medical procedures has been reported in the literature. These iatrogenic incidents could be related to instruments malfunction or to accidental occurrences during medical treatment. In this paper, we present a report of a woman coming for a laparoscopic abdominal hysterectomy who developed intraoperative bronchospasm. In an attempt to administer aerosolized albuterol, the resident anesthesia provider fractured the Luer-lock tip of the 60-cc syringe, which he was using to hold the albuterol nebulizer. The plastic tip was dislodged into the endotracheal tube (ETT). On further inspection with a fiberoptic instrument the plastic tip was located loosely adherent to the distal part of the ETT and was held in place by the moisture, which had precipitated in the distal tube. An intraoperative consult with interventional pulmonary medicine was obtained after unsuccessfully attempting to retrieve the foreign body with a grasper. The syringe tip was then removed using a Fogarty balloon catheter that was threaded through the hole of the plastic tip.

Keywords: Foreign body retrieval; bronchoscopy; syringe tip

Submitted Mar 13, 2018. Accepted for publication Mar 16, 2018.

doi: 10.21037/jtd.2018.03.118

View this article at: <http://dx.doi.org/10.21037/jtd.2018.03.118>

Introduction

Foreign body aspiration has long been managed using bronchoscopy tools for safe and quick retrieval from the airways (1). Accidental and iatrogenic aspiration during medical procedures are well described in the literature, more commonly during dental procedures (2). Anecdotal reports about unusual accidental foreign body aspirations have also been reported. Many authors described airway aspiration of parts of commonly used respiratory equipment. Mohnssen *et al.* published two cases of accidental aspiration of a washer from a closed catheter suction and a part of an intubating stylet. The washer was removed bronchoscopically, but the stylet metallic ball part could not be retrieved bronchoscopically due to its very distal location (3). Anesthesia equipment malfunction can also cause accidental foreign body aspiration. In a case by Jain *et al.* a metal rivet was dislodged from the fulcrum of the direct laryngoscope blade and was lodged in the supraglottic

area. Fortunately, it was uneventfully removed using the Magill forceps (4).

In this report, we describe an accidental dislodgement of a syringe tip into the distal endotracheal tube (ETT) during albuterol inhaler delivery. The syringe tip was retrieved using bronchoscopy and a Fogarty balloon catheter with no airway complications.

Case presentation

A 55-year-old morbidly obese woman (165 kg, BMI 64) was scheduled to undergo a laparoscopic abdominal hysterectomy for endometrial cancer. Her past medical history was significant for chronic obstructive pulmonary disease (COPD) and obstructive sleep apnea (OSA) requiring nocturnal bilevel positive airway pressure (BiPAP). The patient had a 30 pack-year smoking history. Her baseline vital signs were normal and her pulse oximetry was 98% on room air. The patient reported poor exercise

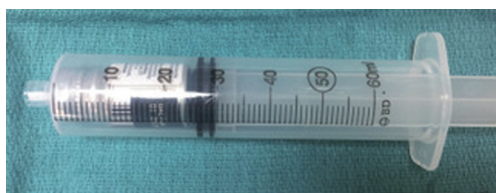


Figure 1 Albuterol administration through the ETT: albuterol MDI inserted into a 60 mL syringe. ETT, endotracheal tube; MDI, metered-dose inhaler.



Figure 2 Plastic tip of the syringe after removal from the ETT. ETT, endotracheal tube.

tolerance. The airway exam revealed a Mallampati class 3 airway. Prior to anesthesia induction, a left radial arterial line was placed in anticipation of a prolonged case and potential significant blood loss. An arterial blood gas obtained on room air prior to induction revealed a pH of 7.43, $p\text{CO}_2$ 39 mmHg, $p\text{O}_2$ 65 mmHg and an O_2 saturation of 96.9%. General anesthesia was induced with propofol and succinylcholine. The intubation was guided by video laryngoscopy using a glide scope and the ETT was secured at 21 cm at the lips. The patient was placed on a volume-controlled ventilator cycle with tidal volume 550 mL, rate 14, PEEP +8 mmHg with a peak airway pressure of 29 mmHg. The end tidal CO_2 was 39 mmHg. Anesthesia was maintained with Sevoflurane, muscle relaxation and fentanyl boluses for analgesia.

About 1 hour into the procedure, the surgeons requested steep Trendelenburg positioning. With repositioning, the peak airway pressure increased to 38 cmH₂O and the

patient's oxygen saturation drifted downward to ~92%. The efforts to "recruit" the atelectatic areas of the lung by hand ventilation and the "sigh" maneuver did not improve the oxygen desaturation. Lung auscultation revealed prolonged expiratory phase and wheezing. To administer a bronchodilator, an albuterol metered-dose inhaler (MDI) cartridge was placed into a 60 mL BD plastic syringe (Figure 1). The apparatus was tested and confirmed that a puff of aerosolized albuterol could be injected from the tip of the 60 mL syringe. The ETT was disconnected from the anesthesia circuit and several puffs of the albuterol were injected into the ETT. The tip of syringe holding the albuterol dispenser was apparently broken when it was forced against the ETT adapter. Closer examination revealed that the plastic tip of the syringe was no longer attached to the body of the syringe and that it had most likely been lost into the ETT. No change in any of the ventilator parameters or vital signs was noted.

The anesthesia team utilized a fiberoptic bronchoscope which identified the small syringe tip resting at the distal end of the ETT. The surgeon was notified, and several attempts were made by the anesthesia team to recover the foreign body. In light of concern that the plastic piece might be pushed distally into a bronchus, an interventional pulmonary medicine consult was obtained. A fiberoptic bronchoscopy was performed but the 1.8 mm jaw flexible forceps could not grasp the foreign body. To prevent dislodging the syringe tip distally into the airways, a 4 French Fogarty balloon catheter was passed through the hollow center of the plastic syringe tip. The balloon of the catheter was then inflated, and the foreign body was removed *en bloc* with the balloon catheter (Figures 2-4). The remainder of the anesthetic was uneventful, and the patient was brought to the intensive care unit (ICU) with the ETT in place due to the prolonged operative time and the 2 liters of blood loss during the procedure.

Discussion

This patient's morbid obesity, COPD and long-term history of smoking increased her risk of bronchospasm from underlying reactive airway disease (6). Increased airway pressures, expiratory wheezing and a rise in end-tidal CO_2 together with a decrease in oxygen saturation strongly suggested bronchospasm as a diagnosis of the deteriorating intraoperative status (7,8).

An albuterol nebulizer is commonly used as a first-line therapy for patients under general anesthesia, however,

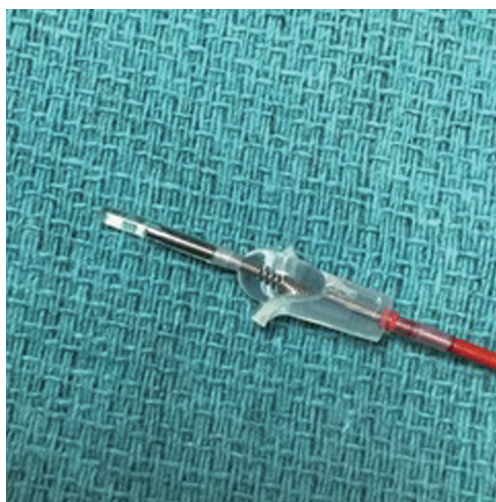


Figure 3 The 4 French Fogarty catheter inserted through the hollow structure of the plastic tip.



Figure 4 A foreign body at the distal tip of the endotracheal tube: this video shows the 4 French Fogarty balloon catheter insertion through the hollow structure of the syringe tip (5). Inflation of the balloon locked the foreign body in and allowed its retrieval.
Available online: <http://www.asvide.com/article/view/25001>

there are no standardized methods for administering aerosolized albuterol through an ETT in the operating room. Multiple methods have been described to administer the inhaled bronchodilators through the ETT (9,10). One method is to use an MDI in the barrel of a 60 mL syringe with the plunger being used to activate the device. Another method suggests attaching a 15 cm length of tubing to the Luer-lock of the syringe to facilitate administering the aerosolized albuterol as distally as possible down the ETT. Many clinicians attach the 60 mL syringe containing

the MDI utilizing the gas sampling port at the elbow connecting the anesthesia circuit to the ETT allowing administration of the albuterol to immediately precede a positive pressure breath.

In our case, the 60 mL syringe containing the albuterol MDI was positioned directly at the opening of the ETT which had been disconnected from the anesthesia circuit. In attempting to administer the albuterol, the downward force on the syringe plunger caused the Luer-lock tip to fracture against the tube connector. After recognizing that the tip of the syringe was missing, we confirmed by fiberoptic bronchoscopy that it was lodged at the distal ETT. Many tools have been used by bronchoscopists to retrieve foreign bodies from the airways (11). In this case, we used a small balloon catheter and we inserted it through the hole of the syringe tip. Inflating the balloon allowed the foreign body to be firmly attached to the balloon catheter and the *en bloc* retrieval of the foreign body with the balloon catheter was possible. This technique highlights the importance of improvising based on a case by case scenario and to use available tools as deemed safe and effective. For aspirated foreign bodies that possess a hollow structure, the balloon catheters use as described in our case should be considered.

Iatrogenic aspiration of medical equipment is possible and whether it is due to tool's malfunction or it is accidental, the anesthesiologists and the proceduralists should be aware of its occurrence. Prompt intervention is crucial to prevent catastrophic airway compromise. Being familiar with the used equipment and tools and checking for any missing parts are the mainstay of early detection to allow effective intervention. Additionally, in patients who develop an airway compromise during medical procedures, the possibility of iatrogenic foreign body aspiration should not be overlooked.

Acknowledgements

None.

Footnote

Conflicts of Interest: The authors have no conflicts of interest to declare.

Informed Consent: Written informed consent was obtained from the patient for publication of this manuscript and any accompanying images.

References

1. Hewlett JC, Rickman OB, Lentz RJ, et al. Foreign body aspiration in adult airways: therapeutic approach. *J Thorac Dis* 2017;9:3398-409.
2. Yadav RK, Yadav HK, Chandra A, et al. Accidental aspiration/ingestion of foreign bodies in dentistry: A clinical and legal perspective. *Natl J Maxillofac Surg* 2015;6:144-51.
3. Mohnssen SR, Greggs D. Iatrogenic aspiration of components of respiratory care equipment. *Chest* 1993;103:964-5.
4. Jain A, Naithani M, Chaudhary Z, et al. Rare iatrogenic airway foreign body: The rivet from the fulcrum of the McCoy laryngoscope blade. *Indian J Anaesth* 2012;56:301-2.
5. Farkas G, Lederman D, Pradhan T, et al. A foreign body at the distal tip of the endotracheal tube: this video shows the 4 French Fogarty balloon catheter insertion through the hollow structure of the syringe tip. *Asvide* 2018;5:526. Available online: <http://www.asvide.com/article/view/25001>
6. Shore SA. Obesity and asthma: implications for treatment. *Curr Opin Pulm Med* 2007;13:56-62.
7. Dewachter P, Mouton-Faivre C, Emala CW, et al. Case scenario: bronchospasm during anesthetic induction. *Anesthesiology* 2011;114:1200-10.
8. Westhorpe RN, Ludbrook GL, Helps SC. Crisis management during anaesthesia: bronchospasm. *Qual Saf Health Care* 2005;14:e7.
9. Dhand R, Tobin MJ. Inhaled bronchodilator therapy in mechanically ventilated patients. *Am J Respir Crit Care Med* 1997;156:3-10.
10. Georgopoulos D, Mouloudi E, Kondili E, et al. Bronchodilator delivery with metered-dose inhaler during mechanical ventilation. *Crit Care* 2000;4:227-34.
11. Blanco Ramos M, Botana-Rial M, Garcia-Fontan E, et al. Update in the extraction of airway foreign bodies in adults. *J Thorac Dis* 2016;8:3452-6.

Cite this article as: Farkas G, Lederman D, Pradhan T, Harris K. An unusual foreign body aspiration requiring an unusual retrieval technique. *J Thorac Dis* 2018;10(5):3098-3101. doi: 10.21037/jtd.2018.03.118