

Acute pulmonary embolism after pneumonectomy

Zongfei Wang, Chu Pei, Lunchao Ma, Daoyuan Wang, Jiangfen Zhou, Wei Wang, Jianfei Shen, Zhiqiang Xu, Jianxing He

Department of Cardiothoracic Surgery, the First Affiliated Hospital of Guangzhou Medical College; Guangzhou Institute of Respiratory Disease, State Key Laboratory of Respiratory Disease, Guangzhou, China

ABSTRACT

Pulmonary embolism (PE) by occlusion of the pulmonary arterial bed may lead to acute life-threatening but potentially reversible right ventricular failure, one of the most severe complications of thoracic surgery. Still, the incidence of acute pulmonary embolism after surgery is reduced by comprehensive anticoagulant prevention, improved surgical techniques, appropriate perioperative management and early ambulation. However, there is difficulty in diagnosing PE after thoracic surgery due to the lack of specific clinical manifestations. So that optimal diagnostic strategy and management according to the clinical presentation and estimated risk of an adverse outcome is fundamental.

KEY WORDS

Acute pulmonary embolism; lung cancer; pneumonectomy

J Thorac Dis 2012;4:76-82. DOI: 10.3978/j.issn.2072-1439.2011.10.02

Acute pulmonary embolism (PE) is one of the most severe complications in thoracic surgery. The occlusion of pulmonary arterial vascular bed may lead to sudden life-threatening danger and the potentially reversible right ventricular (RV) failure. It is very difficult to diagnose PE, and meanwhile the missed diagnosis and misdiagnosis are extremely common due to the lack of specific clinical manifestations (1). The mortality rate reaches up to 30% in un-treated PE patients, where as it may also be as low as 2%-10% in patients with timely diagnosis and treatment (2).

Epidemiology

The data of PE after thoracic surgery are extremely rare, and mostly case reports, which may be associated with its lower occurrence rate after thoracic surgery as compared with that after orthopedic, general and gynecological surgeries (3). Incidence of PE after thoracotomy reported by Collins in 1988

was up to 20% (4), and that by Ziomek in 1993, the most frequently cited in literature, was 5%, and the incidence reported by Dentali *et al.* in 2008 through active prevention was 1.3% (6). Reduced incidence of PE after surgery is suggested along with comprehensive anticoagulant prevention, better surgical techniques, appropriate management in perioperative period and early ambulation, etc. Although video-assisted thoracic surgery (VATS) has been widely carried out, there is no relative literature and report on PE after VATS yet.

Risk factors and natural course

The risk factors of PE includes old age, previous history of venous thromboembolism (VTE), active tumor, nerve diseases accompanied with acromelic paralysis, surgeries, diseases involving prolonged bedridden time, natural or acquired thrombophilia, hormone replacement therapy and oral contraception, etc (1). Sorensen *et al.* (7) reported the high risk of PE in obese people, smokers and patients with systemic hypertension or metabolic syndrome (MS). Furthermore, there were some specific risk factors associated with pulmonary lobectomy. Ziomek *et al.* (5) reported that PE occurrence was higher in malignant tumor than in benign diseases, in primary bronchial cancer than in lung metastatic tumor, in adenocarcinoma than in other types, in lung cancer with diameter>3cm than in relatively smaller lung cancer, in II phase than in I phase and in pneumonectomy or pulmonary lobectomy than in segmentectomy or wedge resection. Kalweit (8) reported that the risk factors of PE after lung surgery included long surgery duration, chemo-treatment before surgery

No potential conflict of interest.

Corresponding to: Jianxing He, MD, PhD, FACS. Department of Cardiothoracic Surgery, the First Affiliated Hospital of Guangzhou Medical College, No. 151, Yanjiang Rd, Guangzhou 510120, Guangdong Province, PR China. Tel: +86-20-83062800; Fax: +86-20-83062800. Email: drjianxing.he@gmail.com.

Submitted Sep 12, 2011. Accepted for publication Oct 05, 2011.

Available at www.jthoracdis.com

ISSN: 2072-1439

© Pioneer Bioscience Publishing Company. All rights reserved.

and little postoperative activity. Nagahiro *et al.* (9) pointed out that the higher PE occurrence in right lateral position (RLP) cases might be associated with iliac compression syndrome and decreased venous velocity of the right femoral vein. Moreover, the right lateral PE is more common due to gravity and increased blood flow in the right pulmonary artery after left pulmonary lobectomy. Improper treatment of pulmonary stumps or anastomosis is also a risk factor for local thrombosis. Kwek *et al.* (10) confirmed that the length of stump is associated with thrombosis. The transfixing suture of pulmonary stumps causes thrombosis easily as compared with continuous suture in an animal experiment by Isik *et al.* (11).

PE and deep vein thrombosis (DVT) are two clinical manifestations of venous thromboembolism (VTE) that involve the same apt factors (1). DVT of upper or lower extremities are found in 90% of PE patients, which suggests that PE is the subsequent result of DVT in most cases (12). PE usually occurs 3 to 7 days after DVT occurrence, 10% patients die within one hour after presence of symptoms, whereas PE can not be identified in most death cases by the current diagnostic approaches. After PE occurrence, complete recoveries of the perfusion defects can be found in about 2/3 patients. Most death cases (>90%) were un-treated patients arising from diagnostic failure of PE, while less than 10% of death cases underwent treatment (1).

Diagnosis

It is much more difficult to diagnose PE after pulmonary lobectomy than spontaneous PE, that's because the clinical signs and symptoms of PE such as chest pain, shortness of breath, tachycardia and decreased blood oxygen saturation can be considered to be correlated with incisional pain, reduced blood volume and pulmonary atelectasis caused by the surgery or covered by the analgesic measures such as an epidural anesthesia (3), hence it is necessary to identify PE with pneumonedema, heart failure, lung infection and bronchospasm after surgery. Sakuragi *et al.* (13) suggested particular attention to the first ambulation since most postoperative patients caught PE on their first walk after operation. PE is highly suspected in patients with symptoms such as sudden or progressively worsened breathing difficulties, chest pain and persistent hypotension (14). Nevertheless, only 20% of patients are confirmed diagnosis through objective workups (15). Although the individual symptoms, signs and the conventional workups lack the sensitivity and specificity, by a definite clinical prediction rule in combination of these variables, more accurately diagnosis of PE is still achievable. The latest guideline suggests that clinical probability should be evaluated before diagnostic workups (16). The Wells Clinical Prediction Rule established by Wells *et al.* (17) is the most commonly used rule (Table 1), which

Table 1. Wells Clinical Prediction Rule.

| Variable | Points |
|---|--------|
| Predisposing factors | |
| Previous DVT or PE | +1.5 |
| Recent surgery or immobilization | +1.5 |
| Cancer | +1 |
| Symptoms | |
| Haemoptysis | +1 |
| Clinical signs | |
| Heart rate > 100 beats/min | +1.5 |
| Clinical signs of DVT | +3 |
| Clinical diagnosis | |
| Alternative diagnosis less likely than PE | +3 |
| Clinical probability (3levels) | Total |
| Low | 0-1 |
| Intermediate | 2-6 |
| High | ≥7 |
| Clinical probability (2levels) | |
| Non-PE | 0-4 |
| PE | >4 |

has been widely validated by three-fold classification (clinical probability of low, intermediate risk and high risk) and two-fold classification (PE possibility).

Since Wells Clinical Prediction Rule is somewhat not that objective, more objective regulations are further established in recent years, such as Geneva, Charlotte and Miniati rules, which contribute to a more effective and simpler diagnosis of PE for clinicians. The diagnosis is established on the clinical symptoms resulting from Haemodynamic stability or Clinical probability assessment instability (14) (Figure 1).

D-dimer is a soluble degradation production generated from cross linked fibrin based on the fibrinolytic system, with negative prediction value higher than positive prediction value (1). Surgery, tumor, pregnancy, hospitalization and advanced age might result in the elevated D-dimer (18). The quantitative enzyme-linked immunoabsorbent assay (ELISA) showed that the thromboembolic risk was 0.14% in patients with a normal D-dimer concentration within 3 months of not taking anticoagulation therapy (19). Therefore, the positive D-dimer is of little significance in diagnosis of PE after pulmonary lobectomy, while the negative D-dimer plays an important role in acute PE exclusion hence no need of further workups for PE diagnosis. Of course, the blood test be useful as first level exam, especially for low/medium probability of clinical testing of patients is of great significance.

Been widely used in clinic, the chest multi slice CT pulmonary angiography (SCTPA) shows direct signs of pulmonary arterial

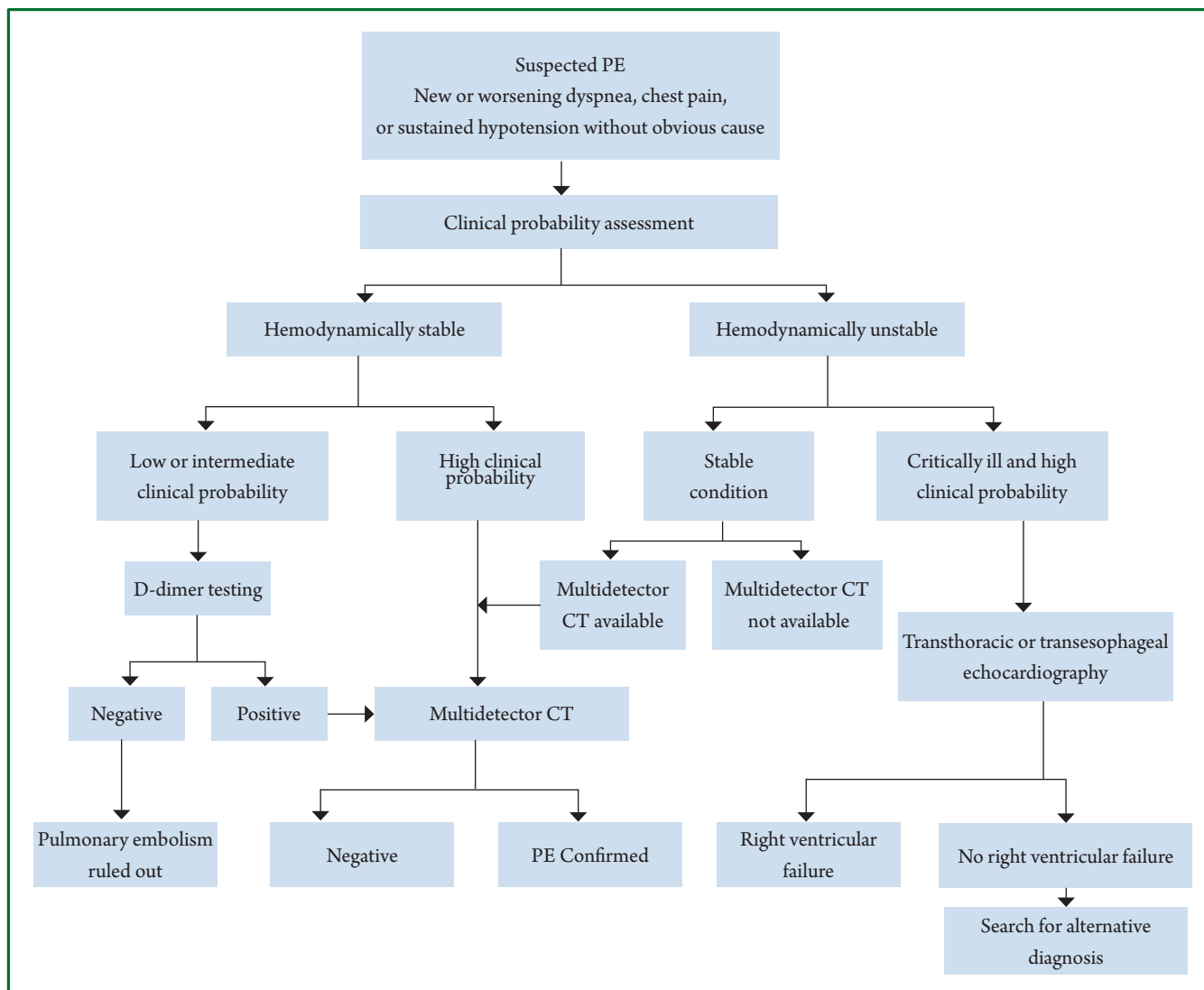


Figure 1. Diagnostic Workup for Pulmonary Embolism.

low-density filling defect, partly or completely surrounded by the opaque blood flow or total filling defect with the distal end of blood vessel being absent. The SCTPA has advantages such as specificity of high spatial/temporal resolution and arterial opaqueness, non-invasiveness, convenience and rapid result acquisition. A large prospective research demonstrated that the sensitivity of SCTPA was 83%, specificity was 95% (20) and sensitivity to the emboli in pulmonary artery was 97% (21). Meanwhile, SCTPA displays abnormalities such as lung infection, pulmonary atelectasis, pneumonema and pleural effusion, and assists making differential diagnosis of PE. So that in clinical practice, SCTPA has been a preferred method for pulmonary angiography in patients with suspicious PE. The combined pulmonary CT angiography and CT venography of lower extremity improves sensitivity and specificity (83%-90%, 95%-97%, respectively) (20), however, it should be avoided due to its little clinical significance and high dose of radiation (22).

Dual-source CT (DSCT), first used in 2006, is fast, accurate and safe in diagnosing PE. DSCT enjoys a higher time resolution, better spatial resolution and less radiation quantity compared with single-source CT (SSCT) (2), and it is still developing along with new technology and improved capacity (23). False negative values by CT in PE patients with high clinical PE probability are reported, however this situation is rare and these patients have small risk of venous thrombosis within 3 months after lobectomy. At present, it is still controversial on whether to perform further examinations and on perform what kind of examination on these patients (1).

Pulmonary ventilation--perfusion scanning remains an effective way for diagnosing patients with contraindications of CT examination such as allergic to contrast agents, with renal failure or pregnancy, in severe conditions or child-bearing age. PE is excluded if pulmonary perfusion defects distributed in lung segments do not match the ventilation imaging, and the normal

Table 2. Risk stratification according to expected pulmonary embolism-related early mortality rate.

| Early mortality relative to PE | Risk markers | | | Potential treatment indications |
|--------------------------------|--|--------------------|------------------------|--------------------------------------|
| | Clinically shock or low blood pressure (b) | RV dysfunction (c) | Myocardial defects (d) | |
| High >15% | + | (+)a | (+)a | Thrombolysis or surgical embolectomy |
| Intermediate 3-15% | — | + | + | Hospitalization |
| Not high | | + | — | |
| Low <1% | — | — | + | Early discharge or at-home therapy |
| | | — | — | |

Notes: a. In the presence of shock or hypotension it is not necessary to confirm RV dysfunction/injury to classify as high risk of PE-related early mortality; b. Defined as a systolic blood pressure, less than 90 mmHg or a pressure drop of more than 40 mmHg for at least 15 min if not caused by new-onset arrhythmia, hypovolaemia or sepsis; c. RV dilatation, hypokinesis or pressure overload on echocardiography; RV dilatation on spiral computed tomography; brain natriuretic peptide (BNP) or N-terminal proBNP (NT-proBNP) elevation; right heart pressure elevation at right heart catheterization; d. Positive cardiac troponin T or I.

negative predictive value of ventilation-perfusion scanning is 97% (24). Nevertheless, the ventilation-perfusion scanning is only applicable in diagnosis of 30%-50% suspicious PE patients. A randomized contrastive study of CT and ventilation-perfusion scanning showed that the occurrence rates of VTE were 0.4% and 1.0% in patients excluded from PE by examinations within 3 months, respectively (25). Meanwhile, many diseases affect both ventilation and blood flow, thus the ventilation-perfusion scanning has to be interpreted according to the clinical status. At present, the ventilation-perfusion scanning is only used in patients with renal failure or allergy to contrast medium and pregnant women.

Echocardiography allows bedside operation and is used in evaluation of right ventricular function, which has 96% of sensitivity and 83% of specificity in diagnosis of PE combining with clinical symptoms and electrocardiogram (ECG). Thrombus in the pulmonary trunk is detected in PE patients with hemodynamic instability by transesophageal ultrasonography (26). Echocardiography is the best option for PE patients at high risk (27), it is mainly used in risk stratification though its significance in diagnosis of non-high risk PE is little, and its negative results may not exclude the possibility of PE.

Since 90% of PE are caused by deep vein thrombosis (DVT) of lower extremities, ultrasonography on the lower extremity has replaced venography in diagnosis of deep venous thrombosis to a great extent. Based on proximal deep venous thrombosis, if the sensitivity is over 90% and the specificity is about 95%, 10% patients would not need for further lung scanning.

Magnetic resonance angiography (MRA) refers to a novel diagnostic technique that can be used in patients with contraindications of iodine contrast agent or ionizing radiation. A prospective Phase III study (29) showed sensitivity and

specificity of being 78% and 99% respectively when excluding technique improper (25%). The sensitivity can be increased to 92% in combination with magnetic resonance venography (MRV), whereas the proportion of improper technique also increases to 52%. Compared with SCTPA, MRA takes a longer time, poorer acceptability for patients, also it fails in excluding other cardiovascular and lung diseases apart from PE, besides it is not available for patients with implanted pacemaker and other equipments. MRA is complex, so MRA is only suggested in patients with contraindications to standard workups in conventional medical centers.

The catheter pulmonary angiography is the gold standard in diagnosing PE, with sensitivity at 98% and specificity at 95%-98%. The direct signs are the pulmonary filling defects or complete obstruction of pulmonary artery branches, according to which, small thrombosis of 1-2 mm in length are visible in segmental pulmonary artery (30). Nevertheless, the catheter pulmonary angiography is usually used before skin embolus resection since it is invasive and expensive, and it might lead to complications such as increased local bleeding associated with thrombolytic therapy (TT) and even death in severe patients.

In sum, the examination approaches should be selected according to the clinical probability, patient status, applicable examination approaches, allergic to iodine contrast agent or not, risk of ionizing radiation and examination costs, etc.

Treatment

Immediate treatment is required in acute PE after pulmonary lobectomy cases. Before treatment, risk stratification is made based on clinical manifestations, myocardial function and injury markers for individualized treatment. PE was classified into high

risk and non-high risk groups by European Society of Cardiology (ESC). Notably, the non-high risk group is subdivided into intermediate risk and low risk groups (1) (Table 2).

Hypoxia and hypocapnia are common in PE patients, among whom most are with moderate hypoxia. Hypoxemia can be corrected usually by oxygen inhalation through nasal catheter but seldom mechanical ventilation. If mechanical ventilation is required, particular attention are paid to avoid the side effects of hemodynamics, especially in those with high risk PE because mechanical ventilation-induced intrathoracic positive-pressure may decrease venous reflux and progress RV failure (RVF). The acute RVF and the RVF-induced low cardiac output are the main cause for death. Trails show that RVF might be worsened by the strong hyperolemic therapy through excessive stretching of ventricular walls and/or reflex constriction suppression (31). Appropriate liquid infusion may increase the low cardiac indexes and cardiac indexes of PE patients with normal blood pressure (32). Thereby, the appropriate supportive treatment and administration of vasoactive drugs are of great importance to PE patients with RVF.

Strong treatments are necessary for high risk patients, including medication and mechanical thrombolysis. Notably, thrombolysis treatment rapidly resolves thrombus embolism and effectively improves the hemodynamic parameters; furthermore, by thrombolysis treatment performed within 48 hours of the presence of symptoms, the greatest benefit is achievable, and it remains beneficial even to patients with symptoms for 6-14 days (33). immediate thrombolysis treatment is recommended for severe PE patients who are definitely indicated with RVF by echocardiography and thus can not undergo CT examination for confirming diagnosis. Thrombolytic drugs such as streptokinase (SK), urokinase (UK) and rtPA significantly increase the risk of bleeding especially when there are bleeding-related relative risk factors or complications. Since non-invasive imaging technique has been successively used in diagnosing PE in the last decade, the life-threatening bleeding is not common now. Therefore, thrombolysis treatment is performed in all high risk PE patients unless there are absolute contraindications. Pulmonary lobectomy within 3 weeks is a contraindication for thrombolysis, however, all contraindications are comparative since high risk PE patients are encountering immediate life-threatening danger. Molina *et al.* (34) reported that a 9.6-day interval between the thrombolysis drugs and surgery was relatively safe. Kameyama *et al.* performed thrombolysis treatment in high risk PE patients undergone ineffective anticoagulant treatments, with thrombosis in lobes or lung segments and hemodynamic instability after pulmonary lobectomy (27). Notably, one case was performed 3.5 hours later after surgery and all patients were successfully discharged after active management. The r-tPA thrombolysis with a very short plasma half-life was suggested in such patients because it decreases bleeding.

For patients with absolute contraindications of thrombolysis and unimproved hemodynamic status by thrombolysis, embolectomy is the optimal treatment. Literatures suggested immediate embolectomy after confirming of central PE (35). At present, the indication of pulmonary arterial embolectomy has spread to patients with RVF but without severe shock, with the early mortality rate reported at 6-8% (36). If pulmonary arterial embolectomy also fails to take effect immediately, intraductal embolectomy or repulping surgery of thrombolysis are considered.

Non-high risk PE patients usually have favorable short-term prognosis. But the mixed data from 6 trials showed no clinical benefits from thrombolysis treatment to this group of patients (37), under this circumstance, anticoagulation therapy should be performed immediately. The rapid anticoagulation is performed only through parenteral anticoagulants such as venous unfractionated heparin (UFH), subcutaneous injection of low-molecular-weight heparin (LMWH) and fondaparinux X a. For patients with high clinical PE probability, anticoagulation therapy is given even before confirming diagnosis (38). Moreover, parenteral anticoagulants usually need to be administered together with the oral vitamin K antagonists (VKAs). A meta analysis showed no significant difference in recurrence rate of VTE, massive hemorrhage and mortality rate between non-high risk PE patients treated with low-molecular-weight heparin and those with unfractionated heparin (39). For PE patients with probability of massive hemorrhage or severe renal failure, UFH is suggested as the initial anticoagulation drug, and the partial thromboplastin time (PTT) needs to be detected. Furthermore, the platelet value also needs to be detected due to the risk of heparin-induced thrombocytopenia. For most acute non-high risk PE patients without severe renal failure, LMWH or fondaparinux is a preferred treatment and it's no need to monitor the dose of subcutaneous injection according to the body weight. No matter UFH, LMWH or fondaparinux, the anticoagulation treatment is supposed for taking at least 5 days. In addition, VKAs are to be used as early as possible and had better combining with anticoagulation treatment. The parenteral anticoagulants are stopped when international normalized ratio (INR) staying at 2.0-3.0 for 2 days. Kilic (40) suggested LMWH for intermediate risk groups so as to avoid complications associated with thrombolytic therapy such as bleeding and secondary pyothorax. Nevertheless, the second urgent thrombolysis is usually required during thrombolytic therapy for intermediate risk patients, though to whom the optimal treatment is still controversial.

A recent systematic review including 11 nonrandomized studies demonstrated that proper outpatient follow-ups allowed effective and safe home treatments in low risk patients. However, it is controversial and the patients should be strictly selected.

There is still no literature definitely on whether thrombolytic

therapy is necessary for patients with PE in the single subsegmental lung on SCTPA. At present, thrombolytic therapy is performed merely according to habits of doctors, clinical suspicion and other examinations. Therefore, it is important to study in these patients, whether the risk of fatal PE is greater than that of anticoagulant complications (12).

Vena cava filter can be placed into PE patients with anticoagulant complications (42), but there hasn't evidence proving that the festbremsen brakes are beneficial to PE patients at present.

Preventions

Kalweit (8) reported that the mortality rate of PE was 92.6% in patients with malignant tumor after pulmonary lobectomy hence active prevention is advised, whereas there are still no established prevention measures in thoracic surgery yet. The postoperative prevention reported in western literatures include early ambulation, intermittent sequential compression for improving blood circulation in lower extremities, drug preventions (such as UFH, LMWH and warfarin), subclavian vein intubation and shortened time of mechanical ventilation, etc. Nevertheless, these measures fail in completely preventing the occurrence of PE. The clinical practice guideline of American College of Chest Physicians (ACCP) (42) suggested the conventional use of LMWH and fondaparinux in prevention of thrombus for patients after thoracic surgery and appropriate use of mechanical prevention such as progressive compression stockings and intermittent inflation for postoperative patients with high risk of hemorrhage. Due to the coagulation differences between the yellow race and the white race, peroperative anticoagulation is seldom applied in Japan, effect of which reported in Japan is not as good as that in western studies (13). Nagahiro *et al.* (9,43) found that the efficacy of anticoagulation equals with that of western studies only when performing intermittent pneumatic compression (IPC) in preventing PE.

Recurrence is potential in acute PE patients, the possibility of which is 2%-10% in patients without VKAs persistent anticoagulation therapy but less than 1% in treated cases (44). A systematic review showed that more than 50% patients still had residual thrombosis 6 months later (45). For PE patients, VKAs treatment is advised successively for 3 months after pulmonary lobectomy, and further VKAs treatment is decided according to the individual conditions.

References

1. Torbicki A, Perrier A, Konstantinides S, Agnelli G, Galiè N, Pruszczyk P, et al. Guidelines on the diagnosis and management of acute pulmonary embolism: the Task Force for the Diagnosis and Management of Acute Pulmonary Embolism of the European Society of Cardiology (ESC). *Eur Heart J* 2008;29:2276-315.
2. Nikolaou K, Thieme S, Sommer W, Johnson T, Reiser MF. Diagnosing pulmonary embolism: new computed tomography applications. *J Thorac Imaging* 2010;25:151-60.
3. Auer RC, Schulman AR, Tuorto S, Gönen M, Gonsalves J, Schwartz L, et al. Use of helical CT is associated with an increased incidence of postoperative pulmonary emboli in cancer patients with no change in the number of fatal pulmonary emboli. *J Am Coll Surg* 2009;208:871-8;discussion 878-80.
4. Collins R, Scrimgeour A, Yusuf S, Peto R. Reduction in fatal pulmonary embolism and venous thrombosis by perioperative administration of subcutaneous heparin. Overview of results of randomized trials in general, orthopedic, and urologic surgery. *N Engl J Med* 1988;318:1162-73.
5. Ziomek S, Read RC, Tobler HG, Harrell JE Jr, Gocio JC, Fink LM, et al. Thromboembolism in patients undergoing thoracotomy. *Ann Thorac Surg* 1993;56:223-6;discussion 227.
6. Dentali F, Malato A, Ageno W, Imperatori A, Cajozzo M, Rotolo N, et al. Incidence of venous thromboembolism in patients undergoing thoracotomy for lung cancer. *J Thorac Cardiovasc Surg* 2008;135:705-6.
7. Sørensen HT, Horvath-Puho E, Pedersen L, Baron JA, Prandoni P. Venous thromboembolism and subsequent hospitalisation due to acute arterial cardiovascular events: a 20-year cohort study. *Lancet* 2007;370:1773-9.
8. Kalweit G, Huwer H, Volkmer I, Petzold T, Gams E. Pulmonary embolism: a frequent cause of acute fatality after lung resection. *Eur J Cardiothorac Surg* 1996;10:242-6;discussion 246-7.
9. Nagahiro I, Watanuki Y, Sato S, Nakashima A. Venous velocity of the right femoral vein decreases in the right lateral decubitus position compared to the supine position: a cause of postoperative pulmonary embolism? *Acta Med Okayama* 2007;61:57-61.
10. Kwek BH, Wittram C. Postpneumonectomy pulmonary artery stump thrombosis: CT features and imaging follow-up. *Radiology* 2005;237:338-41.
11. Işık F, Kara M, Tunçöğür B, Sak SD, Kavukçu S. Significance of ligature technique on the formation of pulmonary artery stump thrombosis in a canine model. *Acta Chir Belg* 2005;105:203-6.
12. Sadigh G, Kelly AM, Cronin P. Challenges, controversies, and hot topics in pulmonary embolism imaging. *AJR Am J Roentgenol* 2011;196:497-515.
13. Sakuragi T, Sakao Y, Furukawa K, Rikitake K, Ohtsubo S, Okazaki Y, et al. Successful management of acute pulmonary embolism after surgery for lung cancer. *Eur J Cardiothorac Surg* 2003;24:580-7.
14. Agnelli G, Becattini C. Acute pulmonary embolism. *N Engl J Med* 2010;363:266-74.
15. Righini M, Le Gal G, Aujesky D, Roy PM, Sanchez O, Verschuren F, et al. Diagnosis of pulmonary embolism by multidetector CT alone or combined with venous ultrasonography of the leg: a randomised non-inferiority trial. *Lancet* 2008;371:1343-52.
16. Stein PD, Sostman HD, Bounameaux H, Buller HR, Chenevert TL, Dalen JE, et al. Challenges in the diagnosis of acute pulmonary embolism. *Am J Med* 2008;121:565-71.
17. Wells PS, Anderson DR, Rodger M, Ginsberg JS, Kearon C, Gent M, et al. Derivation of a simple clinical model to categorize patients probability of pulmonary embolism: increasing the models utility with the SimpliRED

- D-dimer. *Thromb Haemost* 2000;83:416-20.
18. Bruinstroop E, van de Ree MA, Huisman MV. The use of D-dimer in specific clinical conditions: a narrative review. *Eur J Intern Med* 2009;20:441-6.
 19. Carrier M, Righini M, Djurabi RK, Huisman MV, Perrier A, Wells PS, et al. VIDAS D-dimer in combination with clinical pre-test probability to rule out pulmonary embolism. A systematic review of management outcome studies. *Thromb Haemost* 2009;101:886-92.
 20. Stein PD, Fowler SE, Goodman LR, Gottschalk A, Hales CA, Hull RD, et al. Multidetector computed tomography for acute pulmonary embolism. *N Engl J Med* 2006;354:2317-27.
 21. van Belle A, Büller HR, Huisman MV, Huisman PM, Kaasjager K, Kamphuisen PW, et al. Effectiveness of managing suspected pulmonary embolism using an algorithm combining clinical probability, D-dimer testing, and computed tomography. *JAMA* 2006;295:172-9.
 22. Brenner DJ, Hall EJ. Computed tomography--an increasing source of radiation exposure. *N Engl J Med* 2007;357:2277-84.
 23. Parker MS, Hui FK, Camacho MA, Chung JK, Broga DW, Sethi NN. Female breast radiation exposure during CT pulmonary angiography. *AJR Am J Roentgenol* 2005;185:1228-33.
 24. Sostman HD, Stein PD, Gottschalk A, Matta F, Hull R, Goodman L. Acute pulmonary embolism: sensitivity and specificity of ventilation-perfusion scintigraphy in PLOPED II study. *Radiology* 2008;246:941-6.
 25. Anderson DR, Kahn SR, Rodger MA, Kovacs MJ, Morris T, Hirsch A, et al. Computed tomographic pulmonary angiography vs ventilation-perfusion lung scanning in patients with suspected pulmonary embolism: a randomized controlled trial. *JAMA* 2007;298:2743-53.
 26. Pruszczyk P, Torbicki A, Pacho R, Chlebus M, Kuch-Wocia A, Pruszyński B, et al. Noninvasive diagnosis of suspected severe pulmonary embolism: transesophageal echocardiography vs spiral CT. *Chest* 1997;112:722-8.
 27. Kameyama K, Huang CL, Liu D, Okamoto T, Hayashi E, Yamamoto Y, et al. Pulmonary embolism after lung resection: diagnosis and treatment. *Ann Thorac Surg* 2003;76:599-601.
 28. Le Gal G, Righini M, Sanchez O, Roy PM, Baba-Ahmed M, Perrier A, et al. A positive compression ultrasonography of the lower limb veins is highly predictive of pulmonary embolism on computed tomography in suspected patients. *Thromb Haemost* 2006;95:963-6.
 29. Stein PD, Chenevert TL, Fowler SE, Goodman LR, Gottschalk A, Hales CA, et al. Gadolinium-enhanced magnetic resonance angiography for pulmonary embolism: a multicenter prospective study (PLOPED III). *Ann Intern Med* 2010;152:434-43, W142-433.
 30. Wolfe MW, Skibo LK, Goldhaber SZ. Pulmonary embolic disease: diagnosis, pathophysiologic aspects, and treatment with thrombolytic therapy. *Curr Probl Cardiol* 1993;18:587-633.
 31. Ghignone M, Girling L, Prewitt RM. Volume expansion versus norepinephrine in treatment of a low cardiac output complicating an acute increase in right ventricular afterload in dogs. *Anesthesiology* 1984;60:132-5.
 32. Mercat A, Diehl JL, Meyer G, Teboul JL, Sors H. Hemodynamic effects of fluid loading in acute massive pulmonary embolism. *Crit Care Med* 1999;27:540-4.
 33. Daniels LB, Parker JA, Patel SR, Grodstein F, Goldhaber SZ. Relation of duration of symptoms with response to thrombolytic therapy in pulmonary embolism. *Am J Cardiol* 1997;80:184-8.
 34. Molina JE, Hunter DW, Yedlicka JW, Cerra FB. Thrombolytic therapy for postoperative pulmonary embolism. *Am J Surg* 1992;163:375-80; discussion 380-1.
 35. Chen Q, Tang AT, Tsang GM. Acute pulmonary thromboembolism complicating pneumonectomy: successful operative management. *Eur J Cardiothorac Surg* 2001;19:223-5.
 36. Meneveau N, Séronde MF, Blonde MC, Legallery P, Didier-Petit K, Briand F, et al. Management of unsuccessful thrombolysis in acute massive pulmonary embolism. *Chest* 2006;129:1043-50.
 37. Wan S, Quinlan DJ, Agnelli G, Eikelboom JW. Thrombolysis compared with heparin for the initial treatment of pulmonary embolism: a meta-analysis of the randomized controlled trials. *Circulation* 2004;110:744-9.
 38. Smith SB, Geske JB, Maguire JM, Zane NA, Carter RE, Morgenthaler TI. Early anticoagulation is associated with reduced mortality for acute pulmonary embolism. *Chest* 2010;137:1382-90.
 39. Quinlan DJ, McQuillan A, Eikelboom JW. Low-molecular-weight heparin compared with intravenous unfractionated heparin for treatment of pulmonary embolism: a meta-analysis of randomized, controlled trials. *Ann Intern Med* 2004;140:175-83.
 40. Kilic D, Akin S, Findikcioglu A, Bilen A, Aribogan A, Hatipoglu A. Low-molecular-weight heparin for treatment of submassive pulmonary embolism after pneumonectomy. *Gen Thorac Cardiovasc Surg* 2007;55:287-9.
 41. Squizzato A, Galli M, Dentali F, Ageno W. Outpatient treatment and early discharge of symptomatic pulmonary embolism: a systematic review. *Eur Respir J* 2009;33:1148-55.
 42. Kearon C, Kahn SR, Agnelli G, Goldhaber S, Raskob GE, Comerota AJ, et al. Antithrombotic therapy for venous thromboembolic disease: American College of Chest Physicians Evidence-Based Clinical Practice Guidelines (8th Edition). *Chest* 2008;133:454S-545S.
 43. Nagahiro I, Andou A, Aoe M, Sano Y, Date H, Shimizu N. Intermittent pneumatic compression is effective in preventing symptomatic pulmonary embolism after thoracic surgery. *Surg Today* 2004;34:6-10.
 44. Agnelli G, Prandoni P, Becattini C, Silingardi M, Taliani MR, Miccio M, et al. Extended oral anticoagulant therapy after a first episode of pulmonary embolism. *Ann Intern Med* 2003;139:19-25.
 45. Nijkeuter M, Hovens MM, Davidson BL, Huisman MV. Resolution of thromboemboli in patients with acute pulmonary embolism: a systematic review. *Chest* 2006;129:192-7.