



# Tailored airway stent: the new frontiers of the endoscopic treatment of broncho-pleural fistula

Alfonso Fiorelli, Vincenzo Ferrara, Mary Bove, Mario Santini

Thoracic Surgery Unit, Università della Campania Luigi Vanvitelli, Naples, Italy

Correspondence to: Alfonso Fiorelli, MD, PhD. Thoracic Surgery Unit, Università della Campania "Luigi Vanvitelli", Piazza Miraglia, 2, I-80138 Naples, Italy. Email: [alfonso.fiorelli@unicampania.it](mailto:alfonso.fiorelli@unicampania.it).

Provenance: This is an invited article commissioned by the Section Editor Shuangjiang Li (Department of Thoracic Surgery and West China Medical Center, West China Hospital, Sichuan University, Chengdu, China).

Comment on: Han X, Yin M, Li L, *et al.* Customized airway stenting for bronchopleural fistula after pulmonary resection by interventional technique: single-center study of 148 consecutive patients. *Surg Endosc* 2018;32:4116-24.

Submitted Feb 21, 2019. Accepted for publication Mar 26, 2019.

doi: [10.21037/jtd.2019.04.07](https://doi.org/10.21037/jtd.2019.04.07)

View this article at: <http://dx.doi.org/10.21037/jtd.2019.04.07>

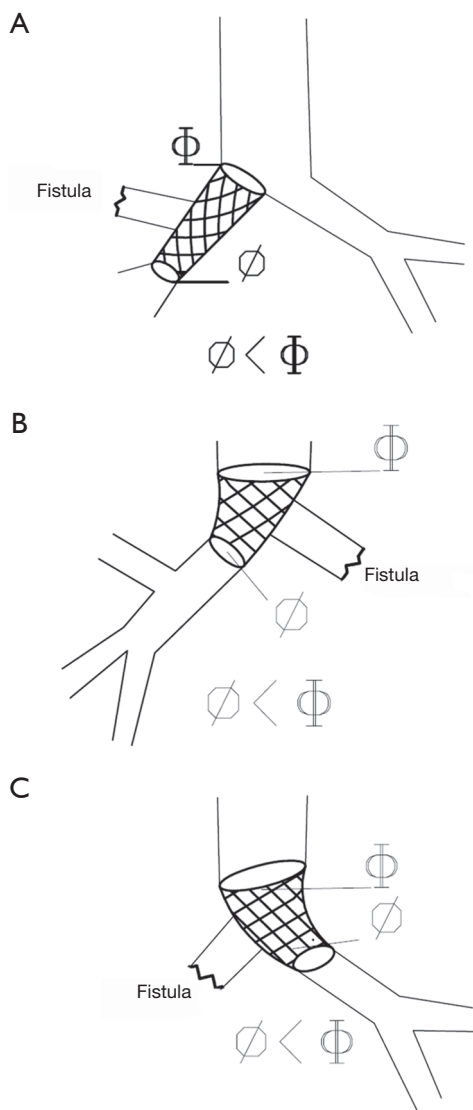
Broncho-pleural fistula (BPF) is the most dreaded and serious complication after lung resection. Despite the advancement in surgical technique, BPF still occurs between 4.5–20% after pneumonectomy, and 0.5–15% after lobectomy (1,2). It is associated with a significant mortality (ranging from 25% to 67%), and treatment remains a challenge especially in presence of concomitant empyema (3).

Emergency chest tube drainage represents the initial treatment to control tension pneumothorax, to avoid aspiration pneumonia (the main cause of early death related to BPF), and to treat empyema, if present. Once the infection of pleural cavity is under control, several techniques ranging from surgery to endoscopy can be carried out to close the fistula. Surgery includes different options as open window thoracostomy, thoracoplasty, and direct closure of the fistula with flaps of different origins (4). However, these are mutilating and disabling procedures that may be not tolerated by already compromised patient. Thus, in the last two decades, many endoscopic techniques using fibrin glues (5-7), coils (8), endobronchial valves (9,10), and airway stents (11) have been proposed as alternative to surgery for closing fistula. However, the best treatment remains still debate as the experiences published in literature are limited to single case report or small case series, and there are no randomized studies comparing the different techniques.

Generally, small fistula  $\leq 3$  mm in size may be successfully treated with fibrin glue alone or in combination with

other substances (5-7) while larger fistula ( $>4$  mm) with a complete bronchial stump dehiscence require more complex procedures as stent insertion (11). Despite the ideal stent does not exist, metallic stent is generally preferable to silicon stent since it better adapts to airway and provides a better seal of the fistula. The shape of the stent is then chosen on the basis of size, site, and fistula edge obtained by radiological and endoscopic findings. Yet, in selected cases who cannot be treated with standard stents due to the difficult anatomy of BPF, customized airway stents (12-14) have been used in order to improve the success rate and decrease the incidence of complications.

In line with this policy, Han *et al.* (15) reported a new customized covered metallic stent, having a bullet head or a special part that served to occlude the fistula. The customized stents were used in a large population (n=148) for management of post-pneumonectomy (n=104) and post-lobectomy BPF (n=44) with a successful closure rate of 96.6% at first attempt. Despite the high success rate, it is notable that 39 (27%) patients died of lung infection and respiratory failure. Furthermore, among the 67 survivors, only 26 (38.8%) had chest tube removal at the time of stent removal. These results suggest that endoscopic closure of the fistula does not necessarily mean eradication of germs especially in post-pneumonectomy space. In the series of Hollaus *et al.* (4), Thirty-six patients with BPF undergoing endoscopic closure with fibrin sealant and decalcified spongy calf bone. Successful closure was obtained in



**Figure 1** The pictures illustrate the use of conical stent insertion in different situations for the management of broncho-pleural fistula. (A) It shows the insertion of conical stent from the main right bronchus to the intermedium bronchus so that the mid point of the stent closes the upper bronchial fistula; (B) it shows the insertion of conical stent from the trachea to the right main bronchus so that the mid-point of the stent closes the left bronchial fistula; (C) it shows the insertion of conical stent from the trachea to the left main bronchus so that the mid-point of the stent closes the right bronchial fistula.

11 cases (30%), but in only 4 cases the fistula closure was associated with the resolution of the concomitant empyema, and these patients left the hospital without drainage.

The remaining 7 patients were discharged with chronic empyema and permanent drainage. However, persistent empyema after fistula closure should not be considered as a failure as it saves from life-threatening aspiration, and allows to perform antibiotic irrigation of pleural cavity through the chest drainage without danger of aspiration. Furthermore, discharge with a chest drainage may be a valid alternative to more invalidation procedures as open window thoracotomy or thoracoplasty, that remain inevitable interventions in case of empyema progression. Thus, in selected cases BPF associated with concomitant empyema needs multimodal treatment including endoscopy and surgery, as recently reported by Andreotti *et al.* (16), in order to eradicate empyema and close the fistula.

From a technical point of view, in our experience the use of standard conical stent (16-18) could be a valid option to customized stent for management of upper lobar bronchus fistula (Figure 1A) and of post-pneumonectomy fistula (Figure 1B,C). The different diameters of proximal and distal end of the conical stent adapt to the different diameters between right main bronchus and intermedium bronchus (in case of right upper lobar fistula) or between trachea and main bronchus (in case of post-pneumonectomy fistula). The main advantage of this stent compared to customized stent is to treat BPF quickly, without waiting for the company to build a custom made stent.

In the future, the availability of 3D printed personalized airway stent could revolutionize the endoscopic treatment of BPF. Recently, our group proposed the use of 3D printed model for planning interventional bronchoscopic procedures (19), but the main limitation for creating a personalized airway stent is the lack of a suitable 3D printable flexible, biocompatible material. Thus, by combining tissue engineering with 3D printing suitable materials, airway stent could be available in the near future so that each physician will be able to create a personalized stent in his own hospital.

### Acknowledgements

None.

### Footnote

*Conflicts of Interest:* The authors have no conflicts of interest to declare.

## References

1. Boudaya MS, Smadhi H, Zribi H, et al. Conservative management of postoperative bronchopleural fistulas. *J Thorac Cardiovasc Surg* 2013;146:575-9.
2. Fiorelli A, Caronia FP, Daddi N, et al. Sublobar resection versus lobectomy for stage I non-small cell lung cancer: an appropriate choice in elderly patients? *Surg Today* 2016;46:1370-82.
3. Ginsberg RJ, Saborio DV. Management of the recalcitrant postpneumectomy bronchopleural fistula: the transsternal transpericardial approach. *Semin Thorac Cardiovasc Surg* 2001;13:20-6.
4. Hollaus PH, Lax F, el-Nashef BB, et al. Natural history of bronchopleural fistula after pneumonectomy: a review of 96 cases. *Ann Thorac Surg* 1997;63:1391-6.
5. Varoli F, Roviario G, Grignani F, et al. Endoscopic treatment of bronchopleural fistulas. *Ann Thorac Surg* 1998;65:807-9.
6. Baumann WR, Ulmer JL, Ambrose PG, et al. Closure of a bronchopleural fistula using decalcified human spongiosa and a fibrin sealant. *Ann Thorac Surg* 1997;64:230-3.
7. Fiorelli A, Frongillo E, Santini M. Bronchopleural fistula closed with cellulose patch and fibrin glue. *Asian Cardiovasc Thorac Ann* 2015;23:880-3.
8. Ponn RB, D'Agostino RS, Stern H, et al. Treatment of peripheral bronchopleural fistulas with endobronchial occlusion coils. *Ann Thorac Surg* 1993;56:1343-7.
9. Gaspard D, Bartter T, Boujaoude Z, et al. Endobronchial valves for bronchopleural fistula: pitfalls and principles. *Ther Adv Respir Dis* 2017;11:3-8.
10. Fiorelli A, D'Andrilli A, Cascone R, et al. Unidirectional endobronchial valves for management of persistent air-leaks: results of a multicenter study. *J Thorac Dis* 2018;10:6158-67.
11. Cao M, Zhu Q, Wang W, et al. Clinical Application of Fully Covered Self-Expandable Metal Stents in the Treatment of Bronchial Fistula. *Thorac Cardiovasc Surg* 2016;64:533-9.
12. Wu G, Li ZM, Han XW, et al. Right bronchopleural fistula treated with a novel, Y-shaped, single-plugged, covered, metallic airway stent. *Acta Radiol* 2013;54:656-60.
13. Bi Y, Li J, Yu Z, et al. Multiple Bifurcated Covered Self-Expanding Metallic Stents for Complex Tracheobronchial Fistulas or Stenosis. *Cardiovasc Intervent Radiol* 2019;42:426-32.
14. Andreetti C, Poggi C, Rendina EA, et al. Temporary Treatment of Complex Subglottic Stenosis by an On-Site Customized Stent. *Semin Thorac Cardiovasc Surg* 2019;31:319-22.
15. Han X, Yin M, Li L, et al. Customized airway stenting for bronchopleural fistula after pulmonary resection by interventional technique: single-center study of 148 consecutive patients. *Surg Endosc* 2018;32:4116-24.
16. Andreetti C, Menna C, D'Andrilli A, et al. Multimodal Treatment for Post-Pneumectomy Bronchopleural Fistula Associated With Empyema. *Ann Thorac Surg* 2018;106:e337-9.
17. Fiorelli A, Caterino U, Raucci A, et al. A conical self-expanding metallic stent for the management of critical complex tracheobronchial malignant stenosis. *Interact Cardiovasc Thorac Surg* 2017;24:293-5.
18. Andreetti C, D'Andrilli A, Ibrahim M, et al. Effective treatment of post-pneumectomy bronchopleural fistula by conical fully covered self-expandable stent. *Interact Cardiovasc Thorac Surg* 2012;14:420-3.
19. Fiorelli A, Scaramuzzi R, Minerva I, et al. Three-dimensional (3D) Printed Model to Plan the Endoscopic Treatment of Upper Airway Stenosis. *J Bronchology Interv Pulmonol* 2018;25:349-54.

**Cite this article as:** Fiorelli A, Ferrara V, Bove M, Santini M. Tailored airway stent: the new frontiers of the endoscopic treatment of broncho-pleural fistula. *J Thorac Dis* 2019;11(Suppl 9):S1339-S1341. doi: 10.21037/jtd.2019.04.07