

Heart-lung transplantation

Charles B. Huddleston, Samuel R. Richey

Department of Cardiothoracic Surgery, Saint Louis University School of Medicine, St. Louis, MO, USA

Correspondence to: Charles B. Huddleston, MD. Glennon Hall, 5th Floor, 1465 South Grand Blvd, St. Louis, MO 63104, USA. Email: chuddle7@slu.edu.

Abstract: Heart-lung transplantation itself is not a particularly difficult operation technically. It is the setting in which this procedure is performed which is difficult. The three issues of importance in a successful outcome are appropriate harvest of the heart-lung bloc from the donor, careful explant of the heart and lungs of the recipient, and finally the implant of the heart-lung bloc into the recipient. None of this requires extraordinary technical skill, but does require careful coordination and planning as well as adhering to some fundamental principles. One of the major pitfalls encountered is bleeding related to the explant procedure. Another is graft failure related to harvest and/or the implant procedure. The third is injury to either the phrenic nerve(s) or the left recurrent laryngeal nerve related to the explant procedure. Heart-lung transplantation is a major investment in resources of all sorts including financial, personnel, as well as the organs themselves. It is absolutely imperative that this procedure be performed only by experienced surgeons in centers with established expertise.

Keywords: Technique; transplantation; heart-lung transplantation

Submitted Mar 28, 2014. Accepted for publication May 15, 2014.

doi: 10.3978/j.issn.2072-1439.2014.05.11

View this article at: <http://dx.doi.org/10.3978/j.issn.2072-1439.2014.05.11>

Introduction

Experimentation in heart-lung transplantation was conducted for more than 25 years prior to the first clinical success (1,2). The initial studies in dogs were marked by failures related to altered respiratory pattern in these animals, most likely a consequence of cardiopulmonary denervation. This was not seen when these experiments were performed in primates (3,4). In the late 1960's and early 1970's three attempts at heart-lung transplantation were made. The longest survival of these three was 23 days. Finally in the early 1980's, the group in Stanford successfully transplanted the heart and lungs into three recipients all of whom had pulmonary vascular disease (5). Two of the three were long term survivors of greater than 5 years. The introduction of cyclosporine as an immunosuppressant was felt to be integral in these successful transplants. These patients actually represent the first long term survivors of any sort of lung transplant as clinical isolated lung transplants did not occur until 4-5 years subsequent to this (6). Initially, the majority of heart-lung transplants were for pulmonary vascular disease and cystic fibrosis,

diseases primarily treated with lung transplantation alone currently. Fewer and fewer heart-lung transplants have been performed since 1990 when the largest number were recorded in the registry maintained by the International Society of Heart and Lung Transplantation. Less than 100 are performed throughout the world today (7). The role of heart-lung transplantation continues to evolve. Technical problems account for approximately one-fifth of all deaths early following heart-lung transplantation, hence the importance of having a firm grasp on the surgical technique of both the harvest and organ implant.

Donor evaluation and harvest

The donor organs individually must meet the same criteria for donation as for isolated heart and lung transplantation. The heart function must be nearly normal on modest inotropic support at most. There should be no significant valvar stenosis or insufficiency. The chest radiograph should be free of significant infiltrates and the arterial pO₂ on oxygen challenge should exceed 350 mmHg. The donor must be free of systemic infection and have no evidence of



Figure 1 Preparation of the heart-lung bloc. The organs are taken from the cold storage and brought up onto the operative field. The lungs and heart should remain in a slush solution as much as possible during this preparation. All the excess pericardial tissue is removed followed by the esophagus and aortic tissue taken with the organs at the time of the harvest. The trachea is identified and transected at a point approximately 1-2 cartilaginous rings above the takeoff of the right upper lobe bronchus. There is always an impressive collection of mucoid secretions present. These are cultured and then suctioned completely to remove as much as possible (8).

malignancy. Size matching is often difficult because of the relative malnourished state of recipients with end-stage heart and lung disease. A larger donor may be problematic fitting the organs into the chest of the recipient unless there is significant hyperexpansion of the lungs creating a larger thoracic cavity. Recipients with fibrotic lung diseases typically have contracted chest cavities; one should be very cautious of a larger donor in these instances. The lungs can be trimmed or a lobectomy performed to allow for a better fit in some cases. Smaller donors obviously will fit easily but potentially can suffer hyperexpansion pulmonary edema when the mismatch is significant. In general, one is safe to accept a donor 10% above and below the weight of the recipient with a similar height range. Beyond this very limited range, one can expand the accepted donor size based upon the recipient characteristics.

The final evaluation of the donor is on-site with flexible bronchoscopy to evaluate the airways for evidence of aspiration or pneumonia as well as looking for other anomalies. A median sternotomy is performed. The donor heart is examined by direct inspection with the chest open. The pleural spaces are opened widely to allow direct visual and tactile examination of the lungs. The trachea is dissected circumferentially between the aorta and the

superior vena cava. Both the superior vena cava and inferior vena cava are dissected out. At the appropriate time, heparin is given intravenously and prostaglandin E1 is administered into the main pulmonary artery. The inferior vena cava is divided and the left atrial appendage is amputated. This allows complete emptying of the heart. The aorta is cross-clamped and both the heart preservative and lung preservative solutions are delivered via cannulae inserted into the ascending aorta and main pulmonary artery respectively. Topical cold saline and slush are applied to the organs. A nominal ventilator rate should be maintained throughout this period of time to enhance the distribution of the pulmoplegia.

The organs are harvested as a heart-lung bloc. The pericardium is divided down to the diaphragm and posteriorly along the diaphragm. The inferior pulmonary ligaments are divided up to the inferior pulmonary veins on each side. The left lung is flipped medially, effectively out of the pleural space allowing access to the posterior mediastinum. The pleura there are divided with a knife and the mediastinal contents are bluntly mobilized including the esophagus and descending aorta. A similar procedure is performed in the right pleural space. The aorta is divided at the level of the innominate artery; a longer segment of aorta can be taken if necessary for any reconstructive purposes in the recipient. The trachea is mobilized further and stapled to occlude it distally at least one centimeter above the carina. The lungs should be mildly inflated at low pressure at the time of application of the stapler. It is then divided proximally while occluded with a clamp of some sort. The esophagus is divided with a GIA type of stapler proximally and distally. The NG tube should have been removed and the endotracheal tube pulled back enough to be excluded from the stapling devices. The descending thoracic aorta is divided. The heart-lung bloc can now be removed from the chest and placed in cold solution, usually the cardioplegia solution, and then placed in cold storage for transport.

Recipient operation

Preparation of the heart-lung bloc

The heart-lung bloc is taken out of cold storage at the appropriate time and all excess mediastinal tissue is removed (*Figure 1*). This includes the mediastinal portion of the esophagus, in addition to the excess aorta and pericardium (*Figure 2A*). The paratracheal tissue of the donor should be left intact to facilitate post-transplant blood supply to the area

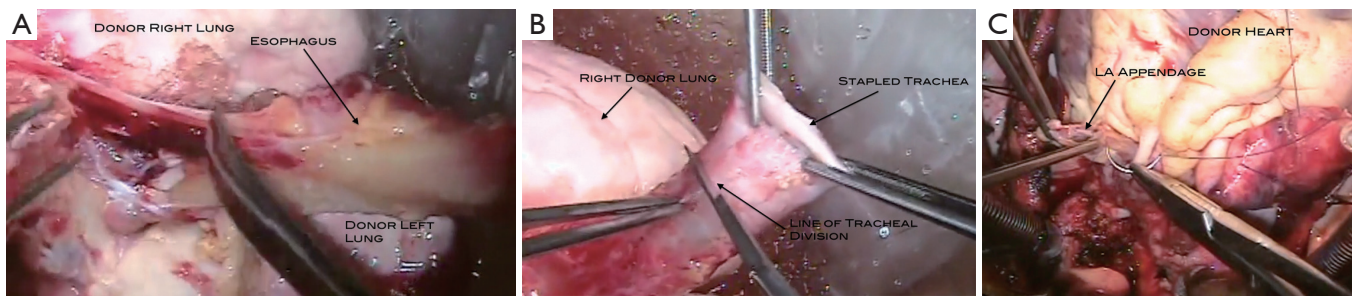


Figure 2 (A) The stapled esophagus is removed by dissecting it away from its mediastinal attachments. The remaining pericardium and aorta have been trimmed away. The trachea is divided above the bifurcation; (B) The trachea is divided above the bifurcation and the staple line is removed; (C) The left atrial appendage which had been amputated is closed with a pursestring to allow the insertion of a catheter for irrigating the left side cardiac structures with cold crystalloid solution.

of the anastomosis. This comes primarily from coronary artery collaterals. The staple line on the trachea is removed leaving one or two cartilaginous rings above the take-off of the right mainstem bronchus for the tracheal anastomosis (*Figure 2B*). A culture of the tracheal secretions is taken and all the retained mucous is suctioned with a separate suction device which will be discarded as soon as the tracheal anastomosis is completed. The amputated left atrial appendage is closed with a pursestring stitch (*Figure 2C*) which is placed on a tourniquet for use during the transplant procedure. This is done while preparing to perform the aortic anastomosis during the transplant procedure. The atrial septum is inspected through the orifice of the inferior vena cava and any defect present should be closed at this point.

Cardiopneumonectomy

In general, a median sternotomy is the optimal approach for heart-lung transplantation. Given the circumstances, one should perform as much of the dissection as possible prior to initiating cardiopulmonary bypass. This is particularly true for patients who have had prior operations. The pleural spaces are opened widely and all adhesions are taken down. Care is taken to preserve the phrenic nerves. The pericardium is opened posterior to the right phrenic nerve as far from the nerve as feasible. The donor lung will be placed posterior to the nerves to get into the respective pleural spaces, so this posterior opening from the pericardium into the pleural space must be along nearly all the length of the phrenic nerves.

The patient is then placed on cardiopulmonary bypass using bi-caval cannulation and cooled to 28 degrees C (*Figure 3*). The caevae are snared and the aorta cross-

clamped. The heart is then excised followed by each lung. One can anticipate significant pulmonary venous return via the extensive aortopulmonary collateral network that commonly accompanies patients with the diseases for which heart-lung transplantation is performed. The aorta is divided just above the aortic valve and the main pulmonary artery just above the pulmonic valve. The right atrium is opened with the incision going onto the roof around the right atrial appendage and down toward the coronary sinus. The incision in the roof of the right atrium is taken across into the left atrium and then follows along the atrio-ventricular groove. The atrial septum is divided down toward the coronary sinus. The heart is then removed from the field. Excess right atrium is removed, leaving sufficient cuffs of tissue for the superior and inferior venae cavae anastomoses.

Bilateral pneumonectomies are then performed (*Figure 4*). Each lung is dissected out of the pleural space leaving only the bronchus attached. The pulmonary artery and vein branches do not have to be ligated, but rather can be divided with the electrocautery. The mainstem bronchus is then stapled and the distal bronchus divided. The lungs are then removed from the thoracic cavity. The excess atrial tissue is removed along with any remnants of the proximal branch pulmonary arteries. A sufficient rim of inferior and superior vena cava is necessary for the respective connections with the donor heart (*Figures 5,6*). It is generally advisable to leave a small island of pulmonary artery at the insertion of the ligamentum arteriosum so that risk of injury to the left recurrent laryngeal nerve is lessened. Both mainstem bronchi are then grasped with Allis clamps to assist with the remaining dissection of the distal airway (*Figure 7*). A stay suture is



Figure 3 Recipient cardiectomy. The operation is performed via a midline sternotomy. After dissection of as much of the heart and lungs as possible off bypass, bicaval/aortic cannulation is performed and the patient is placed on cardiopulmonary bypass. The aorta is cross-clamped. The caval tapes are snared. The right atrium is opened in the midportion of the anterior wall. There is a tremendous amount of pulmonary venous return in this case because of an extensive aortopulmonary collateral network related to the longstanding cyanosis. The aorta is divided. The atrial incision is taken superiorly around the right atrial appendage and across the atrial septum to the roof of the left atrium. The incision inferiorly is taken toward the coronary sinus. There is no pulmonary artery connection in this patient so that is not divided. The remaining atrial wall holding the heart in is divided and the heart removed from the operative field. This leaves behind the atrial mass (left and right atrial tissue) (9).



Figure 4 Left pneumonectomy. Bilateral pneumonectomies are performed. This video demonstrates highlights from the left pneumonectomy. Adhesions along the pleural surface and mediastinum are taken down with the electrocautery. The inferior pulmonary ligament is divided with the electrocautery and this is further used to go through the pulmonary veins and arteries, rather than taking the time to ligate these vessels; the veins are already open into the pericardium and the only flow into the arteries is via aortopulmonary collateral circulation. The bronchus is dissected free. A stapling device is then applied to the bronchus and it is divided distally. The lung should be able to be removed at this point. A similar procedure is performed for the right lung (10).



Figure 5 Preparation of the IVC and SVC. The remaining atrial tissue is removed. This transplant will be performed using caval anastomoses (rather than a right atrial anastomosis), so as the atrial tissue is removed there should be a sufficient cuff left behind to which the donor SVC and IVC will be sewn. The orifices of the pulmonary veins are easily visible. Liberal use of the electrocautery is evident. Once this tissue is removed, the chest is devoid of the heart and lungs, leaving behind an impressive cavity (11).

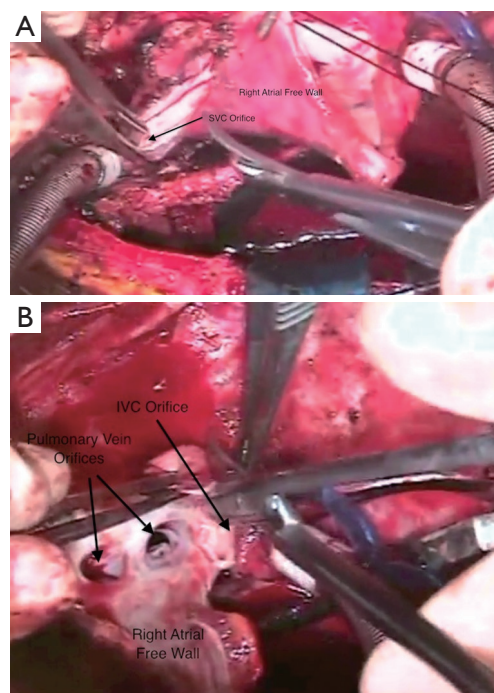


Figure 6 (A) This demonstrates the preparation of the SVC cuff. The excess right atrial tissue is trimmed leaving a sufficient rim for the anastomosis to the donor SVC; (B) Similarly for the IVC a cuff of the right atrium should be left attached to the IVC to allow sufficient tissue and length for the IVC anastomosis to the donor heart. SVC, superior vena cava; IVC, inferior vena cava.



Figure 7 Removal of bronchi and distal trachea. The remaining mainstem bronchi and distal trachea are now excised. The mainstem bronchi are grasped with Allis clamps to assist with the dissection. Placing a stay suture on the more proximal trachea is often helpful for exposure during the tracheal anastomosis. Avoid dissection along the lateral portion of the trachea as much as possible to maintain adequate blood supply to this area. The trachea is divided as distally as possible, remaining cephalad to the mainstem bronchi. Once the anterior wall of the trachea is incised it is obvious from the bleeding that the blood supply is excellent. The remaining portion of the trachea is incised and the distal segment is dissected away from the mediastinum, leaving an open trachea in the mediastinum prepared for the anastomosis (12).

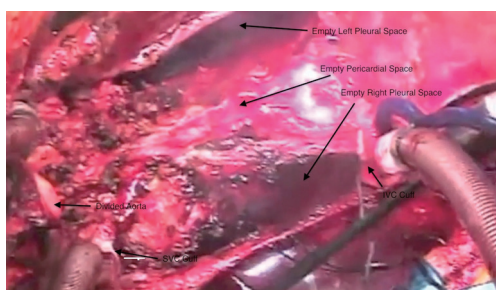


Figure 8 With both lungs and the heart out of the chest the only things remaining are pericardium on both sides to include the phrenic nerves and mediastinal tissue with the lymphatics, esophagus and descending thoracic aorta. Note the large opening posterior to each leaf of pericardium posteriorly to allow the passage of the donor lungs of the heart-lung bloc into the respective thoracic cavities.

placed on the more proximal trachea for traction. The trachea is then divided just above the takeoff of the right mainstem bronchus, which is usually slightly more cephalad than the left. The final step in this portion of the operation is meticulous hemostasis. There are often many mediastinal



Figure 9 Placement of the heart-lung bloc. A pathway has been created posterior to the phrenic nerves on each side. The heart-lung bloc is lowered into the chest passing one lung (the left in this case) into its thoracic space and then the other. Because the lungs remain somewhat inflated, this may require some gentle encouragement to get each lung into its respective position. The heart should be well aligned once this is accomplished (13).

collateral and bronchial vessels which can cause vexing problems with bleeding if not addressed at this point where exposure is optimal. With both lungs and the heart out of the chest, there is an impressive cavity left behind (*Figure 8*).

Transplant procedure

The heart-lung bloc is then lowered into the chest cavity passing the left lung posterior to the phrenic nerve/pericardial pedicle and then the right lung into the left chest posterior to the left phrenic nerve pedicle (*Figure 9*). The order of which lung is passed first is not important. This should place the heart in the midline, lining up the trachea for its anastomotic connection to the recipient trachea. The tracheal anastomosis is done first using a running polypropylene suture (*Figures 10,11*). Some surgeons prefer running the membranous portion and interrupting the cartilaginous portion. When this anastomosis is completed it should be wrapped with whatever viable tissue is in the vicinity, such as pericardium or lymphatic tissue so that the suture line is not up against a vascular structure. This may also provide some additional security against ischemia at the level of the anastomosis. At this point, a catheter is placed into the left atrium via the appendage using the pursestring stitch placed around the amputated left atrial appendage during the preparation of the heart-lung bloc (*Figure 12*). This catheter can be a small vent. It is used to infuse cold crystalloid solution. This keeps the heart cool, but also serves as a way

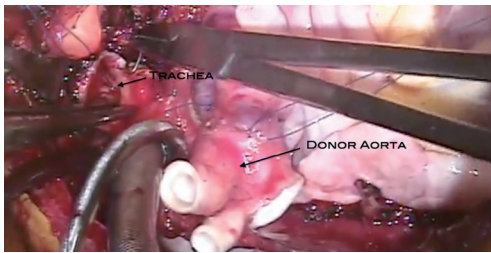


Figure 10 The tracheal anastomosis is the first connection for the heart-lung bloc. This can be done with either a running simple suture technique or using the running technique for the membranous portion and interrupted stitches for the cartilaginous portion of the trachea.



Figure 11 Tracheal anastomosis. This is usually done with a continuous suture of 4-0 polypropylene suture. Other monofilament absorbable suture is certainly reasonable to use as well. Once this is completed, the suture line should be covered with the paratracheal and lymphatic tissue nearby (14).

to evacuate air from the left sided cardiac structures because there is no pulmonary venous return at all during the organ implant of a heart-lung transplant. Next the aortic anastomosis is performed (*Figures 13,14*). As this is being completed the cold saline infusing into the left atrium will be coming out the aorta. The cross clamp is then removed and the saline infusion is stopped. The catheter inserted via the left atrial appendage can now be converted to a vent. The inferior vena cava anastomosis is performed next (*Figures 15,16*). Alternatively, this could be done with the aortic cross clamp still on; this avoids the nuisance of the coronary sinus blood flooding the operative field. However, it does extend the ischemic time somewhat. The superior vena cava anastomosis is then performed (*Figure 17*). Care must be taken to avoid pursestringing this anastomosis.



Figure 12 Placement of the LA catheter. Prior to performing the aortic anastomosis, a catheter is placed via the left atrial appendage into the body of the left atrium. A standard LV vent is appropriate with an attachment that allows for the instillation of cold crystalloid solution during the aortic anastomosis. This is placed at the site of the LS appendage amputation of the appendage performed at the time of the organ harvest. The infusion of cold crystalloid solution via this catheter keeps the heart cold, but also provides a means of air evacuation. There is no pulmonary venous return to the left atrium until there is antegrade flow through the lungs because the bronchial circulation has been divided. The fluid is run through this catheter at a rate that results in a low flow of fluid from the aorta (15).

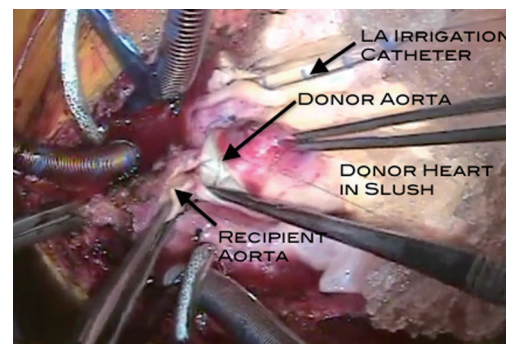


Figure 13 The aortic anastomosis is performed here using a simple running suture technique.

With the completion of all the connections for the new heart-lung bloc, time is taken while on cardiopulmonary bypass to ensure hemostasis. This cannot be emphasized enough. The tissues incised in the process of the recipient cardiectomy and pneumonectomies are all vascular, especially in the setting of cyanotic congenital heart disease or when there have been previous chest



Figure 14 Aortic anastomosis. This is a simple end-to-end connection. As this is being completed the cold crystalloid solution infusing via the LA catheter can be seen coming out of the open portion of the aortic anastomosis. This aids in the de-airing process. Once this is done the aortic cross-clamp can be removed to re-perfuse the heart (16).



Figure 17 SVC anastomosis. Again, this is a simple end-to-end anastomosis. Care should be taken to avoid pursestringing this anastomosis by interrupting the suture line in three or four locations. If there is significant size discrepancy it is probably better to open the smaller vessel longitudinally and sew on a patch to enlarge this (18).

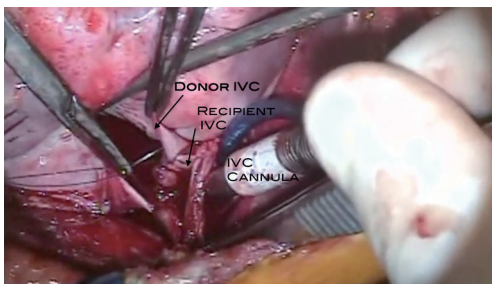


Figure 15 The IVC anastomosis is performed in an end-to-end fashion. IVC, inferior vena cava.



Figure 18 Functioning transplanted heart and lungs. This merely shows the heart and lungs once off cardiopulmonary bypass. The heart is contracting vigorously and the lungs appear appropriately pink (19).



Figure 16 IVC anastomosis. This is generally done with the cross-clamp off the aorta and the heart re-perfused. However, the coronary sinus return to the right atrium often obscures the anastomotic site. This connection is also a simple end-to-end anastomosis (17).

operations. Bronchial arteries as well as arterial supply to lymphatic tissue are all large and may be difficult to control with the electrocautery alone. This is all performed while on cardiopulmonary bypass to allow manipulation of the heart and lungs to visualize those areas that would otherwise be difficult to see. Ventilation is then initiated and the patient is weaned from cardiopulmonary bypass (*Figure 18*).

Special considerations

Patients with congenital heart disease often present

anatomic challenges when isolated heart transplantation is to be performed. Many of these challenges are eliminated by virtue of the complete evacuation of all mediastinal and chest contents to implant the heart-lung bloc. However, there are some situations that are worthy of mention.

Systemic venous anomalies that might be encountered include bilateral superior venae cavae, interrupted inferior vena cava with azygous continuation to the superior vena cava or hemiazygous continuation to the left superior vena cava, isolated hepatic veins entering directly into the right atrium. In general, all of these entities are best handled by maintaining the route of venous return to the right atrium and performing an atrial anastomosis rather than caval anastomoses. The left superior vena cava returns blood to the right atrium via the coronary sinus. When the recipient cardiectomy is performed the coronary sinus is left intact by trimming off the heart above the coronary sinus at the level of the atrioventricular groove. Azygous continuation of an interrupted inferior vena cava results in a very large superior vena cava that will likely have a significant size mismatch with the donor superior vena cava. Depending upon the size discrepancy, the more practical approach to this may be an atrial anastomosis rather than caval anastomoses.

Situs inversus is another entity producing challenges in technical management. Since there is no left atrial anastomosis in heart-lung transplantation, the entire atrial mass can be devoted to the right atrial anastomosis. When the recipient cardiectomy is performed, the atrial septum is removed. A portion of the wall of the anatomic right atrium on the patient's left side is closed, effectively moving the atrial anastomosis to the right, using the recipient anatomic left atrium. The right lung of the donor heart-lung bloc must pass under this atrial mass from left to right to obtain optimal positioning.

Summary

Heart-lung transplant is a procedure performed infrequently even in centers with large heart and lung transplant programs. Those patients often have complex problems that make isolated heart or lung transplant not possible. It is critical that recipients be carefully chosen and that all aspects of the transplant procedure be carefully planned in advance, especially for recipients with congenital cardiac anomalies and have had prior palliative operations. These challenging patients require experienced congenital heart surgeons with expertise in heart-lung transplantation to ensure optimal utilization of these precious organs.

Acknowledgements

Disclosure: The authors declare no conflict of interest.

References

1. Webb WR, Howard HS. Cardio-pulmonary transplantation. *Surg Forum* 1957;8:313-7.
2. Lower RR, Stofer RC, Hurley EJ, et al. Complete homograft replacement of the heart and both lungs. *Surgery* 1961;50:842-5.
3. Nakae S, Webb WR, Theodorides T, et al. Respiratory function following cardiopulmonary denervation in dog, cat, and monkey. *Surg Gynecol Obstet* 1967;125:1285-92.
4. Reitz BA, Burton NA, Jamieson SW, et al. Heart and lung transplantation: autotransplantation and allotransplantation in primates with extended survival. *J Thorac Cardiovasc Surg* 1980;80:360-72.
5. Reitz BA, Wallwork JL, Hunt SA, et al. Heart-lung transplantation: successful therapy for patients with pulmonary vascular disease. *N Engl J Med* 1982;306:557-64.
6. Patterson GA, Cooper JD, Dark JH, et al. Experimental and clinical double lung transplantation. *J Thorac Cardiovasc Surg* 1988;95:70-4.
7. Yusen RD, Christie JD, Edwards LB, et al. The Registry of the International Society for Heart and Lung Transplantation: thirtieth adult lung and heart-lung transplant report--2013; focus theme: age. *J Heart Lung Transplant* 2013;32:965-78.
8. Huddleston CB, Richey SR. Preparation of the heart-lung bloc. *Asvide* 2014;1:248. Available online: <http://www.asvide.com/articles/260>
9. Huddleston CB, Richey SR. Recipient cardiectomy. *Asvide* 2014;1:249. Available online: <http://www.asvide.com/articles/261>
10. Huddleston CB, Richey SR. Left pneumonectomy. *Asvide* 2014;1:250. Available online: <http://www.asvide.com/articles/262>
11. Huddleston CB, Richey SR. Preparation of the IVC and SVC. *Asvide* 2014;1:251. Available online: <http://www.asvide.com/articles/263>
12. Huddleston CB, Richey SR. Removal of bronchi and distal trachea. *Asvide* 2014;1:252. Available online: <http://www.asvide.com/articles/264>
13. Huddleston CB, Richey SR. Placement of the heart-lung bloc. *Asvide* 2014;1:253. Available online: <http://www.asvide.com/articles/265>
14. Huddleston CB, Richey SR. Tracheal anastomosis. *Asvide*

- 2014;1:254. Available online: <http://www.asvide.com/articles/266>
15. Huddleston CB, Richey SR. Placement of the LA catheter. *Asvide* 2014;1:255. Available online: <http://www.asvide.com/articles/267>
 16. Huddleston CB, Richey SR. Aortic anastomosis. *Asvide* 2014;1:256. Available online: <http://www.asvide.com/articles/268>
 17. Huddleston CB, Richey SR. IVC anastomosis. *Asvide*

Cite this article as: Huddleston CB, Richey SR. Heart-lung transplantation. *J Thorac Dis* 2014;6(8):1150-1158. doi: 10.3978/j.issn.2072-1439.2014.05.11

- 2014;1:257. Available online: <http://www.asvide.com/articles/269>
18. Huddleston CB, Richey SR. SVC anastomosis. *Asvide* 2014;1:258. Available online: <http://www.asvide.com/articles/270>
 19. Huddleston CB, Richey SR. Functioning transplanted heart and lungs. *Asvide* 2014;1:259. Available online: <http://www.asvide.com/articles/271>