

Beware of arteria lusoria during lymph node dissection of the right paratracheal fossa for lung cancer surgery

Daniel Pan, Maria Elena Cufari, Eric Lim

Imperial College and Academic Division of Thoracic Surgery, London, UK

Correspondence to: Mr Eric Lim. Academic Division of Thoracic Surgery, Royal Brompton Hospital, Sydney Street, London, SW3 6NP, UK.

Email: e.lim@rbht.nhs.uk.

Abstract: An asymptomatic elderly woman presented with a solitary right upper lobe mass revealed to be non-small cell lung cancer following routine surveillance post mastectomy. Upon review of CT with contrast in preparation for rigid bronchoscopy and right upper lobectomy, we noticed that the patient had a rare case of *arteria lusoria*. This is the presence of an aberrant right subclavian artery extending from the left side of the aortic arch, crossing posteriorly across the midline to supply the upper limb. We suggest that with a documented 100% diagnostic sensitivity on 64 multislice computed tomography, the presence of *arteria lusoria* within the posterior paratracheal fossa may cause life-threatening complications in the unaware during systematic lymph node dissection for non-small cell lung cancer (NSCLC).

Keywords: Arteria lusoria; lobectomy; lymph node

Submitted Sep 12, 2014. Accepted for publication Oct 15, 2014.

doi: 10.3978/j.issn.2072-1439.2014.11.12

View this article at: <http://dx.doi.org/10.3978/j.issn.2072-1439.2014.11.12>

Case report

A 76-year-old woman who was an ex-smoker (13 pack years) presented with a solitary right upper lobe mass shadowing following routine CT surveillance post mastectomy for past breast cancer. Biopsy subsequently confirmed non-small cell lung cancer (NSCLC) with a PET staging of T1N2M0. The patient had exposure to asbestos from her previous work as a glass cutter and has a family history of aggressive metastatic cancer in multiple family members. She reported no bone pain, shortness of breath/chest pain or dysphagia, and physical examination was unremarkable at time of pre-operation.

After multidisciplinary review and patient input, the recommend course of action was right upper lobectomy and systematic nodal dissection.

Upon review of CT with contrast we (M.E.C) noticed that the patient had four branches of the aortic arch with absence of the brachiocephalic trunk (*Figure 1*). The most distal left sided origin artery passed posteriorly to the oesophagus as it crossed the midline of the body to supply the right arm. This is consistent with what is known as

an aberrant right subclavian artery or *arteria lusoria*. The unusual course of the artery was noted pre-operation due to its proximity with the right upper lobe tumour.

We proceeded to rigid bronchoscopy and right upper lobectomy. The aberrant vessel was noted in the right paratracheal fossa (*Figure 2*) and was carefully avoided during lymph node dissection.

Discussion

Aberrant right subclavian artery, clinically known as *arteria lusoria* is the most common embryologic abnormality of the aortic arch (1). It arises as the last branch of the aortic arch or from the proximal descending aorta, on the left side of the thorax. 80-84% crosses upwards and to the right behind the oesophagus, whilst 12.7-15% between the oesophagus and trachea and 4.2-5% in front of the trachea (2). In 60% of patients, the artery's origin arises from an aortic arch diverticulum as first described by Kommerell (3). It is thought that this aberrant origin is caused by involution of the right fourth vascular arch and proximal right dorsal aorta and the persistence of the seventh intersegmental

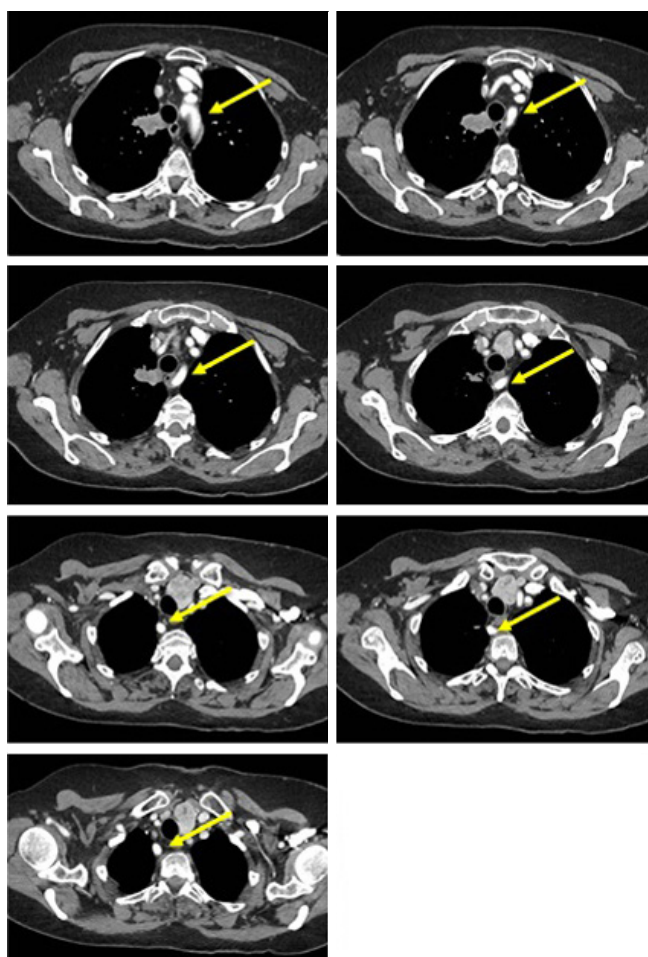


Figure 1 CT of the mediastinal window, showing the course of the right aberrant brachiocephalic artery as it branches off the aorta from the left side, crossing the midline posterior to the oesophagus to supply the right upper limb (yellow arrow).

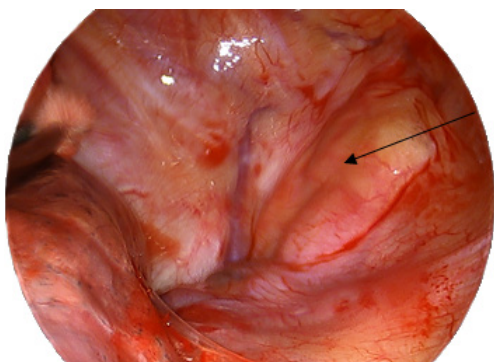


Figure 2 Photo taken during video assisted thoracotomy of the aberrant right subclavian artery (black arrow) is shown in the right paratracheal fossa.

artery originating from the proximal descending aorta (4). *Arteria lusoria* is commonly associated with a right sided nonrecurrent laryngeal nerve, where during embryonic development, the vessel fails to drag the right recurrent laryngeal nerve caudally when the heart descends and the neck elongates (5).

The vast majority of documented cases of *arteria lusoria* are clinically silent, due to the fact that the aberrant artery does not form a complete vascular ring around the oesophagus and trachea and is most often discovered by chance. Associated anomalies include a higher incidence of *truncus bicaroticus* (the presence of a common carotid trunk), aortic coarctation and a replaced right or left vertebral artery. More rarely, an aberrant left subclavian artery may also arise from a right aortic arch. *Arteria lusoria* is also associated with cardiac anomalies in 91% of patients as well as Downs', Edwards' and DiGeorge (6).

There are three possible situations in which the condition can become symptomatic in adults. These all result in compression upon the oesophagus, resulting in *dysphagia lusoria*:

- ❖ The presence of a truncus bicaroticus;
- ❖ Aberrant subclavian aneurysm;
- ❖ Atherosclerotic hardening/fibromuscular dysplasia of arteries with increasing age.

Other symptoms include breathlessness, chronic coughing and dyspnoea from compression of the trachea. This is less likely to occur because of tracheal rigidity compared with the oesophagus. A much rarer but life threatening condition is due to aneurysmal dilatation of the artery, causing right arm ischemia from embolization, oesophageal fistula formation, superior vena cava syndrome and haemorrhagic shock from rupture.

With a documented 100% diagnostic sensitivity on 64 multislice computed tomography and 97.6% on Doppler sonography, clinicians should be aware of *arteria lusoria* as it may have adverse effects on surgery in multiple disciplines (7). The presence of ARSA along with the absence of the right recurrent laryngeal nerve on the lower pole of the thyroid may cause injury to the nerve if it is not found in the aberrant area. Only 60% of transradial coronary procedures are successful in the presence of an *arteria lusoria*. Furthermore the possibility of fistulous connection between the oesophagus and trachea means that an aberrant right subclavian artery is an added potential risk factor for haemorrhage in the presence of prolonged nasogastric, endotracheal intubation or tracheotomy as well

as transhiatal oesophagectomy for cancer (8).

In this case report, we suggest that it is important to consider arteria lusoria as a potential risk factor for operation morbidity during systematic nodal dissection for non-small cell lung cancers. The pulmonary artery vasculature lies inferior to the aortic arch and anterior to the descending aorta, making it one of the closest structures in proximity to a potential ARSA. Uniportal video-assisted thoracoscopic surgery (VATS) for lobectomy is a comparatively new procedure with greater difficulty than a traditional thoracotomy approach, since the surgeon's tactile input is compromised and the procedure relies on a thorough understanding of pulmonary anatomy in order for individual ligation and division of the pulmonary artery, pulmonary vein and bronchus where they enter the lung. Furthermore, the additional requirement of aggressive removal of mediastinal lymph nodes in non-small cell lung cancer means that there may be an increased possibility of unforeseen problems leading to possible conversion to thoracotomy and increase operation morbidity if the surgeon is unaware of this aortic vascular anomaly. The current International Association for the Study of Lung Cancer (IASLC) guidelines recommend undertaking at least three mediastinal stations. The aberrant right subclavian artery lies directly in the posterior bed of the para-tracheal fossa, which could lead to catastrophic injury in the unaware.

Conclusions/learning points

- ❖ *Arteria lusoria*/ARSA is the most common embryologic abnormality of the aortic arch.
- ❖ Although commonly asymptomatic, it can lead to dysphagia (*dysphagia lusoria*), respiratory symptoms as well as more severe symptoms such as right arm ischaemic and haemorrhagic shock from aneurysmal rupture.
- ❖ Diagnostic sensitivity of ARSA is 100% on 64 multislice computed tomography, allowing surgeons to be aware of this condition as it may complicate surgery to the mediastinum.

- ❖ ARSA should be taken into consideration as a possible risk factor for increased complications in VATS lobectomies.

Acknowledgements

Disclosure: The authors declare no conflict of interest.

References

1. Polgaj M, Chrzanowski Ł, Kasprzak JD, et al. The aberrant right subclavian artery (arteria lusoria): the morphological and clinical aspects of one of the most important variations--a systematic study of 141 reports. *ScientificWorldJournal* 2014;2014:292734. Polgaj M, Chrzanowski Ł, Kasprzak JD, et al. The aberrant right subclavian artery (Arteria Lusoria)--the morphological and clinical aspects of the one of the most important variations: a systematic study of 141 reports.
2. Arteria lusoria: Developmental anatomy, clinical, radiological and surgical aspects. *Annales de cardiologie et d'angiologie*: Elsevier, 2010.
3. Kommerell B. Verlagerung des Ösophagus durch eine abnorm verlaufende Arteria subclavia dextra (Arteria lusoria). *Fortschr Geb Roentgenstrahlen* 1936;54:590-5.
4. Kopp R, Wizgall I, Kreuzer E, et al. Surgical and endovascular treatment of symptomatic aberrant right subclavian artery (arteria lusoria). *Vascular* 2007;15:84-91.
5. Schneider J, Baier R, Dinges C, et al. Retroesophageal right subclavian artery (lusoria) as origin of traumatic aortic rupture. *Eur J Cardiothorac Surg* 2007;32:385-7.
6. Singh S, Grewal PD, Symons J, et al. Adult-onset dysphagia lusoria secondary to a dissecting aberrant right subclavian artery associated with type B acute aortic dissection. *Can J Cardiol* 2008;24:63-5.
7. Sun Z, Lin C, Davidson R, et al. Diagnostic value of 64-slice CT angiography in coronary artery disease: a systematic review. *Eur J Radiol* 2008;67:78-84.
8. Pop D, Venissac N, Nadeemy AS, et al. Lesson to be learned: beware of lusoria artery during transhiatal esophagectomy. *Ann Thorac Surg* 2012;94:1010-1.

Cite this article as: Pan D, Cufari ME, Lim E. Beware of arteria lusoria during lymph node dissection of the right paratracheal fossa for lung cancer surgery. *J Thorac Dis* 2014;6(12):E264-E266. doi: 10.3978/j.issn.2072-1439.2014.11.12