

# Endobronchial carcinoid tumor in a Crohn disease patient treated with a TNF $\alpha$ inhibitor

Carolina Carcano<sup>1</sup>, Eduardo C Oliveira<sup>2</sup>, Felipe Martinez<sup>1</sup>, Jacobo Kirsch<sup>1</sup>

<sup>1</sup>Division of Radiology, Cleveland Clinic Florida, FL, USA; <sup>2</sup>Division of Medicine - Chairman, Department: Pulmonary, Allergy and Critical Care Medicine, Cleveland Clinic Florida, FL, USA

Corresponding to: Carolina Carcano, MD. Cleveland Clinic Florida, 2950 Cleveland Clinic Blvd, Weston Fl. 33331, USA. Email: carcanc@ccf.org.

**Abstract:** A young patient with Crohn's disease is presented in whom pulmonary carcinoid tumor was incidentally found. Bronchoscopy showed an endobronchial lesion and biopsy pathology was consistent with atypical carcinoid. Octeotide scan suggested primary origin of the tumor. Although patients with Crohn's disease have been reported to have increased incidence of intestinal carcinoid, we believe this to be the second case of primary carcinoid pulmonary located in this population.

**Key Words:** Crohn's disease, carcinoid tumor



Submitted Nov 13, 2012. Accepted for publication Dec 13, 2012.

doi: 10.3978/j.issn.2218-6751.2012.12.03

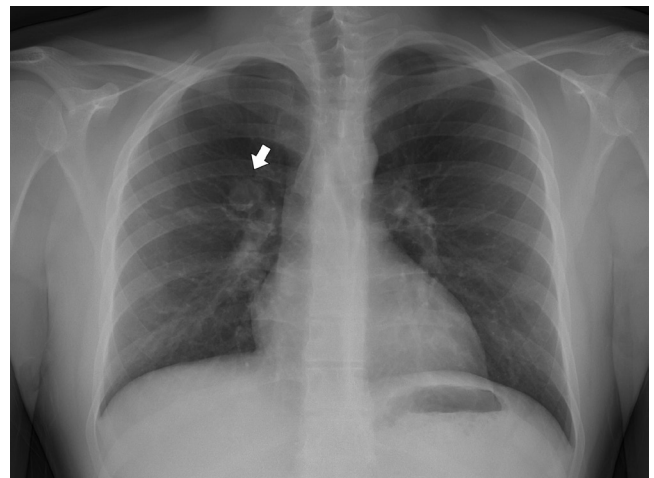
Scan to your mobile device or view this article at: <http://www.tlcr.org/article/view/829/1420>

A 19-year-old male with a history significant for Crohn's disease presented for evaluation of persistent fever after drainage of a perirectal abscess. He had been on treatment with adalimumab for the last year. At admission, a chest radiograph showed a 2.1-cm mass-like opacity in the right hilar region (*Figure 1*). A contrast-enhanced chest CT scan was obtained (Siemens Sensation 64, Siemens Medical Solutions, Forchheim, Germany - 3 mm slices with 2 mm overlap, 100 kV, and 180 mAs) which revealed a well-defined enhancing endobronchial lesion measuring 1.8 cm in the proximal aspect of the bronchus intermedius (*Figure 2A,B*). The endobronchial location was better demonstrated on the coronal reformatted images (*Figure 2C*). Subcentimeter nodular opacities in the posterior lower lobes and in the right upper lobe were also present. Right hilar lymphadenopathy was present as well.

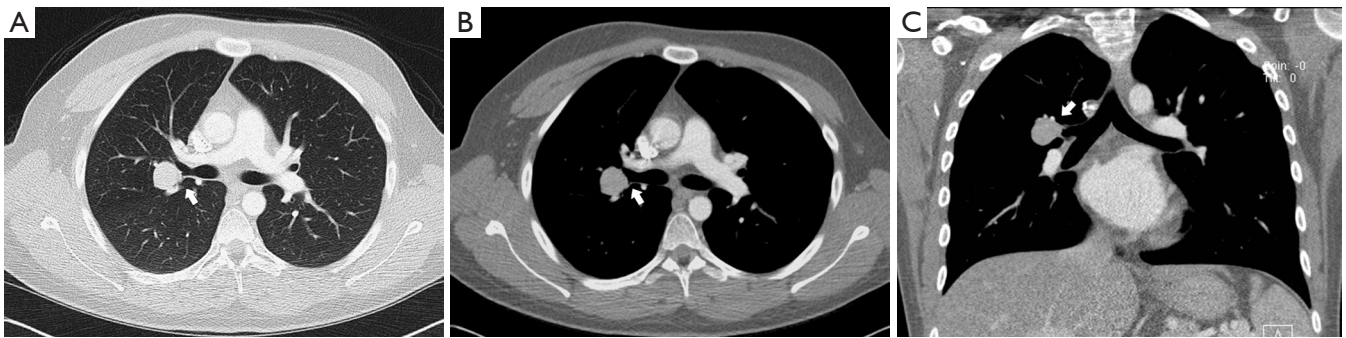These CT findings prompted bronchoscopic evaluation showed an endobronchial lesion (*Figure 3*). Endobronchial ultrasound (EBUS) and EBUS-guided transbronchial needle aspiration was performed (*Figure 4*). Pathology was consistent with a well differentiated atypical carcinoid tumor. Cultures of bronchoalveolar lavage obtained during bronchoscopy revealed *Mycobacterium fortuitum* infection, suggesting that the smaller nodules were infectious in

nature. It is unclear if the smaller nodules observed in the lower lobes and right upper lobe were related to metastatic carcinoid or *Mycobacterium fortuitum* infection but further radiologic studies of the thorax showed reduced size and number of his micronodular disease.

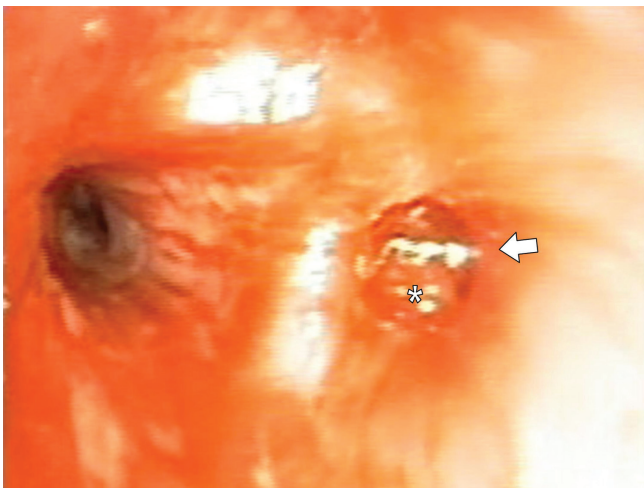
An octreotide whole body scan was performed to



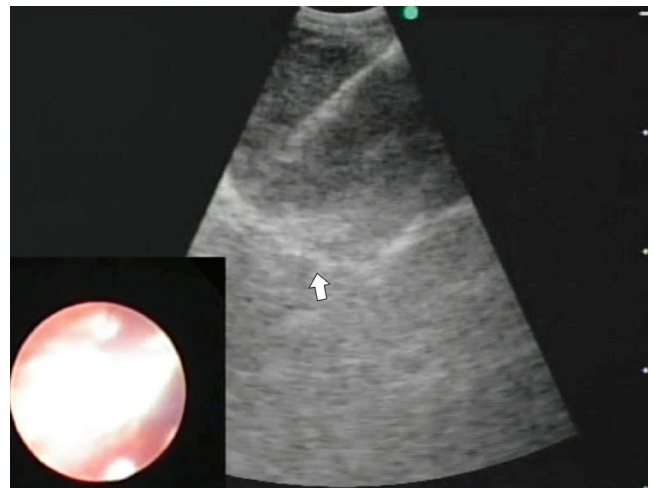
**Figure 1** 19 years old male with lung mass. Posteroanterior shows a well defined opacity of 2.0 cm round suprahilar opacity



**Figure 2** 19 years old male with lung mass. Contrast-enhanced axial CT in lung (A) and soft tissue (B) window settings shows a low-attenuation 2.0 cm mass adjacent to the right superior bronchi. Coronal MPR in soft tissue window settings (C) shows a mass arising from the right lower bronchi (white arrow)



**Figure 3** 19 years old male with lung mass. Endoscopic view reveals a hypervascular bulging mass (asterisk) in the superior segmental bronchus (arrow)



**Figure 4** Endobronchial ultrasound guided transbronchial needle aspiration (EBUS-TNA) reveals a well-defined homogeneous low-echoic mass

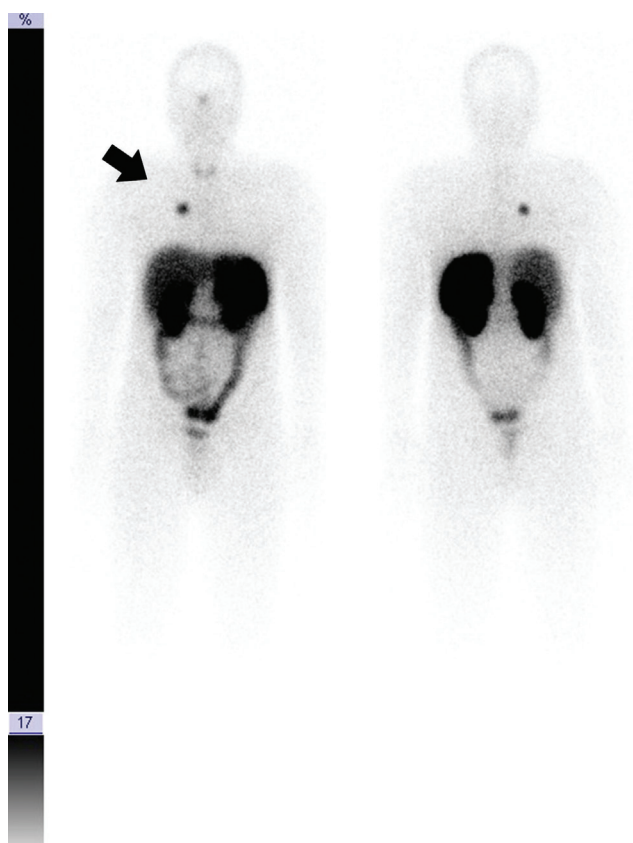
determine if this represented a primary endobronchial process or a metastatic lesion from an abdominal source. There was intense tracer uptake associated with the bronchial tumor without additional foci of definite somatostatin avidity (*Figure 5*). Equivocal faint increased tracer uptake was found on the right lower quadrant of the abdomen interpreted as related to an area of prior bowel resection and re-anastomosis.

## Discussion

The increased risk of development and progression of intestinal carcinomas in patients with Crohn's disease (CD)

has been well defined. Reported meta-analysis showed a 4 to 20- fold increased risk of developing colorectal carcinoma (1,2), and to a lesser extent lymphoma, leukemia, squamous cell carcinoma, and carcinoid tumors (3).

Published case series linking CD to abdominal carcinoid tumors indicates that they are usually found incidentally during surgery. A retrospective study done in 111 patients with CD that underwent bowel resection showed a 15 fold higher incidence of carcinoid tumors in Crohn patients compared to the controls, particularly in locations other than the site of surgery, suggesting that the development of carcinoid tumors could be secondary to distant pro-inflammatory mediators (1). Another case series found a



**Figure 5** In-111 Pentetrotide Whole body SPECT shows intensely avid lesion in the right midlung zone, corresponding with the known pulmonary nodule, without additional foci of definite somatostatin avidity

0.3% incidence of carcinoid tumors in appendectomies of patients with CD (4).

To our knowledge, after extensive literature research, there is a single previous case report of a pulmonary carcinoid tumor in a patient with anti-TNF therapy. That patient was found to have a 2-cm right upper lobe mass after pulmonary nodular opacities were incidentally discovered on an abdominal CT obtained for the assessment of perianal fistulas. Video-assisted thoracoscopic surgery (VATS) was performed revealing the presence of primary pulmonary carcinoid (5).

Carcinoid tumors have somatostatin receptors, therefore radionuclide-coupled octreotide is used for perioperative staging and follow up evaluation of metastatic disease and disease recurrence. Two small series reported high sensibility (up to 90%) and specificity (up to 86%) for the detection of primary and metastatic bronchial tumors in patients with histologically proved carcinoids (5,6). Indium

111-octreotide is the suggested method to rule out a primary abdominal origin of carcinoid tumors (7).

Patients with CD with CT findings of a well defined thoracic mass displayed characteristic prominent enhancement after the administration of intravenous contrast, should rise the suspicion of a carcinoid tumor (7,8). In these cases octreotide scanning technique is the recommended scan for the visualization of tumors with somatostatin receptor, in order to rule out a primary abdominal origin of the tumor (9).

Adalimumab has been proven to be an effective biological agent to induce and maintain clinical remission in patients with moderate-to-severe ulcerative colitis who did not have an adequate response to conventional therapy with steroids or immunosuppressant (10,11). However, a recent meta-analysis on cancer risk with tumor necrosis factor alpha (TNF) inhibitors, found that almost 1% of 15,418 individuals randomized to anti-TNF therapy were diagnosed with cancer, compared to 0.6% of 7,486 individuals randomized to a comparator, representing increased relative risks associated with all anti-TNF for cancers specially for non-melanoma skin cancer (12).

Other studies have also associated anti-TNF agents to augmented incidence of non-Hodgkin's lymphomas, endometrial cancer, and penile intraepithelial neoplasia (5,13,14). This may be related to possible permissive growth of neoplasia when suppressing TNF $\alpha$  (12,15).

This is the second case report of a primary carcinoid tumor of the lung in a patient with Crohn disease; however it is the first case to show a bronchial location, which is indeed the most frequent location for carcinoid tumors. The possibility of distant carcinoid related to proinflammatory mediators has been proposed in the etiology of these tumors, and modest evidence relates them to the use of immunomodulators. Although both cases were diagnosed in patients treated with Adalimumab, the role of immunomodulators in the development of carcinoid tumors remains unclear.

### Acknowledgements

*Disclosure:* The authors declare no conflict of interest.

### References

1. West NE, Wise PE, Herline AJ, et al. Carcinoid tumors are 15 times more common in patients with Crohn's disease. *Inflamm Bowel Dis* 2007;13:1129-34.

2. Tsianos EV, Katsanos KH, Tsianos VE. Role of genetics in the diagnosis and prognosis of Crohn's disease. *World J Gastroenterol* 2012;18:105-18.
3. Friedman S. Cancer in Crohn's disease. *Gastroenterol Clin North Am* 2006;35:621-39.
4. Freeman HJ. Appendiceal carcinoids in Crohn's disease. *Can J Gastroenterol* 2003;17:43-6.
5. Betteridge JD, Veerappan GR. Pulmonary carcinoid tumor in a patient on adalimumab for Crohn's disease. *Inflamm Bowel Dis* 2012. [Epub ahead of print].
6. Bertino EM, Confer PD, Colonna JE, et al. Pulmonary neuroendocrine/carcinoid tumors: a review article. *Cancer* 2009;115:4434-41.
7. Meisinger QC, Klein JS, Butnor KJ, et al. CT features of peripheral pulmonary carcinoid tumors. *AJR Am J Roentgenol* 2011;197:1073-80.
8. Jeung MY, Gasser B, Gangi A, et al. Bronchial carcinoid tumors of the thorax: spectrum of radiologic findings. *Radiographics* 2002;22:351-65.
9. Lamberts SW, Bakker WH, Reubi JC, et al. Somatostatin-receptor imaging in the localization of endocrine tumors. *N Engl J Med* 1990;323:1246-9.
10. Sandborn WJ, van Assche G, Reinisch W, et al. Adalimumab induces and maintains clinical remission in patients with moderate-to-severe ulcerative colitis. *Gastroenterology* 2012;142:257-65.e1-3.
11. Viola F, Civitelli F, Di Nardo G, et al. Efficacy of adalimumab in moderate-to-severe pediatric Crohn's disease. *Am J Gastroenterol* 2009;104:2566-71.
12. Askling J, Fahrback K, Nordstrom B, et al. Cancer risk with tumor necrosis factor alpha (TNF) inhibitors: meta-analysis of randomized controlled trials of adalimumab, etanercept, and infliximab using patient level data. *Pharmacoepidemiol Drug Saf* 2011;20:119-30.
13. Kreuter A, Meyer MF, Wieland U. Occurrence of penile intraepithelial neoplasia following adalimumab treatment for psoriatic arthritis. *Arch Dermatol* 2011;147:1001-2.
14. Erten S. Endometrium cancer in a female with psoriatic arthritis treated with TNF alpha antagonist adalimumab. *Rheumatol Int* 2011;31:1537-8.
15. Fink G, Krelbaum T, Yellin A, et al. Pulmonary carcinoid: presentation, diagnosis, and outcome in 142 cases in Israel and review of 640 cases from the literature. *Chest* 2001;119:1647-51.

**Cite this article as:** Carcano C, Oliveira EC, Martinez F, Kirsch J. Endobronchial carcinoid tumor in a Crohn disease patient treated with a TNF $\alpha$  inhibitor. *Transl Lung Cancer Res* 2013;2(1):E29-E32. doi: 10.3978/j.issn.2218-6751.2012.12.03