

A 71-year-old male with a 37-cm abdominal tumor

Jiping Wang

Division of Surgical Oncology, Department of Surgery, Brigham and Women's Hospital, Harvard Medical School, Boston, MA, USA

Correspondence to: Jiping Wang, Department of Surgery, Brigham and Women's Hospital, 75 Francis Street, Boston, MA 02445, USA.

Email: jwang39@bwh.harvard.edu.

Received: 14 November 2017; Accepted: 19 November 2017; Published: 21 December 2017.

doi: 10.21037/aos.2017.11.05

View this article at: <http://dx.doi.org/10.21037/aos.2017.11.05>

Case presentation

This is a 71-year-old male noted increased difficulty breathing over the last 3 months especially when laying on his back. Over the last few weeks, patient also experienced difficulty in moving his bowels, urinary urgency and increased frequency. He also noted tingling in his legs bilaterally. CT scan showed a 37-cm predominantly fatty density mass within the abdomen and pelvis probably arising from the retroperitoneum on the left as well as multiple soft tissue masses and is concerning for a liposarcoma (Figures 1,2).

What is the treatment plan (single best answer):

- A. Chemotherapy followed by surgery;
- B. Radiation followed by surgery;
- C. Surgery followed by adjuvant chemotherapy;
- D. Surgery followed by adjuvant radiation;
- E. Surgery followed by surveillance.

Please chose one best answer before continue.

Patient underwent debulking of retroperitoneum and mesenteric liposarcoma, left adrenalectomy, left nephroureterectomy, splenectomy, distal pancreatectomy and resection of psoas muscle. Pathology showed well differentiated liposarcoma (46 cm). Mitoses number less than one [1] per ten [10] HPF. Patient did not receive any adjuvant therapy and now is under surveillance program.

Your comments: (Please send your comments to the Editorial Office at aos@amegroups.com.)

Acknowledgements

None.

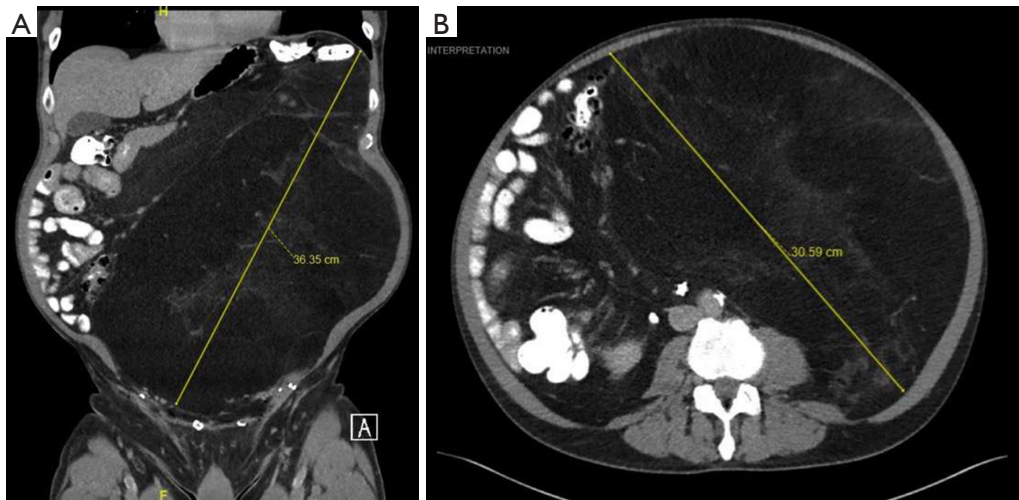


Figure 1 (A) coronal view (B) cross sectional view of the large abdominal mass.



Figure 2 Retroperitoneal liposarcoma (1).

Available online: <http://aos.amegroups.com/post/view/2017121102>

doi: 10.21037/aos.2017.11.05

Cite this article as: Wang J. A 71-year-old male with a 37-cm abdominal tumor. *Art Surg* 2017;1:10.

Footnote

Conflicts of Interest: The author has no conflicts of interest to declare.

Informed Consent: Written informed consent was obtained from the patient for publication of this manuscript and any accompanying images.

References

1. Wang J. Retroperitoneal liposarcoma. *Art Surg* 2017;1:v005. Available online: <http://aos.amegroups.com/post/view/2017121102>