



# Conversion to thoracotomy in thoracoscopic surgery: damnation, salvation or timely choice?

Ahmed Elkhoully<sup>1</sup>, Eugenio Pompeo<sup>2</sup>

<sup>1</sup>Department of Cardiothoracic Surgery, Tanta University, Tanta, Egypt; <sup>2</sup>Department of Thoracic Surgery, Policlinico Tor Vergata University, Rome, Italy

*Correspondence to:* Prof. Eugenio Pompeo. Department of Thoracic Surgery, Policlinico Tor Vergata University, V.le Oxford 81, 00133 Rome, Italy. Email: pompeo@med.uniroma2.it.

*Comment on:* Agzarian J, Shargall Y. Open thoracic surgery: video-assisted thoracoscopic surgery (VATS) conversion to thoracotomy. *Shanghai Chest* 2017;1:31.

Received: 13 November 2017; Accepted: 29 November 2017; Published: 11 January 2018.

doi: 10.21037/shc.2017.12.03

View this article at: <http://dx.doi.org/10.21037/shc.2017.12.03>

Video-assisted thoracic surgery (VATS) is today universally adopted to perform a number of simple and more technically demanding surgical procedures including anatomical pulmonary resection for lung cancer, which are today increasingly performed following an intermediate contrasted period of proven feasibility and strong critics. In fact, the recent evolution of VATS benefitted of significant technological improvements in video-systems and instrumentation, enlarging institutional experiences, accumulation of research data documenting advantages in terms of postoperative pain, morbidity and hospital stay, and equivalent oncological outcomes with open thoracic surgery (1). On the other hand, the possibility to perform more complex surgical procedures in a closed chest as typical of modern VATS continues to stimulate the debate on indications and particularly to raise concerns as to when and how conversion to thoracotomy should be performed.

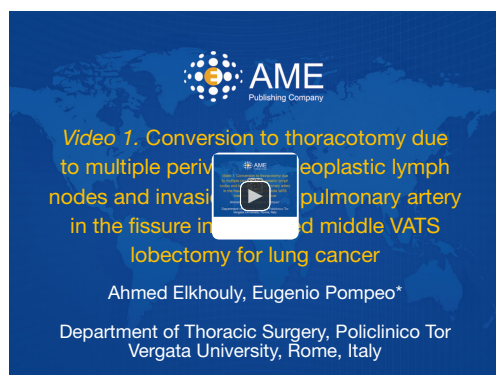
In an interesting review article Drs. Agzarian and Shargall analyze in a comprehensive and sound fashion the issue of conversion to thoracotomy in VATS (2). The authors properly outline that in the last 3 decades indications for VATS have progressively increased whereas in a parallel fashion, contraindications continue to decrease. Indeed even conditions including diffuse pleural adhesions, previous thoracic surgery, neoadjuvant chemotherapy or radiation, central lesions, as well as chest wall or vascular involvement, are now selectively considered eligible for VATS at least by some experienced thoracic surgeons. The authors also noticed that the application of VATS has

been recently expanded to high-risk patients with poor preoperative performance status, compromised respiratory function as well as to elderly patients over 80 years.

The main reasons leading to conversion to thoracotomy have been listed by Drs. Agzarian and Shargall, and include intraoperative complications, technical challenges, anatomical problems and oncological conditions (2). In each of these categories, different reasons may represent the causative factor including an improper surgical maneuvering by a junior surgeon with lack of adequate training or supervision as well as, on the opposite side, an overestimation of an expert surgeon's capacity to deal a difficult and potentially dangerous operative finding.

In this regard, the authors correctly underline that a selection bias exists and VATS technical aptitude continue to demonstrate large variance (2). As a consequence a balance is warranted between deterministic conversions and the surgeon feeling to accept new challenges to enhance personal skills. Overall, it becomes more and more important that the surgeon could promptly foresee when to perform a conversion to thoracotomy prior the occurrence of major complications. This particular aptitude represents in our opinion one of the most important sensibilities that an expert VATS surgeon should develop, namely the capacity to be clearly aware of the personal limits and the consequent ability to convert in a timely and safe manner.

Typical operative conditions in which a timely conversion should be carefully considered include the finding of calcified perivascular lymph nodes or extensive



**Figure 1** Conversion to thoracotomy due to multiple perivascular neoplastic lymph nodes and invasion of the pulmonary artery in the fissure in a planned middle VATS lobectomy for lung cancer (4). Available online: <http://asvidett.amegroups.com/article/view/22325>

scarring as well as of diffuse dense pleural adhesions limiting a clear visualization and exposure of the pulmonary hilum (2). In addition, we believe that during major VATS procedures entailing isolation of pulmonary vessels, the lack of progression over a significant lapse of time can be considered another good indicator for a planned and as yet safe conversion.

Nonetheless, conversion techniques have been divided in planned and emergent and each of these choices has been comprehensively analyzed (2). We would add that the optimal behavior, whenever a planned conversion is needed, can be variable. Indeed, since as shown by Decaluwe *et al.* (3) up to 84% of conversions for operative complications are due to inadvertent vascular bleeding, the technical skills of the surgeon become determinant. In fact, suturing a vascular injury can today often be performed without conversion, provided that adequate instrumentation and consolidated surgeon's training coexist.

It is worth noting that in a large analysis (3) no relation was found with the surgeon's experience when vascular injury requiring conversion to thoracotomy was taken into account since experienced VATS surgeons are likely to face more challenging cases with higher risk for major bleeding (*Figure 1*). On the other hand, for a young surgeon it proves quite difficult to reach an adequate training made during emergency situations entailing vascular injuries. For this reason it might be desirable that computer-based surgical simulators which are now readily available in the market should be increasingly included in modern residency programs to improve the learning curve also in endo suturing techniques (5).

In addition, by increasing the number of VATS lobectomies in most institutions and because of the diffuse use of staplers to divide vessels and bronchi, residents have a lower opportunity to practice performing vascular sutures during open thoracotomy procedures. Overall, these findings may favor the creation of a gap in the learning curve for VATS between the basic knowledge to perform a successful anatomical VATS lung resection and the lack of adequate experience in managing intraoperative vascular complications.

In order to limit operative risks, we believe that some simple gold rules can be kept in mind during major VATS lung resections. Firstly, it is crucial to embark in a VATS lobectomy program once dedicated thoracoscopic instrumentation including curved-tip vascular staplers, endoscopic vascular clamps and dissectors are available in the operating room; secondly, achievement of clear and wide visualization of the pulmonary vessels to be isolated and divided is mandatory and requires in our opinion, proper exposure of the sub-adventitial space, particularly when dealing with pulmonary artery branches; thirdly, it should be absolutely avoided coagulating without having a clear visualization of the coagulator tips. Additionally, when using a harmonic scalpel, it is safer to keep the thinner metallic branch, away from the vessels' wall because this can transmit heat also laterally, particularly when time of coagulation is prolonged possibly leading to inadvertent vascular damage.

Paradoxically, evolutionary changes in VATS have contributed on one side to render surgical maneuvering safer and more accurate, on the other, due to a progressive reduction in the number and extent of the surgical accesses to the pleural cavity; they have often rendered more demanding a prompt management of major inadvertent complications.

As a matter of fact, thoracic surgeons have increasingly adopted single-incision VATS with the aim of improving cosmetic results and further minimize both the surgical invasiveness and postoperative pain. In addition, in an attempt of summing up the advantages of VATS to those of a less invasive anesthesia management, awake VATS strategies entailing avoidance of double lumen tube intubation with mechanical ventilation, based on adoption of local or epidural anesthesia protocols with maintenance of spontaneous ventilation, are being increasingly employed to perform a number of simple and advanced VATS procedures including anatomical lung resections, thymectomy and even tracheal and sleeve resections (6).

It is thus evident that either adoption of uniportal VATS

approaches or of awake/non-intubated strategies may have a practical impact on conversion to thoracotomy and may add some peculiar concerns to this need.

In particular, when considering patients who are deemed high-risk for open surgery and general anesthesia with tracheal intubation and who undergo VATS under spontaneous ventilation and awake anesthesia, the need of a conversion to thoracotomy is often associated to the consensual need of a conversion to double-lumen tube intubation, which may further increase operative risks. In these instances an accurate anamnesis implemented by chest computed tomography assessment is necessary to rule out any direct or indirect sign of fibrous pleural adhesions or other unexpected anatomical findings, which may contraindicate VATS. Another option that we have employed in selected critical instances is to preoperatively explain to the patient that the operation would be attempted by VATS under awake anesthesia but that following the introduction of the camera, the finding of any anatomical condition rendering surgical maneuvers too technically demanding will lead the procedure to be definitively abandoned.

Within these multifaceted scenarios, the need of conversion to thoracotomy must never be felt by the surgeon as a failure. In anyway, conversion to thoracotomy must be performed whenever necessary and should be considered as one of the contemplated steps of every VATS procedure to be chosen on demand by the surgeon in order to maximize patient's safety and the full success of the operation. This concept is corroborated by literature data (2) showing that end results of VATS procedures that are converted to thoracotomy do not differ from those achieved through elective thoracotomy except for the length of operative time.

In conclusion, conversion to thoracotomy in VATS should never be considered a sort of damnation for the surgeon nor an emergency salvation maneuver for the patient. Rather, this maneuver must be kept in mind as a standardized option to be chosen in a timely fashion whenever the surgeon faces unexpected anatomical findings or feels that surgical maneuvers are becoming alarmingly dangerous or tediously inconclusive posing at risk a safe accomplishment of the planned procedure. Such a mature aptitude of the modern VATS surgeon in combination with the development of novel technological tools will continue to favor the progress of VATS and will be likely to enhance the possibilities to successfully perform an increasing number of thoracic surgery procedures in the safest and

least invasive fashion.

## Acknowledgments

*Funding:* None.

## Footnote

*Provenance and Peer Review:* This article was commissioned and reviewed by Dr. Jianfei Shen, MD (Department of Cardiothoracic Surgery, Taizhou Hospital of Zhejiang Province, Wenzhou Medical University, Taizhou, China).

*Conflicts of Interest:* Both authors have completed the ICMJE uniform disclosure form (available at <http://dx.doi.org/10.21037/shc.2017.12.03>). The authors have no conflicts of interest to declare.

*Ethical Statement:* The authors are accountable for all aspects of the work in ensuring that questions related to the accuracy or integrity of any part of the work are appropriately investigated and resolved.

*Open Access Statement:* This is an Open Access article distributed in accordance with the Creative Commons Attribution-NonCommercial-NoDerivs 4.0 International License (CC BY-NC-ND 4.0), which permits the non-commercial replication and distribution of the article with the strict proviso that no changes or edits are made and the original work is properly cited (including links to both the formal publication through the relevant DOI and the license). See: <https://creativecommons.org/licenses/by-nc-nd/4.0/>.

## References

1. Cai YX, Fu XN, Xu QZ, et al. Thoracoscopic Lobectomy versus Open Lobectomy in Stage I Non-Small Cell Lung Cancer: A Meta-Analysis. *PLoS One* 2013;8:e82366.
2. Agzarian J, Shargall Y. Open thoracic surgery: video-assisted thoracoscopic surgery (VATS) conversion to thoracotomy. *Shanghai Chest* 2017;1:31.
3. Decaluwe H, Petersen RH, Hansen H, et al. Major intraoperative complications during video-assisted thoracoscopic anatomical lung resections: an intention-to-treat analysis. *Eur J Cardiothorac Surg* 2015;48:588-98; discussion 599.
4. Elkhoully A, Pompeo E. Conversion to thoracotomy due to multiple perivascular neoplastic lymph nodes and invasion

of the pulmonary artery in the fissure in a planned middle VATS lobectomy for lung cancer. *Asvide* 2018;5:011. Available online: <http://asvidett.amegroups.com/article/view/22325>

5. Jensen K, Bjerrum F, Hansen HJ, et al. Using virtual

reality simulation to assess competence in video-assisted thoracoscopic surgery (VATS) lobectomy. *Surg Endosc* 2017;31:2520-8.

6. Pompeo E. Awake thoracic surgery--is it worth the trouble? *Semin Thorac Cardiovasc Surg* 2012;24:106-14.

doi: 10.21037/shc.2017.12.03

**Cite this article as:** Elkhoully A, Pompeo E. Conversion to thoracotomy in thoracoscopic surgery: damnation, salvation or timely choice? *Shanghai Chest* 2018;2:2.