



A review of the surgical principles of primary and post-chemotherapy retroperitoneal lymph node dissection for non-seminomatous germ cell tumors

Nadia V. Halstead, Nicholas G. Cost

Department of Surgery, Division of Urology, University of Colorado Anschutz Medical Campus and Children's Hospital Colorado, Aurora, CO, USA

Contributions: (I) Conception and design: Both authors; (II) Administrative support: Both authors; (III) Provision of study materials or patients: Both authors; (IV) Collection and assembly of data: Both authors; (V) Data analysis and interpretation: Both authors; (VI) Manuscript writing: Both authors; (VII) Final approval of manuscript: Both authors.

Correspondence to: Nadia V. Halstead, MD, MPH. Department of Surgery, Division of Urology, University of Colorado Anschutz Medical Campus and Children's Hospital Colorado, 12631 East 17th Ave, M/S C-319, Aurora, CO 80045, USA. Email: Nadia.Halstead@CUAnschutz.edu.

Abstract: Testicular cancer is the most common solid malignancy in men 20–40 years old, notably with a slowly increasing prevalence. The survival rate associated with non-seminomatous germ cell tumors (NSGCT) has seen a dramatic improvement over the past several decades. This improvement in survival has been largely attributed to a multidisciplinary approach that includes cisplatin-based chemotherapies and surgical advances in retroperitoneal lymph node dissection (RPLND). While most urologists are comfortable operating in the retroperitoneum and despite the pathologic staging and treatment benefits demonstrated by the RPLND, it remains a technically challenging surgery with a high potential for risk and morbidity even in the most skilled hands. These challenges are especially pronounced in the post-chemotherapy setting due to severe desmoplasia. Therefore, it should be performed by experienced surgeons at high volume centers. Surgeons attempting this surgery should possess a detailed knowledge of retroperitoneal anatomy, lymphatic drainage and associated metastatic pattern, and ability to troubleshoot potential complications should they arise as these are of paramount importance for success of this operation. Laparoscopic and robotic surgical approaches have been gaining traction and are useful for pathologic staging, but there is still insufficient evidence to support these modalities for curative intent. In this review we detail the surgical principles of RPLND.

Keywords: Retroperitoneal lymph node dissection (RPLND); testis cancer; retroperitoneal; testicular cancer; germ cell tumor

Received: 09 March 2020; Accepted: 03 August 2020; Published: 25 March 2021.

doi: 10.21037/amj-20-62

View this article at: <http://dx.doi.org/10.21037/amj-20-62>

Introduction

Testicular cancer is the most common solid malignancy in men 20–40 years old (1-3). There are expected to be roughly 9,560 new cases in 2019, the vast majority of which will be low stage, and an estimated 410 deaths (4). While overall it remains a rare malignancy (1%), this has been increasing in prevalence over the past two decades (1-3). The 5-year survival rate has dramatically improved from

64% to now >95%, in large part due to cisplatin-based chemotherapies and surgical advances, making it one of the highest survival rates of any cancer (3,5).

The treatment of patients with testicular cancer requires coordination among a multidisciplinary team comprised of urologists, medical oncologists, radiation oncologists, pathologists, and radiologists (1). The role of the urologist is predominately surgical, with radical inguinal orchiectomy

Table 1 Indications for RPLND

Stage & criteria	Recommendation
Stage IA NSGCT that desire treatment or are noncompliant	Can be offered as primary treatment (not preferred)
Stage IB NSGCT	Can be offered as primary treatment
Stage I NSGCT with secondary somatic malignancy (teratoma)	Can be offered as primary treatment
Stage IIA NSGCT with normal tumor markers post orchiectomy	Can be offered as primary treatment
Stage IIB NSGCT with normal tumor markers and lymph node metastasis in expected distribution	Can be offered as primary treatment in highly selected cases
Stage IIA/B NSGCT post chemotherapy with normal tumor markers and a retroperitoneal mass ≥ 1 cm	Can be offered as post-chemotherapy management
Stage IIA/B NSGCT post chemotherapy with normal tumor markers and < 1 cm mass (in select cases)	Can be offered as post-chemotherapy management in selected cases
Stage IIA–III seminoma after primary chemotherapy and a residual retroperitoneal mass > 3 cm with normal tumor marker and illumination on PET scan (if technically feasible)	Can be offered as post-chemotherapy management

RPLND, retroperitoneal lymph node dissection; NSGCT, non-seminomatous germ cell tumors.

being the mainstay of primary treatment and also includes the potential need for retroperitoneal lymph node dissection (RPLND) thereafter pending pathology and staging via tumor markers alpha-fetoprotein (AFP), beta human chorionic gonadotropin (bHCG), and lactate dehydrogenase (LDH) (1). The goal of treatment is oncologic cure while minimizing treatment-related toxicity (2). While cisplatin-based chemotherapies resulted in a dramatic improvement in survival, it is associated with the potential for significant morbidity with long-term late effects, the most serious of which are cardiovascular disease and secondary malignancies (6). Primary RPLND can offer patients oncologic cure without chemotherapy and post-

chemotherapy RPLND (PC-RPLND) a curative option following chemotherapy.

This review aims to highlight the surgical principles of RPLND, focusing on anatomical considerations and surgical approaches. We reviewed English language literature over the past 40 years, focusing on landmark studies for topics related to surgical principles of RPLND.

Indications

Per National Comprehensive Cancer Network (NCCN) and American Urological Association (AUA) guidelines, RPLND may be offered to a subset of patients with germ cell tumors, outlined in *Table 1* (1,7).

The retroperitoneum is the most common site for metastatic disease for those with testicular cancer and residual disease is most commonly found in the retroperitoneum after chemotherapy (2,8). Those with non-seminomatous germ cell tumors (NSGCT) are at higher risk for nodal involvement (2). A predominance of embryonal histology, lympho-vascular invasion, and teratoma in the primary tumor place patients at high risk for metastatic disease and therefore the urologists index of suspicion should remain high in those presenting with these pathologic characteristics (9,10).

RPLND is currently the only reliable method to detect micro-metastatic disease and aids in pathologic staging. There also remains a low recurrence rate after a full bilateral template RPLND, making the intent of this surgery curative in nature (2). The cure rates for those with pN1 retroperitoneal malignancy and teratoma (pN1–3) are remarkably high with RPLND alone (2). Roughly 73–78% of patients with clinical stage I NSGCT are cured with RPLND, negating need for further treatment (10,11). Teratoma may be present in 15–25% of pre-chemotherapy retroperitoneal masses associated with testicular GCT, which are resistant to chemotherapy and therefore favor the surgical option (2). Long-term cancer specific survival is nearly 100% for those with teratoma only who undergo RPLND (2). Surgery may allow a significant number of patients to avoid chemotherapy altogether, eliminating the toxic side effects associated with chemotherapy that impact quality of life.

Patients with NSGCT post-chemotherapy most likely to benefit from RPLND are those with initial lymph nodes ≤ 3 cm with residual nodes after chemotherapy and those with lymph nodes > 3 cm (12). Those most likely to relapse to the retroperitoneum are those with lymph nodes ≥ 5 cm.

Currently there are two prospective studies (SEMS and PRIMETEST) evaluating RPLND as a primary treatment for metastatic seminoma (13). However, this is not currently the standard of care and thus will not be the focus of this review.

Surgical principles

Many urologists are comfortable operating in the retroperitoneum, but the nerve-sparing RPLND poses some unique challenges given the anatomy and nature of the disease. Important in planning a nerve-sparing RPLND, the surgeon must ensure abdominal imaging (CT abdomen/pelvis with contrast or MRI) has been completed within the last 4 weeks and tumor markers (AFP, bHCG) within the last 7–10 days to confirm staging prior to operation (1,3).

While nerve-sparing RPLND has proven oncologic efficacy with generally low short and long-term morbidity, it remains a technically complex operation even in the hands of skilled surgeons. Therefore, we recommend referral to an experienced surgeon at a high-volume center. Here we will outline the surgical principles of RPLND.

Anatomy

The retroperitoneum houses critically important structures and therefore detailed knowledge of the anatomy is paramount for a successful operation. The surgeon should perform a careful review of preoperative imaging to identify normal or aberrant anatomy, accessory vessels, location and extent of masses, and their involvement of nearby structures.

Lymphatic drainage and therefore metastatic spread generally follow a predictable pattern bypassing the pelvic lymph nodes. The spermatic cord lymphatics travel to the retroperitoneal lymph node chain but differ according to side of primary testis tumor. A tumor within the right testis drains to the interaortocaval, precaval nodes, and paracaval nodes. The left testis drains to the paraaortic and preaortic nodes (14). Lymphatic spread in this area then drains from right to left and may have some drainage caudally towards the aortic bifurcation (15).

The classic full bilateral open template RPLND has largely been replaced with modified template nerve-sparing dissections with aims to reduce morbidity by helping to preserve ejaculatory function and fertility. The nerves for emission and ejaculation course through the retroperitoneum. Sympathetic fibers from the ventral

roots of T12–L3 spinal nerves control emission through contracting the vas deferens, prostate, and seminal vesicles (16). These nerves extend to the paravertebral sympathetic ganglion chain behind the inferior vena cava (IVC) and aorta. They then converge in front of the aortic bifurcation to form the hypogastric plexus. Both somatic and autonomic nerve fibers at the sacral and lumbar vertebra contribute to antegrade ejaculation by closing the bladder neck, relaxing the external sphincter, and contracting the bulbocavernosus muscle. The nerve fibers for ejaculation also travels through the paravertebral sympathetic chain and pelvic plexus.

Metastatic pattern

A full bilateral nerve-sparing RPLND template was described in 1988 and reported 97% preservation of antegrade ejaculation with excellent oncologic control (17). The surgical template is based around the anticipated distribution of nodal metastases using anatomical mapping studies (17). Donohue *et al.* found that in patients with stage II NSGCT 93% of right sided tumors appear in the interaortocaval nodes and left sided tumors have 88% presenting preaortic and 86% paraaortic (18). Post-chemotherapy patients with stage I, IIa, and IIb left sided tumors also generally follow a predictable pattern of spread consistent with a left modified template (19). While it may be uncommon to have contralateral node involvement in those with early stage cancers, it is more common in patients with right sided tumors given the direction of lymphatic drainage. In addition to patients with right sided tumors, patients with clinical stage IIc or III generally have more variable patterns of lymphatic spread (19). In *Table 2* and *Figure 1* the surgical template is outlined.

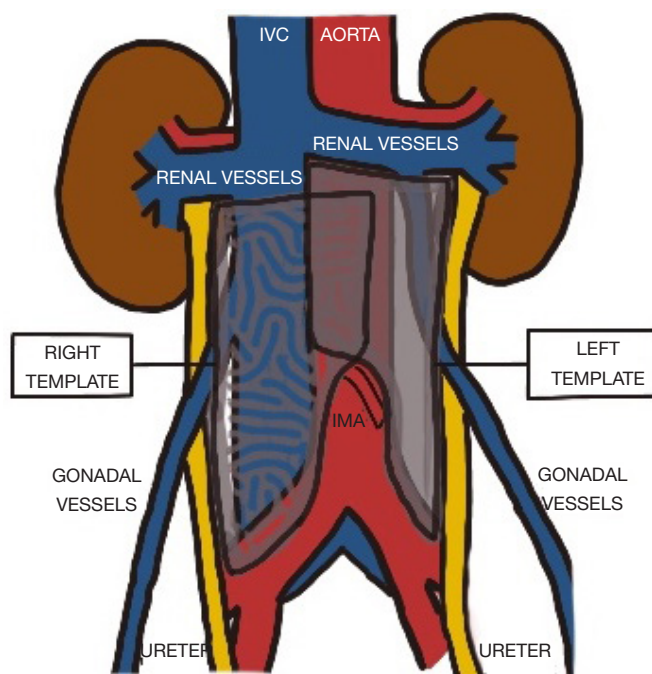
Generally, an ipsilateral modified nerve-sparing template may be applied to clinical stage I and low volume clinical stage II patients. The NCCN guidelines assert that all PC-RPLND patients should undergo a full bilateral template with boundaries being the renal vessels cephalad, ureters lateral, and the common iliac vessels caudal but may consider extending the template to the diaphragmatic crus and below the aortic bifurcation in those post-chemotherapy patients with stage IIc or III (7,20).

However, the Heidenreich criteria suggests that a unilateral modified template may be used in PC-RPLND if the residual masses are <5 cm and if the pre-chemotherapy metastases are found in the expected ipsilateral nodes (21). The full bilateral template is still supported for those with

Table 2 Boundaries of the modified surgical template

Borders	Right	Left
Lateral	Right ureter	Left ureter
Medial	Anterior infra-renal aorta—includes precaval, paracaval, retrocaval, and interaortocaval regions	Medial aspect of infra-renal IVC—includes pre-aortic up to the IMA, para-aortic, and retroaortic regions
Caudal	Anterior aspect of right common iliac vessels at its bifurcation	Anterior aspect of left common iliac at its bifurcation
Cephalad*	Renal vessels	Renal vessels
Posterior	Psoas muscle to the anterior spinous ligament	

*, If suprahilar or retrocrural masses are identified, then the boundary becomes the diaphragmatic crura. IVC, inferior vena cava.

**Figure 1** RPLND modified template. RPLND, retroperitoneal lymph node dissection; IVC, inferior vena cava.

contralateral spread, involvement of the interaortocaval nodes, or residual masses >5 cm. The benefit of the unilateral template option was similar oncologic efficacy with decreased morbidity (preserving antegrade ejaculation). The study was again validated and found to be a reliable selection method (22).

Vascular considerations

Depending on pre- and intraoperative findings,

some patients may require vascular resection and/or reconstruction of the great vessels which substantially increases the risks associated with surgery. Preparation leading up to surgery may help mitigate some of the risks associated with the operation. Significant predictors of the need for great vessel resection or reconstruction in PC-RPLND include vessel deformity, dominant mass size ≥ 5 cm, IVC involvement >135 degrees, and aortic involvement >330 degrees (23,24).

Donohue *et al.* found >60% of post-chemotherapy

IVC resections due to tumor involvement can house active cancer and >30% with teratoma elements thereby adding justification for IVC resection in these cases (25). The IVC more commonly requires resection or reconstruction. The increasing need can be associated with higher International Germ Cell Cancer Collaborative Group (IGCCCG) risk class and mass size (nearly 18% in those with masses ≥ 5 cm) (24). Other common indications for vena cava resection and/or grafting including IVC tumor thrombus, need for wider resection for tumor clearance, and scar occlusion of the cava.

Need for aortic resection and/or reconstruction closely mirrors the indications for the IVC. However, since the aorta withstands greater pressures it is at high risk of rupture or developing fistulae to surrounding sites. Risk for aortic rupture is caused by disruption in the integrity of the wall of the vessel, usually by means of extended dissection in the subadventitia due to tumor involvement (25). In this instance it may be prudent to perform prospective grafting at the time of dissection as the area is already exposed during RPLND. Aortoenteric fistulas more commonly occur when there are bowel enterotomies or violation of the bowel serosa during dissection. Primary bowel repair, omental interposition, and aortic grafting may help protect against development of fistula (25).

In patients with tumor encasing the renal hilum or kidney itself adjunctive nephrectomy may be indicated as residual disease may be present in ~66% of nephrectomy specimens (26). Patients should be appropriately counseled pre-operatively about the downstream effects of associated nephrectomy, including risks of chronic renal insufficiency.

Minimally invasive surgery

Most studies have focused around the standard open RPLND, but with minimally invasive surgery gaining traction over the past few decades there have been efforts to incorporate this as an option for some patients. The robotic approach allows excellent visualization and greater dexterity when compared to laparoscopy. Unfortunately, to this day the studies supporting minimally invasive approaches have been lacking in power.

One early study of seven patients reported a 51.7% complication rate associated with laparoscopic PC-RPLND (27). Since then many studies have reported vastly improving outcomes. This may partly be due to increasing power of the studies and increasing technical skill of the

surgeons as these minimally invasive modalities have been around longer, especially robotic surgery (28-31). Studies have found less blood loss in MIS, better postoperative recovery, but more chylous ascites (32,33). Studies spanning several years admit to improvement in outcomes with increasing experience of the surgeon (34).

A recent study from Indiana University reported on patients referred to their center for recurrences following robotic RPLND and found 4 out of 5 patients had out of field recurrences in unexpected locations with subsequent high treatment burdens (35). While the study is limited in size, the unusual recurrences still merit further investigation with studies looking at long term follow-up for patients undergoing robotic RPLND. Many other studies advocating MIS approaches to RPLND generally report on feasibility and short-term complications. Additionally, they are retrospective in nature and therefore are limited by bias. Laparoscopic surgery can be considered for pathologic staging and while robotic aims to match the oncologic efficacy of open RPLND there ultimately is insufficient data to support these approaches as a standard of care over open RPLND for curative intent (33).

Complications and considerations

Complications for a primary nerve-sparing RPLND for stage I NSGCT have been cited as 14.2% minor complications and 5.4% major (36). Although there is >90% preservation of antegrade ejaculation in patients undergoing a unilateral nerve-sparing RPLND all patients should be counseled pre-operatively on the risk of infertility and offered sperm banking when appropriate (1,36). Patients who have undergone chemotherapy have the highest rates of infertility, but the risk still remains with surgery due to risks of nerve injury and subsequent retrograde ejaculation (37,38). The risk of nerve injury has largely been mitigated by the nerve-sparing template (38). However, the quality of dissection should not be compromised solely in an effort to preserve nerve function.

PC-RPLND poses a more technically challenging operation due to the post-chemotherapy desmoplasia (33). This leads to greater operative times due to the delicate nature of the operation and association with the great vessels.

While many have moved to unilateral modified nerve sparing templates, there may be disease outside of the template in 3–23% of patients (39). Extending the right template to include paraaortic, preaortic, and right common

iliac can decrease extratemplate disease to 2%. Extended left sided templates to include intraaortocaval, precaval, paracaval, and left common iliac can decrease this to 3%. Extended templates are not necessary in all patients and may lead to over treatment. However, urologists should bear in mind that reoperation is associated with a relatively high complication rate (27%) and extended hospital stays. This is also associated with a significant drop in survival outcomes, some quoting a 67% 5-year disease specific survival rate (40). Therefore, it is of utmost importance to perform a complete resection within the designated templates.

There are some other general drawbacks to the RPLND. This remains a major abdominal surgery and even with the most experienced surgeons there are risks of complications and impacts to quality of life (2). As this surgery demands a high-volume center and experienced surgeon it may not be available as a feasible option to all patients as access becomes a hindrance.

Conclusions

The surgical approaches to RPLND have undergone dramatic improvements over the past several decades in an aim to limit morbidity and improve oncologic outcomes. The nerve-sparing RPLND has become a mainstay of surgical treatment for some but is not without complications and risks. A sound understanding of anatomy is required for successful RPLND and therefore these operations should be reserved for experienced surgeons. As more technological advances are made in surgery and robotic approaches are more closely studied, we may see a shift in the learning curve and expansion in the number of surgeons able to offer this surgery to their patients.

Acknowledgments

Funding: None.

Footnote

Provenance and Peer Review: This article was commissioned by the Guest Editor (Simon P. Kim) for the series “Surgical Management of Genitourinary Malignancies” published in *AME Medical Journal*. The article has undergone external peer review.

Conflicts of Interest: Both authors have completed the ICMJE uniform disclosure form (available at <https://amj.amegroups.com/article/view/10.21037/amj-20-62/coif>). The series “Surgical Management of Genitourinary Malignancies” was commissioned by the editorial office without any funding or sponsorship. The authors have no other conflicts of interest to declare.

Ethical Statement: The authors are accountable for all aspects of the work in ensuring that questions related to the accuracy or integrity of any part of the work are appropriately investigated and resolved.

Open Access Statement: This is an Open Access article distributed in accordance with the Creative Commons Attribution-NonCommercial-NoDerivs 4.0 International License (CC BY-NC-ND 4.0), which permits the non-commercial replication and distribution of the article with the strict proviso that no changes or edits are made and the original work is properly cited (including links to both the formal publication through the relevant DOI and the license). See: <https://creativecommons.org/licenses/by-nc-nd/4.0/>.

References

1. American Urological Association. diagnosis and treatment of early stage testicular cancer: AUA guideline (2019). Available online: <https://www.auanet.org/guidelines/testicular-cancer-guideline> (Accessed February 7, 2020).
2. Stephensen AJ, Gilligan TD. Neoplasms of the Testis. In: Partin A. editor. Campbell-Walsh Urology. 12th ed. Philadelphia: Elsevier, 2021. Available online: <https://www-clinicalkey-com.proxy.hsl.ucdenver.edu/#!/content/book/3-s2.0-B9781455775675000340> (Accessed February 8, 2020).
3. Motzer RJ, Jonasch E, Agarwal N, et al. Testicular cancer, version 2.2015. J Natl Compr Canc Netw 2015;13:772-99.
4. Siegel RL, Miller KD, Jemal A. Cancer statistics, 2019. CA Cancer J Clin 2019;69:7-34.
5. De Angelis R, Sant M, Coleman MP, et al. Cancer survival in Europe 1999-2007 by country and age: results of EUROCare--5-a population-based study. Lancet Oncol 2014;15:23-34.
6. Haugnes HS, Bosl GJ, Boer H, et al. Long-term and late effects of germ cell testicular cancer treatment and implications for follow-up. J Clin Oncol 2012;30:3752-63.
7. National Comprehensive Cancer Network. Testicular cancer (version 2.2020). Available online: https://www.nccn.org/professionals/physician_gls/pdf/testicular.pdf (Accessed February 7, 2020).

8. Toner GC, Panicek DM, Heelan RT, et al. Adjunctive surgery after chemotherapy for nonseminomatous germ cell tumors: recommendations for patient selection. *J Clin Oncol* 1990;8:1683-94.
9. Williams SB, McDermott DW, Dock W, et al. Retroperitoneal lymph node dissection in patients with high risk testicular cancer. *J Urol* 2009;181:2097-101; discussion 2101-2.
10. Nicolai N, Miceli R, Artusi R, et al. A simple model for predicting nodal metastasis in patients with clinical stage I nonseminomatous germ cell testicular tumors undergoing retroperitoneal lymph node dissection only. *J Urol* 2004;171:172-6.
11. Rabbani F, Sheinfeld J, Farivar-Mohseni H, et al. Low-volume nodal metastases detected at retroperitoneal lymphadenectomy for testicular cancer: pattern and prognostic factors for relapse. *J Clin Oncol* 2001;19:2020-5.
12. Fléchon A, Tavernier E, Boyle H, et al. Long-term oncological outcome after post-chemotherapy retroperitoneal lymph node dissection in men with metastatic nonseminomatous germ cell tumour. *BJU Int* 2010;106:779-85.
13. Hu B, Daneshmand S. Retroperitoneal lymph node dissection as primary treatment for metastatic seminoma. *Adv Urol* 2018;2018:7978958.
14. MacLennan GT. Testis. In: MacLennan GT, editor. *Hinman's Atlas of UroSurgical Anatomy*. 2nd ed. Philadelphia: Elsevier, 2012. Available online: <https://www-clinicalkey-com.proxy.hsl.ucdenver.edu/#!/content/book/3-s2.0-B9781416040897000268?scrollTo=%23hl0000955> (Accessed February 8, 2020).
15. Paño B, Sebastià C, Buñesch L, et al. Pathways of lymphatic spread in male urogenital pelvic malignancies. *Radiographics* 2011;31:135-60.
16. Alwaal A, Breyer BN, Lue TF. Normal male sexual function: emphasis on orgasm and ejaculation. *Fertil Steril* 2015;104:1051-60.
17. Large MC, Sheinfeld J, Eggener SE. Retroperitoneal lymph node dissection: reassessment of modified templates. *BJU Int* 2009;104:1369-75.
18. Donohue JP, Zachary JM, Maynard BR. Distribution of nodal metastases in nonseminomatous testis cancer. *J Urol* 1982;128:315-20.
19. Ehrlich Y, Yossepowitch O, Kedar D, et al. Distribution of nodal metastases after chemotherapy in nonseminomatous testis cancer: a possible indication for limited dissection. *BJU Int* 2006;97:1221-4.
20. Carver BS, Shayegan B, Eggener S, et al. Incidence of metastatic nonseminomatous germ cell tumor outside the boundaries of a modified postchemotherapy retroperitoneal lymph node dissection. *J Clin Oncol* 2007;25:4365-9.
21. Heidenreich A, Pfister D, Witthuhn R, et al. Postchemotherapy retroperitoneal lymph node dissection in advanced testicular cancer: radical or modified template resection. *Eur Urol* 2009;55:217-24.
22. Vallier C, Savoie PH, Delpero JR, et al. External validation of the Heidenreich criteria for patient selection for unilateral or bilateral retroperitoneal lymph node dissection for post-chemotherapy residual masses of testicular cancer. *World J Urol* 2014;32:1573-8.
23. Johnson SC, Smith ZL, Nottingham C, et al. Clinical and radiographic predictors of great vessel resection or reconstruction during retroperitoneal lymph node dissection for testicular cancer. *Urology* 2019;123:186-90.
24. Winter C, Pfister D, Busch J, et al. Residual tumor size and IGCCCG risk classification predict additional vascular procedures in patients with germ cell tumors and residual tumor resection: a multicenter analysis of the German Testicular Cancer Study Group. *Eur Urol* 2012;61:403-9.
25. Donohue JP, Thornhill JA, Foster RS, et al. Vascular considerations in postchemotherapy. Retroperitoneal lymph-node dissection: Part I--Vena cava. *World J Urol* 1994;12:182-6.
26. Stephenson AJ, Tal R, Sheinfeld J. Adjunctive nephrectomy at post-chemotherapy retroperitoneal lymph node dissection for nonseminomatous germ cell testicular cancer. *J Urol* 2006;176:1996-9; discussion 1999.
27. Palese MA, Su LM, Kavoussi LR. Laparoscopic retroperitoneal lymph node dissection after chemotherapy. *Urology* 2002;60:130-4.
28. Cresswell J, Scheitlin W, Gozen A, et al. Laparoscopic retroperitoneal lymph node dissection combined with adjuvant chemotherapy for pathological stage II disease in nonseminomatous germ cell tumours: a 15-year experience. *BJU Int* 2008;102:844-8.
29. Bhayani SB, Ong A, Oh WK, et al. Laparoscopic retroperitoneal lymph node dissection for clinical stage I nonseminomatous germ cell testicular cancer: a long-term update. *Urology* 2003;62:324-7.
30. Nicolai N, Tarabelloni N, Gasperoni F, et al. Laparoscopic retroperitoneal lymph node dissection for clinical stage I nonseminomatous germ cell tumors of the testis: safety and efficacy analyses at a high volume center. *J Urol* 2018;199:741-7.
31. Pearce SM, Golan S, Gorin MA, et al. Safety and early

- oncologic effectiveness of primary robotic retroperitoneal lymph node dissection for nonseminomatous germ cell testicular cancer. *Eur Urol* 2017;71:476-82.
32. Nakamura T, Kawauchi A, Oishi M, et al. Post-chemotherapy laparoscopic retroperitoneal lymph node dissection is feasible for stage IIA/B non-seminoma germ cell tumors. *Int J Clin Oncol* 2016;21:791-5.
 33. Schwen ZR, Gupta M, Pierorazio PM. A review of outcomes and technique for the robotic-assisted laparoscopic retroperitoneal lymph node dissection for testicular cancer. *Adv Urol* 2018;2018:2146080.
 34. Janetschek G, Hobisch A, Peschel R, et al. Laparoscopic retroperitoneal lymph node dissection for clinical stage I nonseminomatous testicular carcinoma: long-term outcome. *J Urol* 2000;163:1793-6.
 35. Calaway AC, Einhorn LH, Masterson TA, et al. Adverse surgical outcomes associated with robotic retroperitoneal lymph node dissection among patients with testicular cancer. *Eur Urol* 2019;76:607-9.
 36. Heidenreich A, Albers P, Hartmann M, et al. Complications of primary nerve sparing retroperitoneal lymph node dissection for clinical stage I nonseminomatous germ cell tumors of the testis: experience of the German Testicular Cancer Study Group. *J Urol* 2003;169:1710-4.
 37. Arai Y, Kawakita M, Okada Y, et al. Sexuality and fertility in long-term survivors of testicular cancer. *J Clin Oncol* 1997;15:1444-8.
 38. Jacobsen KD, Ous S, Wæhre H, et al. Ejaculation in testicular cancer patients after post-chemotherapy retroperitoneal lymph node dissection. *Br J Cancer* 1999;80:249-55.
 39. Eggener SE, Carver BS, Sharp DS, et al. Incidence of disease outside modified retroperitoneal lymph node dissection templates in clinical stage I or IIA nonseminomatous germ cell testicular cancer. *J Urol* 2007;177:937-42; discussion 942-3.
 40. McKiernan JM, Motzer RJ, Bajorin DF, et al. Reoperative retroperitoneal surgery for nonseminomatous germ cell tumor: clinical presentation, patterns of recurrence, and outcome. *Urology* 2003;62:732-6.

doi: 10.21037/amj-20-62

Cite this article as: Halstead NV, Cost NG. A review of the surgical principles of primary and post-chemotherapy retroperitoneal lymph node dissection for non-seminomatous germ cell tumors. *AME Med J* 2021;6:2.