doi: 10.3978/j.issn.1000-4432.2017.06.07
View this article at: http://dx.doi.org/10.3978/j.issn.1000-4432.2017.06.07

中山大学中山眼科中心梁凌毅教授的文章“Protruding Iris Collarette”在《新英格兰医学杂志》发表

中山大学中山眼科中心科技处

3月16日，中山大学中山眼科中心梁凌毅教授的文章“Protruding Iris Collarette”[凸起的虹膜领(又称虹膜卷缩轮)]以临床医学图片形式发表于《新英格兰医学杂志》(*The New England Journal of Medicine* 2017 Mar 16，图1)。《新英格兰医学杂志》是由美国麻州医学协会所出版的医学期刊，杂志主要提供重要的、未被刊登过的研究成果、临床发现以及观点，注重文章的实用性，文章多为指导临床实践。它也是一种目前全世界最受欢迎及广受阅读的同行审阅性质的综合性医学期刊，影响因子59.558分。

梁凌毅教授偶然发现一位结膜炎就诊患者的双眼虹膜正常解剖的变异——异常凸起的虹膜领(又称虹膜卷缩轮)，如文中图片所示。该变异是良性的，目前尚无证据其与疾病相关。该患者中异常突起的虹膜领可能为胚胎时期瞳孔膜吸收不完全所导致。此外，它是否是临床上永久性瞳孔残膜的一种变异表现尚不明确。虹膜领是虹膜的重要的解剖结构，位于距瞳孔缘1.5~2 mm处、与瞳孔缘平行的环形突起，区分虹膜中央瞳孔区和外周睫状体区。

以往大家对虹膜卷缩轮关注不多，但近年热门的虹膜个人识别以及虹膜形态与全身疾病的关系都和虹膜卷缩轮相关，值得进一步关注。

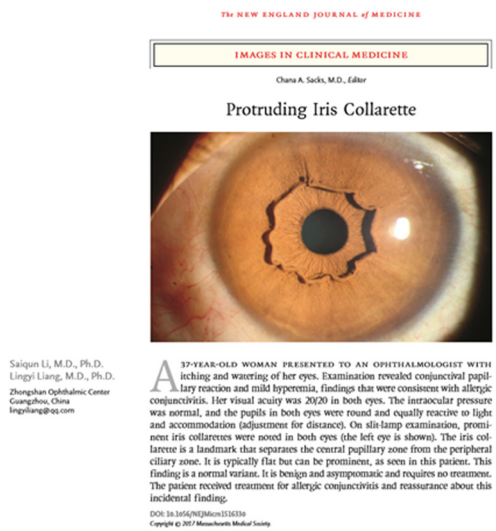
The NEW ENGLAND JOURNAL of MEDICINE

IMAGES IN CLINICAL MEDICINE

Chana A. Sacks, M.D., Editor

Protruding Iris Collarette

Saiqun Li, M.D., Ph.D.
Lingyi Liang, M.D., Ph.D.
Zhongshan Ophthalmic Center
Guangzhou, China
lingyiliang@qq.com

A 37-YEAR-OLD WOMAN PRESENTED TO AN OPHTHALMOLOGIST WITH itching and watering of her eyes. Examination revealed conjunctival papillary reaction and mild hyperemia, findings that were consistent with allergic conjunctivitis. Her visual acuity was 20/20 in both eyes. The intraocular pressure was normal, and the pupils in both eyes were round and equally reactive to light and accommodation (adjustment for distance). On slit-lamp examination, prominent iris collarettes were noted in both eyes (the left eye is shown). The iris collarette is a landmark that separates the central pupillary zone from the peripheral ciliary zone. It is typically flat but can be prominent, as seen in this patient. This finding is a normal variant. It is benign and asymptomatic and requires no treatment. The patient received treatment for allergic conjunctivitis and reassurance about this incidental finding.

DOI: 10.1056/NEJMicm1516330
Copyright © 2017 Massachusetts Medical Society.

图1 梁凌毅教授文章“Protruding Iris Collarette”发表于《新英格兰医学杂志》

文章链接：http://www.nejm.org/doi/full/10.1056/NEJMicm1516330

本文引用：中山大学中山眼科中心科技处. 中山大学中山眼科中心梁凌毅教授的文章“Protruding Iris Collarette”在《新英格兰医学杂志》发表[J]. 眼科学报, 2017, 32(2): 115. doi: 10.3978/j.issn.1000-4432.2017.06.07

收稿日期 (Date of reception)：2017–03–20