



Narrative review of flaps and grafts in robotic reconstructive urologic surgery

Karen M. Doersch^{1^}, Laena Hines¹, Divya Ajay²

¹Department of Urology, University of Rochester Medical Center, Rochester, NY, USA; ²Sidney Kimmel Center for Prostate and Urologic Cancers, Memorial Sloan Kettering Cancer Center, New York, NY, USA

Contributions: (I) Conception and design: D Ajay, KM Doersch; (II) Administrative support: All authors; (III) Provision of study materials or patients: D Ajay, KM Doersch; (IV) Collection and assembly of data: All authors; (V) Data analysis and interpretation: All authors; (VI) Manuscript writing: All authors; (VII) Final approval of manuscript: All authors.

Correspondence to: Karen M. Doersch, MD, PhD. Department of Urology, University of Rochester Medical Center, 601 Elmwood Avenue, Box 656, Rochester, NY 14610, USA. Email: karen_doersch@urmc.rochester.edu.

Background and Objective: Flaps and grafts are used for filling dead space, ureteral substitution, and as mesh alternatives. The surgical robot is invaluable in urologic reconstructive surgery due to the ability of the robot to reach the deep pelvis, its minimally invasive access, the ability to use indocyanine green to identify structures and assess tissue perfusion and viability, and ergonomics for the surgeon. Robotic reconstruction can involve tissue transfer in the form of flaps and grafts to provide form and function to organs that have been damaged by iatrogenic injuries, trauma, infections, cancer, radiation injury, or congenital abnormalities. Common flaps and grafts can be readily adapted to the robotic approach. In this literature review, we examine the robotic use of flaps and grafts in reconstructive urology.

Methods: A thorough literature review was conducted via a PubMed search for predefined terms.

Key Content and Findings: Flaps and grafts in reconstructive urology are used for interposition, ureteral substitution, and as mesh alternatives. Omental flaps are used for tissue interposition, or to provide structure and nutrients, and are easily employed with the robot. Various robotic applications of peritoneal flaps have been described. Vascular rectus abdominis musculocutaneous flaps are well-vascularized flaps that occupy dead space and provide structural support, which can be harvested readily with the robot. Sigmoid epiploica are an excellent flap for pelvic reconstruction. Gracilis flaps and fascia lata grafts are well-tolerated and provide space occupying tissue. Boari flaps aid in robotic ureteral reconstruction, especially in the setting of long defects. Oral mucosa is excellent for ureteral or bladder neck reconstruction. Rectal mucosa is well-tolerated and easy to harvest robotically for a variety of urinary tract reconstructive applications. The appendix or ileum can be interposed for repair of damaged ureters.

Conclusions: Various flaps and grafts have been adapted for robotic reconstructive urology. As the field develops, refinement of techniques and innovation in flaps and employment of the robot will propel this field forward. More studies, especially comparative studies, are needed to elucidate the flaps and grafts that are most likely to be successful with the least morbidity for each use case.

Keywords: Omental flap; peritoneal flap; ureteral reconstruction; vascular rectus abdominus musculocutaneous flap; fistula repair

Received: 29 June 2023; Accepted: 13 October 2023; Published online: 16 November 2023.

doi: 10.21037/ales-23-36

View this article at: <https://dx.doi.org/10.21037/ales-23-36>

[^] ORCID: 0000-0001-8374-9639.

Introduction

Background

Robotic reconstruction of the urinary tract is intended to restore anatomy and function to improve quality of life. Tissue substitution, in the form of flaps and grafts is a common strategy to replace damaged or absent tissue and fill or obliterate dead space. Flaps are tissues that remain attached to their original blood supply, which have the advantage of increased perfusion, resulting in improved take and reduced infections. However, flaps can be difficult to harvest, carry significant morbidity, or may not reach the desired location for reconstructive use. Grafts are detached from their original blood supply and then translocated to the desired location, which have the advantage of being able to reach and being easy to harvest, resulting in reduced morbidity. Grafts rely on blood and nutrient supply at the host site via imbibition (passive diffusion of nutrients) and inosculation (ingrowth of new vasculature). When these processes are insufficient to support the graft, graft failure and atrophy occur. Minimally invasive approaches using the robot have the advantage of smaller incisions, better visualization, and shorter recovery than open approaches.

Rationale and knowledge gap

Flaps and grafts are broadly employed in reconstructive urology. However, there are few reviews discussing and comparing the properties of these various grafts and flaps and their applicability to reconstructive urology employing

a robotic approach.

Objective

In this review we will discuss flaps and grafts used in robotic reconstructive urologic surgery, including their potential roles, and considerations for harvest and placement during robotic surgery. The authors of this review will not take a position as to whether tissue interposition is necessary for various reconstructive applications but rather discuss options for flaps and grafts that are amenable to placement via a robotic approach when tissue interposition is desired. We present this article in accordance with the Narrative Review reporting checklist (available at <https://ales.amegroups.com/article/view/10.21037/ales-23-36/rc>).

Methods

A thorough literature search was conducted using PubMed to search for the terms listed in *Table 1* between June 5th and 6th, 2023 by KMD. Literature was then reviewed for relevance by KMD. Literature review was evaluated for completeness by DA.

Findings

General considerations

Reconstructive procedures in urology are employed to restore form and function in the setting of injuries or congenital disruptions of typical passage of urine from the

Table 1 Search criteria and characteristics

Items	Specification
Date of search	6/5/2023, 6/6/2023
Databases and other sources searched	PubMed
Search items used	Robotic AND omental flap; VRAM and urology; VRAM AND robotic; vertical rectus abdominis myocutaneous AND robotic, vertical rectus abdominis, robotic AND peritoneal flap; epiploic flap; robotic AND gracilis flap; robotic AND boari flap; appendiceal interposition; robotic AND ileal interposition; robotic AND ileal diversion; TAMIS AND urology; robotic AND alloderm; buccal graft AND robotic; fascia lata AND urology
Timeframe	2000–2023
Inclusion and exclusion criteria	Inclusion: related to robotic urologic surgery and/or graft use; original research or systematic reviews. Exclusion: duplicate, non-English language, full text unavailable, describing non-urologic procedures, article commentaries or narrative review articles, non-human studies
Selection process	Selection was performed by KMD and evaluated by DA

Table 2 Flaps and grafts: list of flaps and grafts and their characteristics

Tissue type	Flap or graft	Blood supply	Donor site	Common uses
Ileum	Flap	Ileocolic artery, branch of the superior mesenteric artery	Ileum	Urinary diversion; bladder augmentation; ureteroplasty
Visceral peritoneum	Flap	Arterial: superior and inferior mesenteric arteries; venous: portal vein	Intraabdominal organs	Covering defects in the pelvis
Parietal peritoneum	Flap	Arterial: iliac, lumbar, and epigastric arteries; venous: inferior vena cava	Abdominal wall	Covering defects in the pelvis
Omentum	Flap	Left and right gastroepiploic artery and vein	Transverse colon	Wrapping ureter; occupying intrabdominal or pelvic space
Sigmoid epiploica	Flap	Contain 2 arterioles and 1 venule	Sigmoid colon	Covering defects in the pelvis
Gracilis	Flap	Deep femoral artery	Medial thigh	Covering defects in the pelvis; gender affirming genitoplasty
VRAM	Flap	Deep inferior epigastric artery and vein	Abdominal wall	Occupying intrabdominal or pelvic space
Boari	Flap	Superior vesical artery	Superior bladder	Ureteroplasty
Appendiceal	Flap	Appendiceal artery, branch of the ileocolic artery	Mobilized from cecum	Ureteroplasty; catheterizable channel
Rectal	Flap or graft	Rectal arteries and veins	Rectum	Urethroplasty; vaginal reconstruction
Oral mucosa	Graft	Imbibition/inosculation	Cheek, lip, or tongue	Urethroplasty; ureteroplasty
Fascia lata	Graft	Imbibition/inosculation	Medial thigh	Sacrocolpopexy; sacrohysteropexy

VRAM, ventral rectus abdominis musculocutaneous.

kidneys out of the body. Robotic surgery is uniquely suited for urologic reconstruction owing to the familiarity of many urologists with robotic surgery and the ability of the robot to reach structures within the pelvis (1). Additionally, it has been increasingly established that various flaps and grafts used in urologic reconstruction can be harvested and utilized via a robotic approach (2-4). In selecting graft or flaps, it is important to consider desired tissue properties as well as anatomic location of both donor and recipient site (Table 2). Assessing health of flaps is tantamount to reconstructive success and the robotic approach has the advantage of allowing indocyanine green to be employed to evaluate flap perfusion (5).

Obliterating dead space/interposition

Omental flaps

The omentum is a hammock of fat, connective tissue, and lymphatics that is attached at the greater curvature of the stomach and the transverse colon. Omental harvest is performed by dissecting it off the transverse colon and then rotating this flap to the desired location, such as the

pelvis. The omental flap is dependent on the right and left gastroepiploic artery.

Surgical approach

Following preparation of the desired location of the omental flap, the omentum can often be stretched or pulled and sutured in place with minimal dissection of the omentum itself (Figure 1). It is important, however that the omentum is able to reach without tension to facilitate adequate repair. In some individuals, the omentum is easily able to reach the pelvis with minimal dissection. If it is unable to reach the desired location, it can safely be divided along either the right or left gastroepiploic artery and will be perfused by its remaining attachment. This maneuver allows for a great length of well-vascularized tissue. This tissue can then be fixed into its desired location with suture.

Common uses and advantages

Advantages of this flap include that it is large and well-vascularized even following the division of one arm of its blood supply. It can be used to occupy space, such as allowing for exclusion of the small bowel from the pelvis or filling an intrabdominal defect.

Omental flaps are excellent for wrapping the ureter

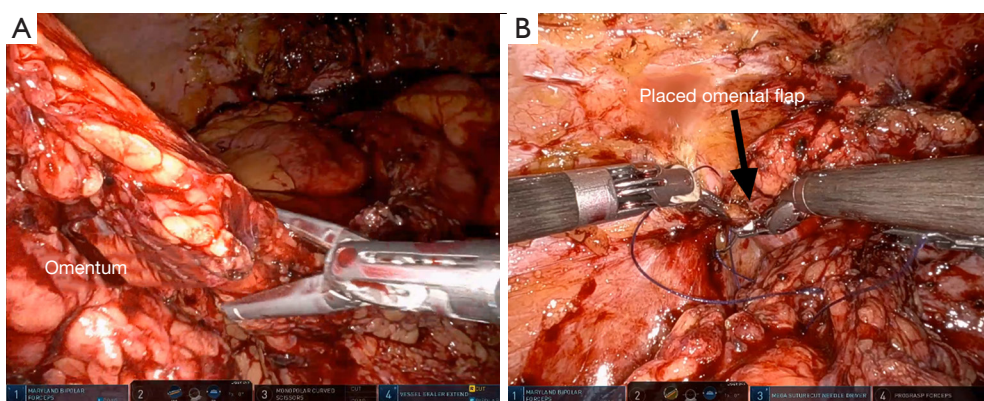


Figure 1 Omental flap for repair of a vesicovaginal fistula. (A) The omentum in this case was easily able to reach the pelvis; (B) image of omentum after securing in place into the pelvis. Courtesy of Divya Ajay.

after ureteral reconstruction or ureterolysis, which may disrupt the ureteral blood supply (6). A well-vascularized omentum can supply needed nutrients to support ureteral health following ureteral surgery (6). An omental wrap can also be used to augment grafting for ureteral strictures, providing additional blood supply and support (7). This strategy can work for native tissue or for grafts, for example in wrapping a buccal graft ureteroplasty (8,9). Additionally, omental flaps, which can reach the pelvis, can be used as an interposing flap to cover defects or injuries when performing reconstructive surgery on the pelvic organs. One such use is when the rectum is injured during a prostatectomy, during which omental coverage of a primary rectal closure can provide extra tissue to prevent breakdown of the rectal repair and subsequent fistula formation (10,11). Additionally, repair of fistulae, such as rectovesical, rectourethral, and vesicovaginal fistula, can be successfully augmented with omental flaps (1,12-15).

Disadvantages and complications

Port placement allowing for access to the omental blood supply as well as the desired landing area must be carefully planned prior to employment of omental flaps during robotic surgery. The omentum can shrink substantially in the setting of abdominal radiation or malnutrition, leading to small size or low flap quality. Thus, when planning to use this flap when either of these conditions are present, it is important to have a backup plan. Additionally, when patients have had extensive prior abdominal surgeries, the omentum is unlikely to be of adequate quality to be used (16). Use of omentum can be complicated by delayed return of bowel function, ileus, small bowel obstruction (SBO), and bowel injury during mobilization. Fortunately, the

improved visualization with the robot aids in recognition and management of bowel injuries during such cases.

Peritoneal flaps

The peritoneum is the tissue overlying the abdominal wall and visceral organs, which can be easily mobilized to cover other structures in the abdomen. The visceral peritoneum is supplied by the superior and inferior mesenteric arteries. Use of a peritoneal flap for robotic-assisted laparoscopic vesicovaginal fistula repair was first reported in 2005 by Melamud *et al.* (17). Since then it has been used extensively in robotic reconstruction.

Surgical approach

To harvest the graft robotically, the peritoneal tissue is incised at the desired location using electrocautery. It is then sharply and bluntly dissected from the extraperitoneal fat. Once mobilized from the fatty tissue, it can be rotated into the pelvis for an additional layer of closure.

Uses and advantages

Peritoneal flaps can be used for management of fistulae, including vesicovaginal fistulas and prostatosymphiseal fistulas (16-18). Additionally, the peritoneum is conveniently located to serve as a flap when rectal injuries occur in the course of the posterior dissection of a prostatectomy, which may reduce the risk of subsequent fistula formation (11). Gender affirming feminizing genitoplasty also frequently utilizes peritoneal flaps in the creation of the apex of the neovagina (19). Use of peritoneum in this setting enhances vaginal length (20). Recently, there has been significant interest in the use of peritoneal flaps during robotic prostatectomy to prevent lymphoceles. Multiple randomized clinical trials have been conducted to demonstrate reduction

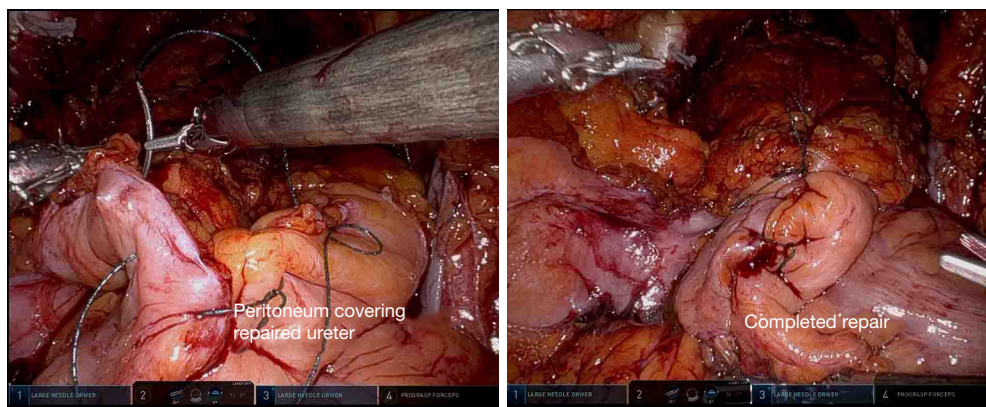


Figure 2 Peritoneal fixation following ureteral reimplantation. (A) Suturing of peritoneal flaps over the repaired ureter; (B) completed repair. Courtesy of Guan Wu.

in lymphoceles following employment of this simple technique (21-23) (*Figure 2*).

Disadvantages and complications

Peritoneal flaps are associated with few complications even in the setting of complex surgeries (18,20). However, one study did report a fistula between the urethra and the neovagina following feminizing genitoplasty, without clearly implicating the peritoneal flap harvest as a contributing factor (24). Peritoneal flaps following prostatectomy do not completely eliminate lymphocele risk, so it is important to remain vigilant for symptomatic lymphoceles even with employment of this technique (25). Additionally, the peritoneum can be affected by the disease process that caused the need for reconstruction, such as radiation damage, which can cause it to be unhealthy and unusable.

Vascular rectus abdominis musculocutaneous (VRAM) flaps

The rectus abdominis attaches at the 5th–7th costal cartilage and the pubic symphysis, and is enclosed by the rectus sheath. This muscle is supplied by the deep inferior epigastric artery and vein, from the external iliac vessels, which enter the muscle laterally (4).

Surgical approach

VRAM flaps are easily harvested robotically via three trocars placed on the contralateral side of the abdomen (4) (*Figure 3A*). The flap can be mobilized robotically by incising the anterior peritoneum vertically to the costal margin cranially and the arcuate line caudally (*Figure 3B*). The rectus muscle is then sharply and bluntly dissected off the anterior rectus sheath. The superior epigastric

artery is ligated and the muscle is transected, allowing the cranial aspect of the flap to be rotated into the pelvis for reconstruction (*Figure 3C*) (4). The flap can then be transposed into the desired location (*Figure 3D*).

Uses and advantages

These flaps are large and have a robust blood supply, making them an excellent space occupying flap (4). VRAM flaps are commonly employed in urologic oncology for reconstruction following pelvic exenteration or for coverage of groin wounds following removal of inguinal lymph nodes (26–28). It is easily rotated from its donor site into the inguinal region to cover large defects (27). VRAM flaps also provide excellent coverage for fistulas, especially in the setting of an inability to use omental flaps due to atrophic or radiated omentum (29).

Disadvantages and complications

To employ a VRAM flap via a robotic approach, surgeons must be familiar with both the flap and robotic surgery. Thus, adoption of this flap may be reduced by a lack of robotically trained plastic surgeons or urologic surgeons familiar with the harvest of VRAM flaps. Furthermore, the trocar positioning that is optimal for VRAM flap harvest is different than that of most pelvic surgeries, and thus may require extra port placement for this portion of a case or suboptimal port placement for both parts of the procedure (4). Use of a VRAM flap can result in a defect/bulge at the donor site as the rectus abdominis muscle provides significant support for the abdominal wall (30). This complication is especially common in individuals with larger abdominal girth or history of prior abdominal surgery. Mesh can be placed into the abdominal wall at the time of flap harvest to reduce the risk of this complication (30). Other donor

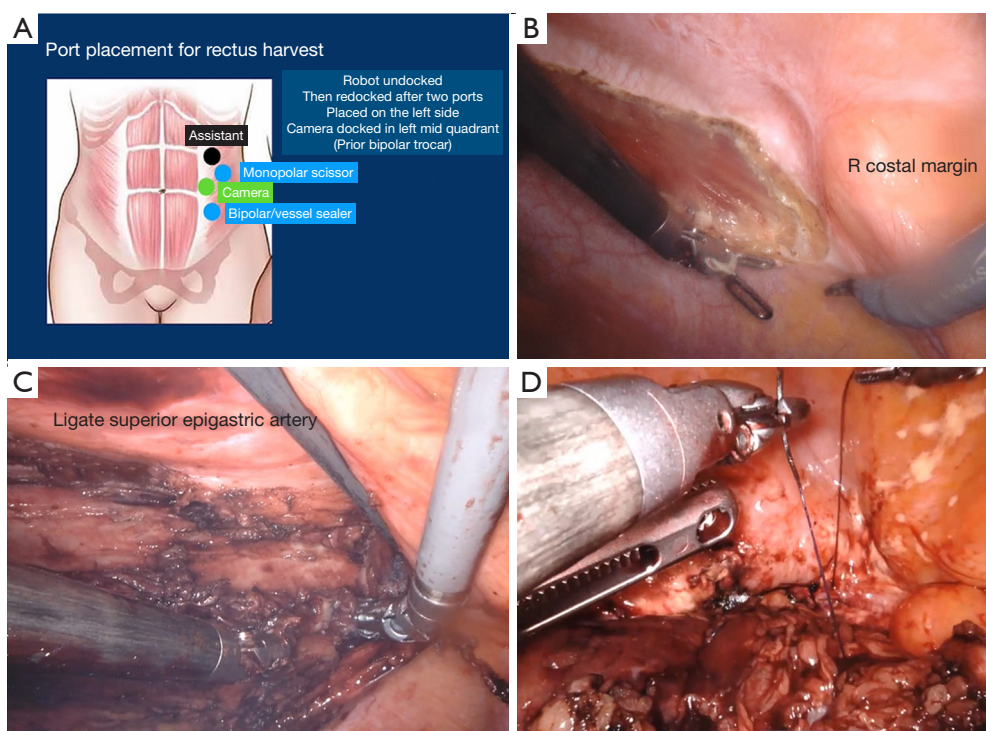


Figure 3 VRAM Flap formation. (A) Port placement for VRAM flaps; (B) opening the posterior sheath from the right costal margin (cranially) to the arcuate line (caudally); (C) dissection of the muscle off the anterior rectus sheath and ligation of the superior epigastric artery; (D) placement of the VRAM flap. Courtesy of Divya Ajay. VRAM, vascular rectus abdominis musculocutaneous.

site complications include dehiscence and infections (28). Finally, while devitalization and failure of this flap is uncommon, it does occur, which may result in failure of a reconstructive surgery and need for additional procedures to further restore structure and function (28).

Sigmoid epiploica

The colon is studded with pedunculated fat or epiploica, which can both occupy space and provide support for structures in reconstructive urology (31).

Surgical approach

To use this flap, the sigmoid colon is mobilized and relocated near the desired recipient site and sutured in place (1,16) (Figure 4). The epiploic fat remains attached to the colon, allowing for a rich nutrient supply.

Uses and advantages

Multiple groups have described using sigmoid epiploic fat as an interposition flap in to facilitate repair of vesicovaginal fistulae (1,16,31). The sigmoid colon is already within the pelvis, making this flap a convenient interposition flap for fistula repair without extensive mobilization (16). The sigmoid colon is suitable for repair of fistulae to the bladder,

even down to the level of the trigone (31). Use of this tissue is well tolerated and associated with few complications (16,31).

Disadvantages and complications

The epiploic appendix can experience ischemia or torsion if care is not taken to place the epiploic fat in its anatomic position (31). Additionally, the requirement for bowel mobilization can result in large bowel obstruction or injury, which can require additional procedures to manage or extend the length of hospital stay.

Gracilis flaps

The gracilis muscle is found in the medial thigh and can be relocated as a flap without causing significant deficits in most patients. They can be harvested from the leg and then passed through into the pelvis for use in robotic reconstruction. The gracilis muscle is supplied by the medial femoral circumflex system.

Surgical approach

In some instances, its mobilization will be done by plastic surgeons working alongside the urologist. Mobilization begins with identification of the adductor longus; approximately 2–3 cm below this the surgeon identifies

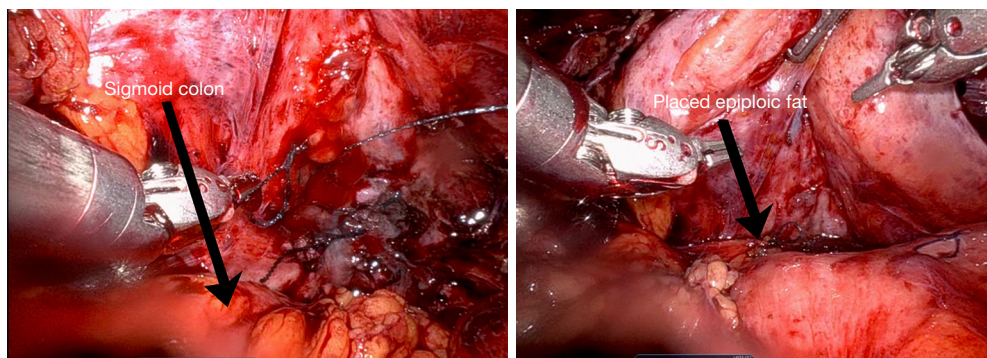


Figure 4 Use of sigmoid epiploic fat in a vesicovaginal fistula repair. (A) The initial positioning of the fat over the area of the vesicovaginal fistula; (B) completed fixation. Courtesy of Hani Rashid.

the gracilis muscle. A longitudinal incision on the medial thigh is made with care to protect the greater saphenous vein. The gracilis is dissected from the adductor longus, protecting the pedicle. The muscle is released distally from the tendon after measuring the desired length, and then can be rotated proximally into the perineum for use (32-37).

Uses and advantages

Gracilis flaps are used for perineal and pelvic reconstruction owing to the proximity of the donor site to the pelvis and the high-quality, well vascularized flap that results (28,32). Gracilis flaps can be used as an interposition flap during repair of pelvic fistulas, such as complex vesicovaginal fistulas and post-prostatectomy rectourethral fistulas (33-35). Gracilis is extensively used to reconstruct defects following pelvic exenteration procedures for urinary tract and bowel cancers (28). Gracilis flaps are also used to provide blood supply in the setting of complex urethroplasties to prevent necrosis at the bulbar segment, although to our knowledge this has not been performed via a robotic approach (36). The use of the gracilis muscle has been described for gender affirming masculinizing surgery (32,37). During this procedure, a vaginectomy is performed with use of vaginal mucosa and labial tissue to form the pars fixa (37). The pars fixa has a high stricture rate owing to the risk for ischemia of this tissue following mobilization (37). The gracilis muscle can serve as support and is a well vascularized flap, which provide much needed blood supply to this area (32,37). Gracilis muscle harvest takes approximately 20 minutes and thus does not add significant duration to a surgery (37). Additionally, when the vaginectomy is being performed robotically, the gracilis flap harvest can be performed simultaneously, which is an advantage of the robotic employment of this flap (32). This

procedure is well-tolerated and all patients were able to ambulate in one series on post-operative day 1 (37).

Disadvantages and complications

In one series of subjects undergoing robotic masculinizing surgery with gracilis flaps, one subject developed a seroma and one developed an infection (37). Other donor site complications include wound dehiscence (28). Gracilis flaps, like any flaps, can fail, which may require additional reconstructive surgeries for management (28). Gracilis flap harvest is associated with a mild deficit in hamstring strength, which improves with time (38). Thus, use of this flap is generally well-tolerated.

Alloderm™

Alloderm™ is a commercially available extracellular matrix depleted of cells which can be implanted as a space occupying material. It is available in various sizes and thicknesses. Following implantation, the matrix is then populated by ingrowth of cells from the surrounding tissue.

Surgical approach

After selecting the Alloderm™ graft that is most suitable for the desired tissue location, the Alloderm™ graft is soaked in sterile normal saline for approximately 2 minutes. It can then be placed in the desired location and stitched into place with absorbable sutures (*Figure 5*).

Uses and advantages

Alloderm™ has been successfully used to repair a rectourethral fistula via a transrectal approach (39). Alloderm™ has also been used during revision vaginoplasty for gender affirmation with a high degree of success (40). Because Alloderm™ is an exogenous product, it has the advantage of avoiding the morbidity of graft or flap harvest. There is also an ongoing clinical trial concerning the use of

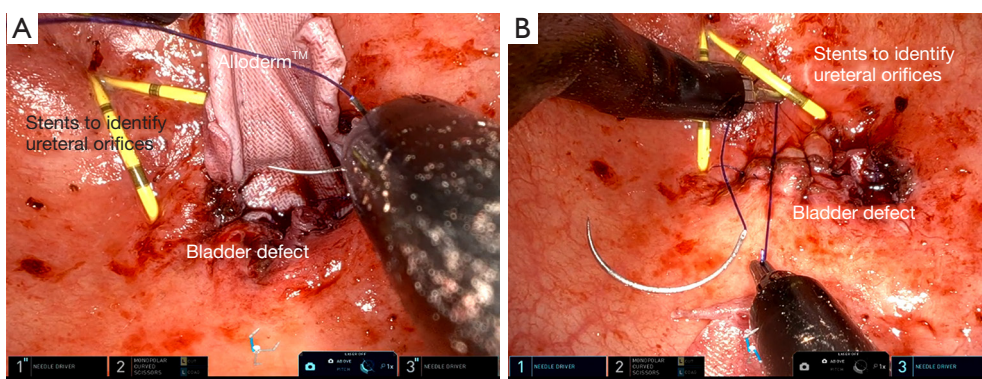


Figure 5 Use of Alloderm™ in repair of colovesical fistula. (A) Placement of Alloderm™; (B) completed repair.

Alloderm™ to close the donor site following buccal graft harvest (41).

Disadvantages and complications

Complications with Alloderm™ are fairly uncommon. One study noted that 2/9 subjects undergoing vaginoplasty with alloderm had an area of excess Alloderm™ that failed to epithelialize (40). Because it is not a flap and does not have a blood supply it may fail, and does not provide any nutritional support to surrounding tissues following placement. Other complications observed in this study were likely not attributable to the use of Alloderm™. Thus, its use is fairly well-tolerated.

Ureteral substitution

Boari flaps

A Boari flap is a tubularized strip of bladder tissue mobilized from the superior bladder (42,43). Boari flaps can be quite long and are able to bridge substantial gaps (8–15 cm) in the urinary system (43,44). They are dependent on the blood supply of the bladder and, in harvesting these flaps, it is important to maintain a broad base to facilitate good blood supply to the entire segment (42,45).

Surgical approach

The ureteral remnant is spatulated to facilitate a patent repair. A full thickness flap of a desired length is raised from the anterior bladder wall with an ideal length to width ratio of 2:1–5:1 (46). This is then sutured to the spatulated ureter and this is tunneled submucosally into the bladder and sutured in place. The flap is then tubularized, often with placement of a double-J stent, and the bladder opening is closed in 2 layers.

Uses and advantages

Boari flaps are especially useful for ureteral reconstruction

with a long defect because they can cover an extended distance to form a tension free anastomosis between the remaining ureter and the bladder (42). Such situations include long distal ureteral strictures, iatrogenic ureteral injuries or avulsions, and resection of distal ureteral segments for management of tumors (42,44,45,47). One group demonstrated the harvest of a long Boari flap to perform a calycovesicostomy for a refractory ureteropelvic junction obstruction (48). Thus, this flap is able to create a long, tubularized segment with a high degree of success for bridging gaps between the ureter and the bladder (43). Additionally, if a Boari flap results in insufficient length, it can be augmented with other procedures such as mobilization of the kidney or the use of grafts (49).

Disadvantages and complications

The use of a Boari flap can be complicated by urine leak, which may require drainage (43). Other structures can be injured during dissection of the flap and, in one study, a rectovesical fistula was noted following Boari flap creation in 1 patient of a cohort of 721, indicating that this is a rare scenario (43). Additionally, if the proximal portion of the flap is too narrow, the segment can become ischemic, resulting in stricture formation (42). Cystoscopy should be performed prior to the utilization of a Boari flap in the setting of urothelial cancer to verify that no bladder tumors are present. Additionally, prior to use of a Boari flap, it is important to evaluate the baseline bladder capacity and function with either uroflowmetry or formal urodynamics studies to confirm that an individual will tolerate the removal of a portion of their bladder.

Oral mucosa grafts

The oral mucosa, including the buccal, lingual, and labial tissues, is highly amenable to grafting in the urinary tract.

Surgical approach

Prior to harvest of an oral mucosal graft, surgeons must communicate with the anesthesiology team to ensure positioning of the endotracheal tube does not interfere with graft procurement. Oral graft harvest begins with measurement of the recipient site and marking out an appropriate area of the donor site to ensure adequate graft length and width, with the knowledge that grafts shrink 8–10% following harvest (50). Injection of lidocaine with epinephrine along the submucosal plane is used to hydrodissect and reduce bleeding. The graft is then cut along its outline with sharp dissection, removed from its underlying attachments, defatted, and then placed in the desired location. When harvesting a buccal mucosal graft, it is important to avoid Stensen's duct to prevent problems with salivary secretions (50).

Uses and advantages

The tissue quality of oral mucosa makes it especially useful in replacement of urinary tissues. It is well-vascularized with a dense plexus of vessels and the mucosa is non-keratinized and self-lubricating (8). Buccal mucosa has been described as suitable robotic ureteral replacement tissue by multiple groups via multiple different approaches (8,51,52). Robotic ureteroplasty has also been performed successfully with lingual mucosa (7,49). Additionally, buccal ureteroplasty with the single port robot has been described (53). Oral tissue can be used to augment the ureter anywhere along its length, including at the ureteropelvic junction (9,54,55). One study demonstrated pyeloplasty with buccal grafting improved diuretic renography findings in 2 subjects, indicating the success of this procedure (54). The use of oral mucosa for ureteral reconstruction is suitable for both pediatric and adult patients (8,9). Compared to an open approach for ureteral reconstruction with oral mucosal grafting, the robotic approach has the advantages of improved visualization for delicate placement and suturing of the graft (51). Oral tissue has also been successfully used in ureteral reconstruction even in the setting of revisions (8,9). Bladder neck contracture, which is a known complication of prostatic surgery, has been successfully managed with buccal grafting via a robotic approach without recurrence or complication (56).

Disadvantages and complications

Longer strictures are associated with an increased rate of failure of buccal ureteroplasty (52). At a median 2-year follow up, one small study demonstrated an approximately 10% failure rate of buccal ureteroplasty with both failures occurring in the subjects with a history of prior ureteral

surgery (8). Additionally, the revision setting was associated with both increased blood loss and longer operative time in one study of robotic pyeloplasty with oral mucosa (55). In one series of buccal ureteroplasty cases, the complication rate was approximately 20%; however, none of the complications were clearly related to the buccal graft or ureteroplasty portions of the surgery (8). The oral mucosal donor site can be a source of irritation for the patient during healing, and the use of lingual mucosa can be associated with tongue numbness during the recovery period (7,49).

Rectal mucosa

There has been recent interest in the harvest of rectal mucosa for repair of urologic structures or management of fistulas to the urinary tract (39). These can be harvested via the robotic transanal minimally invasive surgery (R-TAMIS) approach (39).

Surgical approach

Harvest can be performed both via a multi-port robot with a transanal access port or a single port robot (3,57,58). The robot is docked transanally with the patient in the dorsal lithotomy position. The pressure is set between 12–15 mm of mercury to ensure adequate working space without collapse (3). The desired area of flap placement is measured to determine the flap length and injection of lidocaine with epinephrine is used to hydrodissect the flap and reduce bleeding. The flap is elevated, removed, and translocated to its desired site of placement. The defect is left to heal by second intention.

Uses and advantages

Rectal mucosa has been used to close rectourethral and rectovesical fistulas by numerous surgeons, with a high degree of success (39,59,60). Rectal mucosa can also be harvested in a similar manner to oral mucosa and used as a graft for replacement of other structures for substitution urethroplasties or complex vaginal reconstruction (3,57,58). One advantage of rectal mucosa over buccal mucosa is that the graft that can be harvested can be quite large, allowing for management of very long strictures (3,57).

Disadvantages and complications

This procedure is well-tolerated with minimal morbidity (57). Given the involvement of bowel work and the need for insufflation of the rectum, there is a potential for rectal injury; however, with the use of a rectal access port, careful dissection, and pressures of 12–15 mm of mercury, the risk of rectal injury is low (39,57,61).

Ileum

Following separation of a segment of the ileum and the

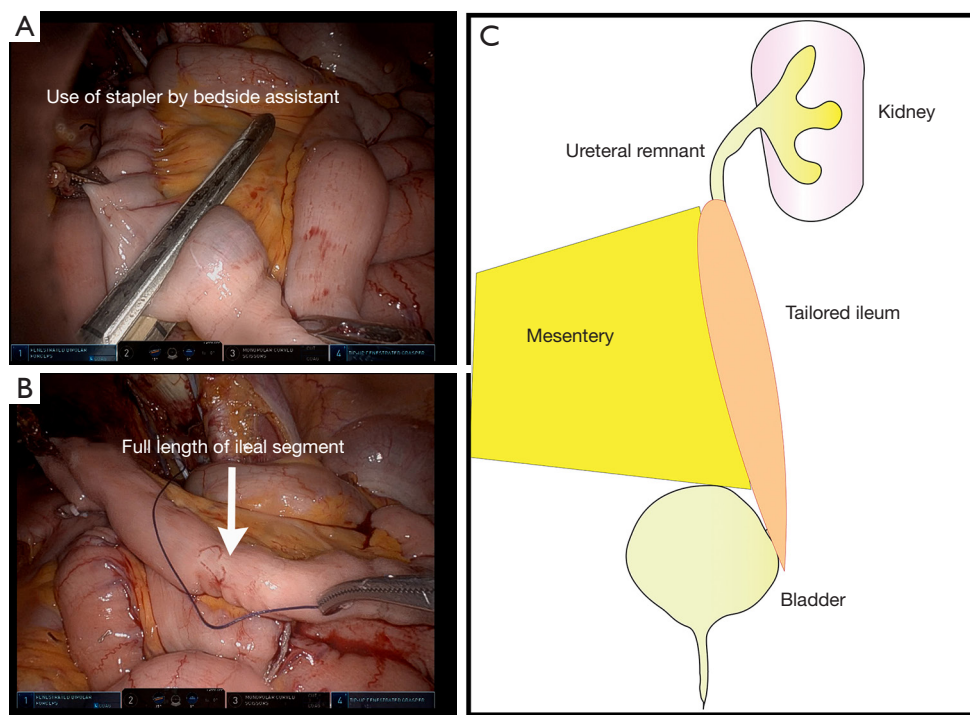


Figure 6 Formation of an ileal flap. (A) A handheld stapler is used by the assistant to divide a 15 cm ileal conduit approximately 15 cm from the ileocecal junction and separate it from the remaining bowel, which will then be reanastomosed; (B) isolated ileal segment; (C) the ileal flap can then be fashioned into a ureter. Courtesy of Hani Rashid.

bowel reanastomosis, with its blood supply intact, can be relocated to the desired portion of the ureter, tailored, tubularized and used as graft to the ureter (*Figure 6*) (62).

Surgical approach

A segment of ileum the desired length to cover the defect is measured and taken approximately 15 centimeters from the ileocecal junction. Care must be taken not to disrupt the ileocecal valve, which plays a role in preventing bacterial overgrowth and reducing malabsorption (63). It can then be divided on its antimesenteric side and tailored to a segment of suitable width.

Uses and advantages

The ileum is amenable to ureteral reconstruction, including as a ureteral replacement or as an inlay or onlay flap into the ureter. The robotic approach is very suitable to an intracorporeal formation of an ileal ureteral replacement (62,64,65). In one series, of 36 subjects, 3 of whom underwent a robotic ileal ureter reconstruction, 83% remained patent after 4-year follow-up (64).

Disadvantages and complications

One series, which included both robotic and open ileal ureteral replacements, demonstrated a 23.9% complication

rate, including wound infections, urine leak, recurrent ureteral obstruction, and abdominal bowel related complications such as ileus (64).

Appendiceal interposition flaps

The appendix can be removed without significant consequences to a patient and can serve as an excellent flap. The appendiceal artery serves as its blood supply.

Surgical approach

The appendix is identified and divided from its attachment to the cecum with care taken to leave its blood supply intact. This can then be interposed between a spatulated end of the ureter and the bladder. It can also be divided on its anti-mesenteric border and be inlaid into a ureter that is incompletely disrupted.

Uses and advantages

The appendix is a tubular structure meaning that it is very suitable for providing a flap for reconstruction of a tubular structure such as a ureter (66-69). The appendix also has a rich blood supply from the appendiceal artery, which helps maintain its vitality. Additionally, it is a well-described clinical principle that grafts and flaps should

not be fully tubularized at their time of placement due to the risk of stenosis; however, a structure that is already tubular avoids this risk (67,70). The appendix can also be de-tubularized and inlaid or onlaid into a ureter that is not completely disrupted (2,68). The appendix has been utilized in the performance of robotic pyeloplasty to add additional tissue to the stenotic segment (71). The appendix can more readily be used to replace the distal right ureter than other structures due to the proximity of the right distal ureter to the native location of the appendix (67). When a ureteral stricture is radiation-induced, the appendix may have been excluded from the field of radiation, allowing for replacement of the ureter with tissue that is non-irradiated and thus healthier (72). While many urologic surgeons would place a stent to maintain patency following robotic ureteral reconstruction with the appendix, recent reports of stentless appendiceal ureteroplasty have also yielded promising results (66,67,73).

Disadvantages and complications

The size of the appendix varies greatly, and a short appendix can limit the length of ureter which can be replaced during an appendiceal ureteroplasty (66). Appendiceal flaps may stenose leading to recurrent ureteral obstruction and thus should be monitored for symptoms and via ultrasounds (68). Additionally, despite ureteral replacement, some patients will not have improvement of their kidney function, so careful patient evaluation and selection to avoid the morbidity of a surgical intervention that will not work should be employed (69). Because of the use of a structure on the bowel, bowel injury or bowel obstruction can occur (69). The use of the appendix for replacement of the left ureter requires more extensive mobilization, which can be technically challenging (69). Finally, radiation that damages the ureter may also damage the appendix, so an alternative plan must be in place prior to approaching repair of radiation-induced ureteral strictures with the hope of using the appendix (72).

Mesh alternatives

Fascia lata grafts

Fascia lata is the deep fascia of the thigh, which can be harvested with minimal deficit. Use of this tissue can yield up to a 5 by 18 cm graft (74).

Surgical approach

To harvest fascia lata, a mark is made from the anterior iliac crest to the lateral knee to delineate the approximate location of the fascia. A small incision on the lateral knee

is made and the subcutaneous fat is separated from the fascia. A cut is then made through the fascia lata and the posterior aspect is separated bluntly from the underlying tissue. An incision at the proximal extent of the graft is then made. The fascia lata is then cut along its lateral aspects to the desired length, removed from its distal attachment and passed through the proximal incision where it is separated from its proximal attachment.

Uses and advantages

Fascia lata has been successfully used for robotic sacrocolpopexy to treat pelvic organ prolapse, and is an option for mesh-averse patients, although with poorer long term success rates than sacrocolpopexy with mesh (74-76). Fascia lata can also be utilized for sacrohysteropexy if retention of the uterus is desired (77). Autologous fascia for pelvic organ suspension is preferred over synthetic mesh slings if future pregnancy is desired (77). Another application of fascia lata is autologous fascial urethral slings for urethral suspension in the setting of stress incontinence (74).

Disadvantages and complications

The use of fascia lata can be associated with donor site complications, such as a thigh bulge, paresthesia, or seroma formation (74). However, this procedure is typically well-tolerated without significant gait deficits or complications (74,75,77).

Conclusions

A variety of flaps and grafts are available for robotic reconstruction of the genitourinary tract. Surgeons must be thoughtful about the desired tissue quality and anatomic considerations in flap and graft selections. Each graft or flap has advantages and disadvantages. Future research will aim to improve patient and situation selection for each type of reconstructive technique.

Acknowledgments

Funding: None.

Footnote

Provenance and Peer Review: This article was commissioned by the Guest Editor (Nitin Sharma) for the series "Laparoscopic Urology" published in *Annals of Laparoscopic and Endoscopic Surgery*. The article has undergone external peer review.

Reporting Checklist: The authors have completed the Narrative Review reporting checklist. Available at <https://ales.amegroups.com/article/view/10.21037/ales-23-36/rc>

Peer Review File: Available at <https://ales.amegroups.com/article/view/10.21037/ales-23-36/prf>

Conflicts of Interest: All authors have completed the ICMJE uniform disclosure form (available at <https://ales.amegroups.com/article/view/10.21037/ales-23-36/coif>). The series “Laparoscopic Urology” was commissioned by the editorial office without any funding or sponsorship. The authors have no other conflicts of interest to declare.

Ethical Statement: The authors are accountable for all aspects of the work in ensuring that questions related to the accuracy or integrity of any part of the work are appropriately investigated and resolved. Written informed consent for publication of this study was obtained from the patients.

Open Access Statement: This is an Open Access article distributed in accordance with the Creative Commons Attribution-NonCommercial-NoDerivs 4.0 International License (CC BY-NC-ND 4.0), which permits the non-commercial replication and distribution of the article with the strict proviso that no changes or edits are made and the original work is properly cited (including links to both the formal publication through the relevant DOI and the license). See: <https://creativecommons.org/licenses/by-nc-nd/4.0/>.

References

- Antonelli A, Veccia A, Morena T, et al. Robot-assisted vesico-vaginal fistula repair: technical nuances. *Int Braz J Urol* 2021;47:684-5.
- Gabrielson A, Li O, Cohen AJ. Robotic-Assisted Augmented Roof Ureteroplasty With Appendiceal Onlay Flap. *Urology* 2023;176:243-5.
- Howard KN, Zhao LC, Weinberg AC, et al. A novel surgery: robotic transanal rectal mucosal harvest. *Tech Coloproctol* 2019;23:691.
- Pedersen J, Song DH, Selber JC. Robotic, intraperitoneal harvest of the rectus abdominis muscle. *Plast Reconstr Surg* 2014;134:1057-63.
- Lee Z, Moore B, Giusto L, et al. Use of indocyanine green during robot-assisted ureteral reconstructions. *Eur Urol* 2015;67:291-8.
- Neulander EZ, Rivera I, Kaneti J, et al. Ureterolysis with ureterotomy and omental sleeve wrap in patients with radiation induced pelvic retroperitoneal fibrosis. *Cent European J Urol* 2019;72:307-11.
- Wang J, Zhang B, Fan J, et al. The application of the "omental wrapping" technique with autologous onlay flap/graft ureteroplasty for the management of long ureteral strictures. *Transl Androl Urol* 2021;10:2871-8.
- Zhao LC, Weinberg AC, Lee Z, et al. Robotic Ureteral Reconstruction Using Buccal Mucosa Grafts: A Multi-institutional Experience. *Eur Urol* 2018;73:419-26.
- Ahn JJ, Shapiro ME, Ellison JS, et al. Pediatric Robot-assisted Redo Pyeloplasty With Buccal Mucosa Graft: A Novel Technique. *Urology* 2017;101:56-9.
- Yee DS, Ornstein DK. Repair of rectal injury during robotic-assisted laparoscopic prostatectomy. *Urology* 2008;72:428-31.
- Roberts WB, Tseng K, Walsh PC, et al. Critical appraisal of management of rectal injury during radical prostatectomy. *Urology* 2010;76:1088-91.
- Sotelo R, de Andrade R, Carmona O, et al. Robotic repair of rectovesical fistula resulting from open radical prostatectomy. *Urology* 2008;72:1344-6.
- Medina LG, Cacciamani GE, Hernandez A, et al. Robotic Management of Rectourethral Fistulas After Focal Treatment for Prostate Cancer. *Urology* 2018;118:241.
- Sayegh AS, La Riva A, Perez LC, et al. Robotic Simultaneous Repair of Rectovesical Fistula With Vesicourethral Anastomotic Stricture after Radical Prostatectomy: Step-by-Step Technique and Outcomes. *Urology* 2023;175:107-13.
- Bragayrac LA, Azhar RA, Fernandez G, et al. Robotic repair of vesicovaginal fistulae with the transperitoneal-transvaginal approach: a case series. *Int Braz J Urol* 2014;40:810-5.
- Agrawal V, Kucherov V, Bendana E, et al. Robot-assisted Laparoscopic Repair of Vesicovaginal Fistula: A Single-center Experience. *Urology* 2015;86:276-81.
- Melamud O, Eichel L, Turbow B, et al. Laparoscopic vesicovaginal fistula repair with robotic reconstruction. *Urology* 2005;65:163-6.
- Lundy SD, Hauser N, Wood H, et al. Management of prostatosymphyseal fistula following photoselective vaporization of the prostate: Case series and systematic review of the literature. *Curr Urol* 2022;16:88-93.
- Jun MS, Gonzalez E, Zhao LC, et al. Penile Inversion Vaginoplasty with Robotically Assisted Peritoneal Flaps. *Plast Reconstr Surg* 2021;148:439-42.

20. Jacoby A, Maliha S, Granieri MA, et al. Robotic Davydov Peritoneal Flap Vaginoplasty for Augmentation of Vaginal Depth in Feminizing Vaginoplasty. *J Urol* 2019;201:1171-6.
21. Student V Jr, Tudos Z, Studentova Z, et al. Effect of Peritoneal Fixation (PerFix) on Lymphocele Formation in Robot-assisted Radical Prostatectomy with Pelvic Lymphadenectomy: Results of a Randomized Prospective Trial. *Eur Urol* 2023;83:154-62.
22. Wagner J, McLaughlin T, Pinto K, et al. The Effect of a Peritoneal Iliac Flap on Lymphocele Formation After Robotic Radical Prostatectomy: Results From the PLUS Trial. *Urology* 2023;173:104-10.
23. Gloger S, Ubrig B, Boy A, et al. Bilateral Peritoneal Flaps Reduce Incidence and Complications of Lymphoceles after Robotic Radical Prostatectomy with Pelvic Lymph Node Dissection-Results of the Prospective Randomized Multicenter Trial ProLy. *J Urol* 2022;208:333-40.
24. Salibian AA, Schechter LS, Kuzon WM, et al. Vaginal Canal Reconstruction in Penile Inversion Vaginoplasty with Flaps, Peritoneum, or Skin Grafts: Where Is the Evidence? *Plast Reconstr Surg* 2021;147:634e-43e.
25. Deutsch S, Hadaschik B, Lebentrau S, et al. Clinical Importance of a Peritoneal Interposition Flap to Prevent Symptomatic Lymphoceles after Robot-Assisted Radical Prostatectomy and Pelvic Lymph Node Dissection: A Systematic Review and Meta-Analysis. *Urol Int* 2022;106:28-34.
26. Chokshi RJ, Kuhrt MP, Arrese D, et al. Reconstruction of total pelvic exenteration defects with rectus abdominus myocutaneous flaps versus primary closure. *Am J Surg* 2013;205:64-70.
27. Alnajjar HM, MacAskill F, Christodoulidou M, et al. Long-term outcomes for penile cancer patients presenting with advanced N3 disease requiring a myocutaneous flap reconstruction or primary closure-a retrospective single centre study. *Transl Androl Urol* 2019;8:S13-21.
28. Esemé EA, Scampa M, Viscardi JA, et al. Surgical Outcomes of VRAM vs. Gracilis Flaps in Vulvo-Perineal Reconstruction Following Oncologic Resection: A Proportional Meta-Analysis. *Cancers (Basel)* 2022;14:4300.
29. Tasmemir N, Abali R, Celik C, et al. The use of an anterior abdominal wall peritoneal flap in the laparoscopic repair of vesicouterine fistula. *Int Surg* 2014;99:673-6.
30. Davila AA, Goldman J, Kleban S, et al. Reducing Complications and Expanding Use of Robotic Rectus Abdominis Muscle Harvest for Pelvic Reconstruction. *Plast Reconstr Surg* 2022;150:190-5.
31. Sanderson DJ, Rutkowski J, Attuwaybi B, et al. Robotic Repair of Supratrigonal Vesicovaginal Fistula with Sigmoid Epiploica Interposition. *JLS* 2018;22:e2018.00055.
32. Jun MS, Shakir NA, Blasdel G, et al. Robotic-assisted Vaginectomy During Staged Gender-affirming Penile Reconstruction Surgery: Technique and Outcomes. *Urology* 2021;152:74-8.
33. Takeda T, Shonaka T, Tani C, et al. Gracilis muscle flap combined with a laparoscopic transabdominal approach is effective in the treatment of post-prostatectomy rectourethral fistula: A case report. *Int J Surg Case Rep* 2022;92:106856.
34. Zmora O, Potenti FM, Wexner SD, et al. Gracilis muscle transposition for iatrogenic rectourethral fistula. *Ann Surg* 2003;237:483-7.
35. Roth T, Rodney MG, Blythe J, et al. Suprapubic approach for repair of a massive vesicovaginal fistula utilizing a myocutaneous gracilis muscle flap. *Journal of Pelvic Medicine and Surgery* 2003;9:19-22.
36. Rozanski AT, Vanni AJ. Ventral Buccal Mucosa Graft Urethroplasty with Gracilis Muscle Flap for High Risk, Long Segment Urethral Strictures: A 20-Year Experience. *Urology* 2020;140:178-80.
37. Cohen O, Stranix JT, Zhao L, et al. Use of a Split Pedicled Gracilis Muscle Flap in Robotically Assisted Vaginectomy and Urethral Lengthening for Phalloplasty: A Novel Technique for Female-to-Male Genital Reconstruction. *Plast Reconstr Surg* 2020;145:1512-5.
38. Burks RT, Crim J, Fink BP, et al. The effects of semitendinosus and gracilis harvest in anterior cruciate ligament reconstruction. *Arthroscopy* 2005;21:1177-85.
39. Hebert KJ, Naik N, Allawi A, et al. Rectourethral Fistula Repair Using Robotic Transanal Minimally Invasive Surgery (TAMIS) Approach. *Urology* 2021;154:338.
40. Parker A, Brydges H, Blasdel G, et al. Mending the Gap: AlloDerm as a Safe and Effective Option for Vaginal Canal Lining in Revision Robotic Assisted Gender Affirming Peritoneal Flap Vaginoplasty. *Urology* 2023;173:204-8.
41. clinicaltrials.gov: Buccal Mucosa Healing Trial With Tissue Matrix Placement. Washington DC: National Institutes of Health; c2019 [cited 2023 Sept 24]. NCT02768467.
42. Sagalovich D, Garisto J, Bertolo R, et al. Minimally Invasive Management of Ureteral Distal Strictures: Robotic Ureteroneocystostomy With a Bilateral Boari Flap. *Urology* 2018;120:268.
43. Corse TD, Dayan L, Cheng N, et al. A Multi-Institutional Experience Utilizing Boari Flap in Robotic Urinary

- Reconstruction. *J Endourol* 2023;37:775-80.
44. Ficarra V, Rossanese M, Crestani A, et al. A Contemporary Case Series of Complex Surgical Repair of Surgical/ Endoscopic Injuries to the Abdominal Ureter. *Eur Urol Focus* 2021;7:1476-84.
 45. Allaparthi S, Ramanathan R, Balaji KC. Robotic distal ureterectomy with boari flap reconstruction for distal ureteral urothelial cancers: a single institutional pilot experience. *J Laparoendosc Adv Surg Tech A* 2010;20:165-71.
 46. Bansal A, Sinha RJ, Jhanwar A, et al. Laparoscopic ureteral reimplantation with Boari flap for the management of long- segment ureteral defect: A case series with review of the literature. *Turk J Urol* 2017;43:313-8.
 47. Kumar S, Modi P, Mishra A, et al. Robot-assisted laparoscopic repair of injuries to bladder and ureter following gynecological surgery and obstetric injury: A single-center experience. *Urol Ann* 2021;13:405-11.
 48. Kumar S, Chandna A, Aggarwal D, et al. Robot-assisted boari flap calycovesicostomy for failed uretero-pelvic junction obstruction: a novel approach to a complex problem. *J Robot Surg* 2019;13:345-9.
 49. Li B, Zhou Y, Chai S, et al. Robotic lingual mucosal graft ureteroplasty combined with Boari flap ureteroneocystostomy for one-stage repair of complex ureteral strictures: initial experience. *Int Urol Nephrol* 2023;55:893-5.
 50. BhalaguruIyyan A, Murugan PP, Alakhananda CC, et al. Evaluation of the Extent of Primary Buccal Mucosal Graft Contracture in Augmentation Urethroplasty for Stricture Urethra: A Prospective Observational Study at a Tertiary Healthcare Centre. *Adv Urol* 2021;2021:9913452.
 51. Zhao LC, Yamaguchi Y, Bryk DJ, et al. Robot-Assisted Ureteral Reconstruction Using Buccal Mucosa. *Urology* 2015;86:634-8.
 52. Lee Z, Lee M, Koster H, et al. A Multi-Institutional Experience With Robotic Ureteroplasty With Buccal Mucosa Graft: An Updated Analysis of Intermediate-Term Outcomes. *Urology* 2021;147:306-10.
 53. Liu W, Shakir N, Zhao LC. Single-Port Robotic Posterior Urethroplasty Using Buccal Mucosa Grafts: Technique and Outcomes. *Urology* 2022;159:214-21.
 54. Zampini AM, Nelson R, Zhang JJH, et al. Robotic Salvage Pyeloplasty With Buccal Mucosal Onlay Graft: Video Demonstration of Technique and Outcomes. *Urology* 2017;110:253-6.
 55. Lee M, Lee Z, Strauss D, et al. Multi-institutional Experience Comparing Outcomes of Adult Patients Undergoing Secondary Versus Primary Robotic Pyeloplasty. *Urology* 2020;145:275-80.
 56. Avallone MA, Quach A, Warneke J, et al. Robotic-assisted Laparoscopic Subtrigonal Inlay of Buccal Mucosal Graft for Treatment of Refractory Bladder Neck Contracture. *Urology* 2019;130:209.
 57. Howard KN, Zhao LC, Weinberg AC, et al. Robotic transanal minimally invasive rectal mucosa harvest. *Surg Endosc* 2019;33:3478-83.
 58. Ozgur I, Justiniano CF, Wood HM, et al. Single-Port Endorobotic Rectal Mucosa Harvest For Urethral Reconstruction. *Dis Colon Rectum* 2023;66:e54-7.
 59. Tseng SI, Huang CW, Huang TY. Robotic-assisted transanal repair of rectourethral fistula. *Endoscopy* 2019;51:E96-7.
 60. Gan T, Naik ND, Hebert KJ, et al. Robotic Transanal Minimally Invasive Surgery: Rectourethral Fistula Closure. *Dis Colon Rectum* 2023;66:e120.
 61. Nicita G, Villari D, Caroassai Grisanti S, et al. Minimally Invasive Transanal Repair of Rectourethral Fistulas. *Eur Urol* 2017;71:133-8.
 62. Brandao LF, Autorino R, Zargar H, et al. Robotic ileal ureter: a completely intracorporeal technique. *Urology* 2014;83:951-4.
 63. Cosnes J, Gendre JP, Le Quintrec Y. Role of the ileocecal valve and site of intestinal resection in malabsorption after extensive small bowel resection. *Digestion* 1978;18:329-36.
 64. Launer BM, Redger KD, Koslov DS, et al. Long-term Follow Up of Ileal Ureteral Replacement for Complex Ureteral Strictures: Single Institution Study. *Urology* 2021;157:257-62.
 65. Sim A, Todenhöfer T, Mischinger J, et al. Intracorporeal ileal ureter replacement using laparoscopy and robotics. *Cent European J Urol* 2014;67:420-3.
 66. Gn M, Lee Z, Strauss D, et al. Robotic Appendiceal Interposition With Right Lower Pole Calycoctomy, Downward Nephropexy, and Psoas Hitch for the Management of an Iatrogenic Near-complete Ureteral Avulsion. *Urology* 2018;113:e9-e10.
 67. Yarlagadda VK, Nix JW, Benson DG, et al. Feasibility of Intracorporeal Robotic-Assisted Laparoscopic Appendiceal Interposition for Ureteral Stricture Disease: A Case Report. *Urology* 2017;109:201-5.
 68. Jun MS, Stair S, Xu A, et al. A Multi-Institutional Experience With Robotic Appendiceal Ureteroplasty. *Urology* 2020;145:287-91.
 69. Burns ZR, Sawyer KN, Selph JP. Appendiceal Interposition

- for Ureteral Stricture Disease: Technique and Surgical Outcomes. *Urology* 2020;146:248-52.
70. Wessells H, Angermeier KW, Elliott S, et al. Male Urethral Stricture: American Urological Association Guideline. *J Urol* 2017;197:182-90.
71. Cao H, Zhou H, Yang F, et al. Laparoscopic appendiceal interposition pyeloplasty for long ureteric strictures in children. *J Pediatr Urol* 2018;14:551.e1-5.
72. Lee M, Lee Z, Metro MJ, et al. Robotic Ureteral Bypass Surgery with Appendiceal Graft for Management of Long-Segment Radiation-Induced Distal Ureteral Strictures: A Case Series. *J Endourol Case Rep* 2020;6:305-9.
73. Avci E, Atıcı SD, Uylas U, et al. Stentless repair of left urethral defect with appendiceal interposition: A case report. *Int J Surg Case Rep* 2022;91:106805.
74. Patel S, Chaus FM, Funk JT, et al. Total Autologous Fascia Lata Sacrocolpopexy for Treatment of Pelvic Organ Prolapse: Experience in Thirty-Four Patients. *Urology* 2022;170:73-7.
75. Damiani GR, Villa M, Falcicchio G, et al. Robotic Sacrocolpopexy with Autologous Fascia Lata: A Case Series. *Gynecol Minim Invasive Ther* 2023;12:10-4.
76. Tate SB, Blackwell L, Lorenz DJ, et al. Randomized trial of fascia lata and polypropylene mesh for abdominal sacrocolpopexy: 5-year follow-up. *Int Urogynecol J* 2011;22:137-43.
77. Shoureshi PS, Dubinskaya A, Magner D, et al. Robotic Sacrohysteropexy With Concurrent Rectopexy using Fascia Lata Graft. *Urology* 2023;173:228.

doi: 10.21037/ales-23-36

Cite this article as: Doersch KM, Hines L, Ajay D. Narrative review of flaps and grafts in robotic reconstructive urologic surgery. *Ann Laparosc Endosc Surg* 2024;9:5.