



# A case report of a rare cause of reversible left ventricular dysfunction: pheochromocytoma

Muhammed Genes<sup>1</sup>, Serkan Asil<sup>1</sup>, Suat Gormel<sup>1</sup>, Salim Yasar<sup>1</sup>, Ali Fuat Çiçek<sup>2</sup>, Uygar Cagdas Yuksel<sup>2</sup>, Murat Celik<sup>1</sup>

<sup>1</sup>Department of Cardiology, Gulhane Training and Research Hospital, University of Health Sciences, Ankara, Turkey; <sup>2</sup>Department of Pathology, Gulhane Training and Research Hospital, University of Health Sciences, Ankara, Turkey

*Correspondence to:* Murat Celik, MD. Professor of Cardiology, Department of Cardiology, Gulhane Training and Research Hospital, University of Health Sciences, 06018 Etlik-Ankara, Turkey. Email: drcelik00@hotmail.com.

**Abstract:** Pheochromocytoma and paraganglioma are infrequent neuro-endocrine neoplasms of the adrenal medulla chromafin cells which overproduce catecholamines. These neoplasms release prompt and extreme amount of catecholamines. Early diagnosis is critical to avoid life-threatening complications. But first, it is necessary to suspect pheochromocytoma. It is classically presenting with paroxysmal hypertension and intermittent episodes of headaches, diaphoresis, palpitations. Since acute or chronic catecholamine intoxication may lead to structural myocardial changes, a number life-threatening cardiovascular complications may occur during the course of this disease. Limited data exists on the presentation, management and outcomes of such pheochromocytoma-induced cardiovascular complications. Besides, the cardiovascular manifestations of pheochromocytoma are usually associated with paroxysmal hypertensive crisis. Pheochromocytoma-induced left ventricle systolic dysfunction is a rare clinical entity and should be considered in the differential diagnosis of patients with idiopathic heart failure and without coronary stenosis, especially in those who have unexplained elevations in blood pressure. Surgical resection of the tumor is the mainstay of treatment. If done at appropriate time it has been shown to significantly improve the myocardial changes seen in the setting of pheochromocytoma. Our case highlights the importance of early suspicion and diagnosis for pheochromocytoma in such patients since a delay in diagnosis may contribute to irreversible myocardial remodeling.

**Keywords:** Pheochromocytoma; catecholamine; cardiovascular; reversible left ventricular dysfunction; case report

Received: 18 March 2021; Accepted: 12 May 2021; Published: 30 September 2021.

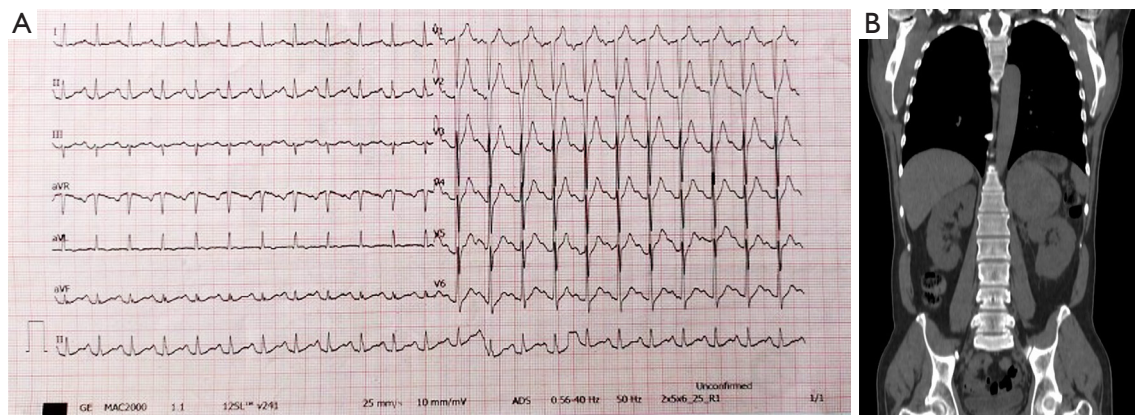
doi: 10.21037/jxym-21-16

View this article at: <http://dx.doi.org/10.21037/jxym-21-16>

## Introduction

Pheochromocytoma is a infrequent neuroendocrine neoplasm of the adrenal medulla chromafin cells and extra-adrenal neuroendocrine neoplasms of sympathetic and parasympathetic ganglia are named as paragangliomas. These neoplasms release prompt and extreme amount of catecholamines. Clinical symptoms associated with catecholamine overproduction are vastly assorted and may be paroxysmal or sustained. Pheochromocytoma is typically presenting with intermittent episodes of headaches, diaphoresis, palpitations and paroxysmal

hypertension. Furthermore, life-threatening cardio- and cerebrovascular complications include cardiac arrhythmia, ST and non-ST elevation myocardial infarction (MI), heart failure, hypertensive urgency, transient ischemic attack, stroke, and subarachnoid haemorrhage may occur (1). It has been suggested that acute or chronic catecholamine intoxication may lead to structural myocardial changes (2). However, limited data exists on the presentation, management and outcomes of such pheochromocytoma-induced cardiovascular complications and prospective studies have not been performed due to its low incidence of this clinical association. In our case report, we present



**Figure 1** The electrocardiogram (ECG) and Computed Tomography (CT) scan of current case. ECG showing sinus tachycardia and nonspecific intraventricular conduction delay (A); CT scan showing a well-demarcated mass lesion seen in left adrenal gland, measuring 81 mm × 76 mm (B).

a case of pheochromocytoma with a rare presentation of systolic heart failure, hypertensive emergency and diabetic ketoacidosis. Thereby, we aimed to aide in further understanding this clinical entity to avoid life-threatening cardiovascular complications of pheochromocytoma.

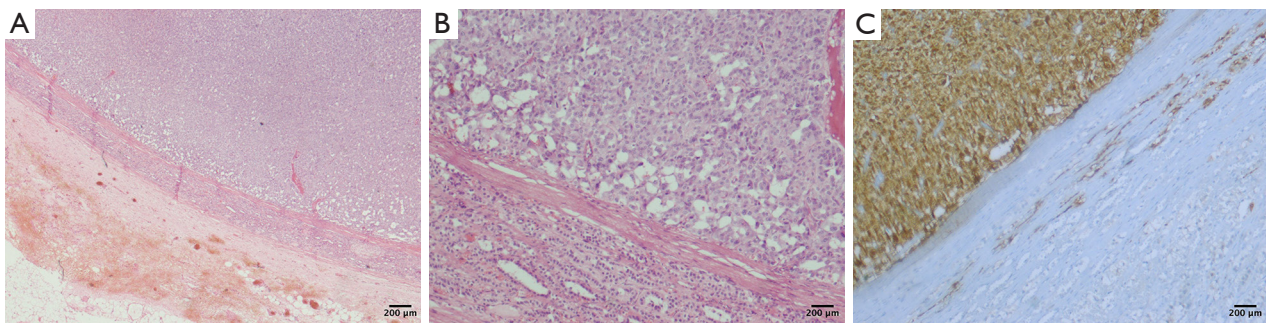
We present the following case in accordance with the CARE reporting checklist (available at <http://dx.doi.org/10.21037/jxym-21-16>).

### Case presentation

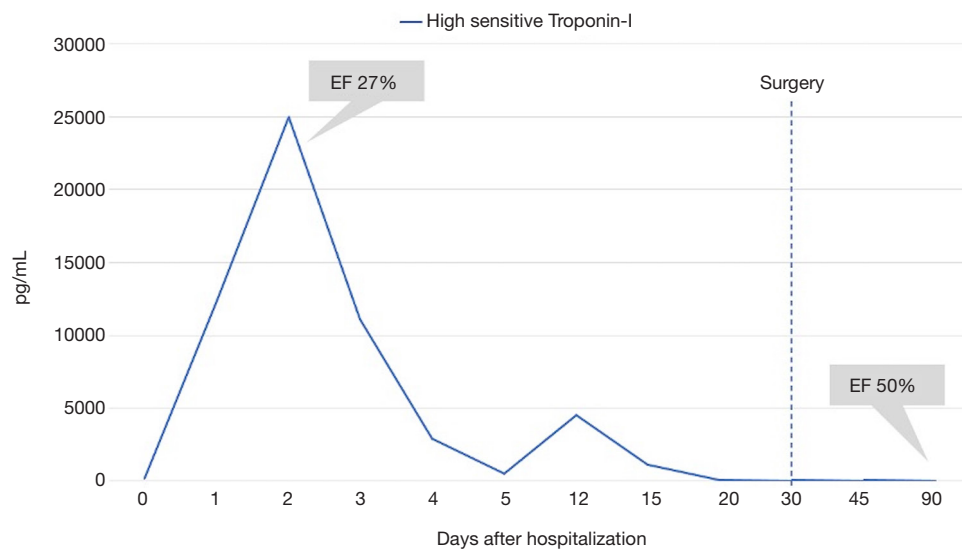
A 46-year-old man with a previous history of hypertension, diabetes mellitus, and cerebrovascular accident was admitted to the emergency room because of chest pain, palpitation and shortness of breath for 2 days. There was no significant family history of note. He did not smoke or drink alcohol. On the day of the admission, the patient was afebrile, and his blood pressure was 190/110 mmHg, heart rate was 120 beats/min, and oxygen saturation (SaO<sub>2</sub>) was 78%. He was conscious, but he was feeling anxious and uncomfortable. Physical examination revealed orthopnea, tachycardia, apical 2/6 systolic murmur and rales in the lower and mid segments of the both lungs. An admission 12-lead electrocardiogram (ECG) showed sinus tachycardia and electrical left ventricular hypertrophy (Figure 1A). Transthoracic echocardiography revealed global hypokinesia of the left ventricle with left ventricular ejection fraction (LVEF) of 25%. Biochemical tests showed some abnormal findings such as white blood cell count of 14,800 cells/ $\mu$ L, serum creatinine level of 1.36 mg/dL, and serum glucose

level of 483 mg/dL. Also, cardiac biomarkers including high sensitive troponin-I and creatine kinase MB were increased by 24,974.4 pg/mL and 82.1 ng/mL, respectively. Venous blood gas analysis revealed pH 7.23, PaCO<sub>2</sub> 35.8 mmHg, PaO<sub>2</sub> 31.9 mmHg, HCO<sub>3</sub><sup>-</sup>: 16.1 mmol/L, and Lactat 10.3 mmol/L. A chest X-ray showed prominent pulmonary vascular markings and bilateral costophrenic angle blunting. Following evaluation, he was diagnosed with acute coronary syndrome and heart failure (ACS) and treated as per guidelines. A coronary angiography (CAG) was performed. Interestingly, CAG did not reveal any stenosis, thrombus or coronary spasm in any of 3 epicardial coronary arteries. Hence, his diagnosis was revised to myocardial infarction with nonobstructive coronary arteries (MINOCA) and/or acute myocarditis. He was discharged when clinical stabilization was achieved. The patient subsequently developed similar symptoms and was readmitted to the hospital 6 days after discharge. Then, he was re-hospitalized for further examination and treatment. When the patient's clinic status was evaluated in detail, investigations revealed raised urinary catecholamines. Total urine metanephrine and normetanephrine levels were 3,271.08 ug/24 hours (normal value <350) and 39,333.20 ug/24 hours (normal value <600), respectively. Subsequent computed tomography (CT) of the abdomen and pelvis revealed a well-defined rounded relatively large size mass in left adrenal gland, measuring approximately 81 mm × 76 mm (Figure 1B).

On the basis of the clinical findings, laboratory reports, and having an adrenal incidentaloma, the patient was primarily thought to have a pheochromocytoma. Patient was



**Figure 2** Hematoxylin and eosin (H&E) stainings of current case. The scale bar indicate 200  $\mu\text{m}$ . Well-defined and encapsular lesion is observed in histological sections (A); At higher magnification, the lesion is demonstrating atypical cells with large eosinophilic cytoplasm and locally prominent nucleoli, forming solid islands and locally microcystic areas (B); Positivity of neuron-specific enolase one of the neuroendocrine markers in immunohistochemical examination (C).



**Figure 3** Clinical course of the patient after hospitalization. High sensitive troponin-I level were increased and ejection fraction was decreased at administration and gradually improved during the course of hospitalization.

medically stabilised with alpha- and beta-adrenergic receptor blocker (doxazocin and metoprolol) at recommended doses. Following consensus by the multiple disciplinary team consisting of cardiology, endocrinology and general surgery, the patient underwent left adrenalectomy. Surgical and post-operative follow-up was uncomplicated. The pathology report confirmed that the tumor was a pheochromocytoma with a well-demarcated and encapsular mass pathology image in which solid islands and atypical cells with large eosinophilic cytoplasm forming microcystic areas, locally prominent nucleoli, and positive neuroendocrine markers in immunohistochemical examination (Figure 2). After the

tumor was excised, the patient's condition dramatically improved, and transthoracic echocardiography performed 3 months after surgery revealed an improvement in the LVEF with 50%. An overview of the patient's clinical course is displayed in Figure 3.

#### **Ethical statement**

All procedures performed in studies involving human participants were in accordance with the ethical standards of the institutional and/or national research committee(s) and with the Helsinki Declaration (as revised in 2013). Written

informed consent was obtained from the patient.

## Discussion

Pheochromocytoma and paraganglioma are neuroendocrine neoplasms which overproduce catecholamines. The average age of presentation of these neuroendocrine tumors is between 30 and 50 years (3). There is no clear gender tendency. The initial clinical presentation may be imprecise and symptoms and signs may be difficult to interpret. This often leads to delayed diagnosis and irreversible cardiac remodeling in many cases. This delay in the diagnosis is generally reported at 3 years for pheochromocytoma (4) and 5 years for paraganglioma (5). However, early diagnosis of pheochromocytoma is critical to avoid life-threatening complications. First of all, it is necessary to suspect pheochromocytoma. Sampling of blood and urinary catecholamines and metanephrines can be helpful to aid its diagnosis in suspected cases. Furthermore, it is important to note that imaging should be done only when there is biochemical confirmation of pheochromocytoma. CT scan of the adrenal gland is valuable to detect the presence and the localization of the tumor. Other imaging studies such as magnetic resonance imaging (MRI), meta-iodobenzylguanidine scintigraphy and positron emission tomography scan could all be used for confirmation the diagnosis or when CT findings are insufficient.

The cardiovascular manifestations of pheochromocytoma are usually associated with paroxysmal hypertensive crisis. Furthermore, recent years, pheochromocytoma has been described in association with myocarditis, acute coronary syndrome, different type of cardiomyopathies (Takotsubo cardiomyopathy, hypertrophic obstructive cardiomyopathy, dilated cardiomyopathy, or unspecified cardiomyopathy), left ventricular dysfunction, arrhythmias, cardiogenic shock, and pulmonary edema (1,6). The clinical picture of these tumors is depending on the type and amount of the catecholamine produced. Diagnosis of pheochromocytoma-related cardiovascular diseases is often delayed due to the atypical presentation. Whilst norepinephrine-mediated alpha receptor stimulation causes vasoconstriction, volume contraction and hypertension; epinephrine-mediated beta 2 receptor stimulation results in vasodilatation and hypotension (7). It also noted that right-sided pheochromocytomas were more likely to be associated with cardiovascular symptoms and ECG abnormalities than those on the left side (8). In our case, the patient had reversible

left ventricular dysfunction induced by pheochromocytoma due to a large left-sided adrenal mass. High blood pressure at initial presentation is not usually observed in heart failure with reduced LVEF. Thereby, while investigating the causes of heart failure, usually pheochromocytoma is not considered. Knowledge about this pathology is limited due to difficulties in diagnosing because of variability in clinical manifestations, and its low incidence and prevalence. Prospective studies mostly cannot be done and publications predominantly consist of isolated case reports. However, unexplained cardiomyopathy and/or heart failure with reduced LVEF with patent coronary arteries should lead to suspicion of the presence of a pheochromocytoma, especially in patients with unexplained unpredictable blood pressure. Besides, sinus tachycardia and electrical left ventricular hypertrophy at clinical onset are considered as strong complementary arguments for pheochromocytoma (2). Investigation of these intermittent non-specific symptoms prior to the index admission, may have led to the diagnosis of pheochromocytoma and prevent the subsequent cardiovascular complication. Left ventricular dysfunction was temporary in most cases when pheochromocytoma was diagnosed early and treated properly or was persistent when the tumors remained undetected. In our case, we deemed the catecholamine-induced myocarditis causing diffuse left ventricular dysfunction, and LVEF improved significantly after surgical adrenalectomy.

Although numerous hypotheses have been accounted for catecholamine-induced cardiovascular complications, the exact pathogenesis is uncertain. The main proposed mechanisms are cardiotoxicity due to excessive catecholamine secretion, myocardial ischemia, sympathetic nervous system hyperactivation, metabolically induced coronary insufficiency due to demand/supply imbalance caused by intense adrenergic stimulation, functional hypoxia due to increased contractility and coronary spasm leading to decreased blood flow, increased oxygen consumption due to excessive free fatty acid induced mitochondrial uncoupling, intracellular calcium excess, oxidative stress, microvascular dysfunction, and left ventricular outlet tract obstruction (6,9,10). Heart failure may develop depending on the magnitude and the duration of this damage. While acute catecholaminergic stress overwhelms myocardial B receptors leading to a stunning of the left ventricle via slight histological apoptosis, chronic and long-standing catecholaminergic exposure might lead to permanent structural myocardial alterations (2,11). Prolonged catecholamine exposure produces some

cardiac histopathological changes mainly in the form of focal contraction band necrosis (CBN), hypercontracted sarcomeres, diffuse interstitial inflammatory cell infiltration with lymphomonocytes, myocyte apoptosis and myocardial fibrosis leading to left ventricle dysfunction (2,6,12,13). Based on inflammatory cell infiltration, considerable number of patients with pheochromocytoma-induced left ventricular dysfunction have been diagnosed as myocarditis. However, CBN illustrated histologically by dense irregular eosinophilic clustering of the sarcoplasm with intervening cleared areas is different from the myocardial infarction necrosis (6,14). CBN initiates mononuclear cell reaction and the healing process leads to myocardial fibrosis associated with a poorer prognosis (13). Thereby, the inflammatory cell infiltration is a result of secondary response to catecholamine excess in the myocardium and not a primary myocarditis.

Malignancy is a known complication of pheochromocytomas and approximately 10% of pheochromocytomas are malignant (15). Although it is controversial, increased tumor size, the magnitude of areas of tumor necrosis, extra-adrenal manifestation, and younger age all have been previously demonstrated as a predictive factor of malignancy, tumor recurrence, and a poorer prognosis (15). The patient in our case was relatively young and size of the tumor was relatively big. PASS score, derived from the tumour's pathological features, has been used to differentiate the aggressive or benign behavior of the tumor. Tumors with a PASS score of 4 and above are reported to behave in a more aggressive way (16). In our case, the patient's PASS score was 7 indicated that it was an aggressive tumour. However, there is no data associating PASS score and clinical presentation of the pheochromocytoma. Also, the Ki-67 proliferation index was up to 2% in our case.

Appropriate management of the pheochromocytoma has been shown to significantly improve the myocardial changes seen in heart failure. Standard heart failure treatment is recommended as the treatment of heart failure due to pheochromocytoma. But, it should not be forgotten that surgical resection of the tumor is the mainstay of treatment. Early diagnosis and end of catecholamine exposure after surgical resection of the pheochromocytoma might give the potential reversibility of structural myocardial changes. The proportion of LV systolic function recovery was only 50% via medical treatment while reaching 82.2% after surgery (2). In our study, we observed the recovery of LVEF after surgery. Beyond this, appropriate presurgical medical therapy with alpha adrenergic receptor blocker (doxazosin and phenoxybenzamine) and adjustment of intravascular volume is pivotal (17,18). Beta-blockers (propranolol, metoprolol or

atenolol) have also preferably been added to alpha adrenergic receptor blocker (18). However, attention should be paid to not to start Beta-blockers before alpha-blockers in the setting of pheochromocytoma. Because some challenges may be encountered during the cardiovascular system management due to the unopposed alpha blockade (7).

## Conclusions

Pheochromocytoma-induced left ventricle systolic dysfunction is a rare clinical entity and should be considered as a differential diagnosis in patients with idiopathic heart failure and without coronary stenosis, especially in those who have unexplained elevations in blood pressure at admission. Surgery remains the gold standard treatment modality and allows the potential reversibility of left ventricular dysfunction when it is performed at the proper time. Our case highlights the importance of early suspicion and diagnosis for pheochromocytoma in such patients since a delay in diagnosis may contribute to irreversible myocardial remodeling and death.

## Acknowledgments

*Funding:* None.

## Footnote

*Reporting Checklist:* The authors have completed the CARE reporting checklist. Available at <http://dx.doi.org/10.21037/jxym-21-16>

*Conflicts of Interest:* All authors have completed the ICMJE uniform disclosure form (available at <http://dx.doi.org/10.21037/jxym-21-16>). The authors have no conflicts of interest to declare.

*Ethical Statement:* The authors are accountable for all aspects of the work in ensuring that questions related to the accuracy or integrity of any part of the work are appropriately investigated and resolved. All procedures performed in studies involving human participants were in accordance with the ethical standards of the institutional and/or national research committee(s) and with the Helsinki Declaration (as revised in 2013). Written informed consent was obtained from the patient.

*Open Access Statement:* This is an Open Access article

distributed in accordance with the Creative Commons Attribution-NonCommercial-NoDeri 4.0 International License (CC BY-NC-ND 4.0), which permits the non-commercial replication and distribution of the article with the strict proviso that no changes or edits are made and the original work is properly cited (including links to both the formal publication through the relevant DOI and the license). See: <https://creativecommons.org/licenses/by-nc-nd/4.0/>.

## References

- Luca F, Holl N, Vinzio S, et al. Cardiac manifestations of pheochromocytoma. *Ann Endocrinol (Paris)* 2009;70:43-7.
- Batisse-Lignier M, Pereira B, Motreff P, et al. Acute and Chronic Pheochromocytoma-Induced Cardiomyopathies: Different Prognoses?: A Systematic Analytical Review. *Medicine (Baltimore)* 2015;94:e2198.
- Tan JH, Mafee MF. Case 197: malignant paraganglioma manifesting with calvarial metastases. *Radiology* 2013;268:919-23.
- Lenders J W, Eisenhofer G, Mannelli M, et al. Pheochromocytoma. *Lancet* 2005;366:665-75.
- Saddoud N, Turki I, Chammakhi R, et al. Malignant paraganglioma with vertebral and skull metastasis. *J Radiol* 2006;87:1887-90.
- Y-Hassan S, Falhammar H. Cardiovascular Manifestations and Complications of Pheochromocytomas and Paragangliomas. *J Clin Med* 2020;9:2435.
- Pappachan JM, Tun NN, Arunagirinathan G, et al. Pheochromocytomas and Hypertension. *Curr Hypertens Rep* 2018;20:3.
- Liao WB, Liu CF, Chiang CW, et al. Cardiovascular manifestations of pheochromocytoma. *Am J Emerg Med* 2000;18:622-5.
- Adameova A, Abdellatif Y, Dhalla NS. Role of the excessive amounts of circulating catecholamines and glucocorticoids in stress-induced heart disease. *Can J Physiol Pharmacol* 2009;87:493-514.
- Lyon AR, Rees PS, Prasad S, et al. Stress (Takotsubo) cardiomyopathy--a novel pathophysiological hypothesis to explain catecholamine-induced acute myocardial stunning. *Nat Clin Pract Cardiovasc Med* 2008;5:22-9.
- Zhang R, Gupta D, Albert SG. Pheochromocytoma as a reversible cause of cardiomyopathy: Analysis and review of the literature. *Int J Cardiol* 2017;249:319-23.
- Bourke SJ, Wilkes G, Maloney DL, et al. Pheochromocytoma-induced myocardial necrosis. *Scott Med J* 1991;36:184.
- Silver MD. Myocardial lesions in pheochromocytoma. *CMAJ* 1990;142:99-100.
- Karch SB, Billingham M E. Myocardial contraction bands revisited. *Hum Pathol* 1986;17:9-13.
- Chrisoulidou A, Kaltsas G, Ilias I, et al. The diagnosis and management of malignant pheochromocytoma and paraganglioma. *Endocr Relat Cancer* 2007;14:569-85.
- Thompson LD. Pheochromocytoma of the Adrenal gland Scaled Score (PASS) to separate benign from malignant neoplasms: a clinicopathologic and immunophenotypic study of 100 cases. *Am J Surg Pathol* 2002;26:551-66.
- Falhammar H, Kjellman M, Calissendorff J. Treatment and outcomes in pheochromocytomas and paragangliomas: a study of 110 cases from a single center. *Endocrine* 2018;62:566-575.
- Lenders JWM, Kerstens MN, Amar L, et al. Genetics, diagnosis, management and future directions of research of pheochromocytoma and paraganglioma: a position statement and consensus of the Working Group on Endocrine Hypertension of the European Society of Hypertension. *J Hypertens* 2020;38:1443-56.

doi: 10.21037/jxym-21-16

**Cite this article as:** Genes M, Asil S, Gormel S, Yasar S, Çiçek AF, Yuksel UC, Celik M. A case report of a rare cause of reversible left ventricular dysfunction: pheochromocytoma. *J Xiangya Med* 2021;6:24.