



Is reimplant after breast implant-associated anaplastic large cell lymphoma a safe procedure? Yes, no, or may be?

Vittoria Tarantino¹, Tetiana Skypets², Francesco Angrilli³, Massimo Federico¹

¹Department of Diagnostic, Clinical and Public Health Medicine, University of Modena and Reggio Emilia, Modena, Italy; ²Onco-Haematology Department, National Cancer Institute, Kiev, Ukraine; ³Ospedale Civile S. Spirito, Pescara, Italy

Correspondence to: Vittoria Tarantino, MD. Department of Diagnostic, Clinical and Public Health Medicine, University of Modena and Reggio Emilia, Centro Oncologico Modenese, Via del Pozzo 71, 41124 Modena, Italy. Email: vittoriatarantino@hotmail.it.

Abstract: Breast implant-associated (BIA) anaplastic large cell lymphoma (ALCL) is a rare clinical-pathologic entity recently recognized in the 2016 WHO classification of lymphoid neoplasms. Being a very rare lymphoma sub-type, it is difficult to be certain about the absolute risk of developing this disease and the issues about pathogenesis and etiology are still controversial and matter of debate. Current treatment strategies indicate that the capsulectomy and removal of breast implants are required. An excellent prognosis is reached after surgical removal. Thanks to the excellent prognosis, an increasing number of women who underwent breast implant for aesthetic reasons express the desire of a new reimplant, if safe. Here we present the case of a 48 years old woman diagnosed with a BIA-ALCL developed 8 years after breast implants for aesthetic reasons, in absence of any breast disease, with no evidence of disease 6 months after implant removal. She worried about her physical aspect after bilateral removal of breast implants and asked how safe a breast reimplant would be. After a careful analysis of pros and cons we concluded that smooth implants could be re-inserted after at least 1 year of follow-up, once the absence of any recurrence was confirmed. Given the relevance of the question proposed by our patient, we believe that more information on safety of breast reimplant is urgently needed.

Keywords: Breast implant-associated anaplastic large cell lymphoma (BIA-ALCL); breast implant; T cell lymphoma; treatment

Received: 12 June 2018; Accepted: 27 July 2018; Published: 02 August 2018.

doi: 10.21037/aol.2018.07.01

View this article at: <http://dx.doi.org/10.21037/aol.2018.07.01>

Introduction

Breast implant-associated anaplastic large cell lymphoma (BIA-ALCL) is a rare type of T-cell non-Hodgkin lymphoma, classified as a provisional entity in the 2016 WHO classification of lymphoid neoplasms (1). The disease has morphological and immunophenotypic features indistinguishable from those of ALK-negative ALCL, arising primarily in association with a breast implant.

The first case of BIA-ALCL was described in 1997 by Keech *et al.*, as a lymphoma arising in proximity to a saline-filled breast implant (2). Usually, it occurs in fluid collected in an implant surrounding after surgery for aesthetic or reconstructive reason.

The real incidence of BIA-ALCL still remains unknown,

although the risk of developing a BIA-ALCL is estimated in one case per 500,000 women with breast implants (1,3,4)

Since the first report, approximately 400 cases of this rare entity have been reported in the literature so far (3,5). Due to large number of breast augmentation procedures and reconstructions after mastectomy, it is reasonable estimating that an increasing number of women are at risk for developing BIA-ALCL.

BIA-ALCL usually occurs 3–14 years after aesthetic or reconstructive breast augmentation, with different types of implants (saline or silicone) (6,7). Frequently, patients present with seroma or fluid effusion in implant surrounding, breast inflammation, swelling and asymmetry.

The issues on etiology and pathogenesis are still

controversial and matter of debate. However, there is increasing evidence that inflammatory reaction to chronic bacterial/biofilm infection and use of textured implants may promote the development of BIA-ALCL (7,8).

The prognosis of this type of lymphoma is excellent, once the breast implants with the capsule are removed. Current treatment strategies indicate that the removal of both breast implants is required, because a small number of cases that have been diagnosed on both sides at the same time. However, a small group of patients have a tumor mass and may require additional therapy.

While exhaustive guidelines on treatment of BIA-ALCL are already available (9) there is no data available on the safety, and timing, of new breast implant insertion for aesthetic and psychological aspects, once BIA-ALCL has been successfully treated.

Here we like to share with the readers the case of a 48 years old woman diagnosed with stage I BIA-ALCL developed 8 years after a textured, silicone filled breast implant was performed for aesthetic reasons, and treated with surgical removal six months earlier. She came to us with the following intriguing questions: “May I undergo a new breast implant insertion? Which implant type should I consider? And, when the new implant could be re-inserted?”.

Case presentation

A 48 years old lady presented at our attention on November 2017, with a recent diagnosis of BIA-ALCL, developed eight years after implantation with breast silicone and textured implant for cosmetic reason in 2009.

Since February, 2017 patient was complaining with swelling associated with skin rash surrounding the right reconstructed breast. An MRI evaluation was performed detecting a peri-protosthetic fluid collection (*Figure 1*). Other symptoms such as mass, enlargement of lymph nodes or capsular disruption were not reported. The patient underwent an ultrasound guided aspiration of pericapsular fluid. The cytologic analysis revealed the presence of atypical medium-to-large cells with high CD30 expression.

The patient was then referred to a multidisciplinary team with plastic surgeons and hematologists for making a decision on further management and treatment strategy. Following an initial treatment with steroids and antibiotics, the removal of implants and the fibrous capsule around them from both breasts was performed on August, 2017.

Histologic examination confirmed the diagnosis of BIA-ALCL in the right breast. Immunohistochemistry (IHC) showed strong CD30 expression in anaplastic cells and negativity of anaplastic lymphoma kinase (ALK). Tumor cells were also positive for CD4, CD43, CD3, CD45, CD2, and negative for CD5, CD7, CD8, and CD15. No lesions were detected in left breast implant.

Staging procedures performed after surgery, including PET/CT and MRI revealed no abnormalities. No additional treatment was proposed, and the patient was found in complete remission 3 months later.

On November, 2017, the patient was referred to our attention for an opinion on the opportunity to proceed with a breast reimplant.

The patient was in excellent physical condition, reported no problems associated with previous surgical treatment. However, she was extremely worried about her aesthetic aspect. The clinical examination confirmed the absence of disease recurrence. Both “empty” breasts had normal aspect, no signs of inflammation, the skin was soft, not fixed on the underlying tissues.

Once we reassured her that the BIA-ALCL was successfully cured with the removal of both implants and, given the limited stage of the disease, the risk of relapse was negligible, she asked our opinion on the risk of a new BIA-ALCL in case of a new breast implant. She confirmed the strong desire in improving the shape of her breasts.

After a detailed analysis of costs, benefits, and taking into account her expectations, we stated that smooth implants could be re-inserted after at least 1 year of follow-up confirming the absence of any recurrence, also informing the patient that the safety of this strategy is still being investigated.

Discussion

In 2016, more than 1,649,271 breast implants worldwide have been reported by the International Society of Aesthetic Plastic Surgery (ISAPS). Among them, breast augmentation with silicone was by far the most adopted procedure with 87.8% of cases. But there are no data about what kind of implants are in use more frequently: textured or smooth. ISAPS survey showed 9% increase of aesthetic procedures compared to 2015 and highlighted top 5 countries with the highest rank of procedures: USA, Brazil, Japan, Italy, Mexico. Breast augmentation is the third fastest growing cosmetic procedure (increased to 22%) and the first between

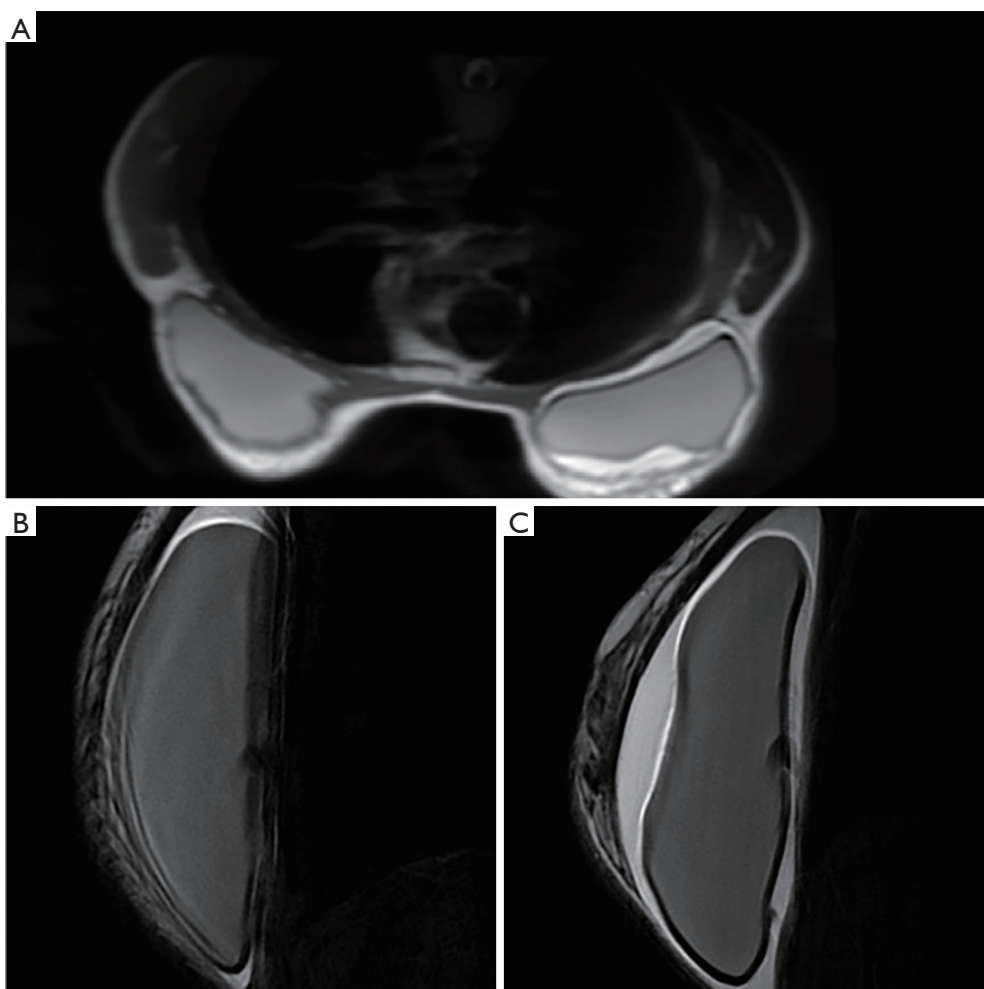


Figure 1 MRI initial assessment of the disease detecting fluid effusion. (A) Imaging study from MRI at diagnosis showing an extended effusion surrounding right breast implant. (B,C) Comparison between left breast implant and right breast implant in sagittal section T2.

surgical procedures (15.8% of all). From year to year the number of such procedures is increasing due to quality of life improvement (QoL) and psychological aspects. Nevertheless, woman proceeded for breast augmentation for aesthetic or reconstructive reasons could be at risk group for developing BIA-ALCL. According to the worldwide experience in diagnostics and treatment of BIA-ALCL, there were proposed recommendations for all patients who is going to proceed for breast implant surgery. They include implant selection, discussion about all benefits and limitations of implant types, avoiding implant removal from asymptomatic woman, the use of antibacterial strategy (10).

Since FDA published data about 359 cases of BIA-ALCL, there are still no references about possibility and safety of reimplant after implant removal. This strategy

requires more detailed investigation, analysis and discussion. According to presented information published last years, there are two main reasons that can be related to each other in the onset of BIA-ALCL: type of implant material and chronic bacterial biofilm infection around implants (8,11).

Out of the 359 cases of BIA-ALCL reported by FDA, there are 231 cases with available information about implant surface. Data showed that 203 cases were with textured implants, while only 28 were smooth, but no significant influence of filled material in implant. This phenomenon should be also explained that only textured implants are available in some countries (5). Other important fact of their worldwide use is a minimal risk of capsular contracture development compared to smooth implants (12).

In addition to above, based on the obtained data, one

of the supposed causes of disease may be the presence of specific bacteria biofilm on implant surface. Hu *et al.* showed specific microbiome of *Ralstonia spp.* (Gram-negative) in BIA-ALCL specimens compared to *Staphylococcus spp.* in normal and contracture capsule specimens (8).

Taking into account these results, Adams *et al.* analyzed the outcome of 42,000 textured implants in 21,650 women who underwent breast augmentation for different reasons (13). Data were prospectively collected from five countries. The main idea was to establish the incidence of BIA-ALCL through the use of the surgical 14-point plan, which was presented and adapted worldwide in 2013 to minimize a level of capsular contractures due to bacterial load during breast augmentation (14,15). Of note, the adoption of the surgical 14-point plan resulted in no cases of BIA-ALCL during follow-up. Despite all data given above, we still need more information about mechanisms of developing BIA-ALCL.

Returning to the issue of possible reimplant in case of these patients, there are still more questions than answers. Some data suggest the safety of reimplant with smooth implants, although the median follow-up is short, and strict monitoring is mandatory (4).

In patients with limited stage BIA-ALCL the risk of relapse after a complete surgical removal is very low. In the report from the MD Anderson Cancer Center, 39 (93%) of 42 patients without a mass achieved complete remission at last follow-up, and 100% of overall survival was reported among 19 cases collected in France from different institutions through Lymphopath over a 5-year period (16).

The Australian and New Zealand BIA-ALCL Task Force has recently provided updated information regarding BIA-ALCL (17). Based on their huge experience and other available information we believe that in patients with limited stage BIA-ALCL asking for reimplant we can say that smooth implants could be re-inserted after at least 1 year of continuous complete remission following surgical removal, also informing the patient that the safety of this strategy is still being investigated.

In conclusion, if we are asked whether reimplant after BIA-ALCL is a safe procedure, based on available data, and upon our own experience we can say "Yes, may be". Of course, we still are in emergency need for more data coming from existing data bases.

Acknowledgements

None.

Footnote

Conflicts of Interest: The authors have no conflicts of interest to declare.

Informed Consent: Informed consent was obtained from the patient for publication of this case report with any accompanying images.

References

1. Swerdlow SH, Campo E, Pileri SA, et al. The 2016 revision of the World Health Organization classification of lymphoid neoplasms. *Blood* 2016;127:2375-90.
2. Keech JA Jr, Creech BJ. Anaplastic T-cell lymphoma in proximity to a saline-filled breast implant. *Plast Reconstr Surg* 1997;100(2):554-5.
3. FDA food and drug administration. Breast Implant-Associated Anaplastic Large Cell Lymphoma (BIA-ALCL) [Internet]. 2017. Available online: <https://www.fda.gov/MedicalDevices/ProductsandMedicalProcedures/ImplantsandProsthetics/BreastImplants/ucm239995.htm>
4. Clemens MW, Nava MB, Rocco N, et al. Understanding rare adverse sequelae of breast implants: anaplastic large-cell lymphoma, late seromas, and double capsules. *Gland Surg* 2017;6:169-84.
5. Leberfinger AN, Behar BJ, Williams NC, et al. Breast Implant-Associated Anaplastic Large Cell Lymphoma: A Systematic Review. *JAMA Surg* 2017;152:1161-8.
6. Australian Government D of H. Breast implants and anaplastic large cell lymphoma [Internet]. 2017. Available online: <https://www.tga.gov.au/alert/breast-implants-and-anaplastic-large-cell-lymphoma>
7. Santanelli di Pompeo F, Laporta R, Sorotos M, et al. Breast Implant-Associated Anaplastic Large Cell Lymphoma: Proposal for a Monitoring Protocol. *Plast Reconstr Surg* 2015;136:144e-51e.
8. Hu H, Johani K, Almatroudi A, et al. Bacterial Biofilm Infection Detected in Breast Implant-Associated Anaplastic Large-Cell Lymphoma. *Plast Reconstr Surg* 2016;137:1659-69.
9. Loch-Wilkinson A, Beath KJ, Knight RJW, et al. Breast Implant-Associated Anaplastic Large Cell Lymphoma in Australia and New Zealand: High-Surface-Area Textured Implants Are Associated with Increased Risk. *Plast Reconstr Surg* 2017;140:645-54.
10. Thompson PA, Prince HM. Breast implant-associated anaplastic large cell lymphoma: a systematic review of the

- literature and mini-meta analysis. *Curr Hematol Malig Rep* 2013;8:196-210.
11. Adams WP Jr. Discussion: Breast Implant-Associated Anaplastic Large Cell Lymphoma in Australia and New Zealand: High-Surface-Area Textured Implants Are Associated with Increased Risk. *Plast Reconstr Surg* 2017;140:663-5.
 12. Headon H, Kasem A, Mokbel K. Capsular Contracture after Breast Augmentation: An Update for Clinical Practice. *Arch Plast Surg* 2015;42:532-43.
 13. Adams WP Jr, Culbertson EJ, Deva AK, et al. Macrot textured Breast Implants with Defined Steps to Minimize Bacterial Contamination around the Device: Experience in 42,000 Implants. *Plast Reconstr Surg* 2017;140:427-31.
 14. Deva AK, Adams WP Jr, Vickery K. The role of bacterial biofilms in device-associated infection. *Plast Reconstr Surg* 2013;132:1319-28.
 15. Clemens MW, Horwitz SM. NCCN Consensus Guidelines for the Diagnosis and Management of Breast Implant-Associated Anaplastic Large Cell Lymphoma. *Aesthet Surg J* 2017;37:285-9.
 16. Miranda RN, Aladily TN, Prince HM, et al. Breast implant-associated anaplastic large-cell lymphoma: long-term follow-up of 60 patients. *J Clin Oncol* 2014;32:114-20.
 17. Kim B, Roth C, Chung KC, et al. Anaplastic large cell lymphoma and breast implants: a systematic review. *Plast Reconstr Surg* 2011;127:2141-50.

doi: 10.21037/aol.2018.07.01

Cite this article as: Tarantino V, Skypets T, Angrilli F, Federico M. Is reimplant after breast implant-associated anaplastic large cell lymphoma a safe procedure? Yes, no, or may be? *Ann Lymphoma* 2018;2:6.