



A narrative review of the role of robotics in cancer surgery

Kaya Jeyarajah, Ben Morrison

Department of Anaesthetics, Royal Surrey NHS Foundation Trust, Guildford, UK

Contributions: (I) Conception and design: None; (II) Administrative support: None; (III) Provision of study materials or patients: None; (IV) Collection and assembly of data: None; (V) Data analysis and interpretation: None; (VI) Manuscript writing: All authors; (VII) Final approval of manuscript: All authors.

Correspondence to: Kaya Jeyarajah, Perioperative Anaesthetic Clinical Fellow, Department of Anaesthetics, Royal Surrey NHS Foundation Trust, Egerton Road, Guildford, Surrey, GU2 7XX, UK. Email: Kayajeyarajah@hotmail.com.

Abstract: In recent times the use of minimally invasive laparoscopic surgery has greatly expanded, becoming increasingly developed since its advent. This technical innovation has allowed more complex procedures to be undertaken. Standard laparoscopic surgery has several limitations, for example positioning of the camera being operator dependent, mostly only providing two-dimensional views and restricted instrument movements for the surgeon. Robotic-assisted surgery allows improved control of the instruments over traditional laparoscopic instruments, more able to achieve the movements that the operator requires thus permitting more and more technically challenging procedures to be accomplished. Advantages of robotic surgery are that it integrates into enhanced recovery after surgery (ERAS) programmes through enabling faster recovery for patients with a shorter length of hospital stay, reduced postoperative pain, fewer wound complications, better cosmetic outcome and reduced blood loss. Robotic surgery also offers three-dimensional views with magnification and surgical instruments capable of increasing degrees of freedom thus replicating hand movements with greater precision. The use of robotics has implications for the anaesthetist including the potential for more restricted access to the patient's airway. This article explores the history of robotic surgery and reviews the literature available for several surgical specialities as well as an insight into areas for the future development of robotics.

Keywords: Surgery; robotics; perioperative; enhanced recovery after surgery (ERAS); cancer

Received: 07 June 2020; Accepted: 30 October 2020; Published: 30 December 2020.

doi: 10.21037/dmr-20-85

View this article at: <http://dx.doi.org/10.21037/dmr-20-85>

Introduction

Minimally-invasive laparoscopic surgery has rapidly expanded, offering minimal tissue damage as its main advantage for patients along with reduced pain, length of stay and blood loss. Robots have become key in this surgical discipline and offer several advantages over standard laparoscopic surgery which has limitations including positioning of the camera being operator dependent, only two-dimensional views and narrower, restricted movements for the surgeon with limited degrees of freedom from the equipment including an absence of wrist movement (1).

Robotic devices used in surgery at this current time are defined by a computer-controlled manipulator that can be

calibrated to move, use instruments, and carry out a wide assortment of duties. These robots have an absence of self-sufficient activities or pre-programmed actions. A more accurate description for these devices is as an enriched tele-manipulator system where the surgeon is transported to the operative site as though they were present in the operative field (2). Importantly the robot does not substitute the surgeon but executes and augments the precision of the surgeon's hands (3).

The history of robotic surgery stemmed from the NASA space programme in the 1960's (4). The first generation of robots were stereotactic robots, such as PUMA 200 (1985), initially developed for obtaining brain biopsies. These robots were developed with the notion of making



Figure 1 Intuitive Da Vinci Xi Surgical System showing (left to right) surgeon's console, vision tower and patient cart. © 2020 Intuitive Surgical, Inc.

more precise movements in scenarios where any erroneous movements could result in disastrous consequences.

The first generation of robots had demonstrated evident drawbacks such as that robotic technology of the time required the surgeon to review each-and-every step prior to proceeding as the robots were unable to execute multiple tasks unsupervised. This ultimately limited the use and variability to other areas of surgery hence a new generation of robots would have to be developed to function with additional dexterity and to accommodate more compliant tissues.

Second-generation robots introduced capabilities that could overcome certain difficulties encountered by traditional laparoscopic surgery, namely two-dimensional visualisation, access to tissue planes such as the thoracic cavity or pelvis due to anatomical restraints and imprecise instruments for delicate procedures, such as anastomoses, and a lack of physical (haptic) feedback from division of certain tissues. The “Probot” for operating on prostate gland and “Zeus” for open heart surgery are examples of second-generation robots. With the “Zeus” robot the arms of the robot were joined to the operating table. It was with this robot that trans-Atlantic surgery was performed where the patient was in France and the surgeons were located in the USA (4).

The gateway to pushing frontiers in robotics was exhibited by the “Da Vinci” robot, 1999, that has subsequently dominated the surgical market (*Figure 1*). The key components comprise of a master console, a robotic surgical manipulator and a visualisation tower. The surgeon sits at the master console and controls the

surgical manipulator. The console permits visualisation of the surgical field, through an eyepiece, in three dimensions. The surgeon has access to control the robot's arms through two actuators and foot controls which combine to regulate the diathermy, camera and multiple instruments (5). The visualization tower contains the computer that incorporates images from the camera and a monitor enabling theatre staff to witness the surgeon's view. As the surgeon is at the master console, a scrubbed assistant is still mandatory to insert instruments through the endoscopic ports alongside other duties. The robotic surgical manipulator has three inbuilt arms, one to hold the camera and two others to hold surgical instruments. There have been various editions of the Da Vinci robot with an increase in the number of arms from three to four and with improved high-definition visual technology edition X and Xi being the most up to date. Edition SP has not appeared in the UK at the time of writing this article and is designed to function with only one endoscopic port.

The features of the Da Vinci robot that retain it in common use today pertain to the fact that the master console allows the surgeon to operate distantly from their patient with three-dimensional imaging thus the surgeon can appreciate depth of the surgical plane. The console reduces tremors of the surgeon's hand compared to traditional laparoscopic use. Moreover, the robot arms produce movements of the endo-wrist allowing seven degrees of freedom in comparison to the routine four degrees of freedom with traditional laparoscopic surgery, this grants the surgeon control of the arms to reach around curved planes that might not be possible with standard

minimally-invasive surgery (5). Ergonomically, the hand-eye coordination movements at the console are in one line allowing for fewer unnecessary movements. Overall, these improvements have been shown to translate to a shorter length of hospital stay, improved pain control, reduced operative blood loss (2) and fewer positive margins when resecting mitotic lesions. Widespread availability of robotic surgery is, however, limited by the high cost of around £1.5 million per robot as well as instrument and servicing costs which constrain its use.

Enhanced recovery after surgery (ERAS) pathways have been developed for several surgeries such as radical cystectomy where the benefits of reduced length of stay and faster recovery to baseline are key for the patient's care. Minimally invasive surgery, with benefit of reduced tissue damage compared to open procedures results, in faster surgical healing, reduced blood loss and transfusions, reduced need for medications with side effects for pain relief, and reduced development of chronic pain as fewer nerves are likely to be damaged (6,7).

The objectives of this article are to explore the more common surgical disciplines in which robotic-assisted procedures are taking place and the evidence behind the continuing use and success of the technology currently available. We will also explore the future avenues of development in robotic-assisted surgery.

Our literature search was conducted using the PubMed and EMBASE search facilities alongside Google Scholar when cross-referencing older articles. We restricted our search to articles published after the year 2000 and written in or translated to the English language.

We present the following article in accordance with the Narrative Review reporting checklist (available at <http://dx.doi.org/10.21037/dmr-20-85>).

Anaesthetic management

There have been several papers reporting major concerns for the anaesthetist in robotic surgery (8,9). A key concern centres around poor access to the patient and airway (3). There are spatial and positioning restrictions due to bulky equipment and encroachment towards the head-end of the operating table thus limiting access. Once the robot has been positioned and docked, access to the patient is limited for the anaesthetist so the endotracheal tube and breathing circuit should be well secured to avoid disconnection. Any invasive lines and monitoring cables must be protected prior

to docking and should be secured carefully to prevent any displacement or damage (8). Another important point is that the position of the patient trolley cannot be changed unless the robot is de-docked. This creates a lag in time which in emergency situations that arise patient management will be delayed which could result in, or worsen the outcome of, critical incidents (9). Furthermore, movement of the patient while robotic instruments remain in position could lead to tearing of internal organs (10).

Positioning of the patient poses a few complexities (Figure 2) as different categories of robotic surgery may require positioning of the patient in steeper positions than in conventional laparoscopic surgery. These positions can result in patients requiring restraints to prevent sliding off the table. Extreme positions may even result in physiological or physical changes such as periorbital/facial oedema. Increases in central venous pressure from the Trendelenburg position and pneumoperitoneum will result from an increase in intracranial pressure and capillary leak resulting in cerebral oedema. Corneal abrasions can result from poor lid closure as a result of periorbital oedema, or injury from hanging cables and drapes that overly the eye area. Proper eye protection is essential, especially when the surgical drapes prevent optimal visualization of patients.

Prior to docking the anaesthetist should check the patient position and once docked attention should be paid to the robotic arms to prevent pressure injuries. One study showed that positioning injuries accounted for 6.6% of 334 robot-assisted adult complications during urological procedures. Longer operation times and inherent patient comorbidities were found to be significant risk factors (9).

Robotic surgeries regarding intrathoracic or intra-abdominal pathologies require the use of pneumoperitoneum. The resulting potential complications are gas embolism, pneumomediastinum and subcutaneous emphysema.

Urological surgery

Nephrectomy

Minervini *et al.* reported that robot-assisted partial nephrectomy (RAPN) was associated with a substantial reduction in blood loss and surgical complications, and with a shorter length of hospital stay compared to open procedures (11). RAPN has been used to reduce the risk of kidney injury by limiting the “warm ischaemic time” (11). To achieve this early unclamping has been attempted however, this is difficult to implement in laparoscopic surgery (11).

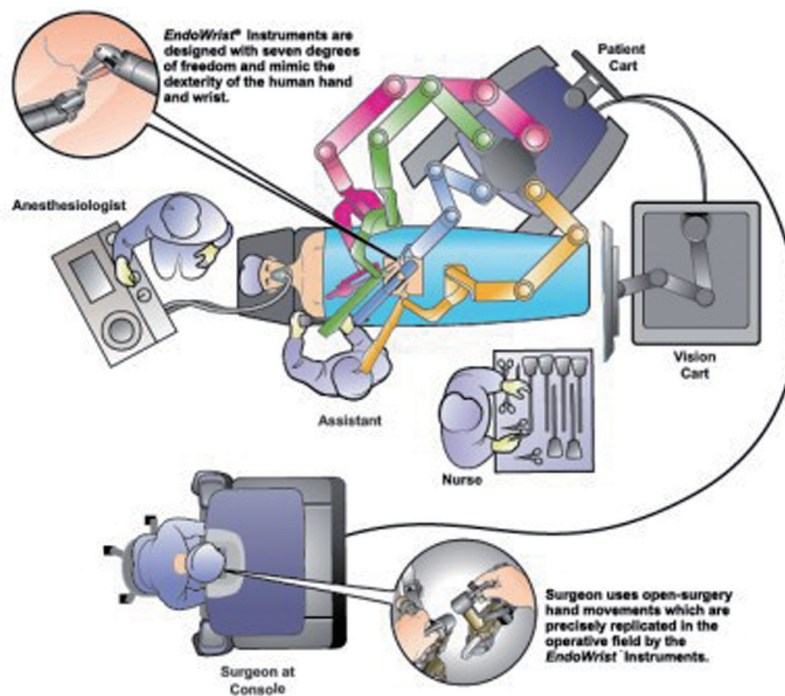


Figure 2 Theatre set up for robotic cystectomy. © Intuitive Surgical, Inc.

Prostatectomy

Binder performed the first robotic-assisted radical prostatectomy (RRP) in 2000 (12) at a time when most prostatectomies were performed as open procedures. There was a long learning curve with traditional laparoscopic prostatectomies due to the precise work involved in nerve sparing. Menon *et al.* found that RRP yielded a more rapid recovery and lower postoperative pain levels compared to open prostatectomies (13). Ahlering *et al.* found that in a series of 60 patients there was a shortened length of hospital stay (1.0 *vs.* 2.2 days), less blood loss (103 *vs.* 418 mL), while cancer control was not significantly different (14).

D'Alonzo confirmed this finding again in a retrospective study of 280 RRP patients showing reduced estimated blood loss (EBL) compared to open radical retropubic prostatectomy patients (853 *vs.* 317 mL). Twenty-four percent of open prostatectomy patients received red blood cell (RBC) transfusions, compared with 0.4% RRP patients. In the perioperative period, robotic-assisted prostatectomy patients received more antihypertensive agents (37% *vs.* 21%), and fewer vasopressors (63% *vs.* 78%) than did retropubic prostatectomy patients. The two groups had comparable morphine-equivalent opioid usage intraoperatively, but in the

post-anaesthetic care unit (PACU), robotic prostatectomy patients required fewer morphine equivalents (11.4 *vs.* 14.9 mg). The RRP patients had longer surgical times (296 *vs.* 193 min) but shorter PACU stays (113 *vs.* 143 min) and shorter hospital stays (44 *vs.* 56 hrs) (15).

Cystectomy

Liss (16) found that studies suggest the learning curve needed to reach an operative time of 6.5 hours for surgeons is around 20 patients. Randomized surgical trials comparing open and robotic techniques displayed comparable lymph node yield. The studies which were looked at showed reduced blood loss, reduced transfusion rates, earlier return of bowel function and reduced complications in an early small series of patients.

Li & colleagues reviewed 962 cases across one RCT, eight prospective studies, and four retrospective studies and suggested there were decreased complication rates for robotic cystectomies compared to open procedures alongside higher lymph node yield, reduced EBL, reduced need for blood transfusion and shorter length of hospital stay. Follow-up post-procedure focused on significant oncological

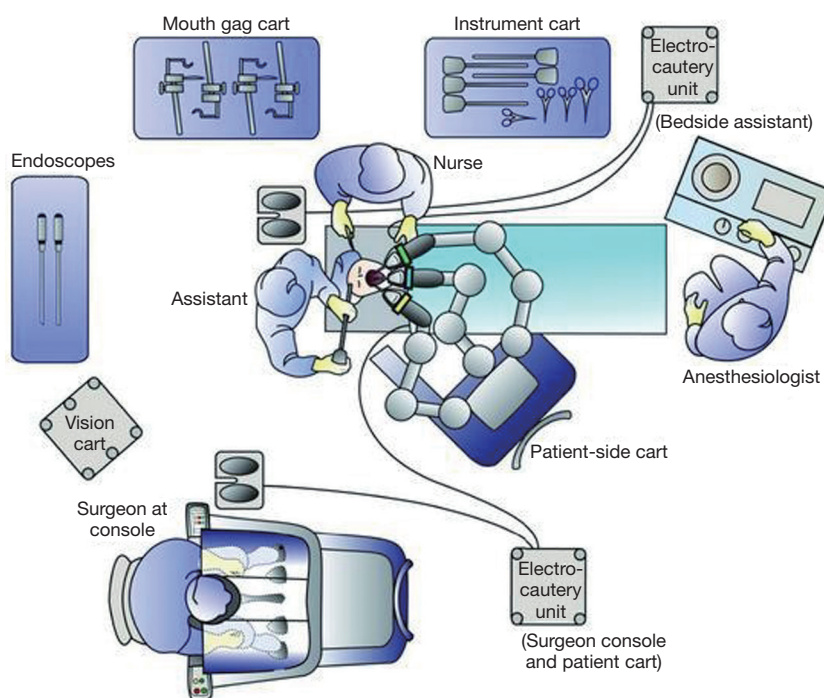


Figure 3 An example theatre setup for trans-oral robotic surgery (TORS). © Intuitive Surgical, Inc.

and survival data, with positive surgical margin rates as a substitute for oncologic control which were equivalent between open and robotic-assisted procedures (6).

Novara *et al.* noted that more high-grade complications at 90 days occurred in the robotic cystectomy group, however all other complication data were shown to be alike between robotic and open procedures. This epitomises some of the robust data which supports the use of robotic over open procedures when performed at a high-volume centre by an experienced surgeon (17).

Nix *et al.* (18) grouped 21 patients to robotic and 20 patients to open procedures and demonstrated non-inferiority of lymph node yield as the principal objective. Other outcomes demonstrated there were no differences in hospital stay or complications between the two groups. The robotic group had a lower mean EBL (258 *vs.* 575 mL), a shorter time to flatus and bowel movements (2.3 *vs.* 3.2 days; 3.2 *vs.* 4.3 days), and lower analgesic requirement, while the open group had a predictably shorter operative time (4.2 *vs.* 3.52 h).

Exclusion criteria have included morbid obesity, significant severe cardiovascular or pulmonary disease, or extra-vesical disease, which may lead to better outcomes for robotic cystectomy cohorts due to more favourable baseline

characteristics (19).

Indeed, case series comparing open to robotic cystectomy confirmed a selection bias toward less-advanced disease in robotic cohorts. Patients with a history of pelvic radiation were prevented from involvement in surgical series, and thus published results may not be generalizable to all patients (20).

Ear nose throat (ENT) surgery

Many ENT procedures are currently conducted with robot assistance, for example neck dissection, trans-oral robotic surgery (TORS), tongue base mucosectomy and thyroid surgery. Radical tonsillectomy, tongue base resection, supraglottic laryngectomy, and phono-microsurgery have been performed using the Da Vinci system.

TORS head + neck

The use of TORS is increasing (21). ENT operations commonly necessitate more expansive surgical exposure than the actual surgical field (*Figure 3*). One of the fundamental utilisations of the Da Vinci system, with a three-dimensional surgical field, is providing adequate depth using various endoscopes, cameras, and dual

eyepieces. Thus, scarring mandibulotomies can be avoided with TORS. Furthermore, the hazards of chemo-radiation may be decreased or prevented all together, and recovery of postoperative quality-of-life, such as speaking and eating, is shown to be more rapidly restored (21).

Indications for TORS are benign lesions of the larynx, pharynx, oral cavity and all T1 and T2 malignancies. Three arms of the robot are needed: instruments are held from the two lateral arms, and the central arm holds the camera. The surgeon places a mouth gag or retractor, and three sterile draped robotic arms are placed into their surgical positions (21).

Weinstein *et al.* published a study in which robot-assisted tonsillectomy was performed on 27 squamous cell carcinoma patients. Twenty-five of the 27 had negative cancer margins and 26 of the 27 patients were able to swallow postoperatively (22). Weinstein *et al.* (23) reported a successful swallowing rate of 97.6% at 12-month follow up. In Weinstein's report of advanced oropharyngeal carcinoma, regional control was obtained in 96% and distant control in 91% of cases at 18 months follow up. Moore *et al.* (24) described that all patients returned to normal swallowing post-procedure with follow-up time ranging from 3 months to 2 years.

Thyroidectomy

The trans-axillary robotic technique was first described in 2005 by Lobe *et al.* (25), where a hemi-thyroidectomy was successfully performed in a paediatric patient. In 2008, Miyano *et al.* described a bilateral axillary technique for removal of total thyroidectomy in two paediatric patients (26).

The principal published experience in robot-assisted thyroidectomy is by Kang *et al.* who developed the gasless trans-axillary technique (27) in a cohort of 338 patients. Robotic thyroidectomy using a trans-axillary approach leaves the scar in the axilla thus considered more aesthetically acceptable.

Robotic-assisted thyroidectomy has been linked with reduced postoperative pain, greater patient cosmetic approval, and reduced swallowing discomfort when compared to conventional surgery (27). A few cases of recurrent laryngeal nerve injury have been reported.

Benign TORS

McLeod and Melder, first published a case of marsupialization of a vallecular cyst (28). Vicini *et al.* evaluated the worth

of robot-assisted surgery in Obstructive Sleep Apnoea (OSA) (29). They looked at 20 patients who underwent a resection of the base of tongue, with some patients additionally having another procedure such as supraglottoplasty and uvulopalatoplasty. Overall patient satisfaction, evaluated by a Visual Analogue Scale (VAS, 0 to 100%) was 94%. All patients gained an acceptable swallowing ability within 2 weeks. There were no postoperative or operative complications (10 months of follow-up). This study exhibited the viability and security of robotic tongue base resection techniques

Gynaecological surgery

Myomectomy, hysterectomy, tubal re-anastomosis, radical hysterectomy, lymph node dissection, and sacro-colpopexy have all been accomplished using robotic surgical systems with hysterectomy being the most common gynaecological procedure performed with robotic assistance.

Case studies and retrospective cohort reviews have indicated that robot-assisted gynaecological surgeries resulted in decreased blood loss and smaller durations of hospital stay than laparoscopic or open surgeries.

Hysterectomy

Kho *et al.* (30) published an article with 91 patients undergoing robotic hysterectomy without lymphadenectomy. An extensive assortment of pathology, including ovarian malignancies, atypical uterine bleeding, and moderate to severe endometriosis, was included. Mean operative time was 127.8 minutes, with EBL of only 78.6 mL and hospital stay of 1.4 days. There were no bladder or ureteral injuries described.

Payne and Dauterive (31) published a retrospective review of 200 consecutive hysterectomy cases completed before and after execution of a robotics program. There were no statistically significant disparities in the characteristics of patients or the weights of the uterus between the two groups. The laparoscopic cohort of 100 patients compared to the robotic cohort had a two-fold higher intraoperative conversion rate to laparotomy (9% compared with 4%). The mean blood loss was also significantly lessened in the robotic group.

Myomectomy

Reynolds *et al.* (32) displayed a retrospective case-matched

analysis of open myomectomy compared with robot-assisted laparoscopic myomectomy. Despite finances and operative times being higher in the robotic group, patients had considerably reduced blood loss and did not require blood transfusion. Complication rates were greater in the laparotomy group. Length of hospital stay was considerably less in the robotic cohort (mean 1.5 days compared with 3.6 days).

Sacro-colpopexy

Elliott *et al.* (33) looked at long-term outcomes in 30 patients who underwent robotic-assisted sacro-colpopexy for post hysterectomy vaginal vault prolapse. The pre-sacral dissection was completed via laparoscopic surgery and the suturing was performed with robotic assistance. One patient developed recurrent grade 3 rectocele and another patient developed recurrent vaginal prolapse. Erosion of the mesh took place in two patients. Overall patient satisfaction was high. The mean operative time was 3.1 (range 2.2–4.8) hours. All patients except one were discharged from hospital on postoperative day 1 (33).

Robotic upper-gastrointestinal (GI) surgery

Upper-GI surgery is associated with a considerable rate of complication (34) and the advancements of minimally-invasive surgery and enhanced recovery are aimed at reducing these rates. Robotic-assisted surgery offers surgeons the ability to work more effectively in traditionally difficult surgical fields whilst maintaining a minimally invasive technique.

As upper-GI surgery is commonly isolated to specialist centres there have been fewer studies relating to the contribution of robots to patient outcomes. Robotic-assisted surgery offers itself well to upper-GI procedures owing to improved instrument movements facilitating more challenges aspects such as lymphadenectomy. A case-series of robotic-assisted laparoscopic subtotal gastrectomies with extended lymphadenectomy was published in 2007 and demonstrated that the introduction of robotics to this speciality was safe and successful with often higher lymph node yields (35,36). Evidence currently remains limited to case-series of varying cohort sizes but the strong suggestion is that robotic surgery offers at least comparable, if not improved outcomes over conventional laparoscopic surgery (37). Operating time was also found to be equivalent to, if not shorter, than conventional laparoscopic surgery, although

understandably longer than with an open technique (38). The surgical learning curve for using the robotic-assisted technique has been found to plateau at around 20 cases with operating time improving thereafter (39).

With regard to oesophagectomy surgery, the properties of robotic-assisted surgery again lend themselves well to this discipline where the need is to operate within the confined spaces of peritoneum and thorax. The MIRO and TIME trials both showed improved outcomes through the use of laparoscopic/thoracoscopic techniques (one or both) when compared to fully open surgery (40,41). Both studies, however, pointed out prolonged operating time and technical difficulties. The use of robotics in oesophagectomy was first described in 2003 using a transhiatal approach (42). Other case-series have since been published, the early papers noting a high rate of morbidity but which has improved over time (43-46). Results show comparable outcomes to open surgery in terms of oncological outcomes despite lower lymph node yields (47).

As with other robotic-assisted disciplines the anaesthetic considerations largely relate to patient positioning (oesophagectomy patients often requiring a semi-prone position) and physiological changes associated with insufflation of surgical fields. The use of more minimally-invasive techniques broadens the debates around the best analgesic technique to employ with reduced need for thoracic epidural analgesia (TEA) with their own associated morbidity.

Robotic lower-GI surgery

The benefits offered by robotic-surgery over conventional laparoscopic surgery may be less overt in lower-GI surgery owing largely to more capacious operating fields and other emerging technological advances including three-dimensional cameras for non-robotic surgery. One recent evaluation published in 2019 compared conventional *vs.* robotic-assisted surgery for rectal carcinoma and found no statistically significant differences in either the primary outcome (conversion to laparotomy) or secondary outcomes including circumferential resection margin positivity, complications and 30-day mortality. Costs in the robotic group were, however, significantly higher, even when removing acquisition and maintenance costs of the robots (48). Other sources suggest a caveat to this for patients in whom surgery is likely to be more technically challenging (49). Older studies and meta-analyses show varying results when comparing robotic *vs.* conventional laparoscopic

surgery with outcomes favouring robotics in areas such as conversion to laparotomy, hospital length of stay, urogenital outcomes and overall complications (50-54). Operative time was largely increased in these studies, however. The impact of cost, as well as operating time, are also thought to be reduced with increased experience of robotic surgery (55). The overall message from current trials is that robotic-assisted surgery is safe in lower-GI cases as well as offering enhanced educational benefit through the use of the dual-console system available with current robotic systems. Future systems are hoped to show further benefit over conventional laparoscopic surgery through enhanced technologies aimed at improving the ability of surgeons to be able to perform optimally.

The future of robotic surgery

Ongoing developments in the world of robotic-assisted surgery are aimed towards improving the existing advantages of the medium—visualisation of the field, dexterity of surgical instruments etc.—alongside the introduction of novel technologies which should enhance the ability of a surgeon to perform a procedure.

Current systems largely require multiple entry sites for the surgical instruments alongside the camera. Single-entry systems are already in use, particularly in trans-oral surgery, and are hoped to become more commonplace in other specialities to further reduce the quantity of surgical incisions (56).

Haptic feedback, the ability for surgeons to receive tactile feedback from the robotic instruments during surgery, is being widely developed and available on some currently less well-known systems (57,58). Eye-tracking cameras and the use of machine-learning are also being developed or recently available (57,59). Other areas of focus for development include more light-weight systems and miniaturized systems (60,61).

Conclusions

Robotic surgery has seen mammoth advancement over the past few decades in numerous arenas. Nevertheless, we are likely to see further developments as the technology continues to mature and additional improvements arise. It has been just over two decades since robotic surgery was first introduced into the operating room. Developments in robotic surgery are also likely to continue as more surgeons become proficient in this technique and more patients

seek minimally invasive surgical operations. Well-designed studies with precise long-term clinical outcomes, including complications, costs, pain, return to daily activity, and quality of life, are needed to completely evaluate the value of this technology.

The movement towards the use of minimally invasive surgery has had an influence on the way new technology is considered, developed, and integrated into clinical practice. Robotic surgery is continuing to advance and is overcoming its constraints whilst continuing to improve outcomes, such as reducing hospital stays, blood loss, use of opiates and infection rates, and allowing for better cosmetic results and patient satisfaction.

Acknowledgments

Funding: None.

Footnote

Provenance and Peer Review: This article was commissioned by the Guest Editors (Chris Jones and Leigh Kelliher) for the series “Perioperative Care of the Cancer Patient” published in *Digestive Medicine Research*. The article has undergone external peer review.

Reporting Checklist: The authors have completed the Narrative Review reporting checklist. Available at <http://dx.doi.org/10.21037/dmr-20-85>

Peer Review File: Available at <http://dx.doi.org/10.21037/dmr-20-85>

Conflicts of Interest: Both authors have completed the ICMJE uniform disclosure form (available at <http://dx.doi.org/10.21037/dmr-20-85>). The series “Perioperative Care of the Cancer Patient” was commissioned by the editorial office without any funding or sponsorship. The authors have no other conflicts of interest to declare.

Ethical Statement: The authors are accountable for all aspects of the work in ensuring that questions related to the accuracy or integrity of any part of the work are appropriately investigated and resolved.

Open Access Statement: This is an Open Access article distributed in accordance with the Creative Commons Attribution-NonCommercial-NoDerivs 4.0 International

License (CC BY-NC-ND 4.0), which permits the non-commercial replication and distribution of the article with the strict proviso that no changes or edits are made and the original work is properly cited (including links to both the formal publication through the relevant DOI and the license). See: <https://creativecommons.org/licenses/by-nc-nd/4.0/>.

References

1. Kenngott HG, Muller-Stich BP, Reiter MA, et al. Robotic suturing: technique and benefit in advanced laparoscopic surgery. *Minim Invasive Ther Allied Technol* 2008;17:160-7.
2. Giri S, Sarkar DK. Current status of robotic surgery. *Indian J Surg* 2012;74:242-7.
3. Sullivan MJ, Frost EA, Lew MW. Anesthetic care of the patient for robotic surgery. *Middle East J Anaesthesiol* 2008;19:967-82.
4. Ashrafian H, Clancy O, Grover V, et al. The evolution of robotic surgery: surgical and anaesthetic aspects. *Br J Anaesth* 2017;119:i72-84.
5. Irvine M, Patil V. Anaesthesia for robot-assisted laparoscopic surgery. *Cont Educ Anaesth Crit Care Pain* 2009;9:125-9.
6. Li K, Lin T, Fan X, et al. Systematic review and meta-analysis of comparative studies reporting early outcomes after robot-assisted radical cystectomy versus open radical cystectomy. *Cancer Treat Rev* 2013;39:551-60.
7. Daneshmand S, Ahmadi H, Schuckman AK, et al. Enhanced recovery protocol after radical cystectomy for bladder cancer. *J Urol* 2014;192:50-5.
8. Baltayan S. A brief review: anesthesia for robotic prostatectomy. *J Robot Surg* 2008;2:59.
9. Mills JT, Burris MB, Warburton DJ, et al. Positioning injuries associated with robotic assisted urological surgery. *J Urol* 2013;190:580-4.
10. Steenwyk B, Lyerly R 3rd. Advancements in robotic-assisted thoracic surgery. *Anesthesiol Clin* 2012;30:699-708.
11. Minervini A, Vittori G, Antonelli A, et al. Open versus robotic-assisted partial nephrectomy: a multicenter comparison study of perioperative results and complications. *World J Urol* 2014;32:287-93.
12. Binder J, Kramer W. Robotically-assisted laparoscopic radical prostatectomy. *BJU Int* 2001;87:408-10.
13. Menon M, Tewari A, Baize B, et al. Prospective comparison of radical retropubic prostatectomy and robot-assisted anatomic prostatectomy: the Vattikuti Urology Institute experience. *Urology* 2002;60:864-8.
14. Ahlering TE, Woo D, Eichel L, et al. Robot-assisted versus open radical prostatectomy: a comparison of one surgeon's outcomes. *Urology* 2004;63:819-22.
15. D'Alonzo RC, Gan TJ, Moul JW, et al. A retrospective comparison of anesthetic management of robot-assisted laparoscopic radical prostatectomy versus radical retropubic prostatectomy. *J Clin Anesth* 2009;21:322-8.
16. Liss MA, Kader AK. Robotic-assisted laparoscopic radical cystectomy: history, techniques and outcomes. *World J Urol* 2013;31:489-97.
17. Novara G, Catto JW, Wilson T, et al. Systematic review and cumulative analysis of perioperative outcomes and complications after robot-assisted radical cystectomy. *Eur Urol* 2015;67:376-401.
18. Nix J, Smith A, Kurpad R, et al. Prospective randomized controlled trial of robotic versus open radical cystectomy for bladder cancer: perioperative and pathologic results. *Eur Urol* 2010;57:196-201.
19. Wang GJ, Barocas DA, Raman JD, et al. Robotic vs open radical cystectomy: prospective comparison of perioperative outcomes and pathological measures of early oncological efficacy. *BJU Int* 2008;101:89-93.
20. Sandberg JM, Hemal AK. Robot-assisted laparoscopic radical cystectomy with complete intracorporeal urinary diversion. *Asian J Urol* 2016;3:156-66.
21. Chi JJ, Mandel JE, Weinstein GS, et al. Anesthetic considerations for transoral robotic surgery. *Anesthesiol Clin* 2010;28:411-22.
22. Weinstein GS, O'Malley BW Jr, Snyder W, et al. Transoral robotic surgery: radical tonsillectomy. *Arch Otolaryngol Head Neck Surg* 2007;133:1220-6.
23. Weinstein GS, O'Malley BW Jr, Cohen MA, et al. Transoral robotic surgery for advanced oropharyngeal carcinoma. *Arch Otolaryngol Head Neck Surg* 2010;136:1079-85.
24. Moore EJ, Olsen KD, Kasperbauer JL. Transoral robotic surgery for oropharyngeal squamous cell carcinoma: a prospective study of feasibility and functional outcomes. *Laryngoscope* 2009;119:2156-64.
25. Lobe TE, Wright SK, Irish MS. Novel uses of surgical robotics in head and neck surgery. *J Laparoendosc Adv Surg Tech A* 2005;15:647-52.
26. Miyano G, Lobe TE, Wright SK. Bilateral transaxillary endoscopic total thyroidectomy. *J Pediatr Surg* 2008;43:299-303.
27. Kang SW, Jeong JJ, Yun JS, et al. Robot-assisted endoscopic surgery for thyroid cancer: experience with the first 100 patients. *Surg Endosc* 2009;23:2399-406.

28. McLeod IK, Melder PC. Da Vinci robot-assisted excision of a vallecular cyst: a case report. *Ear Nose Throat J* 2005;84:170-2.
29. Vicini C, Dallan I, Canzi P, et al. Transoral robotic surgery of the tongue base in obstructive sleep Apnea-Hypopnea syndrome: anatomic considerations and clinical experience. *Head Neck* 2012;34:15-22.
30. Kho RM, Hilger WS, Hentz JG, et al. Robotic hysterectomy: technique and initial outcomes. *Am J Obstet Gynecol* 2007;197:113.e1-4.
31. Payne TN, Dauterive FR. A comparison of total laparoscopic hysterectomy to robotically assisted hysterectomy: surgical outcomes in a community practice. *J Minim Invasive Gynecol* 2008;15:286-91.
32. Reynolds RK, Burke WM, Advincula AP. Preliminary experience with robot-assisted laparoscopic staging of gynecologic malignancies. *JSLs* 2005;9:149-58.
33. Elliott DS, Frank I, Dimarco DS, et al. Gynecologic use of robotically assisted laparoscopy: sacrocolpopexy for the treatment of high-grade vaginal vault prolapse. *Am J Surg* 2004;188:52S-6S.
34. Bhagat R, Bronsert MR, Juarez-Colunga E, et al. Postoperative complications drive unplanned readmissions after esophagectomy for cancer. *Ann Thorac Surg* 2018;105:1476-82.
35. Anderson C, Ellenhorn J, Hellan M, et al. Pilot series of robot-assisted laparoscopic subtotal gastrectomy with extended lymphadenectomy for gastric cancer. *Surg Endosc* 2007;21:1662-6.
36. Kim HI, Han SU, Yang HK, et al. Multicenter prospective comparative study of robotic versus laparoscopic gastrectomy for gastric adenocarcinoma. *Ann Surg* 2016;263:103-9.
37. Qureshi YA, Mohammadi B. Robotic oesophago-gastric cancer surgery. *Ann R Coll Surg Engl* 2018;100:23-30.
38. Tokunaga M, Sugisawa N, Kondo J, et al. Early phase II study of robot-assisted distal gastrectomy with nodal dissection for clinical stage IA gastric cancer. *Gastric Cancer* 2014;17:542-7.
39. Kim KM, An JY, Kim HI, et al. Major early complications following open, laparoscopic and robotic gastrectomy. *Br J Surg* 2012;99:1681-7.
40. Briez N, Piessen G, Bonnetain F, et al. Open versus laparoscopically-assisted oesophagectomy for cancer: a multicentre randomised controlled phase III trial - the MIRO trial. *BMC Cancer* 2011;11:310.
41. Biere SS, Maas KW, Bonavina L, et al. Traditional invasive vs. minimally invasive esophagectomy: a multi-center, randomized trial (TIME-trial). *BMC Surg* 2011;11:2.
42. Horgan S, Berger RA, Elli EF, et al. Robotic-assisted minimally invasive transhiatal esophagectomy. *Am Surg* 2003;69:624-6.
43. de la Fuente SG, Weber J, Hoffe SE, et al. Initial experience from a large referral center with robotic-assisted Ivor Lewis esophagogastrectomy for oncologic purposes. *Surg Endosc* 2013;27:3339-47.
44. van Hillegersberg R, Boone J, Draaisma WA, et al. First experience with robot-assisted thoracoscopic esophagolymphadenectomy for esophageal cancer. *Surg Endosc* 2006;20:1435-9.
45. Puntambekar S, Kenawadekar R, Kumar S, et al. Robotic transthoracic esophagectomy. *BMC Surg* 2015;15:47.
46. van der Sluis PC, Ruurda JP, Verhage RJ, et al. Oncologic long-term results of robot-assisted minimally invasive thoraco-laparoscopic esophagectomy with two-field lymphadenectomy for esophageal cancer. *Ann Surg Oncol* 2015;22 Suppl 3:S1350-6.
47. Park SY, Kim DJ, Yu WS, et al. Robot-assisted thoracoscopic esophagectomy with extensive mediastinal lymphadenectomy: experience with 114 consecutive patients with intrathoracic esophageal cancer. *Dis Esophagus* 2016;29:326-32.
48. Jayne D, Pigazzi A, Marshall H, et al. Robotic-assisted surgery compared with laparoscopic resection surgery for rectal cancer: the ROLARR RCT. Southampton: NIHR Journals Library, 2019.
49. Matsuyama T, Kinugasa Y, Nakajima Y, et al. Robotic-assisted surgery for rectal cancer: Current state and future perspective. *Ann Gastroenterol Surg* 2018;2:406-12.
50. Prete FP, Pezzolla A, Prete F, et al. Robotic versus laparoscopic minimally invasive surgery for rectal cancer: a systematic review and meta-analysis of randomized controlled trials. *Ann Surg*. 2018;267:1034-46.
51. Li X, Wang T, Yao L, et al. The safety and effectiveness of robot-assisted versus laparoscopic TME in patients with rectal cancer: a meta-analysis and systematic review. *Medicine (Baltimore)* 2017;96:e7585.
52. Cui Y, Li C, Xu Z, et al. Robot-assisted versus conventional laparoscopic operation in anus-preserving rectal cancer: a meta-analysis. *Ther Clin Risk Manag* 2017;13:1247-57.
53. Sun Y, Xu H, Li Z, et al. Robotic versus laparoscopic low anterior resection for rectal cancer: a meta-analysis. *World J Surg Oncol* 2016;14:61.
54. Xiong B, Ma L, Huang W, et al. Robotic versus laparoscopic total mesorectal excision for rectal cancer:

- a meta-analysis of eight studies. *J Gastrointest Surg* 2015;19:516-26.
55. Byrn JC, Hrabe JE, Charlton ME. An initial experience with 85 consecutive robotic-assisted rectal dissections: improved operating times and lower costs with experience. *Surg Endosc* 2014;28:3101-7.
 56. Rassweiler JJ, Teber D. Advances in laparoscopic surgery in urology. *Nat Rev Urol* 2016;13:387-99.
 57. Beasley RA. Medical robots: current systems and research directions. *J Robot* 2012;2012:401613.
 58. Fanfani F, Monterossi G, Fagotti A, et al. The new robotic TELELAP ALF-X in gynecological surgery: single-center experience. *Surg Endosc* 2016;30:215-21.
 59. SyncThink Goes for Magic Leap to Get into AR. [cited 2020 Apr 28]. Available online: <https://www.mddionline.com/digital-health/syncthink-goes-magic-leap-get-ar>
 60. Peters BS, Armijo PR, Krause C, et al. Review of emerging surgical robotic technology. *Surg Endosc* 2018;32:1636-55.
 61. Khandalavala K, Shimon T, Flores L, et al. Emerging surgical robotic technology: a progression toward microbots. *Ann Laparosc Endosc Surg* 2020;5:3.

doi: 10.21037/dmr-20-85

Cite this article as: Jeyarajah K, Morrison B. A narrative review of the role of robotics in cancer surgery. *Dig Med Res* 2020;3:61.