



Rectal carcinoid in a 30-year-old male: a review of current treatment options

Sean Patterson¹, Olutayo Sogunro²

¹Department of Medical Education, University of New England College of Osteopathic Medicine, Biddeford, ME, USA; ²Department of Surgery, Hartford HealthCare: St. Vincent's Medical Center, Bridgeport, CT, USA

Correspondence to: Sean Patterson, BA, MA. University of New England College of Osteopathic Medicine, 11 Hills Beach Rd., Biddeford, ME 04005, USA. Email: sean_elizabeth_patterson@yahoo.com.

Abstract: Carcinoid tumors are neuroendocrine tumors that originate from enterochromaffin cells and primarily affect the gastrointestinal tract. They are commonly asymptomatic and found on routine screening colonoscopy. Histologically, these tumors stain positive for CD56, synaptophysin, or chromogranin A, which suggests their neuroendocrine origin. Approximately 20% of carcinoid tumors are found in the rectum. Once a rectal carcinoid is identified, it must be evaluated for the likelihood of metastasis in order to determine the course of treatment. We present a case report of a 30-year-old male with a carcinoid tumor of the rectum that was discovered on a follow-up colonoscopy performed after the patient was treated for sigmoid diverticulitis with a micro-perforation. Because carcinoid tumors are often identified on screening colonoscopy, it is not usually discovered in patients below the age of 50. This suggests that these slow growing tumors may exist in patients of younger age groups, but do not get officially diagnosed until they start getting screened. Our patient's carcinoid tumor was removed via endoscopic mucosal resection, or EMR, however, there are many different options to consider when removing a rectal carcinoid, ranging from local endoscopic resection to radical surgical excision. This case report provides a review of EMR, the treatment used in our patient, and compares this technique to several other treatment options for rectal carcinoid removal.

Keywords: Case report; carcinoid; endoscopic resection; neuroendocrine tumor

Received: 16 August 2020; Accepted: 10 December 2020; Published: 30 December 2020.

doi: 10.21037/dmr-20-123

View this article at: <http://dx.doi.org/10.21037/dmr-20-123>

Introduction

Carcinoid tumors are neuroendocrine tumors that originate from enterochromaffin cells and primarily affect the gastrointestinal tract (1). They most commonly affect the small intestine, rectum, and appendix. These neuroendocrine tumors are identified with immunohistochemical staining for markers like synaptophysin, CD56, or chromogranin A. A study that analyzed 114 intestinal neuroendocrine neoplasms, the majority of which were in the rectum, found that the positive rate of immunohistochemical staining for synaptophysin, CD56, and chromogranin A was 97.4%, 75.4%, and 43% respectively (2). Approximately 20% of these carcinoid tumors are found in the rectum (3). Rectal

carcinoids are commonly asymptomatic and are identified on routine colonoscopy (3). Although rectal carcinoid tumors are slow-growing and rare as compared to rectal carcinomas, they are still cancerous and possess the ability to metastasize (4). The 5-year survival of patients with rectal carcinoids was found to be 86% (4).

Once a rectal carcinoid is identified with biopsy, it must be evaluated for the likelihood of metastasis to determine the course of treatment. Carcinoid tumors can be analyzed for depth of invasion with both transrectal ultrasonography and computed tomography (CT) scan imaging; however, ultrasound is more accurate at assessing depth of invasion compared to CT (5). Smaller tumors without adverse features are often treated with endoscopic excision, while larger or more invasive tumors may require radical surgical

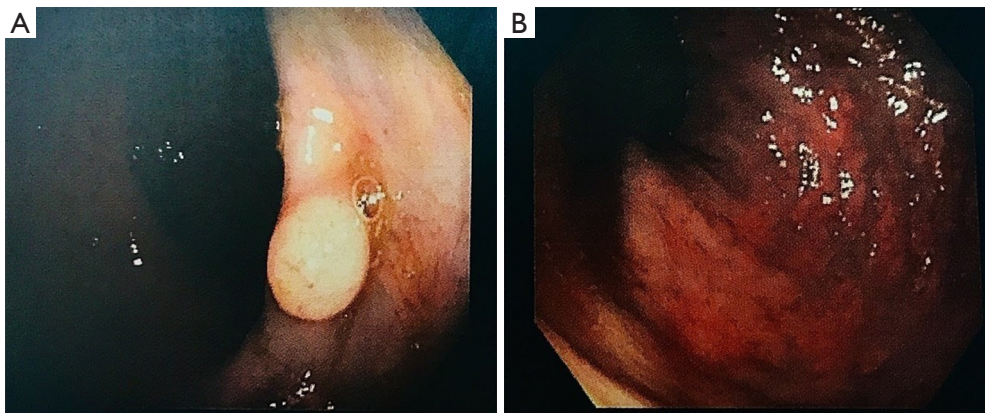


Figure 1 Rectal images on colonoscopy. (A) Rectal polyp at 10 cm from the anal verge on endoscopy; (B) normal retroflexed view of rectum.

excision (4).

We present a case of a 30-year-old male with a carcinoid tumor of the rectum that was treated with endoscopic mucosal resection, or EMR, because the depth of his carcinoid tumor was limited to the mucosa. As these types of tumors are indolent and slow growing, they are often found on screening colonoscopy, making people over 50 years old the most affected age group. Finding this cancer in a 30-year-old patient is very rare, making this case report unique and suggesting that this cancer may be present in those of younger age groups, but is never found. The patient gave written informed consent for publication of this report. We present the following case in accordance with the CARE reporting checklist (available at <http://dx.doi.org/10.21037/dmr-20-123>).

Case presentation

A 30-year-old male presented to the emergency department with a 3-day history of left lower quadrant abdominal pain. He reported fevers, chills, and headaches as accompanying symptoms. He was febrile on admission and was worked up with laboratory work and a CT scan of the abdomen and pelvis, which revealed leukocytosis and evidence of sigmoid diverticulitis with a micro-perforation, respectively. There was a phlegmon along the wall of the colon but no drainable abscess. He was admitted as an inpatient and started on intravenous antibiotics, given bowel rest, and serial abdominal exams were performed. He responded well to non-operative conservative therapy, and his leukocytosis resolved, pain improved, and he tolerated a diet. He was discharged on hospital day #4 on a 10-day course of oral antibiotics, to complete a 14-day total course. He had an

outpatient colonoscopy 10 weeks after the hospitalization which revealed some residual minimal sigmoid diverticulitis and a rectal polyp at 10 cm from the anal verge. The polyp appeared sessile, light pink in color consistent with the surrounding mucosa, however, it was relatively broad based, measuring approximately 1 cm at the base (see *Figure 1*). The polyp was removed endoscopically with cold biopsy forceps and sent as a specimen. Pathology revealed a low-grade carcinoid (neuroendocrine) tumor, positive for CD56 and synaptophysin, and negative for chromogranin. Different treatment options were discussed with the patient and we elected for referral to gastroenterology for EMR of the carcinoid tumor. The procedure was successful, and pathology revealed that the low-grade carcinoid tumor was resected in its entirety with negative margins. Postoperatively, the patient did very well. All procedures performed in studies involving human participants were in accordance with the ethical standards of the institutional and/or national research committee(s) and with the Helsinki Declaration (as revised in 2013). Written informed consent was obtained from the patient.

Discussion

Carcinoid tumors were first described in 1867, but the term carcinoid, meaning “carcinoma-like”, was not used until 1907 (4). Rectal carcinoid tumors are rare, making up only 1.1% to 1.3% of all rectal tumors; however, the incidence of rectal carcinoids is increasing, most likely due to the increased availability of screening endoscopy (6). Only a small portion of rectal carcinoids are identified during evaluation of symptoms of carcinoid syndrome, including flushing, diarrhea, rectal bleeding, and abdominal pain (3).

Carcinoid syndrome is a paraneoplastic syndrome caused by secretion of serotonin from the tumor, which is seen more commonly in patients with larger or more invasive carcinoids (7). Our patient had a less invasive tumor and did not have carcinoid syndrome.

The term “carcinoid” implies that the tumor is of neuroendocrine origin and is well differentiated, as opposed to adenocarcinoma, another more common type of rectal cancer, which is poorly differentiated and therefore associated with a poorer prognosis (3). Although rectal carcinoid tumors are more often benign as compared to rectal adenocarcinomas, they are still cancerous and do have the ability to metastasize (4). Rectal carcinoids are more likely to metastasize if they are >10 mm in size, have an atypical surface, invade the muscular, perineural, or lymphovascular layers, or are found in patients over the age of 60 years old (4). After a carcinoid tumor has been identified by biopsy, an assessment of regional lymph node or distant metastasis should be conducted with chest X-ray, CT scan, or positron emission tomography (PET) scan imaging. The most common site for distant metastasis of rectal carcinoids is the liver (8). Survival in patients with rectal carcinoids without metastasis was better than those with rectal adenocarcinomas, but when the carcinoid had metastasized, the survival rate was similar between both of these types of rectal cancer (8).

The best course of treatment for rectal carcinoid tumors is controversial. It has been previously accepted that tumors less than 16 mm in size without adverse features can be treated with local excision, while tumors greater than 16 mm or those with greater risk of metastasis should be surgically excised (4). However, with recent advancements and more research in endoscopic resection, surgeons are opting for less invasive, but equally efficacious, local excision in lieu of radical surgery and its associated risks.

There are several endoscopic options that range in their level of invasiveness. EMR involves only a dissection of the rectal mucosa, sparing the submucosa. This procedure is less time consuming and less invasive than other methods (1). However, many rectal carcinoid tumors invade the submucosa, making endoscopic submucosal dissection (ESD) a more comprehensive approach. As a more invasive technique, ESD has significantly greater procedure time and hospitalization stays, as well as a higher risk of complications like bleeding and perforation (1). ESD is also a more technically difficult procedure to perform and therefore requires a more experienced endoscopist (6). ESD has higher *en bloc* resection rates, lower recurrence rates,

and more accurate pathological estimations than EMR, making it a more comprehensive treatment approach than EMR alone (1).

However, there are modifications to the EMR approach that utilize aspects of ESD, while saving time and costs. One study compared the outcomes of conventional EMR to strip biopsy using a two-channel endoscope and EMR with circumferential incision (CI-EMR). CI-EMR (referred to as EMR-P in the Lee study) utilizes the ESD circumferential incision into the submucosa, but then the tumor is snared and resected like in the EMR approach (9). This retrospective study showed that standard EMR had significantly lower histopathologic complete resection rates as compared to strip biopsy & CI-EMR, suggesting that these modifications to conventional EMR can increase their efficacy and curability of rectal carcinoids (9).

Modifications to the EMR approach may increase their efficacy as compared to conventional EMR, but what about as compared to ESD? A study done by Chen *et al.* found that CI-EMR saves time and cost, is technically simpler, less invasive, and as effective as ESD in terms of *en bloc* resection and histological resection rates (1). EMR with endoloop ligation (EMR-LC) is another comparable treatment option to ESD, as it leads to ischemic necrosis around the tumor margin, which further clears local lesions and seals the wound to prevent bleeding (10). These modified EMR techniques are very promising, and may be performed faster by less experienced endoscopists, while maintaining comparable efficacy to the more comprehensive ESD technique.

However, one retrospective study showed that ESD had greater complete resection rates than CI-EMR, which is clinically important as it avoids the need for further treatment that can provoke anxiety for patients and can be more technically difficult to perform due to submucosal fibrosis from previous excisions (11). Another retrospective study found that EMR with cap aspiration (EMR-C) and EMR with band ligation (EMR-L) were time-saving options with lower complication rates. They also showed comparable histologic complete resection rates to ESD, but ultimately ESD showed higher *en bloc* resection rates and more accurate pathological estimation, suggesting that there are benefits to the more invasive and time consuming ESD technique (12).

Transanal local excision (TALE) is an option for rectal carcinoid tumors that are not amenable to conventional endoscopic removal. This technique requires spinal anesthesia and therefore puts the patient at risk for acute retention of urine (AROU), but it provides a deeper vertical

resection margin than ESD and may be the treatment of choice for scar embedded rectal carcinoids (13).

The endoscopic techniques discussed above are recommended over radical surgical excision in tumors that are <2 cm in size, while tumors >2 cm should be treated with radical resection according to the National Comprehensive Cancer Network (NCCN) guidelines (3). Recent studies have examined whether the use of rectal resection is actually necessary in these larger carcinoids. A large retrospective study examined over 1,900 patients with rectal carcinoids grouped as small (<2 cm), intermediate (2.1–4.0 cm), or large (>4 cm) tumors. Nearly half of the intermediate and large tumors were treated with local resection against NCCN guidelines (3). No difference was found in the overall survival of patients treated with local and radical excision, and local excision was actually associated with improved survival for tumors >4 cm in size, showing that local excision should be considered even for large tumors, as long as they don't have adverse features like muscular or lymphovascular invasion (2).

Another large retrospective study showed that surgical resection was associated with worse 10-year overall survival and disease specific survival compared to local excision or biopsy alone; however, they admit that these differences could be due to uncaptured clinical factors that caused the surgeon to choose radical resection over local excision (7). Another group examined rectal carcinoids based on their risk of metastasis, with low-risk tumors being those >10 mm without lymphovascular invasion and high-risk tumors being those >10 mm or ones with lymphovascular invasion (14). High-risk tumors showed no difference in the rate of recurrence between patients undergoing local or radical resection, suggesting that local excision should be considered even in larger, high-risk tumors as it is safe and equally efficacious (14).

Conclusions

Overall, the treatment for rectal carcinoid tumors must be selected on a case-by-case basis. Based on several retrospective studies, local endoscopic excision is safer and equally effective compared to radical resection and should be considered as a first option regardless of tumor size or risk of metastasis. Which endoscopic technique should be chosen is still controversial, but modified EMR techniques with aspects of ESD offer a safe and time saving, yet effective, treatment option for rectal carcinoids. Endoscopists must weigh their own technical skill and the

risk of muscular or lymphovascular invasion when deciding between the many endoscopic resection options.

Our patient presented with acute diverticulitis, and the carcinoid tumor was discovered during a follow-up colonoscopy. His tumor was 10 mm in size, making it amenable to endoscopic treatment. Because he was only 30 years old, the less invasive EMR approach was favored and performed to preserve his quality of life. Although EMR has lower *en bloc* resection rates, higher recurrence rates, and less accurate pathological estimations as compared to ESD, it is less time consuming and requires shorter hospital stays, and, in this case, was sufficient to remove the entire tumor with negative margins. This case shows us that EMR is an acceptable and effective approach for tumors equal to or less than 10 mm and can remove low-risk tumors in their entirety.

Acknowledgments

We would like to acknowledge the patient in this case who was kind enough to allow us to utilize his experience to further medical research.

Funding: None.

Footnote

Reporting Checklist: The authors have completed the CARE reporting checklist. Available at <http://dx.doi.org/10.21037/dmr-20-123>

Peer Review File: Available at <http://dx.doi.org/10.21037/dmr-20-123>

Conflicts of Interest: All authors have completed the ICMJE uniform disclosure form (available at <http://dx.doi.org/10.21037/dmr-20-123>). The authors have no conflicts of interest to declare.

Ethical Statement: The authors are accountable for all aspects of the work in ensuring that questions related to the accuracy or integrity of any part of the work are appropriately investigated and resolved. All procedures performed in studies involving human participants were in accordance with the ethical standards of the institutional and/or national research committee(s) and with the Helsinki Declaration (as revised in 2013). Written informed consent was obtained from the patient.

Open Access Statement: This is an Open Access article distributed in accordance with the Creative Commons Attribution-NonCommercial-NoDerivs 4.0 International License (CC BY-NC-ND 4.0), which permits the non-commercial replication and distribution of the article with the strict proviso that no changes or edits are made and the original work is properly cited (including links to both the formal publication through the relevant DOI and the license). See: <https://creativecommons.org/licenses/by-nc-nd/4.0/>.

References

1. Chen R, Liu X, Sun S, et al. Comparison of Endoscopic Mucosal Resection With Circumferential Incision and Endoscopic Submucosal Dissection for Rectal Carcinoid Tumor. *Surg Laparosc Endosc Percutan Tech* 2016;26:e56-61.
2. Gao W, Liu SM, Lu HZ, et al. Analysis of clinicopathological features of intestinal neuroendocrine neoplasms. *Zhonghua Zhong Liu Za Zhi* 2012;34:450-6.
3. Ezekian B, Adam MA, Turner MC, et al. Local excision results in comparable survival to radical resection for early-stage rectal carcinoid. *J Surg Res* 2018;230:28-33.
4. McDermott FD, Heeney A, Courtney D, et al. Rectal carcinoids: a systematic review. *Surg Endosc* 2014;28:2020-6.
5. Kim NK, Kim MJ, Yun SH, et al. Comparative study of transrectal ultrasonography, pelvic computerized tomography, and magnetic resonance imaging in preoperative staging of rectal cancer. *Dis Colon Rectum* 1999;42:770-5.
6. Kaneko H, Hirasawa K, Koh R, et al. Treatment outcomes of endoscopic resection for rectal carcinoid tumors: an analysis of the resectability and long-term results from 46 consecutive cases. *Scand J Gastroenterol* 2016;51:1489-94.
7. McConnell YJ. Surgical management of rectal carcinoids: trends and outcomes from the Surveillance, Epidemiology, and End Results database (1988 to 2012). *Am J Surg* 2016;211:877-85.
8. Konishi T, Watanabe T, Kishimoto J, et al. Prognosis and risk factors of metastasis in colorectal carcinoids: results of a nationwide registry over 15 years. *Gut* 2007;56:863-8.
9. Lee HJ, Kim SB, Shin CM, et al. A comparison of endoscopic treatments in rectal carcinoid tumors. *Surg Endosc* 2016;30:3491-8.
10. Zhang DG, Luo S, Xiong F, et al. Endoloop ligation after endoscopic mucosal resection using a transparent cap: A novel method to treat small rectal carcinoid tumors. *World J Gastroenterol* 2019;25:1259-65.
11. Zhang J, Liu M, Li H, et al. Comparison of endoscopic therapies for rectal carcinoid tumors: Endoscopic mucosal resection with circumferential incision versus endoscopic submucosal dissection. *Clin Res Hepatol Gastroenterol* 2018;42:24-30.
12. Choi CW, Park SB, Kang DH, et al. The clinical outcomes and risk factors associated with incomplete endoscopic resection of rectal carcinoid tumor. *Surg Endosc* 2017;31:5006-11.
13. Yan FH, Lou Z, Hu SJ, et al. Endoscopic submucosal dissection versus transanal local excision for rectal carcinoid: a comparative study. *World J Surg Oncol* 2016;14:162.
14. Shigeta K, Okabayashi K, Hasegawa H, et al. Long-term outcome of patients with locally resected high- and low-risk rectal carcinoid tumors. *J Gastrointest Surg* 2014;18:768-73.

doi: 10.21037/dmr-20-123

Cite this article as: Patterson S, Sogunro O. Rectal carcinoid in a 30-year-old male: a review of current treatment options. *Dig Med Res* 2020;3:74.