



Laparoscopic uterosacral ligament consolidation and fixation based on the sacrospinous ligament/coccygeus complex

Wu Huang, Cheng Chen, Zhiying Yang, Xiangbo Lan, Zhijiang Fang

Department of Obstetrics and Gynecology, Pidu District People's Hospital, Chengdu 611730, China

Correspondence to: Wu Huang. Director of Obstetrics and Gynecology, Pidu District People's Hospital, No. 666, Section 2, North Deyuan road, Pidu District, Chengdu 611730, China. Email: Huanglinpuyu@163.com.

Abstract: Here, we introduce a new type of surgery that we recently developed for middle pelvic prolapse: laparoscopic uterosacral ligament consolidation and fixation based on the sacrospinous ligament/coccygeus complex. This operation is characterized by the concepts of fixation and strengthening. For fixation, the sacral part of the uterine sacral ligament is sutured and fixed on the sacrospinous ligament/coccygeus complex. The uterosacral ligament neck is then sutured and fixed in the posterior dome or the posterior wall of the cervix to solve the problem of sacral ligament avulsion. For strengthening, the middle part of the uterosacral ligament is shortened and strengthened with a focus on solving the avulsion or relaxation of the uterosacral ligament from the attachment point, so as to restore the normal anatomical position of the pelvic organ and reduce recurrence. Because there is no change in the vaginal axial direction, this procedure can reduce the incidence of anterior vaginal wall prolapse. After the operation, the top of the vagina has a certain degree of movement to the surrounding area, especially an upward degree, which can improve the quality of sexual life.

Keywords: Uterosacral ligament; sacrospinous ligament/coccygeus complex; middle pelvic prolapse

Received: 16 November 2019; Accepted: 19 December 2019; Published: 25 March 2020.

doi: 10.21037/gpm.2019.12.09

View this article at: <http://dx.doi.org/10.21037/gpm.2019.12.09>

Introduction

Currently, there are three main surgical methods for middle pelvic prolapse, namely sacral colpopexy, sacrospinous ligament fixation (SSLF), and high uterosacral ligament suspension (HUS). Each of the above operations has its own set of complications (1). The complications of sacral colpopexy include intestinal obstruction, ureteral injury, sacral osteitis, thromboembolic symptoms, mesh exposure to the vagina, eroded viscera, ureteral obstruction, etc. The complications of SSLF include rectal injury, compression syndrome of the sciatic nerve, fecal incontinence, etc. The complications of HUS include ureteral injury, ureteral obstruction, etc (2). Most of the complications often require reoperation (*Video 1*).

We have completed 50 of these surgeries, with good postoperative recovery and no cases of relapse. This surgery video is of a 68-year-old female patient. She was found

to have vaginal prolapse for 20 years with aggravation for 1 year. Her pelvic organ prolapse quantification (POP-Q) score when admitted to the hospital is visible in *Figure 1*.

Pre-operative assessment

We use the pelvic organ prolapsed quantification method (POP-Q) for staging. Patients with a POP-Q score \geq II are eligible for the procedure.

Patients are excluded from this procedure if, combined with chronic cough and other medical diseases, they exhibit malignant lesions of the uterus and uterine adnexa.

A preoperative 3D conventional vaginal scrub is performed, and women who have been menopausal for many years and have obvious atrophy of vaginal mucosa are given topical estrogen ointment 1 week before surgery. The patient in the video had an ulcer in the vaginal mucosa, and had to wait for the ulcer to heal before undergoing surgery.

Aa	+2	Ba	+3	C	+8
Gh	5	Pb	1.5	Tvl	-3
Ap	+1	Bp	+2	D	+5

Figure 1 The patient's POP-Q score when admitted to the hospital. POP-Q, pelvic organ prolapse quantification.

Anaesthesia and positioning

All patients are anesthetized with combined endotracheal intubation and intravenous anesthesia. The umbilical hole is punctured to establish the artificial pneumoperitoneum, the laparoscopic lens with a 10 mm trocar puncture is inserted, and this is followed by insertions of the second trocar in the left abdomen and the third trocar in the right abdomen.

Operative techniques

The operation proceeds in the following steps. (I) The position of the ureter is first confirmed. the pelvic peritoneum is cut to the lateral uterosacral ligament by going along the ureter from the pelvic entrance to the ureter 1–2 cm away. The rectal lateral fossa nearby the lateral ureter is sharply separated until the intersection of the ureter and uterine artery. We usually call this the ureteral tunnel (*Figure 2*). (II) The loose connective tissue of the rectal lateral fossa and the lateral ureter is sharp and blunt separated by ultrasonic knife (*Figure 3*), and the medial sacrospinous ligament is then exposed. The assistant touches the sciatic spine from the vagina, looking for the sacrospinous ligament. The surgeon gently pulls the sacrospinous ligament with the separation forceps in his left hand to further confirm the sacrospinous ligament. The surgeon use ultrasonic knife to inward and upward separate the medial margin of the sacrospinous ligament, and the sacrospinous ligament/coccygeus complex near the attachment of the sacrum is exposed (*Figure 4*). (III) An ultrasonic knife is used to cut the lateral serous layer of the uterosacral ligament, push the ureter laterally, and expose the entire lateral section of the uterosacral ligament (*Figure 5*). (IV) A No. 0 non-absorbable suture with a needle is used to suture the sacrospinous ligament/coccygeus muscle complex near the attachment of the sacrum. The depth of the needle insertion is 3–5 mm (*Figure 6A,B*). After pulling the suture, in order to make sure there is enough tension

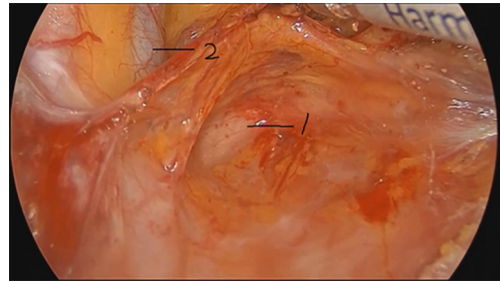


Figure 2 Confirming the position of the ureter (1: external iliac blood vessel; 2: ureter).

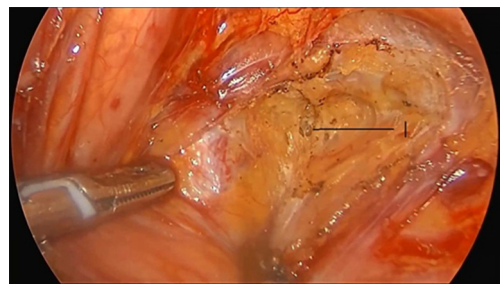


Figure 3 Separating the loose connective tissue of the rectal lateral fossa and the lateral ureter (1: rectal lateral fossa).

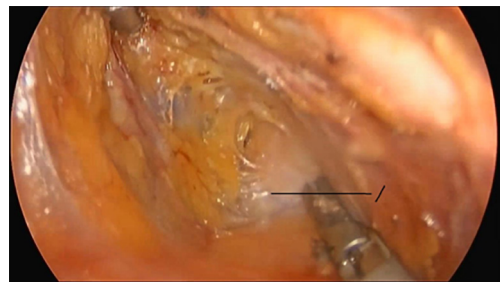


Figure 4 Exposing the sacrospinous ligament/coccygeus complex near the attachment of the sacrum (1: the sacrospinous ligament/coccygeus complex).

(*Figure 7*), the suture needle is sutured to the sacral part of the uterosacral ligament and then knotted to fix the uterosacral ligament (*Figure 8*) (first step suture). (V) The lateral edge of the middle part of the uterosacral ligament is then exposed. Next, the stitch which was previously fixed on the sacrospinous ligament/coccygeal complex is used to suture the middle part of the uterosacral ligament with 2–3 stitches (*Figure 9A,B*). The knot is then tied for the purpose of shortening and strengthening the uterosacral

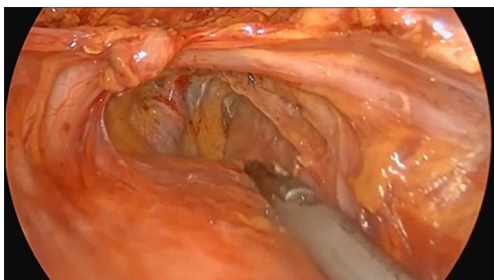


Figure 5 Exposing the entire lateral section of the uterosacral ligament.

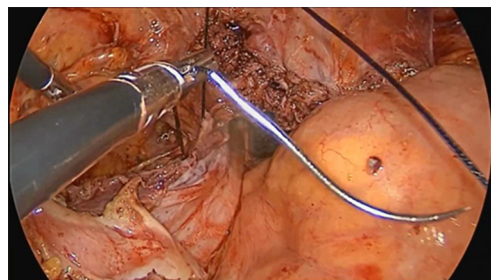


Figure 7 Pulling the suture to ensure sufficient tension.

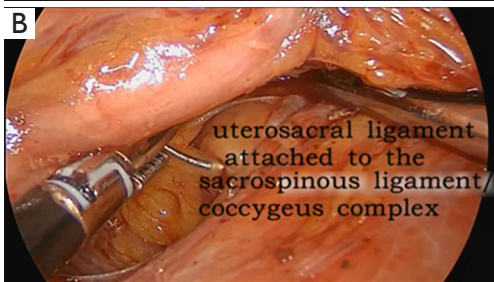
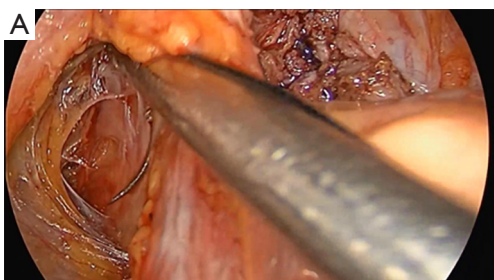


Figure 6 Suturing with one needle on the sacrospinous ligament/coccygeus muscle complex.

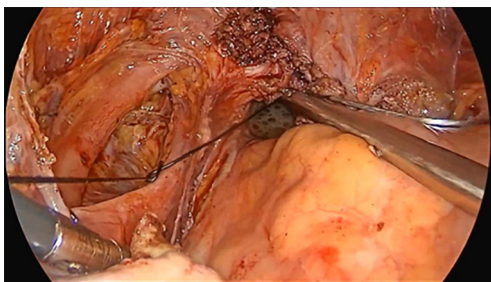


Figure 8 Tying a knot to fix the uterosacral ligament.

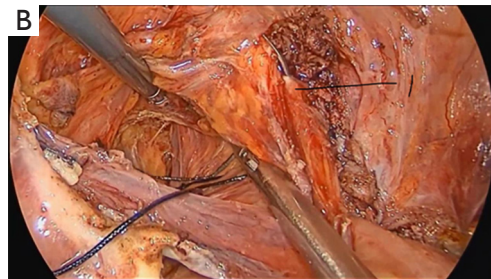
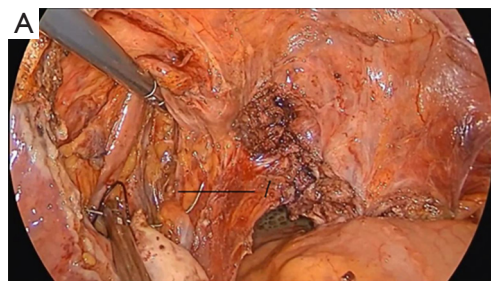


Figure 9 Stitching two or three stitches to the uterosacral ligament in order to shorten the ligament (1: uterosacral ligament).

ligament (*Figure 10*) (second step suture). (VI) The assistant uses oval plier clamps to place a gauze ball into the vagina, raises the vaginal vault and the top of the vagina, and uses the previous non-absorbable suture with a needle to pass through the neck of the uterosacral ligament and the entire top layer of the vagina that has been closed (*Figure 11*). The mucous membrane or the posterior lateral uterosacral ligament attachment of the cervix should not be penetrated. The suture is tightened, the vaginal tip is pulled 2 cm above the sciatic spine, and the suture is knotted (*Figure 12*) (third step suture). (VII) These six steps above are also performed on the right side. (VIII) The assistant uses oval plier clamps to place a gauze ball into the vagina again in order to check that the range of motion at the top of the vagina is 1–2 cm. The vagina is then disinfected, and the vaginal stump and

the anterior and posterior walls are checked for bulging or bleeding. (IX) Bipolar electrocoagulation is used to stop bleeding during the operation, and the absorption suture is used to close peritoneum (*Figure 13*).

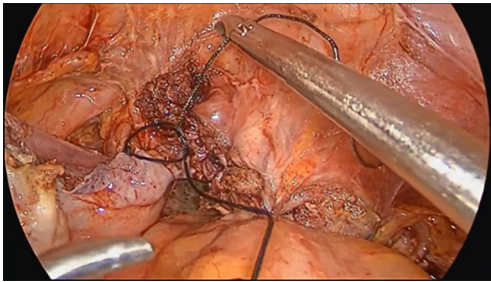


Figure 10 Tying the knot after 2–3 stitches in order to shorten and strengthen the uterosacral ligament.

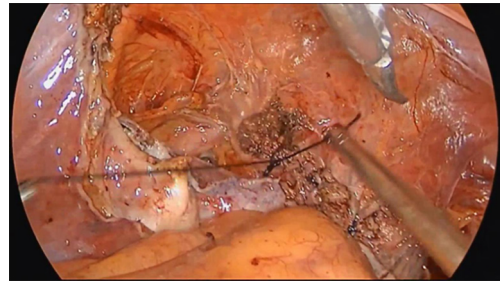


Figure 12 Tying the knot.

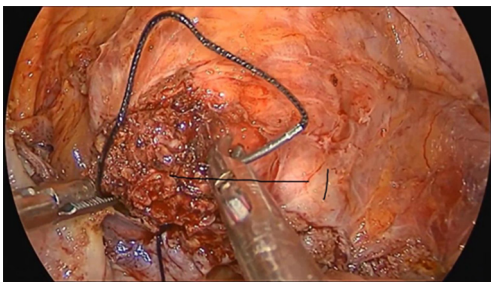


Figure 11 Passing the stitch through the entire top layer of the vagina (1: the top of the vagina).

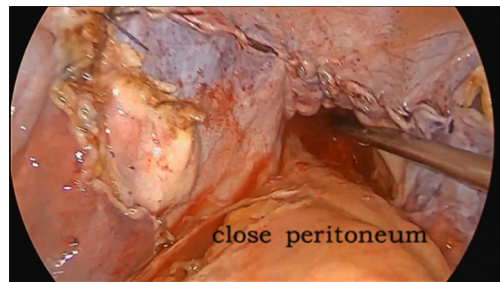


Figure 13 Performing the same steps on the right side and then closing the peritoneum.

Postoperative management

According to the routine nursing after laparoscopic surgery, continuous catheter is applied for 5–6 days, with appropriate use of antibiotics. Women who have been menopausal for many years are given topical estrogen. After 5–6 days, the catheter is removed, urine output is observed, and residual urine volume is measured. Regular follow-up is conducted at 1, 3, 6, 9, and 12 months after operation, and a review occurs every 6 months. Medical history is collected (including urine output, presence of prolapse in the vagina or not, or the sensation of prolapse, vaginal examination, POP-Q measurement, residual urine volume, sexual satisfaction, etc.) A subjective cure is defined as patients having no conscious symptoms after surgery, while objective cure is defined as postoperative stage 0 of the top of the vagina or uterus using the POP-Q as the assessment method.

Comments

Uterosacral ligament consolidation and fixation has the following innovations: (I) a change of the fixed position to

the sacrospinous ligament/coccygeus complex (physiological attachment point of the uterosacral ligament); (II) making full use of the uterosacral ligament to strengthen the middle section, which solves the problem of uterosacral ligament relaxation lengthening, reduces stress, and conforms more to the concept of self-repair; (III) adopting the “three-step suture technique”, which is stable and is not likely to lead to relapse. Firstly, to suture sacrospinous ligament/coccygeus complex with uterosacral ligament for fixation. Secondly, to suture uterosacral ligament with 2–3 stitches for shortening. Lastly, to suture uterosacral ligament with uterus/(top of the vagina) for fixation.

Acknowledgments

The video was awarded the third prize in the First International Elite Gynecologic Surgery Competition (2019 Masters of Gynecologic Surgery).

Funding: None.

Footnote

Provenance and Peer Review: This article was commissioned

by the editorial office, *Gynecology and Pelvic Medicine* for the series “Award-Winning Videos from the First International Elite Gynecologic Surgery Competition (2019 Masters of Gynecologic Surgery)”. The article has undergone external peer review.

Conflicts of Interest: All authors have completed the ICMJE uniform disclosure form (available at <https://gpm.amegroups.com/article/view/10.21037/gpm.2019.12.09/coif>). The series “Award-Winning Videos from the First International Elite Gynecologic Surgery Competition (2019 Masters of Gynecologic Surgery)” was commissioned by the editorial office without any funding or sponsorship. The authors have no other conflicts of interest to declare.

Ethical Statement: The authors are accountable for all aspects of the work in ensuring that questions related to the accuracy or integrity of any part of the work are appropriately investigated and resolved. All procedures performed in studies involving human participants were in accordance with the ethical standards of the institutional and/or national research committee(s) and with the Helsinki Declaration (as revised in 2013). Written informed consent was obtained from the patient for publication of this

manuscript and any accompanying images.

Open Access Statement: This is an Open Access article distributed in accordance with the Creative Commons Attribution-NonCommercial-NoDerivs 4.0 International License (CC BY-NC-ND 4.0), which permits the non-commercial replication and distribution of the article with the strict proviso that no changes or edits are made and the original work is properly cited (including links to both the formal publication through the relevant DOI and the license). See: <https://creativecommons.org/licenses/by-nc-nd/4.0/>.

References

1. Committee on Practice Bulletins-Gynecology, American Urogynecologic Society. Practice Bulletin No. 185: Pelvic Organ Prolapse. *Obstet Gynecol* 2017;130:e234-e250.
2. Urogynecology Subgroup, Chinese Society of Obstetrics and Gynecology, Chinese Medical Association; Urogynecology Subgroup Chinese Society of Obstetrics and Gynecology Chinese Medical Association. Guideline for the diagnosis and management of pelvic organ prolapse (draft). *Zhonghua Fu Chan Ke Za Zhi* 2014;49:647-51.

doi: 10.21037/gpm.2019.12.09

Cite this article as: Huang W, Chen C, Yang Z, Lan X, Fang Z. Laparoscopic uterosacral ligament consolidation and fixation based on the sacrospinous ligament/coccygeus complex. *Gynecol Pelvic Med* 2020;3:6.