



Laparoscopic lateral suspension with mesh for the management of pelvic organ prolapse: an educative video (case report)

Jean Dubuisson^{1^}, Jean-Bernard Dubuisson²

¹Department of Pediatrics, Obstetrics and Gynecology, University Hospitals of Geneva, Geneva, Switzerland; ²Institut Champel, Geneva, Switzerland

Correspondence to: Jean Dubuisson. University Hospitals of Geneva, 30 boulevard de la Cluse, 1205 Geneva, Switzerland.

Email: Jean.Dubuisson@hcuge.ch.

Abstract: Laparoscopic sacrocolpopexy (SCP) using a mesh has been the treatment of choice for pelvic organ prolapse for more than 20 years. However, the potential surgical difficulties associated with the promontory dissection have prompted reflection on surgical alternatives that completely avoid the promontory. Laparoscopic lateral suspension (LLS) is a promising option that gives satisfactory anatomical and functional results. The originality of LLS with mesh is the subperitoneal tunnel of the lateral long arms of the T-shaped mesh through the lateral abdominal wall, leaving the skin above the iliac crest. This suspension prevents potential major risks of injury to the blood vessels, nerves, or bowel, and provides symmetrical lateral tension-free suspension in an anatomical vaginal axis. The indications for LLS are anterior pelvic organ prolapse and apical descent. LLS can be considered when the access of the promontory is difficult; for instance, in the presence of severe adhesions, sigmoid megacolon, or a low-positioned left common iliac vein that partially covers the promontory. LLS is also a practical alternative technique for surgeons with only moderate experience in dissecting the promontory area. LLS represents a simple, effective and reproducible technique that rarely causes complications. In this article, the different surgical steps of the procedure are described, providing practical tips for a successful surgery.

Keywords: Lateral suspension; genital prolapse; vaginal vault prolapse; laparoscopy; case report

Received: 15 January 2021; Accepted: 06 May 2021; Published: 25 March 2022.

doi: 10.21037/gpm-21-6

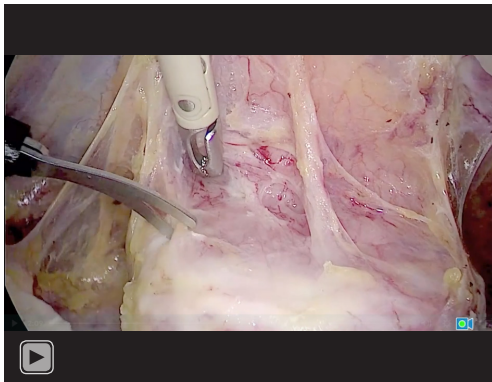
View this article at: <http://dx.doi.org/10.21037/gpm-21-6>

Introduction

Pelvic organ prolapse (POP) is a common pathology that affects up to 30% of women of older than 50 years (1,2). In the 1960s, an alternative approach to vaginal surgery for POP was introduced, SCP, which consisted of a laparotomy and fixation of the pelvic organs (especially the uterus) to the lumbosacral disc (3). However, advances in minimally invasive surgery have made it possible to consider a laparoscopic approach for POP. Laparoscopic SCP with mesh was developed in the late 90s (4). SCP is now the most frequently performed abdominal surgical procedure to treat POP with satisfactory results (5).

However, this technique involves a difficult surgical step comprising the dissection of the promontory area where the mesh will be moored. The dissection and release of the promontory area are sometimes difficult and hemorrhagic, especially in women with obesity, severe pelvic adhesions, megacolon, large varicose veins, and anatomic anomalies such as low bifurcation of the vena cava with coverage of the promontory with the primary left iliac vein or artery. In addition, a recent study reported that *de novo* back pain occurs in 25% to 50% of patients after laparoscopic SCP with the use of sutures or tackers on the promontory (6). Finally, there is a risk of spondylodiscitis at the points of

[^] ORCID: 0000-0002-7244-786X.



Video 1 Technical tips for performing LLS. LLS, laparoscopic lateral suspension.

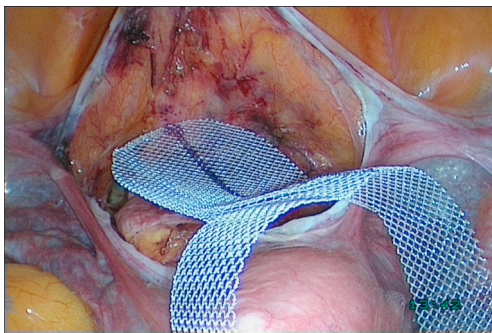


Figure 1 TiLoop mesh (Titanium-coated Polypropylene mesh, pfm medical, Kohn, Germany) applied to the pubovesical fascia and the anterior wall of the vagina as well as to the isthmus.

fixation of the mesh on the promontory, although this is very rare (7).

The potential difficulties associated with the promontory dissection and the risks of postoperative lumbosacral pain have prompted reflection on laparoscopic surgical alternatives that completely avoid the promontory (8). We therefore devised a new technique in the late 90s, namely laparoscopic lateral suspension (LLS) with mesh (9,10).

We propose in this article to describe the different surgical steps of the technique and to precise the indications.

We present the following case in accordance with the CARE reporting checklist (available at <https://gpm.amegroups.com/article/view/10.21037/gpm-21-6/rc>).

Case presentation (Video 1)

A 65-year-old woman was referred to our institution for the

surgical management of a symptomatic POP. She suffered from bulge symptoms related to a stage 3 apex descent with cystocele according to the POP-Q classification. We decided to perform the LLS technique with mesh to repair the pelvis.

We decided to preserve the uterus as long as the uterus was healthy, i.e., normal ultra-sound imaging, cervical cytology and endometrial biopsy.

A standard laparoscopy under general anesthesia was performed. In addition to the umbilical trocar used for the laparoscope, three 5-mm ancillary trocars were needed.

All procedures performed in this study were in accordance with the ethical standards of the institutional and/or national research committee(s) and with the Helsinki Declaration (as revised in 2013). Written informed consent was obtained from the patient.

- (I) The first step of LLS was the anterior cleavage. After opening the anterior cul-de-sac, the vesicovaginal cleavage was carried out as low as possible, below the bladder trigone, which makes it possible to treat the entire cystocele and to avoid any residual low hernia.
- (II) The second step was the introduction of the delicately rolled-up mesh into the abdominal cavity through the optical trocar. An “inverted T” mesh was used, and could be cut with scissors from a large polypropylene mesh, as for laparoscopic SCP. Since 2011, we have used the TiLoop titanium-coated polypropylene mesh (pfm medical, Köln, Germany) (11,12) (Figure 1). The size of the mesh was as follows: wing spread 415 mm, width including the subvesical tab 90 mm, width at the level of the wings 30 mm. The subvesical tab was applied to the pubovesical fascia and the anterior wall of the vagina, as well as to the isthmus; it was fixed by absorbable polyester tackers derived from lactic and glycolic acids (AbsorbaTack, Medtronic) (13) and also by absorbable thread. The fixation with tackers facilitated the technique, limiting the number of sutures.
- (III) The third step was the lateral suspension proper, which constitutes the originality of the “Dubuisson” technique (14). The objective was for the suspension axis to be strictly transverse, so that the preserved uterus remains in the center of the pelvis. The suspension must be exact, without too much tension, to avoid modifying the axis of the vagina. In this step, the arms of the mesh were held with

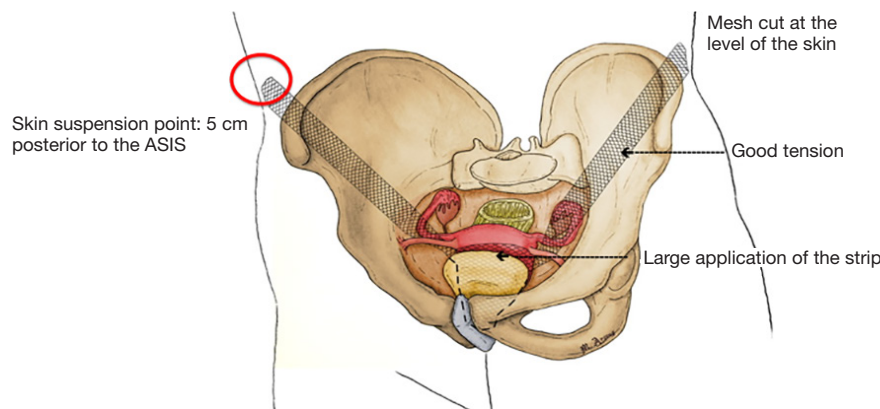


Figure 2 Principles of the correct technique for LLS. LLS, laparoscopic lateral suspension.

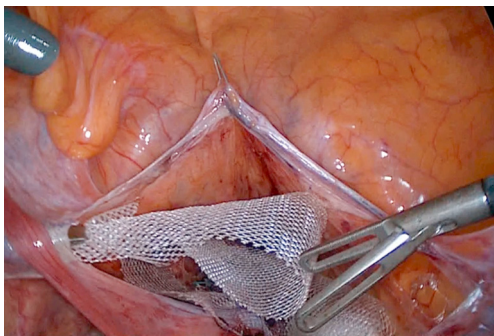


Figure 3 The forceps grips the extremity of the ipsilateral arm of the mesh in the subperitoneal left tunnel.

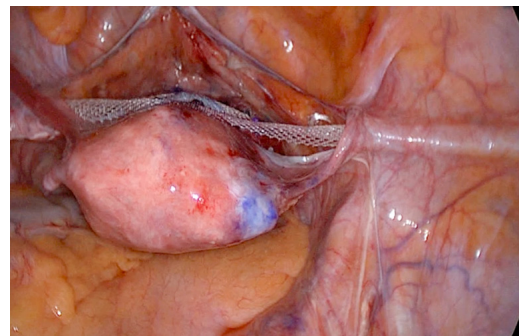


Figure 4 Symmetrical lateral tension-free suspension in an anatomical vaginal axis.

traction forceps, such as 5-mm laparoscopic forceps with claws. The forceps were introduced from the “outside-in” at a precise location on the lateral abdominal wall referred to as “the skin point of the suspension”. This point is a 5-mm skin incision made 2 cm above the iliac crest, approximately 4–5 cm behind the anterior superior iliac spine (ASIS) (*Figure 2*). The selected skin point of the suspension should allow the uterus or vaginal vault to return to the middle part of the pelvis. Using this point as the mesh exit point avoids «opening» the anterior compartment to limit iatrogenic urinary disorders and reduce the risk of cystocele recurrence; it also prevents opening the posterior compartment, which reduces the risk of enterocele or high rectocele. Starting from the skin point, the route of the forceps from the outside-in was the well-defined “bayonet path”. Under a fairly firm pneumoperitoneum, the forceps were pushed

through the skin incision and initially course perpendicular to the abdominal wall, puncturing the fascia and stopping at the peritoneum, without injuring it. For the bayonet path, the forceps were then oriented at a right angle and moved in a horizontal subperitoneal direction, parallel to the peritoneum until they reached the ipsilateral round ligament. The forceps then passed below the ipsilateral round ligament to the area of the vesicovaginal dissection to grip the extremity of the ipsilateral arm of the mesh (*Figure 3*). This end of the mesh was gently pulled backwards through the previously formed tunnel and exteriorized to the skin. The arm of the mesh must lay flat without any twist. The same procedure was performed on the contralateral side. The tension of the mesh was symmetrically adjusted (*Figure 4*). The tension was adapted and maintained until the end of the operation. Kocher forceps were used to fix the

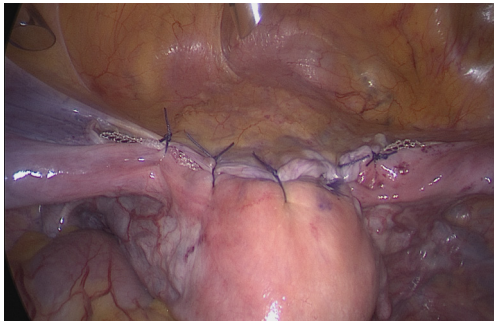


Figure 5 Reperitonealization and final view of the LLS. LLS, laparoscopic lateral suspension.

arm of the mesh at the level of the skin on each side, and establish symmetry and adequate tension. Compliance with hygiene standards was mandatory to avoid any infections related to the presence of the mesh.

- (IV) The final step of the procedure was the reperitonealization of the mesh with a few absorbable sutures (*Figure 5*). The two exteriorized distal ends of the mesh were cut at the level of the skin. The arms were therefore not fixed (“tension-free” principle).
- (V) The last step was not compulsory and depends on the severity of the posterior damage. It is performed to treat associated descent of the posterior compartment or to prevent potential elythrocele and rectocele, as assessed intraoperatively. This step may be performed via two options.
 - i. One option is to do the posterior repair via laparoscopy. This begins with posterior cleavage of the rectovaginal septum. A rectangular mesh cut to the size of the dissected surface of the rectovaginal septum is then applied.
 - ii. Another option is to perform a posterior colporrhaphy through the vaginal route, with the advantage to treat low rectocele and widened vagina.

(VI) In women with vaginal vault prolapse or associated supracervical hysterectomy, a cross-shaped mesh can be used (size 415 mm × 150 mm) (11). The anterior and posterior tabs are applied and fixed to the fasciae covering the corresponding walls of the vagina. Concerning the patient, the clinical follow-up at 1 year was uneventful with no recurrence of the symptoms.

Discussion

Indications of the LLS technique

The main indication for LLS is anterior organ prolapse, which represents the most common form of POP (14). When LLS is chosen, we recommended the use of a synthetic mesh in the shape of an “inverted T” with the median tab providing bladder support, and the lateral arms provide suspension, like the wings of a plane.

The LLS procedure can be used for isolated apex descent or uterine descent associated with cystocele. The “inverted T” mesh must be securely attached to the uterine isthmus to reconstitute part of the pericervical ring. The procedure is often performed with posterior anchorage using high suspension to the uterosacral ligaments.

Vaginal vault prolapse is also a good indication for LLS (15). A cross-shaped mesh is used in women with vaginal vault prolapse. The anterior tab provides the anterior subvesical mesh reinforcement, while the central part of the mesh is fixed to the vaginal vault, the site of previous total hysterectomy scar, or to the cervix after supracervical hysterectomy. Finally, the posterior tab is applied to the rectovaginal septum, securing the distal end of the tab.

In women with associated cervical elongation, cervical amputation can be considered in combination with LLS and uterine preservation.

When rectocele is the predominant element of POP, the LLS technique may not be indicated. Indeed, LLS creates an axis of suspension too anterior to the physiological axis of the rectum. In such cases, SCP or a vaginal approach may be chosen instead.

Results

Several studies have reported the short- and long-term results of LLS with mesh to treat POP (9,10,15). The largest series evaluated 417 patients treated between 2003 and 2011 in the University Hospitals of Geneva, Switzerland (16). At the 1-year follow-up, 78.4% of patients were asymptomatic, and the anatomic success rates, defined as POP Quantification grading system (POP-Q) points Ba, C and Bp of less than -1cm, were 91.6% for the anterior compartment, 93.6% for the apical compartment, and 85.3% for the posterior compartment. The rate of complications (Clavien-Dindo grade 3 or higher) was 2.2% at 1-year follow-up (16,17). After LLS, only 7.3% of patients undergo reoperation for POP with

a follow-up of at least 4 years (5.3% by vaginal route and 2% by laparoscopy) (16); this problem is observed with all procedures, including SCP. The recurrence rate of POP after laparoscopic SCP is up to 23% (18).

Of the 417 patients, 214 participated in a telephone interview for the long-term follow-up (mean 7.2 years). Of the 214 patients interviewed, 187 (87.8%) rated their situation as “improved” or “very much improved”, using the Patient Global Impression of Improvement (PGI-I) questionnaire, and satisfaction was associated with the absence of concomitant hysterectomy. This large series of women who underwent LLS with mesh showed that the technique is feasible and effective with low postoperative complications at 1 year and a high degree of long-term satisfaction (16).

Other recent studies have also reported excellent results of LLS. Mereu *et al.* (19) performed LLS in a series of 120 patients. After 2 years, 89% of patients were asymptomatic, and the anatomic success rate (defined as POP-Q points Ba, C and Bp of less than -1 cm) was 94.2% for the anterior compartment and 94.9% for the apical compartment. The rate of complications (Clavien-Dindo grade 3 or higher) was 0.8%. Repeat surgery for POP was performed in 6.4% of cases. Yassa and Tug (20) reported their experience with LLS with a median follow-up period of 24 months. The anatomical cure rate (defined as POP-Q points C and Ba of less than -1 cm) was 100% for the apical compartment and 88.2% for the anterior compartment. The subjective cure rate (defined as the absence of bulge symptoms) and patient satisfaction scores (using the PGI-I) were 94.12% and 100%, respectively.

Why consider LLS?

As early as the 1990s, we developed the technique of LLS with mesh using a very precise procedure (9). The LLS with mesh procedure was initially developed to simplify the laparoscopic treatment of POP and avoid the operative complications of SCP, which are uncommon but sometimes severe, particularly at the promontory level. The rare but serious adverse events reported after laparoscopic SCP include injuries to the middle sacral vessels and iliac veins, or varicose veins (21).

When SCP is planned, but the access to the promontory is difficult or risky, hemorrhagic (due to adhesions), or impossible (due to osteophytosis or coverage by an iliac vessel), our experience has shown that it is easy to change the planned protocol to LLS. For a gynecological

surgeon who has limited experience with the laparoscopic approach, LLS is less risky than laparoscopic SCP, as the mesh passes through the lateral wall of the abdomen under strict laparoscopic vision, away from dangerous anatomical structures.

The key to successful LLS

The main difficulty of the LLS technique is to properly position the uterovaginal apex. The uterus should be in the correct anatomical position, in the center of the pelvis. As with laparoscopic SCP, the final “tailor-made” mark is essential to prevent discomfort and recurrence.

The technique of grasping and externalizing the mesh is important for the success of the procedure. The sliding of the mesh in its tunnel must be performed carefully and slowly. It is important not to widen the tunnel diameter to avoid any risk of secondary slip. The arms of the mesh are not fixed in the abdominal wall and are left tension-free to avoid the wall pains of traction during mobilization movements. However, the arms can be fixed by an aponeurotic suture placed laparoscopically when it is considered that there is a risk of slipping of the mesh arm due to conditions such as chronic cough or morbid obesity.

Consequences of changes in the pelvic axes after LLS

A recent controlled study evaluated the vaginal axis on MRI after LLS with mesh (22). It is the first study to compare the results of changes in the vaginal axis after LLS with mesh. After LLS, the angles measured between the pubococcygeal line and the lower vaginal segment and between the levator plate and the pubococcygeal line were similar to the angles found in the nulliparous control women. This finding confirms that the vaginal axis is almost normal after LLS with mesh, and supports the practice of this LLS technique in patients with cystocele and apical prolapse.

Uterus-preserving LLS or LLS with hysterectomy?

There is usually no need to perform any additional operative procedure during LLS with the T-shaped mesh. Our study showed that uterus-preserving LLS is an effective technique (23). We evaluated 224 women who underwent uterus-preserving LLS and 94 who underwent LLS and hysterectomy. All patients had stage 2 or greater POP in at least two of the three compartments. The uterus-preserving LLS group tended to achieve better improvement in

the anterior compartment than the group with LLS and hysterectomy (98.7% vs. 94.6%, $P=0.35$).

Complications of LLS

Several studies have reported that LLS achieves good results, with sufficient follow-up and limited non-severe complications (15,19,20). The risk of intravesical mesh migration is theoretically small, as the tensile forces of the mesh arms are not in the direction of the bladder; this type of complication is mostly related to a technical error (24). The risk of vaginal mesh exposure after LLS is low. In our experience, the mesh exposure rate was 4.3% (16). The risk of vaginal mesh exposure appears to be more limited with the use of polypropylene meshes with large pores and limited weight. The use of polypropylene meshes coated with titanium film limits the occurrence of a foreign body reaction (12). However, no randomized study has yet compared the use of polypropylene versus titanium-coated polypropylene for LLS.

In conclusion, it is important to appropriately select women who will benefit from LLS with mesh. In women with cystocele and/or descent of the apical compartment or procidentia, the results of LLS with mesh are satisfactory and as effective as SCP. The “Dubuisson” technique is simple, effective, and reproducible, with a limited rate of non-severe complications. LLS with mesh is a viable option if the surgeon prefers to avoid any dissection of the promontory.

Acknowledgments

Funding: None.

Footnote

Provenance and Peer Review: This article was commissioned by the Guest Editor (Alexander Popov) for the series “Surgical Treatment of Genital Prolapse and Urinary Incontinence” published in *Gynecology and Pelvic Medicine*. The article has undergone external peer review.

Reporting Checklist: The authors have completed the CARE reporting checklist. Available at <https://gpm.amegroups.com/article/view/10.21037/gpm-21-6/rc>

Conflicts of Interest: Both authors have completed the ICMJE uniform disclosure form (available at <https://gpm.amegroups.com/article/view/10.21037/gpm-21-6/coif>). The

series “Surgical Treatment of Genital Prolapse and Urinary Incontinence” was commissioned by the editorial office without any funding or sponsorship. The authors have no other conflicts of interest to declare.

Ethical Statement: The authors are accountable for all aspects of the work in ensuring that questions related to the accuracy or integrity of any part of the work are appropriately investigated and resolved. All procedures performed in this study were in accordance with the ethical standards of the institutional and/or national research committee(s) and with the Helsinki Declaration (as revised in 2013). Written informed consent was obtained from the patient.

Open Access Statement: This is an Open Access article distributed in accordance with the Creative Commons Attribution-NonCommercial-NoDerivs 4.0 International License (CC BY-NC-ND 4.0), which permits the non-commercial replication and distribution of the article with the strict proviso that no changes or edits are made and the original work is properly cited (including links to both the formal publication through the relevant DOI and the license). See: <https://creativecommons.org/licenses/by-nc-nd/4.0/>.

References

1. Løwenstein E, Ottesen B, Gimbel H. Incidence and lifetime risk of pelvic organ prolapse surgery in Denmark from 1977 to 2009. *Int Urogynecol J* 2015;26:49-55.
2. Olsen AL, Smith VJ, Bergstrom JO, et al. Epidemiology of surgically managed pelvic organ prolapse and urinary incontinence. *Obstet Gynecol* 1997;89:501-6.
3. Huguier J, Scali P. Posterior suspension of the genital axis on the lumbosacral disk in the treatment of uterine prolapse. *Presse Med* 1958;66:781-4.
4. Wattiez A, Maschiach R, Donoso R. Laparoscopic repair of vaginal vault prolapse. *Curr Opin Obstet Gynecol* 2003;15:315-9.
5. Rivoire C, Botchorishvili R, Canis M, et al. Complete laparoscopic treatment of genital prolapse with meshes including vaginal promontofixation and anterior repair: a series of 138 patients. *J Minim Invasive Gynecol* 2007;14:712-8.
6. Vieillefosse S, Thubert T, Dache A, et al. Satisfaction, quality of life and lumbar pain following laparoscopic sacrocolpopexy: suture vs. tackers. *Eur J Obstet Gynecol Reprod Biol* 2015;187:51-6.

7. Brito LG, Giraudet G, Lucot JP, et al. Spondylodiscitis after sacrocolpopexy. *Eur J Obstet Gynecol Reprod Biol* 2015;187:72.
8. Cornier E, Madelenat P. The M. Kapandji hysteropexy; a laparoscopic technique and preliminary results. *J Gynecol Obstet Biol Reprod (Paris)* 1994;23:378-85.
9. Dubuisson JB, Jacob S, Chapron C, et al. Laparoscopic treatment of genital prolapse: lateral utero-vaginal suspension with 2 meshes. Results of a series of 47 patients. *Gynecol Obstet Fertil* 2002;30:114-20.
10. Dubuisson JB, Yaron M, Wenger JM, et al. Treatment of genital prolapse by laparoscopic lateral suspension using mesh: a series of 73 patients. *J Minim Invasive Gynecol* 2008;15:49-55.
11. Dubuisson J, Veit-Rubin N, Bouquet de Jolinière J, et al. Laparoscopic lateral suspension: Benefits of a cross-shaped mesh to treat difficult vaginal vault prolapse. *J Minim Invasive Gynecol* 2016;23:672.
12. Hazebroek EJ, Ng A, Yong DH, et al. Evaluation of lightweight titanium-coated polypropylene mesh (TiMesh) for laparoscopic repair of large hiatal hernias. *Surg Endosc* 2008;22:2428-32.
13. Powell BS, Voeller GR. Current developments in hernia repair; adhesives, and tacking. *Surg Technol Int* 2010;20:175-81.
14. Dubuisson JB, Eperon I, Jacob S, et al. Laparoscopic repair of pelvic organ prolapse by lateral suspension with mesh: a continuous series of 218 patients. *Gynecol Obstet Fertil* 2011;39:127-31.
15. Dubuisson J, Eperon I, Dällenbach P, et al. Laparoscopic repair of vaginal vault prolapse by lateral suspension with mesh. *Arch Gynecol Obstet* 2013;287:307-12.
16. Veit-Rubin N, Dubuisson JB, Gayet-Ageron A, et al. Patient satisfaction after laparoscopic lateral suspension with mesh for pelvic organ prolapse: outcome report of a continuous series of 417 patients. *Int Urogynecol J* 2017;28:1685-93.
17. Clavien PA, Barkun J, de Oliveira ML. The Clavien-Dindo classification of surgical complications: five-year experience. *Ann Surg* 2009;250:187-96.
18. Maher CF, Feiner B, DeCuyper EM, et al. Laparoscopic sacral colpopexy versus total vaginal mesh for vaginal vault prolapse: a randomized trial. *Am J Obstet Gynecol* 2011;204:360.e1-7.
19. Mereu L, Tateo S, D'allerio MN, et al. Laparoscopic lateral suspension with mesh for apical and anterior pelvic organ prolapse: A prospective double center study. *Eur J Obstet Gynecol Reprod Biol* 2020;244:16-20.
20. Yassa M, Tug N. Uterus-preserving laparoscopic lateral suspension with mesh operation in pelvic organ prolapse: Initial experience in a single tertiary center with a median 24-months follow-up. *Geburtshilfe Frauenheilkd* 2019;79:983-92.
21. Coolen AW, Bui BN, Dietz V, et al. The treatment of post-hysterectomy vaginal vault prolapse: a systematic review and meta-analysis. *Int Urogynecol J* 2017;28:1767-83.
22. Pulatoğlu Ç, Yassa M, Turan G, et al. Vaginal axis on MRI after laparoscopic lateral mesh suspension surgery: a controlled study. *Int Urogynecol J* 2021;32:851-8.
23. Veit-Rubin N, Dubuisson J, Constantin F, Lange S, Eperon I, Gomel V, Dubuisson JB. Uterus preservation is superior to hysterectomy when performing laparoscopic lateral suspension with mesh. *Int Urogynecol J* 2019;30:557-564.
24. Milani R, Manodoro S, Passoni P, et al. Surgical management of bladder erosion and pelvic pain after laparoscopic lateral suspension for pelvic organ prolapse. *Int Urogynecol J* 2020;31:843-5.

doi: 10.21037/gpm-21-6

Cite this article as: Dubuisson J, Dubuisson JB. Laparoscopic lateral suspension with mesh for the management of pelvic organ prolapse: an educative video (case report). *Gynecol Pelvic Med* 2022;5:11.