

# Oncoplastic central quadrantectomies

Vittorio Pasta<sup>1,2</sup>, Valerio D'Orazi<sup>3</sup>, Raffaele Merola<sup>2</sup>, Federico Frusone<sup>2</sup>, Maria Ida Amabile<sup>2</sup>, Alessandro De Luca<sup>2</sup>, Rosanna Buè<sup>2</sup>, Marco Monti<sup>4</sup>

<sup>1</sup>Department of General Surgery, <sup>2</sup>Department of Surgical Science, Policlinico Umberto I, University of Rome "La Sapienza", Rome, Italy; <sup>3</sup>Department of General Microsurgery and Hand Surgery, Fabia Mater Hospital, I-00171 Rome, Italy; <sup>4</sup>Department of Gynecology and Obstetrics, Sapienza University of Rome, 00161 Rome, Italy

**Contributions:** (I) Conception and design: V Pasta; (II) Administrative support: Department of Surgical Science, Policlinico Umberto I, University of Rome "La Sapienza"; (III) Provision of study materials or patients: Department of Surgical Science, Policlinico Umberto I, University of Rome "La Sapienza"; (IV) Collection and assembly of data: All authors; (V) Data analysis and interpretation: All authors; (VI) Manuscript writing: All authors; (VII) Final approval of manuscript: All authors.

**Correspondence to:** Alessandro De Luca. Department of Surgical Science, Policlinico Umberto I, University of Rome "La Sapienza", Italy.

Email: aless.deluca@libero.it.

**Abstract:** Tumors localized in the central quadrant (centrally located breast tumors) have always represented a challenge for the surgeon because of the critical aesthetical matters related to the nipple-areola complex (NAC). Many years of experience with breast cancer patients treated by using various oncoplastic techniques, has allowed us to develop the modified hemibatwing for the treatment of central breast tumors, where the NAC is involved. Modified hemibatwing—along with the removal of the NAC—is a useful oncoplastic technique and it represents an ideal option for the treatment of central tumors because it assures oncological safety, a reduced surgical timetable and greater aesthetical results.

**Keywords:** Surgery; breast cancer; oncoplastic; breast

Submitted Feb 16, 2016. Accepted for publication Apr 11, 2016.

doi: 10.21037/gs.2016.04.01

**View this article at:** <http://dx.doi.org/10.21037/gs.2016.04.01>

## Introduction

Initial reports of breast conservative therapy (BCS) successfully performed in women with breast cancers were published in the 1990s (1).

However, it was later shown that even through the removal of minimal amounts of tissue, the same results were obtained for the overall survivor and disease free survival. Recently, this approach has also been used for some kinds of sarcoma (2-4).

This approach has resulted in a greater attention to the aesthetic aspects of the issue and in further developments in relation to oncoplastic surgery (5,6).

In regards to BCS, one of the most debated aspects by the scientific community is the study of the resection margins, along with their clinical and therapeutic implications. Many definitions of "negative margins" have been given so far in the scientific literature. A recent study

has defined the negative margin as the margin that doesn't have cancer cells in the ink colored section, the so called "no tumor on ink" (7).

The numerous advances made in studying such margins and the ability to obtain surgical negative margins have certainly driven oncoplastic surgeons towards researching new surgical techniques.

For what concerns oncoplastic surgery, periareolar tumors can be considered peculiar conditions since a central quadrantectomy with resection of the nipple-areola complex (NAC), is required to perform (8).

Various techniques have been proposed for central quadrantectomy, some of which may include more than one operation (9-13).

The aim of the oncoplastic surgery is to reach an appropriate aesthetic result, albeit oncological safety must be considered as the most critical element (14-19).

This evolutive thinking lead us to realize several changes

to the existent techniques with the purpose of reaching better aesthetic results, which themselves are the topic of this paper.

## Material and methods

Between January 2013 and July 2015, a total of 182 patients affected by breast cancer were treated and enrolled in the study. They came to our clinical observation (Dep. Paolucci-Policlinico Umberto I in Rome). Their age was between 25 and 85:

- 36 were treated by mastectomy (9 nipple-sparing and 3 skin-sparing) (19.8%);
- 146 were treated by quadrantectomy (80.2%).

In the latter, 7 were treated by central quadrantectomy with resection of the NAC (4.8%) (20):

- 3 by batwing;
- 3 by modified batwing;
- 1 by our modified hemibatwing technique.

This last, was the case of a 55-year-old woman who had been previously gone through a bilateral reduction mammoplasty a few years before. Our observation had indeed resulted in the diagnosis of carcinoma of the breast.

The study was approved by the hospital ethics committee and the patient has provided written informed consent.

Surgery was performed in a supine position under general anesthesia.

To perform the resection, an onewing-shaped incision was drawn on the skin to include the NAC and the skin overlying the breast malignancy.

The resection consisted of a crescent-shaped area of NAC and gland, followed by a triangle-shape or wing-like area over the adjoining skin and gland extended to one side of the areola. The surgery started with the upper semicircular periareolar incision that was prolonged laterally toward the axilla. From the supero-medial side of the areola, the incision was extended until the inferior margin of the areola and arranged circumferentially around this border involving approximately half the NAC circumference, (corresponding with the superior incision), and finally continued with a linear extension prolonged on the lateral external quadrant according with the position of the lesion.

The axilla was accessed by performing the same incision and sentinel and parasentinel lymph node were detected and reported using the Probe Navigator.

Then, a "remodeling" of the breast was performed by separation of the glandular tissue (local flap) from the fascia

of the large pectoral muscle, and through its cranial and caudal rotation, to obtain a good filling of the resection cavity and the reconstruction of the pseudo-areola (21).

This oncoplastic flapping permitted the layered closure of the glandular tissue, performed with long-term absorbable sutures, and allowed the wound closure with intradermic fast absorbable suture. The areola was sutured with running suture as to fulfill the optical effect of Montgomery tubercles.

Surgery was completed without any difficulties. The patient was discharged after 3 days of hospitalization and the drainage removed by the same time. No complications were observed during the post-surgery period.

The cosmetic results have been valuated after few months and were rated as good (4 out of 5). The patient also considered not necessary the reconstruction of the NAC by tattooing techniques (22-24).

## Discussion

The surgical strategy for breast cancer has considerably changed over the last 20 years, leaning towards a much more conservative approach (8,25-27). Such changes have also promoted the development of oncoplastic surgery; although excluding some types of inflammatory tumors that needs to be treated differently (28,29).

Those tumors localized in the central quadrant have always represented a challenge for the surgeon because of the involvement of critical aesthetical matters related to the NAC (30).

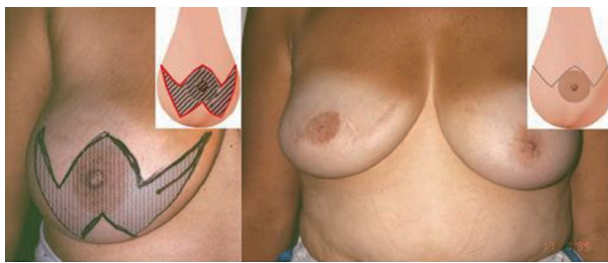Such perspective has been the main reason for researching less intrusive surgical techniques even for tumors of the central quadrant, assuring at the same time, a higher level of patient's satisfaction, without compromising the oncological safety (14,26,29).

As of now, the most common techniques for central quadrant are: grisotti, batwing and hemibatwing.

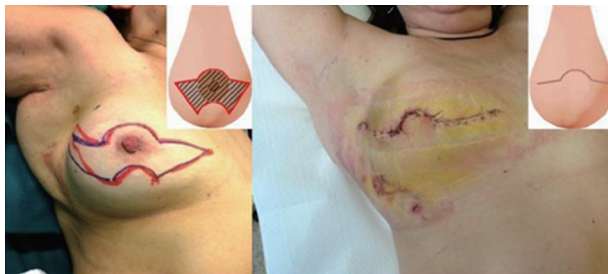Grisotti technique consists in a central quadrantectomy with a transposition of a flap from the lower part of the breast. This technique is used for small-size retroareolar tumors in patients with ptotic breasts.

The resection begins with the incision of the areolar margin. The dissection is continued until the pectoralis muscle fascia. After resecting the specimen, the area of skin outlined in the inferolateral breast is de-epithelized except for the encircled disc of skin that will become the future areola.

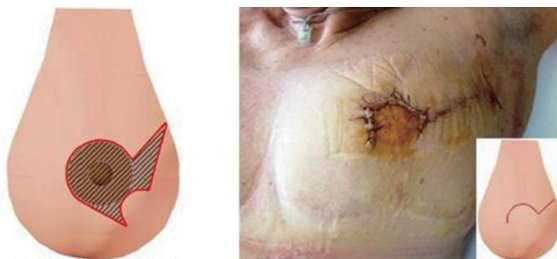
After the resection of the NAC, the quadrantectomy



**Figure 1** Batwing technique.



**Figure 2** Modified batwing.



**Figure 3** Modified hemibatwing.

defect is reconstructed using the rotation of the inferior glandular flaps with mobilization of the skin circle which is to take the place of the excised areola (31-33).

The batwing technique (34-36) is performed with an incision of a double upset M-shape, with the extremities of the inferior incision (more opened) prolonged until they meet the lateral margins of the superior incision (more acute).

The two parallel M incisions are performed above and under the tumor, with a sufficient margin of distance from it.

After the incision, surgery continues with a quadrantectomy until the fascia of the large pectoral muscle.

The upper central border of the incision will become the new superior areolar margin. The remodeling of the defect

is performed by the mobilization and transposition of a flap that is located above and under the cavity resection so as to permit the wound closure (*Figure 1*).

The modified batwing technique was then introduced by us, with the purpose of getting better aesthetical outcomes.

The realization of rounded margins (no more sharp) has resulted in the reproduction of the anatomic profile of the areola (*Figure 2*).

Finally, with the aim of reducing the resected breast tissue, we took the cue from the hemibatwing technique (34), already used for the quadrantectomy with sparing of the NAC, and adapted this technique for central quadrantectomy where the resection of the NAC was necessary.

In this case, we performed a first semicircular incision along the superior margin of the areola and a second one, also semicircular with the same inferior concavity, under the NAC, along the inferior limit of the areola. So, the two medial extremities were connected with another linear incision slightly tilted to the top. Subsequently, the following linear extension of the incision, differently than the Batwing, was performed only to one side of the breast (medial or lateral), depending on the location of the tumor (*Figure 3*).

Therefore, the result of our job was the realization of an applicable modification of the hemibatwing technique, already used to treat the periareolar tumors where the NAC is not involved, to be also performed on centrally located breast tumors with the inclusion of the NAC.

## Conclusions

Many studies have validated the advantages offered by breast conservative surgery compared to mastectomies in patients who were applied for this kind of surgery (37).

Several studies underline the advantages of oncoplastic surgery demonstrating that this approach is not just oncologically safe, but also gives better aesthetical results (14,25).

We consider the hemibatwing approach as the best for tumors of central quadrant with the resection of the NAC.

The technique is proven to be of easy execution; it requires a smaller amount of time compared to both the batwing and the modified batwing. Additionally, the hemibatwing offers better aesthetical outcomes compared to other classic techniques and reduces the risk of complications as Mondor's syndrome because of its less invasivity (38).

Moreover, it allows direct access to the axilla with one incision when the retroareolar tumor, is located/extended to

the external quadrants, as to permit the excision of sentinel lymph node (LS) also with the modified sentinel node and occult lesion localization (SNOLL) technique (39).

In conclusion we believe that the hemibatwing—along with the removal of the NAC—represents an ideal option for the treatment of central tumors because it assures oncological safety, a reduced surgical timetable and greater aesthetical results.

On the other hand, operating small breasts might be harder and, so far, we are not able to state that the aesthetical results would be as good as it is for larger breasts.

## Acknowledgements

None.

## Footnote

*Conflicts of Interest:* The authors have no conflicts of interest to declare.

*Informed Consent:* Written informed consent was obtained from the patient for publication of this case report and any accompanying images.

## References

1. Audretsch WP, Rezai M, Kolotas C, et al. Tumor-specific immediate reconstruction in breast cancer patients. *Perspectives in Plastic Surgery* 1998;11:71-106.
2. Pasta V, Sottile D, Urciuoli P, et al. Rare chondrosarcoma of the breast treated with quadrantectomy instead of mastectomy: A case report. *Oncol Lett* 2015;9:1116-20.
3. Pasta V, Monti M, Cialini M, et al. Primitive sarcoma of the breast: new insight on the proper surgical management. *J Exp Clin Cancer Res* 2015;34:72.
4. Pasta V, Monti M, Antonucci D, et al. Primary sarcoma of the breast: criteria for radical surgery. *G Chir* 1997;18:703-6.
5. Petit JY, De Lorenzi F, Rietjens M, et al. Technical tricks to improve the cosmetic results of breast-conserving treatment. *Breast* 2007;16:13-6.
6. Pillarisetti RR, Querci Della Rovere G. Oncoplastic breast surgery. *Indian J Surg* 2012;74:255-63.
7. O'Kelly Priddy CM, Forte VA, Lang JE. The importance of surgical margins in breast cancer. *J Surg Oncol* 2016;113:256-63.
8. Park HC, Kim HY, Kim MC, et al. Partial breast reconstruction using various oncoplastic techniques for centrally located breast cancer. *Arch Plast Surg* 2014;41:520-8.
9. Moustafa A, Fakhr I. Outcome of different oncoplastic surgical (OPs) techniques for centrally located breast cancer (CLBC). *J Egypt Natl Canc Inst* 2014;26:203-9.
10. Munhoz AM, Montag E, Gemperli R, et al. Oncoplastic breast surgery: indications, techniques and perspectives. *Gland Surg* 2013;2:143-57.
11. Kijima Y, Yoshinaka H, Shinden Y, et al. Oncoplastic breast surgery for centrally located breast cancer: a case series. *Gland Surg* 2014;3:62-73.
12. Fitzal F, Nehrer G, Hoch D, et al. An oncoplastic procedure for central and medio-cranial breast cancer. *Eur J Surg Oncol* 2007;33:1158-63.
13. McCulley SJ, Durani P, Macmillan RD. Therapeutic mammoplasty for centrally located breast tumors. *Plast Reconstr Surg* 2006;117:366-73.
14. Down SK, Jha PK, Burger A, et al. Oncological advantages of oncoplastic breast-conserving surgery in treatment of early breast cancer. *Breast J* 2013;19:56-63.
15. Semprini G, Cattin F, Vaienti L, et al. Oncoplastic surgery and cancer relapses: cosmetic and oncological results in 489 patients. *Breast* 2013;22:946-51.
16. Khan J, Barrett S, Forte C, et al. Oncoplastic breast conservation does not lead to a delay in the commencement of adjuvant chemotherapy in breast cancer patients. *Eur J Surg Oncol* 2013;39:887-91.
17. Rose M, Manjer J, Ringberg A, et al. Surgical strategy, methods of reconstruction, surgical margins and postoperative complications in oncoplastic breast surgery. *Eur J Plast Surg* 2014;37:205-14.
18. Choi JY, Alderman AK, Newman LA. Aesthetic and reconstruction considerations in oncologic breast surgery. *J Am Coll Surg* 2006;202:943-52.
19. Rietjens M, Urban CA, Rey PC, et al. Long-term oncological results of breast conservative treatment with oncoplastic surgery. *Breast* 2007;16:387-95.
20. Galimberti V, Zurrada S, Zanini V, et al. Central small size breast cancer: how to overcome the problem of nipple and areola involvement. *Eur J Cancer* 1993;29A:1093-6.
21. Anderson BO, Masetti R, Silverstein MJ. Oncoplastic approaches to partial mastectomy: an overview of volume-displacement techniques. *Lancet Oncol* 2005;6:145-57.
22. Nimboriboonporn A, Chuthapisith S. Nipple-areola complex reconstruction. *Gland Surg* 2014;3:35-42.
23. Schoeller T, Huemer GM. Immediate reconstruction of the nipple/areola complex in oncoplastic surgery after

- central quadrantectomy. *Ann Plast Surg* 2006;57:611-5.
24. Carstensen L, Bigaard J. Management of central breast tumours with immediate reconstruction of the nipple-areola complex; a suggested guide. *Breast* 2015;24:38-45.
  25. Fitzal F, Gnant M. Breast conservation: evolution of surgical strategies. *Breast J* 2006;12:S165-73.
  26. Huemer GM, Schrenk P, Moser F, et al. Oncoplastic techniques allow breast-conserving treatment in centrally located breast cancers. *Plast Reconstr Surg* 2007;120:390-8.
  27. Franceschini G, Martin Sanchez A, Di Leone A, et al. New trends in breast cancer surgery: a therapeutic approach increasingly efficacy and respectful of the patient. *G Chir* 2015;36:145-52.
  28. Pasta V, Mitri F, Amabile MI, et al. Inflammatory breast cancer. *Ann Ital Chir* 2006;77:275-9.
  29. Mansfield L, Agrawal A, Cutress RI. Oncoplastic breast conserving surgery. *Gland Surg* 2013;2:158-62.
  30. Mallucci P, Branford OA. Concepts in aesthetic breast dimensions: analysis of the ideal breast. *J Plast Reconstr Aesthet Surg* 2012;65:8-16.
  31. Della Rovere GQ, Pillarisetti RR, Bonomi R, et al. Oncoplastic surgery for retro areolar breast cancer - a technical modification of the Grisotti flap. *Indian J Surg* 2007;69:160-2.
  32. Farouk O, Attia E, Roshdy S, et al. The outcome of oncoplastic techniques in defect reconstruction after resection of central breast tumors. *World J Surg Oncol* 2015;13:285.
  33. Grisotti A. Immediate reconstruction after partial mastectomy. *Operat Tech Plast Reconstr Surg* 1994;1:1-12.
  34. Holmes DR, Schooler W, Smith R. Oncoplastic approaches to breast conservation. *Int J Breast Cancer* 2011;2011:303879.
  35. Masetti R, Di Leone A, Franceschini G, et al. Oncoplastic techniques in the conservative surgical treatment of breast cancer: an overview. *Breast J* 2006;12:S174-80.
  36. Matkowski R, Szynglarewicz B, Kasprzak P, et al. Batwing mastopexy as oncoplastic surgical approach to periareolar tumors in upper quadrants. *Tumori* 2012;98:421-7.
  37. Wagner E, Schrenk P, Huemer GM, et al. Central quadrantectomy with resection of the nipple-areola complex compared with mastectomy in patients with retroareolar breast cancer. *Breast J* 2007;13:557-63.
  38. Pasta V, D'Orazi V, Sottile D, et al. Breast Mondor's disease: Diagnosis and management of six new cases of this underestimated pathology. *Phlebology* 2015;30:564-8.
  39. Soluri A, Trotta C, Scopinaro F, et al. Radioisotope guided surgery with imaging probe, a hand-held high-resolution gamma camera. *Nucl Instrum Methods Phys Res A* 2007;583:366-71.

**Cite this article as:** Pasta V, D'Orazi V, Merola R, Frusone F, Amabile MI, De Luca A, Buè R, Monti M. Oncoplastic central quadrantectomies. *Gland Surg* 2016;5(4):422-426. doi: 10.21037/gs.2016.04.01