



# Radiofrequency ablation as a treatment modality for primary hyperparathyroidism: a systematic literature review

Peter P. Issa<sup>1^</sup>, Emad Kandil<sup>2</sup>, Grace S. Lee<sup>3</sup>

<sup>1</sup>Louisiana State University Health Sciences Center School of Medicine, New Orleans, LA, USA; <sup>2</sup>Department of Surgery, Tulane University School of Medicine, New Orleans, LA, USA; <sup>3</sup>Department of Surgery, Yale University School of Medicine, New Haven, CT, USA

*Contributions:* (I) Conception and design: All authors; (II) Administrative support: All authors; (III) Provision of study materials or patients: All authors; (IV) Collection and assembly of data: All authors; (V) Data analysis and interpretation: All authors; (VI) Manuscript writing: All authors; (VII) Final approval of manuscript: All authors.

*Correspondence to:* Grace S. Lee, MD, FACS. Department of Surgery, Yale University School of Medicine, 330 Cedar St., New Haven 208062, CT 06520, USA. Email: glee727@gmail.com.

**Background:** Primary hyperparathyroidism (pHPT) is an endocrine disorder typically characterized by elevated serum calcium and elevated parathyroid hormone (PTH). While parathyroidectomy is the standard treatment, non-operative intervention such as radiofrequency ablation (RFA) has been adopted as an alternative for the management of pHPT, as it has been utilized in other endocrine glands such as thyroid and adrenal. In this literature review, we aim to evaluate the current practice of RFA for pHPT.

**Methods:** A systematic literature search using PubMed, Web of Science, and Embase through June 2022 was conducted. Studies included in the review consisted of patient cohorts who had an unequivocal diagnosis of pHPT and underwent the treatment of pHPT with RFA. When more than one study was published from a similar cohort of patients, only the study with the most number of patients was considered. Studies included were assessed for bias using the critical appraisal instruments from the Joanna Briggs Institute (JBI) System.

**Results:** A total of 14 studies describing 167 parathyroid glands treated in 163 patients were reviewed. The overall cure rate was 91.2%, with 5 patients undergoing more than one ablation. The most common adverse effect encountered was temporary dysphonia. Incomplete ablation and missed multiglandular disease were the most common reasons for RFA treatment failure.

**Conclusions:** RFA may be an effective and safe alternative to parathyroidectomy in select patients with a well-localized, well-located parathyroid adenoma. Additional long-term data are needed to refine its role in the pHPT treatment algorithm.

**Keywords:** Primary hyperparathyroidism (pHPT); radiofrequency ablation (RFA); review; percutaneous ablation

Submitted Sep 21, 2022. Accepted for publication May 19, 2023. Published online Jun 14, 2023.

doi: 10.21037/gs-22-546

**View this article at:** <https://dx.doi.org/10.21037/gs-22-546>

## Introduction

Primary hyperparathyroidism (pHPT) is an increasingly more recognized and diagnosed endocrine disorder typically characterized by elevated serum calcium and elevated parathyroid hormone (PTH). Estimated to affect

25 in 100,000 men and 66 in 100,000 women, pHPT is more prevalent in women and the elderly, specifically, in post-menopausal women (1,2). Unlike secondary or tertiary hyperparathyroidism, where all parathyroid glands tend to be involved, pHPT frequently arises as a result of a single

<sup>^</sup> ORCID: 0000-0002-5248-3142.

adenoma in up to 80–85% of cases (3). For the remainder of non-single gland cases, pHPT may be presented as multiple adenomas, parathyroid hyperplasia, or, very rarely, parathyroid adenocarcinoma (3). Inherited pHPT, seen in multiple endocrine neoplasia (MEN) syndrome 1, MEN 2A, and hyperparathyroidism-jaw tumor syndrome, is relatively low in overall incidence (4). Patients with pHPT may present with symptoms such as pathologic fractures, osteoporosis, nephrolithiasis, peptic ulcer disease, and pancreatitis, as well as a myriad of gastrointestinal, neuropsychiatric, and musculoskeletal symptoms including bone pain, abdominal discomfort, headache, nausea, weakness, constipation, lethargy, and depression, among others (5-7). Patients may be asymptomatic with no sequelae of pHPT at the time of diagnosis, however. Hypercalcemia with elevated PTH is most commonly found on biochemical workups, although normocalcemia or inappropriately normal PTH may be present as well. Hypophosphatemia, low-to-normal 25-hydroxy vitamin D, and elevated 24-hour urine calcium levels are also noted to further secure the diagnosis of pHPT.

Current guidelines recommend surgical resection of diseased parathyroid glands as the treatment for pHPT (6,8). Indications for parathyroidectomy according to the American Association of Endocrine Surgeons (AAES) include: (I) symptomatic pHPT; (II) serum calcium greater than 1 mg/dL above the normal limits; (III) patients with nephrolithiasis, nephrocalcinosis, impaired renal function [glomerular filtration rate (GFR) <60 mL/min] or other renal involvement; (IV) patients with osteoporosis, multiple bone fractures, vertebral compression, or other skeletal involvement; (V) patients younger than 50 years of age; (VI) features of parathyroid cancer by laboratory workup, imaging, or other clinical evidence; (VII) patients with neurocognitive and/or neuropsychiatric disorders; and (VIII) patients unwilling to comply with treatment (8). Parathyroidectomy has been shown to achieve cure in greater than 95% of cases, with a cure defined as normocalcemia at 6-month post-operation (6). Yet, an appreciable number of patients undergoing parathyroidectomy are left with persistent or recurrent disease at approximately 0.5% and 2.4%, respectively (9).

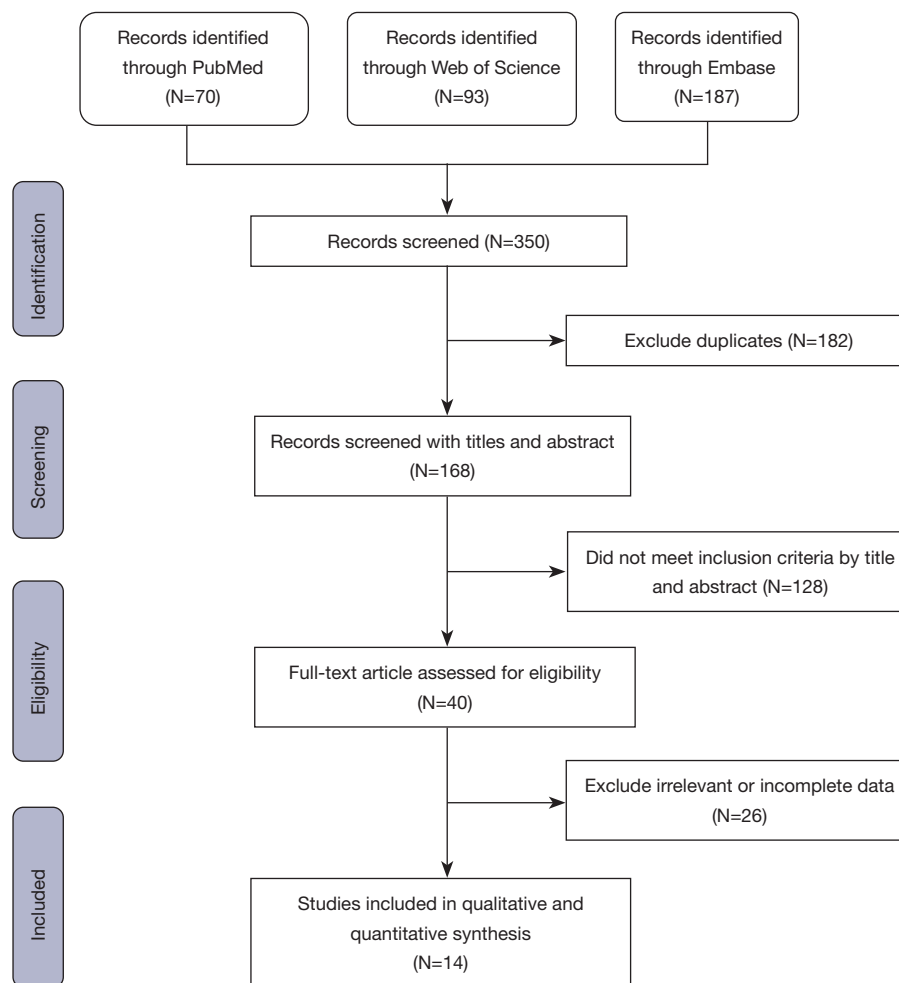
Although minimally invasive and well-tolerated by most, several factors are considered in decision-making to pursue parathyroidectomy such as patient comorbidities, case complexity, recurrent laryngeal nerve palsy, and incisional scar (10). To mitigate a few of these concerns, percutaneous ablation modalities such as high-intensity

focused ultrasound (HIFU), microwave, and radiofrequency ablation (RFA) have been suggested as possible alternatives to parathyroidectomy. RFA, in particular, is performed by using a percutaneous catheter to deliver localized and controlled heat energy for thermal ablation of soft tissue. The technique has been effectively utilized in medicine for many decades in a wide range of applications ranging from cardiac and vascular conditions to tumor ablation in solid organs including the liver, kidney, bone, lung, and adrenal gland (11). Recently, ultrasound-guided RFA of thyroid nodules has been gaining interest as a viable treatment option to reduce the volume of symptomatic, benign thyroid nodules, and treat micropapillary thyroid carcinoma or recurrent thyroid cancer. Given the successful outcome and safety profiles of RFA of the thyroid nodules, RFA has been explored as a primary treatment modality of parathyroid adenomas in recent years, albeit in limited numbers. We aimed to evaluate the current practice of RFA for pHPT by performing a systematic literature review, in accordance with the PRISMA reporting checklist (Available at <https://gs.amegroups.com/article/view/10.21037/gS-22-546/rc>).

## Methods

A systematic literature search was conducted to identify the published studies that described the treatment of pHPT with RFA. All available literature up through June 2022 was screened without language restrictions. The search engines, PubMed, Web of Science, and Embase, were included with the following search keywords: (ablation) AND (thermal OR thermoablation OR RFA OR radiofrequency) AND (hyperparathyroidism OR hyperplastic parathyroid gland OR parathyroid hyperplasia OR parathyroid adenoma OR parathyroid neoplasia). The study selection process is illustrated as a flow diagram in *Figure 1*.

Preprints as well as secondary literature such as review articles, were excluded. Only the primary studies, including case reports, cohort studies, case-controls, and randomized controlled trials, were considered. Studies included in the review consisted of patient cohorts who had an unequivocal diagnosis of pHPT and underwent the treatment of pHPT with RFA. The data was independently collected and extracted by the first author and reviewed by the co-authors. Disagreements were resolved through discussion and arrival at a consensus. Of 168 unique publications produced from the search query, 16 met the inclusion criteria (*Tables 1,2*). When more than one study was published from a similar cohort of patients, such as the work by Wei *et al.* (16,17)



**Figure 1** The study selection process.

or the works by Peng *et al.* (20) and Chai *et al.* (21), the study with the most number of patients was considered for inclusion in the descriptive statistics. One excluded case study described RFA of an incidental parathyroid gland which was initially misdiagnosed as a thyroid nodule and subsequently needed parathyroidectomy (28).

Papers selected for initial inclusion were assessed for risk of bias using the critical appraisal instruments from the Joanna Briggs Institute (JBI) System for the Unified Management, Assessment and Review of Information (29). Items in the checklist have four possible responses, including “yes”, “no”, “unclear”, or “not applicable”. Each study was independently assessed by the first author and reviewed by the co-authors.

Pertinent variables collected for descriptive statistics reporting included patient demographics such as age, sex, number of glands, parathyroid location, pre-operative imaging study, and RFA mean power. Outcomes variables included disease cure rate as well as the presence of complications. The treatment cure was defined as normocalcemia at 6 months after the treatment. Failure to cure or persistent disease was defined as hypercalcemia at 6 months. Not all variables were available for comparison and analysis across all the studies, however, due to the study design or lack of long-term follow-up. We report such variables only in the context of the available pooled data subsets. Overall, a total of 163 patients had 167 parathyroid glands treated with RFA across the 14 studies.

**Table 1** Summary of non-case report studies reporting REA for pHPT

First author	Year	Study design	Country	Number of Patients	Sex (M/F)	MGD (#)	Mean age (years)	Localization modality	Location (upper/middle/lower/intrathyroidal/ectopic)	Mean power (W)	Cure rate (%)	Persistent disease (%)	Recurrent disease (%)	Multiple treatment sessions	Complication
Xu et al. (12)	2013	R	China	2	2/0	No	52	US/MRI/NM	0/1/1/0/0	5	NR	NR	NR	No	Temporary dysphonia [1]
Sormaz et al. (13)	2017	R	Turkey	5	2/3	No	60.25	US/SPECT/ NM	NR	30	60.00	40.00	0.00	1/5	None
Korkusuz et al. (14)	2018	R	Germany	9	2/7	No	NR	US	NR	100	NR	NR	NR	No	None
Ha et al. (15)	2020	NR	Korea	11	2/9	No	64.8	US/NM	NR	NR	63.64	NR	NR	1/11	None
Wei et al. (16)	2021	R	China	27	9/18	No	58.9	CEUS/NM	4/-/-/-/-	35	92.59	NR	NR	No	Dysphonia (unknown duration) [1]
*Wei et al. (17)	2021	R	China	23	7/16	No	59.1	CEUS/NM	NR	NR	87.00	NR	NR	NR	Dysphonia (unknown duration) [1]
Li et al. (18)	2021	P	China	25	3/22	Yes [4]	53.9	US/NM	5/0/24/0/0	5.67	100.00	0.00	0.00	3/25	None
Ebrahimini et al. (19)	2022	R	Iran	27	6/21	No	63.19	US/NM	NR	NR	NR	NR	NR	NR	None
Peng et al. (20)	2022	R	China	51	21/30	No	57.96	US/NM	16/-/34/-/-	NR	98.00	2.00%	0.00%	NR	Temporary dysphonia [3]
*Chai et al. (21)	2022	P	China	39	14/25	No	59.5	US/NM/ CECT	12/0/27/0/0	NR	82.10	0.00	2.00	No	Temporary dysphonia [2]

\*, Wei et al. 2021 (23 patients) and Chai et al. (39 patients) report on similar cohorts to Wei et al. (27 patients) and Peng et al. (51 patients). The published cohort with the larger population was considered for this review's descriptive statistics. Counts in parentheses indicate the number of patients. RFA, radiofrequency ablation; pHPT, primary hyperparathyroidism; R, retrospective; P, prospective; M, male; F, female; MGD, multi-glandular disease; NR, not reported; US, ultrasound; MRI, magnetic resonance imaging; NM, Tc99-Sestamibi nuclear medicine scan; SPECT, single-photon emission computed tomography; CEUS, contrast-enhanced ultrasound; CECT, contrast-enhanced computed tomography.

**Table 2** Summary of case reports discussing RFA for pHPT

First author	Year	Country	Sex	Age, year	Localization modality	Location	Outcome	Comment
Hänsler <i>et al.</i> (22)	2002	Germany	Female	74	US	Superior	Cure	No complication; transient toothache
Kim <i>et al.</i> (23)	2014	Korea	Female	32	US/NM	Inferior	NR	No complication
Zhang <i>et al.</i> (24)	2018	China	Female	39	US	Inferior	Cure	No complication
Hussain <i>et al.</i> (25)	2021	USA	Female	67	US	Inferior	Cure	No complication
Sattarinezhad <i>et al.</i> (26)	2017	Iran	Male	47	US/NM	Middle	Cure	No complication
Shenoy <i>et al.</i> (27)	2017	India	Male	30	US/NM	Inferior	Persistent	No complication

RFA, radiofrequency ablation; pHPT, primary hyperparathyroidism; US, ultrasound; NM, Tc99-Sestamibi nuclear medicine scan; NR, not reported.

## Results

### *Pre-treatment evaluation*

Pre-RFA treatment evaluation includes biochemical confirmation of pHPT diagnosis, pHPT assessment, and parathyroid localization imaging studies similar to pre-operative evaluation for parathyroidectomy. Patients, who are presenting with atypical laboratory values such as normocalcemia or inappropriately normal PTH, need additional or repeat workups to secure the diagnosis of pHPT. Asymptomatic pHPT patients often undergo a bone density scan and renal imaging to evaluate the presence of osteoporosis and nephrolithiasis to assess an objective indication for treatment.

Several imaging modalities may be utilized for the identification of a parathyroid adenoma, depending on the availability and experience at the institution. With a sensitivity of 76.1% and a positive predictive value of 93.2%, ultrasound of the neck does not require intravenous contrast and is a low-cost mapping tool that is especially valuable to surgeons who perform them for surgical planning (30). The ultrasound also allows an opportunity to assess for a concurrent thyroid pathology and gives a real-time spatial correlation to the nearby critical structures around the parathyroid adenoma. In cases where a surgeon or a sonographer cannot visualize a pathological parathyroid gland on the ultrasound, ultrasound-guided RFA is not feasible. Commonly, two different imaging techniques are utilized to increase the sensitivity and specificity of localization for focused treatment and to assess for concurrent thyroid pathology. Tc99-Sestamibi scan relies on the detection of an asymmetrically overactive parathyroid gland. To obtain more anatomically relevant information,

single photon-emission computed tomography (SPECT) and computed tomography (CT) images are concurrently acquired in addition to the planar images. 4-dimensional (4D) CT of the neck, which utilizes timed contrast injection and its washout characteristics, has been increasingly more utilized for its higher resolution and detection of smaller parathyroid glands. Both Tc99-Sestamibi scan and 4D CT are useful in ruling out the presence of ectopic parathyroid adenoma.

4D CT is generally deemed a superior imaging modality to Tc99-Sestamibi and ultrasound in localizing a single-gland disease with respect to specificity (4D CT: 95.6%, Tc99-Sestamibi: 90.4%, US: 86.8%,  $P=0.01$ ), positive predictive value (4D CT: 87.5%, Tc99-Sestamibi: 74.4%, US: 68.1%,  $P<0.01$ ), and accuracy (4D CT: 94.7%, Tc99-Sestamibi: 88.8%, US: 86.2%,  $P<0.01$ ) (31). Other less commonly used imaging adjuncts such as magnetic resonance imaging (MRI) and positron emission tomography (PET)-CT may be necessary to visualize a sonographic correlate, especially in persistent or recurrent disease cases. Whether two concordant imaging studies are necessary prior to either RFA or focused parathyroidectomy, is up for debate.

A majority of the reviewed studies for RFA utilized both ultrasound and Tc99-Sestamibi scans to localize the adenoma. Korkusuz *et al.* was an exception, where they only used a neck ultrasound to identify an adenoma in 9 patients (14). While the authors reported no complications in their series, no cure rate was reported in the study. One patient was reported to have obtained an ultrasound, MRI, and Tc99-Sestamibi scan (12).

While the overall incidence of parathyroid adenocarcinoma is very rare (<1%), a high suspicion of malignancy may

influence the treatment option. Signs of parathyroid malignancy may include, but are not limited to, markedly elevated PTH and calcium, elevated alkaline phosphatase, or larger-sized glands (>3 cm) (32). Of the 163 patients treated in the reviewed studies, 159 (97.5%) patients had a single, localized gland, and 4 had two localized glands. Two of these 4 patients were reported to have achieved normal calcium but with elevated PTH levels at 6 months, suggesting a possible treatment failure due to multi-glandular disease (MGD) (18).

### *Anatomical considerations*

The parathyroid glands are four separate structures that usually sit posterior to the thyroid gland. The superior parathyroid glands are typically found posterior and lateral to the superior pole of the thyroid, approximately 1–2 cm superior to the recurrent laryngeal nerve and the inferior thyroid artery junction. The inferior parathyroid glands are often intimately associated with the inferior pole of the thyroid gland and lie just anterior to the coronal plane of the recurrent laryngeal nerve. The location of the inferior parathyroid glands is more variable than the location of the superior parathyroid glands. Additionally, ectopic parathyroid glands are not uncommon, with one study noting a presence of an ectopic gland in up to 22% of their surgically explored pHPT patients (33). The most common sites of ectopic parathyroid glands include the thymus (38%), retroesophageal region (31%), within the thyroid parenchyma (18%), and mediastinum (6%) (33).

Special consideration needs to be given not only to the identification and location of the diseased parathyroid glands but its relationship to the nearby critical structures. Parathyroid glands which are deep and/or paratracheal are presumed to be in close proximity to the recurrent laryngeal nerve and/or esophagus and are less ideal candidates for RFA. Since the anatomical variation of the recurrent laryngeal nerve is relatively high and the nerve cannot be traced or visualized on imaging, thorough anatomical consideration and planning are vital in avoiding inadvertent complications and preserving the recurrent laryngeal nerve function (34). Similarly, laterally located parathyroid glands found near the carotid sheath, which houses the vagus nerve, carotid artery, and internal jugular vein, also need to be considered carefully for the feasibility of RFA. Intrathyroidal parathyroid adenomas, however, are favorable for RFA as their enclosure within thyroidal tissue confers a safe barrier from thermal spread to critical structures and

enables more complete ablation of parathyroid tissue. Most of the identified parathyroid adenomas located in eutopic positions and of reasonable size are amenable to RFA.

### *Patient selection*

Patients with significant comorbidities, who are deemed less than ideal candidates for surgery, may be considered for treatment of pHPT with RFA. Besides the understandable, anesthesia-related concerns in the setting of cardiopulmonary comorbidities, patient age also plays a role in weighing the risks versus the benefits in surgical decision-making, although no clear consensus exists as to the implication of the patient's age on parathyroidectomy (35,36). An analysis of 7,313 pHPT patients found that patients 65 years or older often had extended hospital stays (7.7% *vs.* 6.5%,  $P < 0.01$ ) and were more likely to have more than 1 postoperative complication (2.2% *vs.* 1.3%,  $P < 0.01$ ) (37). Patients 80 years or older were found to have higher mortality rates (0.8% *vs.* <0.1%,  $P < 0.01$ ) as well (37). Patient BMI has been also shown to influence surgical outcome in parathyroidectomy, with class II obesity (BMI >35 kg/m<sup>2</sup>) patients requiring an overnight stay more often (34% *vs.* 26%,  $P < 0.05$ ) than patients with lower BMI (BMI <35 kg/m<sup>2</sup>) (38).

Patients with cosmetic concerns for a transverse cervical scar or keloid tendency often prefer a scarless treatment to traditional parathyroidectomy. While scarless parathyroidectomy options via remote access parathyroidectomy do exist, they are not as widely performed and accessible a procedure in many countries including the US, and the associated cost of the procedure is a barrier to many who simply wish to avoid incision-related risks (39). Minimal post-operative incisional and musculoskeletal pain, no significant anesthesia-associated complications, and quicker recovery with no time off from work or activity restrictions are additional benefits of RFA that appeal to select patients.

Special considerations can be given to pHPT in pregnancy. Since RFA can be performed without anesthesia and require less analgesia for procedure-related pain, it may be a superior and fitting alternative to parathyroidectomy, regardless of the gestational age of the patient. In the literature, Zhang *et al.* described a case of a 39-year-old female who had her pHPT successfully treated with RFA in her second trimester. The patient had a normal pregnancy post-procedure, delivered a healthy baby, and maintained normal serum calcium and PTH levels at a one-year follow-

up (24). One of the recommendations for performing RFA in pregnancy or patients with an electrical cardiac device is the use of bipolar electrode under continuous monitoring (40).

### Treatment with RFA

Ultrasound-guided RFA of parathyroid glands is performed using an electrode with a small 5–10 mm active tip, similar to RFA of thyroid nodule application. Patients are placed in a supine position with their neck slightly extended for better access and visibility on ultrasound. The usual standard sterile technique and skin preparation are used. Ultrasound is performed to locate the previously imaged parathyroid adenoma. 1% lidocaine is injected into the skin where the electrode is inserted. If separation of the parathyroid adenoma from the surrounding structures is needed, dextrose in 5% water (D5W) is used for hydrodissection and mobilization of the parathyroid gland to a more accessible, safe location. Most of the reviewed studies reported utilizing hydrodissection for parathyroid adenoma ablation (12,13,15–23,25,27). Continuous infusion of D5W throughout the procedure may allow the “heat sink effect” which may minimize the risk of thermal injury to adjacent structures such as the carotid artery, internal jugular vein, trachea, esophagus, and recurrent laryngeal nerve (41). Of note, no intraoperative PTH (IOPTH) monitoring was performed during any of the reported RFA treatments.

### Technique

The moving-shot technique along with the trans-isthmic approach has been advocated as a safe RFA technique for the treatment of thyroid nodules (41,42). As the electrode is inserted into the isthmus and the thyroid nodule is ablated from the medial to the lateral direction, the tracheoesophageal groove where the recurrent laryngeal nerve travels, is better protected from the thermal energy spread. The shaft of the electrode rests on the trachea, so there is an added benefit of obtaining electrode stability in the case the patient coughs, speaks, or swallows saliva (41). In our review, only two studies specifically reported using the trans-isthmic approach for parathyroid ablation, but it is a standard technique adopted by many who perform RFA in the neck (18,25). The moving-shot technique is performed for both the thyroid nodules and parathyroid glands, although it is more technically difficult in parathyroid glands as the target is typically smaller and less stationery

than thyroid nodules. The moving-shot technique considers the parathyroid adenoma to be made of smaller conceptual spheres and strategically creates ablation spheres as the tip moves through the parathyroid adenoma. The moving-shot technique typically proceeds from the deep to the superficial layer, so imaging on ultrasound is maintained and not blurred by the induction of microbubbling from ablation (43,44). The efficacy of RFA relies on factors such as ablative power and total energy delivered to the soft tissue. The mean of pooled power in the studies was 31.4 W (range, 5–100 W) (12–14,16,18,22), which is less than approximately 55 W typically delivered for thyroid nodule ablation (45).

### Post-treatment evaluation

Immediately following RFA, patients were typically observed for a short period of time for adequate pain control and any signs of procedural complication. Post-procedure, patients were followed up at various intervals which were deemed reasonable, ranging from 1 day, 1 week, 1 month, 3 months, 6 months, and up to 12 months (12,16,20). At follow-up visits, patients were evaluated for resolution of symptoms, complications, changes on ultrasound, as well as calcium and PTH levels. Some patients with abnormal biochemical data at 6 months were evaluated by Tc99m-Sestamibi scan for residual disease (20).

### Outcomes

A total of 14 publications that described RFA for the treatment of pHPT were included for the review (12–16,18–20,22–27) (Tables 1,2). The studies are from 7 different countries, with 7 studies originating from China and Korea. Six of the 14 published studies were case reports. Table 3 depicts the appraisal assessment. All studies met at least 50% of the JBI criteria, with four works meeting full criteria. A total of 167 parathyroid glands in 163 pHPT patients underwent ultrasound-guided RFA. A majority of the patients (n=159, 97.5%) had a single, localized gland, while 4 patients had two parathyroid glands localized. Demographically, 114 (69.9%) patients were female and 49 (30.1%) were male with a mean age of 58.49 years (range, 18–92 years). Of the 91 parathyroid glands with their locations described, 26 (28.6%) were superior glands, while 63 (69.2%) were inferior glands (12,16,18,20,22–27).

Most of the RFA patients either declined to undergo

**Table 3** Assessment of methodological quality

Study	Study design	Q1	Q2	Q3	Q4	Q5	Q6	Q7	Q8	Q9	Q10	Q11	Total
Ha <i>et al.</i> (15)	Cohort	Y	Y	Y	Y	U	Y	Y	Y	Y	N	Y	9
Wei <i>et al.</i> (16)	Cohort	Y	Y	Y	U	U	Y	Y	Y	Y	N	Y	8
Li <i>et al.</i> (18)	Cohort	NA	NA	Y	Y	Y	Y	Y	Y	Y	NA	Y	8
Ebrahminik <i>et al.</i> (19)	Cohort	NA	NA	Y	Y	Y	Y	Y	Y	U	N	Y	7
Peng <i>et al.</i> (20)	Cohort	Y	Y	Y	Y	NA	Y	Y	Y	Y	NA	Y	9
Xu <i>et al.</i> (12)	Case series	Y	Y	Y	NA	Y	Y	Y	Y	Y	Y	–	9
Sormaz <i>et al.</i> (13)	Case series	Y	Y	Y	NA	Y	N	Y	Y	N	Y	–	7
Korkusuz <i>et al.</i> (14)	Case series	Y	Y	Y	NA	Y	N	Y	Y	N	Y	–	7
Hänsler <i>et al.</i> (22)	Case report	Y	Y	Y	Y	Y	Y	U	Y	–	–	–	7
Kim <i>et al.</i> (23)	Case report	Y	Y	Y	Y	Y	Y	Y	Y	–	–	–	8
Sattarinezhad <i>et al.</i> (26)	Case report	Y	Y	Y	Y	Y	Y	Y	Y	–	–	–	8
Shenoy <i>et al.</i> (27)	Case report	Y	Y	Y	Y	Y	N	Y	Y	–	–	–	7
Zhang <i>et al.</i> (24)	Case report	Y	Y	Y	Y	Y	Y	Y	Y	–	–	–	8
Hussain <i>et al.</i> (25)	Case report	Y	Y	Y	Y	Y	Y	Y	Y	–	–	–	8

Joanna Briggs Institute critical appraisal for cohort studies, case series, and case reports. For cohort studies, Q1: Were the two groups similar and recruited from the same population? Q2: Were the exposures measured similarly to assign people to both exposed and unexposed groups? Q3: Was the exposure measured in a valid and reliable way? Q4: Were confounding factors identified? Q5: Were strategies to deal with confounding factors stated? Q6: Were the groups/participants free of the outcome at the start of the study (or at the moment of exposure)? Q7: Were the outcomes measured in a valid and reliable way? Q8: Was the follow up time reported and sufficient to be long enough for outcomes to occur? Q9: Was follow up complete, and if not, were the reasons to loss to follow up described and explored? Q10: Were strategies to address incomplete follow up utilized? Q11: Was appropriate statistical analysis used? For case series, Q1: Were there clear criteria for inclusion in the case series? Q2: Was the condition measured in a standard, reliable way for all participants included in the case series? Q3: Were valid methods used for identification of the condition for all participants included in the case series? Q4: Did the case series have consecutive inclusion of participants? Q5: Did the case series have complete inclusion of participants? Q6: Was there clear reporting of the demographics of the participants in the study? Q7: Was there clear reporting of clinical information of the participants? Q8: Were the outcomes or follow up results of cases clearly reported? Q9: Was there clear reporting of the presenting site(s)/clinic(s) demographic information? Q10: Was statistical analysis appropriate? For case reports, Q1: Were patient's demographic characteristics clearly described? Q2: Was the patient's history clearly described and presented as a timeline? Q3: Was the current clinical condition of the patient on presentation clearly described? Q4: Were diagnostic tests or assessment methods and the results clearly described? Q5: Was the intervention(s) or treatment procedure(s) clearly described? Q6: Was the post-intervention clinical condition clearly described? Q7: Were adverse events (harms) or unanticipated events identified and described? Q8: Does the case report provide takeaway lessons? Y, yes; N, no; U, unclear; NA, not applicable.

parathyroidectomy (e.g., anxiety or fear of surgical scar) or were deemed poor candidates for surgical management due to their comorbidities (12-15,18-20,22,24-27). Several comorbidities described included patients with a history of deep vein thrombosis (13), heart failure (22), heart disease (19), brain damage (26), chronic vascular conditions (19), and/or acute necrotizing pancreatitis (13).

The overall cure rate, defined as normocalcemia at 6 months following RFA, was 91.2% (114/125) (13,15,16,18,20,22-27). With the limited data available, persistent disease was reported to be 4.65% (4/86) but

no recurrence was reported (0/86) during the reported follow-up period (13,20,22-27). Granular data could not be obtained from larger studies as they tended to report the aggregate mean calcium values pre- and post-ablation or lacked data at an appropriate interval.

The two patients from Sormaz *et al.* with persistent disease had the largest two parathyroid glands in their cohort of 5 patients (6.2 cm and 3.0 cm). At 6-month post-ablation, the two lesions continued to be large, despite achieving volume reduction rates of 53% (3.0 cm) and 66% (1.1 cm), respectively (13). One patient with persistent



hypercalcemia out of the 51 patients treated by Peng *et al.* was also seen to have residual tissue on postoperative contrast-enhanced ultrasound (20). Shenoy *et al.* reported a patient with persistent disease despite achieving a volume reduction rate of >50% as well. The patient was seen to have sub-centimeter residual tissue (initially 1.36 cm × 1.16 cm), which was subsequently treated by percutaneous ethanol injection. The patient maintained normal PTH and calcium levels at two-year follow-up (27).

### Complication

The overall reported complication rate was 3.07% (5/163). All five patients experienced dysphonia without a report of permanent dysphonia (12,16,20). Recurrent laryngeal nerve (RLN) injury was not documented by laryngoscopy. No hematoma or a major complication was reported following RFA for pHPT. Other less frequently reported procedure-related adverse effects included transient hypocalcemia, toothache, mild pain, and moderate subcutaneous edema.

### Discussion

Surgical treatment for pHPT was first performed by Felix Mandl in 1926 and has remained the gold-standard treatment for the past century (46). However, several advancements, such as parathyroid imaging techniques, utilization of intraoperative adjuncts such as IOPTH monitoring and parathyroid autofluorescence detection, and improved surgical instrumentation, have considerably changed the way modern-day parathyroidectomy is performed (47). Percutaneous intervention for pHPT is the latest addition to the treatment algorithm of pHPT.

RFA has several advantages over conventional parathyroidectomy in select patients with a localized parathyroid adenoma. General anesthesia is typically not required for RFA, which makes RFA an appealing option for the elderly and patients with significant cardiac or pulmonary comorbidities. By using local anesthesia alone, patients experience significantly less post-operative nausea and emesis and other anesthesia-related side effects (47). RFA is also a relatively quicker procedure than parathyroidectomy, taking approximately 15–30 minutes. Even accounting for the cost of the disposable electrode, RFA may be more cost-effective than parathyroidectomy, as it can be performed in the clinic and not in the operating room with general anesthesia. Patients report minimal discomfort and return to work time is arguably shorter than

parathyroidectomy, with fewer post-procedural restrictions in addition. Another benefit is the superior cosmetic result of RFA, as it is a scarless procedure. Traditional parathyroidectomy leaves a 2–6 cm transverse scar across the lower anterior neck, which may become quite noticeable and even attention-grabbing in rare cases. For a sizable portion of the pHPT patient population, a permanent scar in visible location and cosmetic outcome are significant concerns (48).

A patient with a single, well-localized parathyroid adenoma seen on the ultrasound is the most appropriate candidate for the treatment of pHPT with RFA. Although it is technically possible to ablate multiple parathyroid glands, the glands tend to be smaller and not as easily delineated in hyperplasia. Adding to the consideration is extended procedural time which may lead to increased patient discomfort from positioning, multiple skin punctures, and internal heat generation. MGD necessitating multiple ablation attempts, may increase the risk of complication and decrease the chance of cure. While Li *et al.* reported a technical success rate of 100% with all of their 25 patients achieving normocalcemia at 6 months, 3 patients required more than one ablation session, with one patient undergoing RFA three times due to the risk to the RLN (18). In patients with secondary hyperparathyroidism, which is generally considered a MGD, a recent meta-analysis [2019] reported that thermal ablation increased the risk of persistent and recurrent disease as compared to parathyroidectomy (OR =4.24, 95% CI: 1.44–15.76, P=0.03) (49).

From the available data in the reviewed studies, the overall cure rate for pHPT with RFA at 91.2% is lower than the conventional parathyroidectomy cure rate of 95–98%, although the analyzed sample size is very small at 125 patients. Some of the reasons for RFA failure include incomplete ablation of larger parathyroid glands (>3.0 cm), presence of MGD, or difficult procedure with uncooperative patients (13,16). No study mentioned utilizing IOPTH during RFA for pHPT. It is unclear if implementing IOPTH is necessary to achieve more therapeutic ablation, however. Utilizing IOPTH would certainly prolong the procedure duration and may be associated with increased patient discomfort and risk from a longer, awake procedure.

Five patients experienced dysphonia (4 temporary, 1 unspecified duration) but no permanent RLN injury was reported as a complication (12,16,20). No major complication was reported in any of the studies. The combined overall complication rate of 3.07% (5/163) for pHPT is somewhat similar to the outcomes of 1,543 benign

thyroid nodules treated with RFA by Baek *et al.*, where temporary and permanent complications were noted in 3.3% and 0.13%, respectively (50).

Several other ablation techniques besides RFA have been utilized for the treatment of pHPT in recent years. Although the studies are generally of smaller cohorts and not comparative analyses, several studies have described the use of laser (51-53), microwave (54,55), and HIFU (56-58) for ablation of parathyroid glands. Using laser ablation, Appelbaum *et al.* demonstrated an average volume reduction of 72% and normocalcemia in all patients at the 6-month mark in their 12-patient series (53). Only temporary dysphonia was noted in one patient as a procedure-related complication. In a different study, two out of three patients (66.66%) did not achieve a cure and had persistent disease following laser ablation (52). Liu *et al.* compared the safety and efficacy of microwave ablation and surgical resection (54). The authors found that their 28-patient microwave ablation cohort had a shorter operation time ( $P < 0.001$ ) but similar rates of cure ( $P = 0.705$ ) and complication ( $P = 0.752$ ) as the surgical cohort of 28 propensity-matched patients (54). Another study consisting of 22 patients demonstrated an 86.36% success rate using microwave ablation but reported a significant rate of complications such as transient dysphonia and needle tract bleeding with rates of 36.36% (8/22) and 9.09% (2/22), respectively (55). With respect to HIFU, a four-patient series treated for pHPT determined biochemical cure (normocalcemia at 6 months) in only 50% of patients (57). Similarly, Ambrosini *et al.* found a 50% rate (2/4) of normocalcemia at the 6-month follow-up after HIFU (58). While other methods of percutaneous treatment modalities are still under investigation and each may have its place, RFA stands out as the most utilized and studied in the literature. Future studies, as well as comparative analyses, are necessary to quantitatively assess these thermo-ablative technologies.

RFA is not without several weaknesses as a treatment modality for pHPT. Firstly, the procedure precludes the determination of specimen pathology. Unlike thyroid nodules, fine-needle aspiration of parathyroid glands is associated with significant inflammation, scarring, and may result in a more challenging subsequent parathyroid procedure (59). Given that determination of malignancy is not feasible on FNA, along with the extremely low overall incidence rate of parathyroid carcinoma, FNA

of the parathyroid gland before RFA is generally not useful or necessary, unless FNA is performed for PTH aspirate to confirm the gland is of parathyroid origin in rare cases. Any clinical presentation suspicious for parathyroid carcinoma such as severe acute hypercalcemia ( $>14$  mg/dL) should not undergo RFA ablation. Secondly, a concern for parathyromatosis exists for both FNA and RFA (19). Parathyromatosis is thought to occur following gland rupture, allowing the seeding of parathyroid tissue. There was no report of parathyromatosis post-RFA, and parathyromatosis was not implicated in either persistent or recurrent disease, however. Finally, for those patients who do not achieve a cure following RFA, a repeat RFA or parathyroidectomy is still feasible, yet should be carefully considered. Several studies described the use of multiple ablation sessions or ethanol ablation for the same residual gland or additional gland (13,15,16,18), while in others parathyroidectomy was undertaken (13,15).

The current review has several limitations. At least a half of the reviewed studies were a single case study by a single operator, resulting in a small, overall patient pool. However, the case studies provided the granular details to understand the outcome in each case, whereas larger cohort studies only provided mean values and did not allow adequate correlation and comparison across the studies. Long-term data are also lacking in many studies as the application of RFA for pHPT is relatively recent. Additionally, the standard definition of cure, normocalcemia at 6 months, for pHPT cannot be widely applied for RFA treatment, as a handful of patients underwent multiple RFA sessions within 6 months due to sonographic evidence of viable, residual tissue (13,15,18). Furthermore, volume reduction of gland may continue beyond a 6-month duration, as is the case for thyroid nodules (42).

More systematic studies and experience with RFA for pHPT are needed for the effective deployment of this alternative treatment option, as the current evidence in the literature is growing but not robust. The use of IOPTH monitoring in RFA and what role, if any, it would serve is not yet explored. Additionally, studies investigating the influence of relevant thermodynamic parameters, including the power, total energy, and impedance on the outcome, are warranted to maximize cure with a single-treatment and minimize complication rates. Lastly, formally adopted guidelines for RFA for pHPT would help deliver optimized and standardized care.

## Conclusions

RFA may be an appropriate and safe alternative to parathyroidectomy in select patients with a well-localized, well-located parathyroid adenoma. It may be a definitive treatment option in many patients, although a repeat procedure may be needed in some cases and long-term data is promising but not yet available. A thoughtful and comprehensive evaluation with regards to appropriate patient selection, parathyroid localization, disease characteristics, and operator familiarity with the proper technique should be carefully accounted prior to proceeding with RFA for pHPT.

## Acknowledgments

*Funding:* None.

## Footnote

*Provenance and Peer Review:* This article was commissioned by the Editorial Office, *Gland Surgery* for the series “RFA and Recent Innovations in Endocrine Surgery”. The article has undergone external peer review.

*Reporting Checklist:* The authors have completed the PRISMA reporting checklist. Available at <https://gs.amegroups.com/article/view/10.21037/gS-22-546/rc>

*Conflicts of Interest:* All authors have completed the ICMJE uniform disclosure form (available at <https://gs.amegroups.com/article/view/10.21037/gS-22-546/coif>). The series “RFA and Recent Innovations in Endocrine Surgery” was commissioned by the editorial office without any funding or sponsorship. E.K. served as the unpaid Guest Editor for the special series, and serves as an Editor-in-Chief of *Gland Surgery* from May 2017 to April 2024 and as a consultant of STARmed. The authors have no other conflicts of interest to declare.

*Ethical Statement:* The authors are accountable for all aspects of the work in ensuring that questions related to the accuracy or integrity of any part of the work are appropriately investigated and resolved.

*Open Access Statement:* This is an Open Access article distributed in accordance with the Creative Commons Attribution-NonCommercial-NoDerivs 4.0 International

License (CC BY-NC-ND 4.0), which permits the non-commercial replication and distribution of the article with the strict proviso that no changes or edits are made and the original work is properly cited (including links to both the formal publication through the relevant DOI and the license). See: <https://creativecommons.org/licenses/by-nc-nd/4.0/>.

## References

1. Yeh MW, Ituarte PH, Zhou HC, et al. Incidence and prevalence of primary hyperparathyroidism in a racially mixed population. *J Clin Endocrinol Metab* 2013;98:1122-9.
2. Wermers RA, Khosla S, Atkinson EJ, et al. Incidence of primary hyperparathyroidism in Rochester, Minnesota, 1993-2001: an update on the changing epidemiology of the disease. *J Bone Miner Res* 2006;21:171-7.
3. Sociedade Brasileira de Endocrinologia e Metabologia; Bandeira F, Griz L, et al. Diagnosis and management of primary hyperparathyroidism--a scientific statement from the Department of Bone Metabolism, the Brazilian Society for Endocrinology and Metabolism. *Arq Bras Endocrinol Metabol* 2013;57:406-24.
4. Thakker RV, Newey PJ, Walls GV, et al. Clinical practice guidelines for multiple endocrine neoplasia type 1 (MEN1). *J Clin Endocrinol Metab* 2012;97:2990-3011.
5. Pallan S, Khan A. Primary hyperparathyroidism: Update on presentation, diagnosis, and management in primary care. *Can Fam Physician* 2011;57:184-9.
6. Bilezikian JP, Brandi ML, Eastell R, et al. Guidelines for the management of asymptomatic primary hyperparathyroidism: summary statement from the Fourth International Workshop. *J Clin Endocrinol Metab* 2014;99:3561-9.
7. Bandeira F, Griz L, Caldas G, et al. From mild to severe primary hyperparathyroidism: The Brazilian experience. *Arq Bras Endocrinol Metabol* 2006;50:657-63.
8. Wilhelm SM, Wang TS, Ruan DT, et al. The American Association of Endocrine Surgeons Guidelines for Definitive Management of Primary Hyperparathyroidism. *JAMA Surg* 2016;151:959-68.
9. Schneider DE, Mazeh H, Chen H, et al. Predictors of recurrence in primary hyperparathyroidism: an analysis of 1386 cases. *Ann Surg* 2014;259:563-8.
10. Insogna KL. Primary Hyperparathyroidism. *N Engl J Med* 2018;379:1050-9.
11. Mansur A, Garg T, Shrigiriwar A, et al. Image-Guided Percutaneous Ablation for Primary and Metastatic

- Tumors. *Diagnostics (Basel)* 2022;12:1300.
12. Xu SY, Wang Y, Xie Q, et al. Percutaneous sonography-guided radiofrequency ablation in the management of parathyroid adenoma. *Singapore Med J* 2013;54:e137-40.
  13. Sormaz IC, Poyanlı A, Açar S, et al. The Results of Ultrasonography-Guided Percutaneous Radiofrequency Ablation in Hyperparathyroid Patients in Whom Surgery Is Not Feasible. *Cardiovasc Intervent Radiol* 2017;40:596-602.
  14. Korkusuz H, Wolf T, Grünwald F. Feasibility of bipolar radiofrequency ablation in patients with parathyroid adenoma: a first evaluation. *Int J Hyperthermia* 2018;34:639-43.
  15. Ha EJ, Baek JH, Baek SM. Minimally Invasive Treatment for Benign Parathyroid Lesions: Treatment Efficacy and Safety Based on Nodule Characteristics. *Korean J Radiol* 2020;21:1383-92.
  16. Wei Y, Peng CZ, Wang SR, et al. Microwave ablation versus radiofrequency ablation for primary hyperparathyroidism: a multicenter retrospective study. *Int J Hyperthermia* 2021;38:1023-30.
  17. Wei Y, Peng CZ, Wang SR, et al. Effectiveness and Safety of Thermal Ablation in the Treatment of Primary Hyperparathyroidism: A Multicenter Study. *J Clin Endocrinol Metab* 2021;106:2707-17.
  18. Li X, Tufano RP, Russell JO, et al. Ultrasound-Guided Radiofrequency Ablation for the Treatment of Primary Hyperparathyroidism: An Efficacy and Safety Study. *Endocr Pract* 2021;27:1205-11.
  19. Ebrahimini H, Chegeni H, Mosadegh Khah A, et al. Radiofrequency ablation of parathyroid adenomas causing primary hyperparathyroidism: A report of 27 patients. *J Clin Ultrasound* 2022;50:540-6.
  20. Peng CZ, Chai HH, Zhang ZX, et al. Radiofrequency ablation for primary hyperparathyroidism and risk factors for postablative eucalcemic parathyroid hormone elevation. *Int J Hyperthermia* 2022;39:490-6.
  21. Chai HH, Zhao Y, Zeng Z, et al. Efficacy and Safety of Ultrasound-Guided Radiofrequency Ablation for Primary Hyperparathyroidism: A Prospective Study. *Korean J Radiol* 2022;23:555-65.
  22. Hänslér J, Harsch IA, Strobel D, et al. Treatment of a solitary adenoma of the parathyroid gland with ultrasound-guided percutaneous Radio-Frequency-Tissue-Ablation (RFTA). *Ultraschall Med* 2002;23:202-6.
  23. Kim BS, Eom TI, Kang KH, et al. Radiofrequency ablation of parathyroid adenoma in primary hyperparathyroidism. *J Med Ultrason* (2001) 2014;41:239-43.
  24. Zhang X, Xu N, Wu Y, et al. Novel approaches for the management of primary hyperparathyroidism during pregnancy. *Clin Endocrinol (Oxf)* 2018;89:526-7.
  25. Hussain I, Ahmad S, Aljammal J. Radiofrequency Ablation of Parathyroid Adenoma: A Novel Treatment Option for Primary Hyperparathyroidism. *AACE Clin Case Rep* 2021;7:195-9.
  26. Sattarinezhad A, Rasekhi A, Soveid M. Management of a parathyroid adenoma with radiofrequency ablation: a case report. *Iran Red Crescent Med J* 2017;19:e35784.
  27. Shenoy MT, Menon AS, Nazar PK, et al. Radiofrequency Ablation Followed by Percutaneous Ethanol Ablation Leading to Long-Term Remission of Hyperparathyroidism. *J Endocr Soc* 2017;1:676-80.
  28. Kim HS, Choi BH, Park JR, et al. Delayed surgery for parathyroid adenoma misdiagnosed as a thyroid nodule and treated with radiofrequency ablation. *Endocrinol Metab (Seoul)* 2013;28:231-5.
  29. Peters MD, Godfrey CM, Khalil H, et al. Guidance for conducting systematic scoping reviews. *Int J Evid Based Healthc* 2015;13:141-6.
  30. Cheung K, Wang TS, Farrokhyar F, et al. A meta-analysis of preoperative localization techniques for patients with primary hyperparathyroidism. *Ann Surg Oncol* 2012;19:577-83.
  31. Suh YJ, Choi JY, Kim SJ, et al. Comparison of 4D CT, ultrasonography, and 99mTc sestamibi SPECT/CT in localizing single-gland primary hyperparathyroidism. *Otolaryngol Head Neck Surg* 2015;152:438-43.
  32. Bae JH, Choi HJ, Lee Y, et al. Preoperative predictive factors for parathyroid carcinoma in patients with primary hyperparathyroidism. *J Korean Med Sci* 2012;27:890-5.
  33. Roy M, Mazeh H, Chen H, et al. Incidence and localization of ectopic parathyroid adenomas in previously unexplored patients. *World J Surg* 2013;37:102-6.
  34. Shen C, Xiang M, Wu H, et al. Routine exposure of recurrent laryngeal nerve in thyroid surgery can prevent nerve injury. *Neural Regen Res* 2013;8:1568-75.
  35. Chigot JP, Menegaux F, Achrafi H. Should primary hyperparathyroidism be treated surgically in elderly patients older than 75 years? *Surgery* 1995;117:397-401.
  36. Tibblin S, Pålsson N, Rydberg J. Hyperparathyroidism in the elderly. *Ann Surg* 1983;197:135-8.
  37. Thomas DC, Roman SA, Sosa JA. Parathyroidectomy in the elderly: analysis of 7313 patients. *J Surg Res* 2011;170:240-6.
  38. Pitt SC, Panneerselvan R, Sippel RS, et al. Influence of morbid obesity on parathyroidectomy outcomes in primary hyperparathyroidism. *Am J Surg* 2010;199:410-4;

- discussion 414-5.
39. Aidan P, Ali DB, Murad F, et al. Outcome of Robot-Assisted Parathyroidectomy for Primary Hyperparathyroidism. *J Am Coll Surg* 2016;223:e97-8.
  40. Kim JH, Baek JH, Lim HK, et al. 2017 Thyroid Radiofrequency Ablation Guideline: Korean Society of Thyroid Radiology. *Korean J Radiol* 2018;19:632-55.
  41. Park HS, Baek JH, Park AW, et al. Thyroid Radiofrequency Ablation: Updates on Innovative Devices and Techniques. *Korean J Radiol* 2017;18:615-23.
  42. Kandil E, Omar M, Aboueisha M, et al. Efficacy and Safety of Radiofrequency Ablation of Thyroid Nodules: A Multi-institutional Prospective Cohort Study. *Ann Surg* 2022;276:589-96.
  43. Ha EJ, Baek JH, Lee JH. Ultrasonography-Based Thyroidal and Perithyroidal Anatomy and Its Clinical Significance. *Korean J Radiol* 2015;16:749-66.
  44. Sung JY, Baek JH, Kim KS, et al. Single-session treatment of benign cystic thyroid nodules with ethanol versus radiofrequency ablation: a prospective randomized study. *Radiology* 2013;269:293-300.
  45. Trimboli P, Deandrea M. Treating thyroid nodules by radiofrequency: is the delivered energy correlated with the volume reduction rate? A pilot study. *Endocrine* 2020;69:682-7.
  46. Carney JA. Carney JA. The glandulae parathyroideae of Ivar Sandström. Contributions from two continents. *Am J Surg Pathol* 1996;20:1123-44.
  47. Chen H, Pruhs Z, Starling JR, et al. Intraoperative parathyroid hormone testing improves cure rates in patients undergoing minimally invasive parathyroidectomy. *Surgery* 2005;138:583-7; discussion 587-90.
  48. Brown BC, McKenna SP, Siddhi K, et al. The hidden cost of skin scars: quality of life after skin scarring. *J Plast Reconstr Aesthet Surg* 2008;61:1049-58.
  49. Gong L, Tang W, Lu J, et al. Thermal ablation versus parathyroidectomy for secondary hyperparathyroidism: A meta-analysis. *Int J Surg* 2019;70:13-8.
  50. Baek JH, Lee JH, Sung JY, et al. Complications encountered in the treatment of benign thyroid nodules with US-guided radiofrequency ablation: a multicenter study. *Radiology* 2012;262:335-42.
  51. Andrioli M, Riganti F, Pacella CM, et al. Long-term effectiveness of ultrasound-guided laser ablation of hyperfunctioning parathyroid adenomas: present and future perspectives. *AJR Am J Roentgenol* 2012;199:1164-8.
  52. Adda G, Scillitani A, Epaminonda P, et al. Ultrasound-guided laser thermal ablation for parathyroid adenomas: analysis of three cases with a three-year follow-up. *Horm Res* 2006;65:231-4.
  53. Appelbaum L, Goldberg SN, Ierace T, et al. US-guided laser treatment of parathyroid adenomas. *Int J Hyperthermia* 2020;37:366-72.
  54. Liu F, Yu X, Liu Z, et al. Comparison of ultrasound-guided percutaneous microwave ablation and parathyroidectomy for primary hyperparathyroidism. *Int J Hyperthermia* 2019;36:835-40.
  55. Fan BQ, He XW, Chen HH, et al. US-guided microwave ablation for primary hyperparathyroidism: a safety and efficacy study. *Eur Radiol* 2019;29:5607-16.
  56. Kovatcheva R, Vlahov J, Stoinov J, et al. US-guided high-intensity focused ultrasound as a promising non-invasive method for treatment of primary hyperparathyroidism. *Eur Radiol* 2014;24:2052-8.
  57. Kovatcheva RD, Vlahov JD, Shinkov AD, et al. High-intensity focused ultrasound to treat primary hyperparathyroidism: a feasibility study in four patients. *AJR Am J Roentgenol* 2010;195:830-5.
  58. Ambrosini CE, Cianferotti L, Picone A, et al. High-intensity focused ultrasound as an alternative to the surgical approach in primary hyperparathyroidism: a preliminary experience. *J Endocrinol Invest* 2011;34:655-9.
  59. Norman J, Politz D, Browarsky I. Diagnostic aspiration of parathyroid adenomas causes severe fibrosis complicating surgery and final histologic diagnosis. *Thyroid* 2007;17:1251-5.

**Cite this article as:** Issa PP, Kandil E, Lee GS. Radiofrequency ablation as a treatment modality for primary hyperparathyroidism: a systematic literature review. *Gland Surg* 2024;13(1):87-99. doi: 10.21037/gs-22-546