



Tension-free thyroidectomy (medial thyroidectomy) – a prospective study: surgical technique and results of 259 operations

Ilya Sleptsov^{1^}, Roman Chernikov^{1^}, Alexander Pushkaruk^{1^}, Ilya Sablin^{1^}, Tillo Tilloev^{1^}, Natalia Timofeeva^{1^}, Kseniia Gerasimova^{1^}, Dmitrii Buzanakov^{1^}, Shamil Shikmagomedov^{1^}, Svetlana Alekseeva^{1^}, Polina Knyazeva², Alexander Bubnov¹

¹Department of Endocrine Surgery, Saint Petersburg State University Hospital, Saint Petersburg, Russian Federation; ²Center for Minimally Invasive Surgery, Kliniken Essen-Mitte, Essen, Germany

Contributions: (I) Conception and design: I Sleptsov, R Chernikov, A Bubnov; (II) Administrative support: A Bubnov, R Chernikov; (III) Provision of study materials or patients: I Sleptsov; (IV) Collection and assembly of data: S Alekseeva, A Pushkaruk, K Gerasimova, S Shikmagomedov, T Tilloev; (V) Data analysis and interpretation: I Sleptsov, N Timofeeva, A Pushkaruk, D Buzanakov, P Knyazeva; (VI) Manuscript writing: All authors; (VII) Final approval of manuscript: All authors.

Correspondence to: Ilya Sleptsov, MD, DSc. Department of Endocrine Surgery, Saint Petersburg State University Hospital, Fontanka Embankment, 154, 190103 Saint Petersburg, Russian Federation. Email: newsurgery@yandex.ru.

Background: Thyroid surgery is associated with a number of surgical complications including recurrent laryngeal nerve (RLN) injury and hypoparathyroidism. The existing methods share the same principle—the mobilization of the thyroid from the lateral side. The aim of this study was to evaluate the safety of a novel technique of thyroidectomy—tension-free thyroidectomy (TFT) based on the medial approach to the laryngeal nerves and parathyroid glands (PTGs).

Methods: The study was conducted between August 2021 and July 2022 in Saint Petersburg State University Hospital. A total of 261 patients with thyroid diseases were enrolled in the study and operated on using the TFT technique.

Results: The operations with the use of TFT technique were completed in all but two cases which required the conversion to the standard lateral approach. Of 259 TFT cases unilateral laryngeal paresis was registered in 6 (2.3%) cases or in 1.7% of the number of RLNs at risk. In all but one case the vocal fold function recovered in less than 6 months of the follow-up. Among 87 patients who underwent total thyroidectomy transient postoperative hypoparathyroidism was found in 10 cases (11.5%), rate of persistent hypoparathyroidism was 0%. One case of postoperative bleeding was recorded (0.4%).

Conclusions: The TFT technique demonstrated high safety and several advantages over the traditional method of performing operations on the thyroid gland.

Keywords: Thyroidectomy; laryngeal nerve injury; hypoparathyroidism

Submitted Apr 13, 2023. Accepted for publication Jul 20, 2023. Published online Aug 22, 2023.

doi: 10.21037/gs-23-147

View this article at: <https://dx.doi.org/10.21037/gs-23-147>

[^] ORCID: Ilya Sleptsov, 0000-0002-1903-5081; Roman Chernikov, 0000-0002-3001-664X; Alexander Pushkaruk, 0000-0002-9225-0626; Ilya Sablin, 0000-0001-7912-4580; Tillo Tilloev, 0000-0002-4367-7711; Natalia Timofeeva, 0000-0001-6594-8845; Kseniia Gerasimova, 0000-0002-1632-3918; Dmitrii Buzanakov, 0000-0001-8350-8376; Shamil Shikmagomedov, 0000-0002-3876-6306; Svetlana Alekseeva, 0000-0002-7177-0948.

Introduction

One of the most important tasks in thyroid surgery is to prevent specific complications: recurrent laryngeal nerve (RLN) palsy and hypoparathyroidism. In recent years, numerous technical solutions have been introduced into clinical practice to address this issue, including intraoperative neuromonitoring (IONM), fluorescent visualization of the parathyroid glands (PTGs), and methods for assessing their perfusion. However, published results of clinical studies indicate that there has not been a radical change in the rate of the vocal fold palsy (1), and the role of parathyroid fluorescent imaging is not yet well established, though promising results have been obtained (2). One of the possible explanations may be found in the fact that surgeons worldwide still use the same methodology of operation, which principles were developed by Theodor Kocher yet at the end of the 19th century. This technique is based on the lateral approach to the vessels of the thyroid gland and the RLN (3). Although the medial approach to the RLN is described, the use of this method remains limited to the selected cases (4–6), meanwhile some data on its safety and feasibility already are being reported (7). Our preliminary study (8) has shown that the change of the paradigm and the routine application of the medial approach may have a positive effect on the overall complication rate.

The aim of this study was to evaluate the results of medial thyroidectomy [tension-free thyroidectomy (TFT)] as an alternative method of thyroid surgery. We present this article in accordance with the TREND reporting checklist (available at [https://gs.amegroups.com/article/](https://gs.amegroups.com/article/view/10.21037/gS-23-147/rc)

[view/10.21037/gS-23-147/rc](https://gs.amegroups.com/article/view/10.21037/gS-23-147/rc)).

Methods

Patients

The study was conducted between August 2021 and July 2022 in Saint Petersburg State University Hospital—a tertiary referral center. During this period, 270 patients with thyroid diseases were consequently operated on using the TFT technique. The inclusion criteria were: primary thyroid surgery, repeated thyroid surgery in the absence of hypoparathyroidism, and laryngeal nerve dysfunction after the initial intervention. The exclusion criteria included the presence of preoperative dysfunction of the RLN and PTGs, the concomitant primary hyperparathyroidism, the patient's age up to 18 years, anaplastic thyroid carcinoma. After the exclusion criteria were applied to the group, 261 patients remained in the study group.

In the inclusion group continuous sampling was applied: all patients regardless of diagnosis, age, gender, and other clinical parameters, underwent surgery with the TFT technique. The operations with the TFT technique were completed in all but two cases. In those two cases, it was decided to proceed with the standard method of surgery after deep mobilization of the medial surface of the thyroid lobe from the trachea, due to the density of the posterior fibers of Berry's ligament in the area of the recurrent nerve entrance to the larynx.

The final study group consisted of 261 patients—212 (81.2%) were female and 49 (18.8%) were male. The mean age was 45 ± 13 years. The extent and the duration of the surgeries are presented in *Table 1*. Overall, 348 RLNs and 696 PTGs were at risk.

The control group was assembled from a historical cohort. Patients, who were operated on by the same surgeon from August, 2020 to July, 2021 were included, and the same inclusion and exclusion criteria, were applied. The surgery protocols, postoperative laryngoscopy reports and biochemical data were assessed. The control group included 337 patients—277 (82.2%) were female and 60 (17.8%) were male. The mean age was 44 ± 15 years. Overall, 471 RLNs and 942 PTGs were at risk.

Surgery

All operations were performed under endotracheal anesthesia. The surgical team generally included two

Highlight box

Key findings

- Tension-free thyroidectomy (TFT) is a safe and effective approach with several advantages over traditional technique.

What is known and what is new?

- While medial approach is known, it is rarely used and its use is limited to the selected cases.
- This study describes in detail the modified method and justifies the concepts of medial approach, showing that the routine application of TFT is feasible in most cases and can reduce the rate of surgical complications.

What is the implication, and what should change now?

- This study calls for a paradigm shift in thyroid surgery, promoting the adoption of TFT as a preferred method for achieving better results.

Table 1 Types of operations and their duration

Operation	Number of patients	Mean duration (min)	SD
Hemithyroidectomy	116	56	15
Hemithyroidectomy, central cervical lymph node dissection	55	66	17
Hemithyroidectomy, central cervical lymph node dissection, lateral cervical lymph node dissection	3	158	60
Thyroidectomy	51	111	34
Thyroidectomy, central cervical lymph node dissection	25	118	26
Thyroidectomy, central cervical lymph node dissection, lateral cervical lymph node dissection	11	180	40

SD, standard deviation.

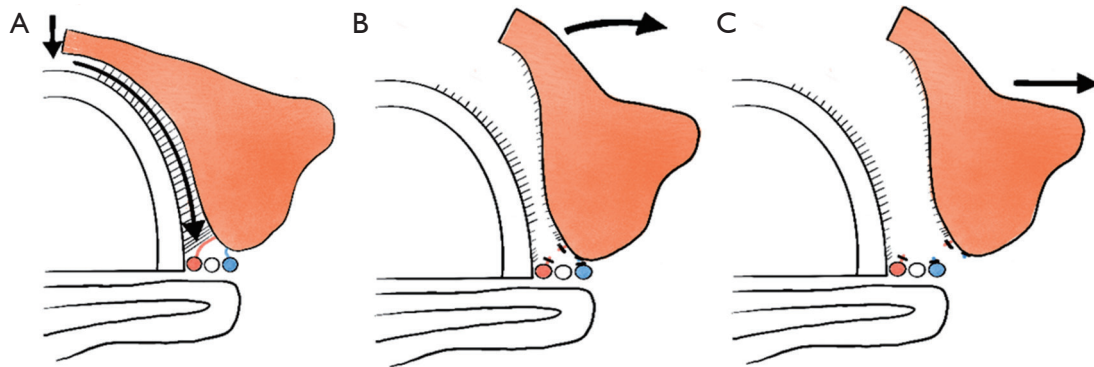


Figure 1 Stages of the operation according to the TFT methodology—dissection of Berry's ligament: (A) dividing the isthmus; (B) dissection of Berry's ligament; (C) lateral traction of thyroid lobe. The arrows indicate the direction of dissection (A) and traction (B,C). TFT, tension-free thyroidectomy.

surgeons or three surgeons if the lateral cervical lymph node dissection was performed. Univet binocular magnifiers ($\times 2.5$ magnification), a Dr. Kim headlamp, an inomed C2 neurostimulator, ERBE VIO3 electrocoagulation, Ethicon Harmonic ultrasonic scalpel, Grena titanium clips 3 and 10 mm were used. The procedure of the operation is described below.

After the skin incision, the thyroid gland is exposed. Medial bundles of the sternothyroid muscle are transected with a harmonic scalpel at 1 cm from the line of the muscle attachment to the thyroid cartilage. Thus, better visualization of the upper pole vessels is provided. The isthmus of the thyroid gland is divided, and then Berry's ligament is completely dissected with the bipolar cutting mode (*Figure 1*). During ligament dissection, the position of the RLN is mapped with the use of IONM (the stimulation amplitude was 5 mA). The posterior sections of Berry's

ligament are dissected using electrocoagulation, clipping, or vascular ligation. After the complete mobilization of the thyroid gland from the trachea and Berry's ligament, the terminal branches of the inferior thyroid artery, are dissected. The superior PTG is mobilized medially from the upper pole of the lobe of the gland, with the preservation of the anastomosis between the superior and inferior parathyroid arteries if is visualized (*Figure 2*). The inferior PTG is mobilized with the preservation of its veins, passing along the medial and lateral surfaces of the thymus. After the complete separation of the PTGs from the thyroid, the latter is extracted into the wound, starting from the lower pole. The thyroid lobe is pulled down, increasing the distance between the cricothyroid muscle and the edge of the upper pole of the thyroid gland. Then the external branch of the superior laryngeal nerve (EBSLN) is identified using IONM. After the nerve is

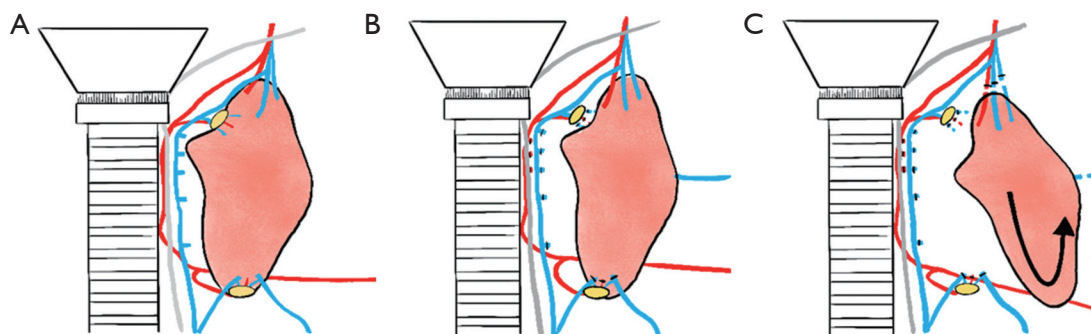


Figure 2 Stages of the operation according to the TFT methodology—preservation of the parathyroid vessels: (A) anatomy of the parathyroid vessels; (B) preservation of the anastomosis between superior and inferior PTGs; (C) transection of Kocher's vein and the upper pole. TFT, tension-free thyroidectomy; PTGs, parathyroid glands.

found, the vessels of the upper pole of the thyroid gland are separated (with an ultrasonic harmonic scalpel or ligation). In cases with central cervical lymph dissection, the upper horns of the thymus are preserved. Central cervical lymph node dissection is performed before total thyroidectomy or the lobectomy. When performing lateral cervical lymph dissection, this stage is performed first, before the manipulations in the central area of the neck.

Standard protocol of IONM is used:

- ❖ V1—vagus nerve function monitoring before resection;
- ❖ R1—control of the function of the recurrent nerve before resection;
- ❖ R2—control of the function of the recurrent nerve after resection;
- ❖ V2—control of vagus nerve function after resection.

The function of the EBSLN is controlled using electrical stimulation after the removal of the thyroid lobe.

Follow-up

Ultrasound laryngoscopy was performed on all patients, before the surgery and on the 1st postoperative day. If the sonographic visualization of the vocal cords was not achieved or damage to their mobility was detected, an endoscopic laryngoscopy was performed (flexible endoscope 4 mm, video recording).

Patients who underwent complete removal of thyroid tissue had a blood test for parathyroid hormone (PTH) in 1 hour and 1 day after the surgery, and also a blood test for ionized calcium 1 day after the surgery. If the PTH level was

decreased, a control blood test for PTH and ionized calcium was performed in 14, 30, and 90 days after the surgery.

Ethics

The study was conducted in accordance with the ethical principles outlined in the Declaration of Helsinki (as revised in 2013) and all applicable laws and regulations. The study received ethics approval from the Local Ethics Committee of Saint Petersburg State University Hospital, reference number 93-1 of 17.07.2021. Informed consent was taken from all the patients.

Statistical analysis

Each individual was analyzed to assess intervention effects. To assess the normality of the data Shapiro-Wilk test was used. Categorical data were compared using Pearson chi-square test. Statistical analysis was performed in SPSS Statistics (IBM Corporation, Armonk, NY, USA).

Results

The mean duration of surgical interventions is shown in *Table 1*. During the study, no significant change in the duration of the operations was observed (one-sample Wilcoxon signed-rank test P values were 0.945 and 0.331 for hemithyroidectomy and total thyroidectomy respectively).

The function of PTG was evaluated in 87 patients who underwent complete removal of thyroid tissue with/without concomitant removal of regional lymph nodes. In 10 cases, a decrease in the level of PTH was found

(11.5%), while 6 out of 10 patients had an increase in the level of PTH on the 1st postoperative day in a comparison with the level in 1 hour after surgery. The incidence of hypoparathyroidism appeared to be significantly lower (chi-square: 4.73, $P=0.03$) than in a group of historical control, in which of 134 cases with postoperative PTH assessment, low PTH level was observed in 30 cases (23.1%). Evaluation of the PTG function after a more distant period (up to 12 months after surgery) showed the restoration of the PTG function in 10 out of 10 patients. Thus, by the time of the writing of this article, no cases of persistent postoperative hypoparathyroidism were recorded. It should be noted that in this group 35 out of 87 patients (40%), total thyroidectomy was performed together with the central cervical lymph node dissection, and in 10 cases (11.5%)—with the lateral cervical lymph node dissection. Of the 52 patients who only underwent total thyroidectomy, 28 patients underwent surgery for toxic goiter, while in 15 patients the volume of the thyroid gland exceeded 60 mL (average volume 147.8 ± 110.9 mL). There was no correlation between the probability of hypoparathyroidism and the performance of central cervical lymph node dissection or a large volume of the thyroid gland. According to histological reports, an accidentally removed PTG was detected in 1 case. In 17 cases fragments of normal parathyroid tissue were detected in the specimen. Thus, the risk of the accidental removal of PTGs was 0.39% of the number of operations and 0.14% of the number of PTGs at risk. The risk of removal of a fragment of a PTG was 6.6% of the number of operations and 2.5% of the number of PTGs at risk.

Unilateral RLN palsy was registered in 6 patients (2.3% of the total number of TFT cases or 1.7% of the number of RLNs at risk by TFT). There were no cases of direct damage to the RLN trunk during the TFT. With two cases, when the RLN injury occurred after the lateral conversion, the overall RLN palsy rate is 3% of operations and 2.3% of nerves at risk. The incidence of unilateral RLN palsy tended to be lower than in a retrospective control group, in which it had been reported in 20 cases (5.9% of patients and 4.2% of the numbers of RLNs at risk), but without achieving statistical significance ($P=0.1$ and $P=0.13$ respectively). Specifically, in 2 cases intraoperative loss of signal (LOS) was recorded after using bipolar electrocoagulation near the nerve. In 4 cases after the nerve's isolation, the signal's decrease was detected after the moment of the isolation of the nerve, however, without complete loss of the signal (V2 amplitude ranged from 0.37 to 1.22 mV). In one of these

cases by the time of the writing of this article (3 months after surgery), the vocal fold palsy still existed. The total rate of persisting RLN palsy in the whole study group is 0.4% of the number of patients and 0.3% of the number of RLNs at risk. Among the two cases with lateral conversion, both resulted in unilateral vocal fold palsy. In one case, the nerve trunk was damaged during dissection, while in the other case, a LOS was registered despite the nerve appearing intact macroscopically.

Postoperative bleeding occurred in 1 case (0.39%), which is comparable with the control group (2 cases, 0.59%). The revision of the neck under the endotracheal anesthesia revealed bleeding from a vein draining the lower PTG. The bleeding was stopped with the application of a titanium clip.

Discussion

Surgical technique and the anatomy of the neck

When performing a traditional operation on the thyroid gland, a surgeon typically follows a set of standard steps. The procedure begins with the transection of the upper pole vessels to mobilize the thyroid lobe and ends with the intersection of the inferior thyroid artery trunk, located most deeply in the wound. At the beginning of the operation, the lateral vein of the thyroid (Kocher's vein) and the veins of the lower pole of the thyroid are ligated, since they are superficially located. After that, the thyroid is displaced out of the wound, to enhance visualization of the anatomical structures, which is a crucial aspect of this type of surgery. The key objective is to access to the RLN and thyroid vessels from the lateral aspect of the thyroid.

Considering the anatomy of the thyroid, the rationale behind the traditional operation cannot be logically justified. Approaching the RLN from the lateral side unavoidably involves the transection of the structures located on this side: Kocher vein, superficial veins of the lower pole of the thyroid, and, in deeper layers—branches or trunk of the inferior thyroid artery, that courses medially from under the main neurovascular bundle of the neck. By accessing the RLN from the lateral side, a surgeon has to occlude the venous outflow from the thyroid first (while preserving arterial inflow from the inferior thyroid artery, responsible for up to 80% of arterial blood supply). This results in venous hypertension in the thyroid tissue, increases the bleeding during the procedure of the thyroid tissue, and adds complexity to the surgeon. Then, in the deeper layers, the surgeon has to make efforts to preserve

the branches of the inferior thyroid artery, supplying the PTGs. Considering that the lateral approach does not allow to visualize the RLN until the final stages, the surgeon dissects both the thyroid veins and the inferior thyroid artery before reaching the nerve's location, thereby posing a significant risk of damaging the smaller arterial branches. It should also be noted that during the lateral approach to the RLN, the surgeon inevitably applies traction to elevate and medialize the thyroid. As a result, a relatively straight line is formed, enabling the surgeon to visualize the RLN. This creates tension within the tissues, and increases the likelihood of RLN injury, as the trunk is stretched with the stretched vessels or fascial fibers. According to the latest data, up to 80% of cases of the loss of function of the RLN are attributed to the damage, caused by traction, rather than direct nerve injury (9).

During the TFT method, the RLN is approached from the medial side and the only anatomical structure located between the surgeon and the nerve trunk is Berry's ligament. There are different opinions, regarding the anatomy of Berry's ligament. One popular opinion suggests that in some patients, the RLN passes between the fibers of the ligament, leading to compression of the nerve trunk during the upward traction of the thyroid gland. One of the recent studies, related to this point of view was conducted by Henry *et al.* (10)], who reported the coursing of the nerve piercing the ligament in 2.8% of cases out of 72 observations. Other studies estimated the rate of the coursing of the RLN through the Berry ligament to be even higher: at 61.8% (11) and 19.5% (12), respectively. Similar anatomical data are provided in the well-known "*Atlas of endocrine surgical techniques*" [edited by Duh *et al.* (13)] On the contrary, Kang *et al.* (7) reported the RLN being dorsolateral to the ligament in all investigated cases (71 patients), and this report is supported by the finding of the present study: 348 RLNs, were visualized and in none of the cases the nerve coursed through Berry's ligament. Instead, the nerve trunk coursed consistently behind the ligament fibers, and no large vessels within the area of Berry's ligament were observed. all the vessels in the vicinity coursed along the posterior edge of the ligament without directly connections to it. As a result, the ligament fibers could be easily dissected with bipolar electrocoagulation in a cutting mode.

The medial approach to the RLN offers several important advantages, making it a more anatomically justified method. These advantages include:

- ❖ Straight access line, that allows direct access to the

RLN without need to extract the thyroid lobe out of the wound.

- ❖ Minimal structures in the surgical path: when approaching the RLN medially, there are only fibers of Berry's ligament along with a few thin vessels between the surgeon and the nerve trunk. All vessels, including veins and arteries, that pass through the thyroid area are situated laterally to the dissection area. Predictable nerve course: the RLN trunk remains straight and uncurved during the medial approach, making it easier for the surgeon to predict its pathway even in areas where the nerve is not directly visible. This notion is supported by the study by Kang *et al.* (7) showing, that the position of RLN in relation to the trachea is very conservative and can be accurately predicted, facilitating safe medial dissection.
- ❖ Lateral traction instead of medial: unlike upward and medial traction, which can compress the nerve against the hard surface of the trachea, lateral traction avoids such compression. The orientation of the vessels of the thyroid gland and the fibers of Berry's ligament also minimizes tension around the RLN trunk during lateral traction. Additionally, the force applied during lateral traction is generally lower compared to upward and medial traction, typically performed by manually holding the thyroid lobe.
- ❖ Preservation of thyroid veins until the later stages of surgery facilitates the outflow of blood from the gland and eliminates hypertension within the thyroid tissue, reducing bleeding during the procedure. In some cases, it is possible to avoid the transection of the main trunks of thyroid veins, separating only their terminal branches.
- ❖ Early transection of the terminal branches of the inferior thyroid artery reduces arterial flow to the thyroid gland and decreases the bleeding of the gland tissue.
- ❖ That the mobilization of PTGs from medial surface of the thyroid to the lateral preserves their blood supply by preservation the trunk of the inferior thyroid artery and the anastomosis between the superior and inferior thyroid arteries, reducing the risk of parathyroid ischemia.
- ❖ Simplified preparation of the vessels in the upper pole of the thyroid is obtained by bringing the upper pole of the lobe closer to the surgeon,

after the thyroid lobe is completely mobilized. Additionally, this downward movement increases the distance between the cricothyroid muscle and the edge of the upper pole, effectively reducing the risk of injury to the superior laryngeal nerve.

Learning curve

During the study, three distinct phases were identified in the learning curve, each characterized by slightly different performance of some elements of the operation.

The first phase (93 operations, 127 nerves at risk) focused on assessing the possibility of medial approach surgery and accumulating experience. During this phase, meticulous execution of all elements of the operation was emphasized, with careful monitoring of the position of the RLN. No cases of RLN injury were observed during this phase. In the series of the first 10 operations, continuous IONM was used, which showed no significant changes in the RLN signal amplitude and latency values during lateral traction of the thyroid lobe. Following this, the use of permanent IONM was discontinued, and only intermittent IONM was used primarily to locate the nerve trunk and monitor RLN function.

During the second phase (31 operations, 40 nerves at risk), attempts to reduce the time by increasing the speed of its elements were made. A less thorough mapping of the RLN position with IONM was performed, which probably, resulted in 4 cases of vocal fold palsies. Two cases of lateral conversion also occurred within this period of time.

Upon analyzing the situation, modifications were made to the surgical methodology to address these complications. At the beginning of the operation, IONM started being used to identify the entry point of the RLN into the larynx, and the position of the nerve near the lower pole of the thyroid lobe. The latter can be found within the triangle-shaped zone between the lateral surface trachea and the medial surface of the lower pole. This zone becomes available once the isthmus is divided and mobilized from the anterior surface of the trachea, the workspace is created by pushing the trachea to the medial with a peanut swab and a thyroid lobe to the lateral with a narrow Farabeuf retractor. By connecting the points, where the nerve is detected, the pathway of the nerve becomes clear, allowing to determine the area where it is safe to use electrocoagulation. Furthermore, the use of bipolar electrocoagulation was decided to be strictly limited in the

area near the RLN, the vessels located near the trunk of the RLN were treated, using titanium clips or ligation instead. Additionally, mobilization of the thyroid lobe from the trachea started being performed along a plane as close as possible to the thyroid tissue, rather than along the trachea itself, to preserve small venous branches along the gland tissue, allowing to maintain a distance of at least 5–7 mm from the RLN trunk, reducing traction on the nerve.

During the third phase (145 operations, 189 nerves at risk), after a change in the methodology was applied, two cases of laryngeal paresis were registered, accounting for 1.4% of the number of patients and 1.1% of the number of RLNs at risk.

Risk of complications—RLN palsy

During the study in none of the 346 cases of nerve preparation using the TFT technique, the macroscopic damage to the nerve trunk was observed. The only case with damage to the nerve trunk occurred when the operation using the TFT technique was deemed impossible, and the surgery was continued with lateral access to the nerve. Considering this, one of the possible conclusions from this experience may be to advise to continue performing operations with the medial approach, even when it seems technically difficult. However, one must take into consideration, that the feasibility of the medial approach for all cases is still unclear. In some cases, normal anatomy can be severely altered by pathological processes, for example, thyroiditis, resulting in fibrosis and growth of tissue around the nerve, or, especially, invasive thyroid cancer, infiltrating thyroid capsule, RLN, or trachea. In this situation, the possibility to visualize the nerve from the medial can be significantly impaired, though successful cases are being reported (6). Nevertheless, under these circumstances, lateral mobilization highly likely poses a much higher risk of functional nerve damage, because of the intensity of the applied traction.

An important question to consider is whether the TFT technique can be performed without the availability of IONM in the clinic. While the authors of this article have personal experience with 6 successful medial access operations performed without IONM, we cannot recommend the use of the technique in clinics that are not equipped with IONM, since its use greatly facilitates the procedure. Performing TFT without IONM may increase the risk of direct damage to the nerve, although this still

remains unclear.

Risk of complications—damage to the EBSLN

During the operations, the function of EBSLN was controlled with IONM. In all cases, no signs of EBSLN damage were observed. However, not enough data are available to guarantee that the TFT technique is universally safe in terms of preserving the function of EBSLN. Unlike the RLN, in which the loss of function is easily detectable, the impairment of the EBSLN function may be subtler and not immediately apparent. This highlights the need for more comprehensive evaluation and follow-up in future studies.

Risk of complications—hypoparathyroidism

It is noteworthy that out of the 696 PTGs at risk, only one was accidentally removed. Small fragments of normal PTG tissue were detected in the histological specimens of 17 patients. Among these patients, a decrease in the level of PTH was observed only in 2 cases. This suggests, that the main cause of postoperative hypoparathyroidism in this study was not the removal of the PTGs, but rather, a disrupted blood supply to the PTGs.

Restoration of PTG function in all cases indicates that the vascular supply to the PTGs was preserved. Notably, in 4 patients, PTG function was restored as early as 1 month after surgery. Nonetheless, one potential approach to further enhance the TFT technique is the utilization of fluorescent vascular imaging with indocyanine green (ICG).

Limitations of the study

This study is limited by several factors needed to be taken into consideration. The study is not randomized, and patients are not assigned to the treatment group or control group randomly. This makes it difficult to eliminate bias and confounding factors. The study also has a small sample size, which limits the applicability of the findings to a larger population. The study is conducted at a single center, which limits the generalizability of the findings to other centers and populations.

Areas for future research

The limitations mentioned above determine the possible areas of future research. The application of the TFT

technique by various surgeons in different institutions with the evaluation of the results may be of particular interest. A randomized study with the evaluation of the results may provide additional data in comparison to a traditional method. Also is important to assess the feasibility of TFT technique in different groups of patients, for example, children.

Conclusions

The technique of thyroid surgery with the medial approach to the RLN and PTGs (medial thyroidectomy, TFT) is feasible in most patients with thyroid diseases requiring surgical treatment. The technique has demonstrated high safety and several advantages over the traditional method of performing operations on the thyroid gland.

Acknowledgments

Funding: None.

Footnote

Reporting Checklist: The authors have completed the TREND reporting checklist. Available at <https://gs.amegroups.com/article/view/10.21037/gS-23-147/rc>

Data Sharing Statement: Available at <https://gs.amegroups.com/article/view/10.21037/gS-23-147/dss>

Peer Review File: Available at <https://gs.amegroups.com/article/view/10.21037/gS-23-147/prf>

Conflicts of Interest: All authors have completed the ICMJE uniform disclosure form (available at <https://gs.amegroups.com/article/view/10.21037/gS-23-147/coif>). The authors have no conflicts of interest to declare.

Ethical Statement: The authors are accountable for all aspects of the work in ensuring that questions related to the accuracy or integrity of any part of the work are appropriately investigated and resolved. The study was conducted in accordance with the ethical principles outlined in the Declaration of Helsinki (as revised in 2013) and all applicable laws and regulations. The study received ethics approval from the Local Ethics Committee of Saint Petersburg State University Hospital, reference number 93-1 of 17.07.2021. Informed consent was taken from all

the patients.

Open Access Statement: This is an Open Access article distributed in accordance with the Creative Commons Attribution-NonCommercial-NoDerivs 4.0 International License (CC BY-NC-ND 4.0), which permits the non-commercial replication and distribution of the article with the strict proviso that no changes or edits are made and the original work is properly cited (including links to both the formal publication through the relevant DOI and the license). See: <https://creativecommons.org/licenses/by-nc-nd/4.0/>.

References

1. Cirocchi R, Arezzo A, D'Andrea V, et al. Intraoperative neuromonitoring versus visual nerve identification for prevention of recurrent laryngeal nerve injury in adults undergoing thyroid surgery. *Cochrane Database Syst Rev* 2019;1:CD012483.
2. Barbieri D, Indelicato P, Vinciguerra A, et al. Autofluorescence and Indocyanine Green in Thyroid Surgery: A Systematic Review and Meta-Analysis. *Laryngoscope* 2021;131:1683-92.
3. Kocher T. *Chirurgische operationslehre*. Jena: Verlag von Gustav Fischer; 1902.
4. Uludağ M, Tanal M, İşgör A. A Review of Methods for the Preservation of Laryngeal Nerves During Thyroidectomy. *Sisli Etfal Hastan Tip Bul* 2018;52:79-91.
5. Ching HH, Kahane JB, Foggia MJ, et al. Medial Approach for the Resection of Goiters with Suprahyoid, Retropharyngeal, or Substernal Extension. *World J Surg* 2018;42:1415-23.
6. Mishra SK, Yadav SK, Bansal N. Medial Approach for Identification of Recurrent Laryngeal Nerve in Locally Advanced Differentiated Thyroid Carcinoma: Revisited. *Indian J Surg Oncol* 2022;13:87-91.
7. Kang KH, Song RY, Suh YJ, et al. Safety of medial dissection of the thyroid gland along the trachea based on anatomic constancy of the laryngeal entry point of the recurrent laryngeal nerve. *Ann Surg Treat Res* 2018;95:16-21.
8. Sleptsov I, Chernikov R, Pushkaruk A, et al. Tension-free thyroidectomy (TFT): initial report. *Updates Surg* 2022;74:1953-60.
9. Chiang FY, Lu IC, Kuo WR, et al. The mechanism of recurrent laryngeal nerve injury during thyroid surgery--the application of intraoperative neuromonitoring. *Surgery* 2008;143:743-9.
10. Henry BM, Sanna B, Graves MJ, et al. The Reliability of the Tracheoesophageal Groove and the Ligament of Berry as Landmarks for Identifying the Recurrent Laryngeal Nerve: A Cadaveric Study and Meta-Analysis. *Biomed Res Int* 2017;2017:4357591.
11. Pradeep PV, Jayashree B, Harshita SS. A Closer Look at Laryngeal Nerves during Thyroid Surgery: A Descriptive Study of 584 Nerves. *Anat Res Int* 2012;2012:490390.
12. Botelho JB, Vieira DM, de Carvalho DM, et al. Anatomy surgical study of relations between the recurrent laryngeal nerves and the ligament of Berry. *Rev Col Bras Cir* 2012;39:364-7.
13. Duh QY, Clark OH, Kebebew E. *Atlas of Endocrine Surgical Techniques*. 1st ed. London: Elsevier; 2009.

Cite this article as: Sleptsov I, Chernikov R, Pushkaruk A, Sablin I, Tilloev T, Timofeeva N, Gerasimova K, Buzanakov D, Shikmagomedov S, Alekseeva S, Knyazeva P, Bubnov A. Tension-free thyroidectomy (medial thyroidectomy)—a prospective study: surgical technique and results of 259 operations. *Gland Surg* 2023;12(9):1242-1250. doi: 10.21037/gS-23-147