



Chest wall depression caused by tissue expander use in breast reconstruction with recoiling following expander removal: a case report

Jong-Ho Kim[^], Se Yeon Lee[^], Chan Yeong Heo

Department of Plastic and Reconstructive Surgery, Seoul National University College of Medicine, Seoul National University Bundang Hospital, Seongnam, Korea

Contributions: (I) Conception and design: JH Kim, CY Heo; (II) Administrative support: JH Kim, CY Heo; (III) Provision of study materials or patients: JH Kim, SY Lee; (IV) Collection and assembly of data: JH Kim, SY Lee; (V) Data analysis and interpretation: JH Kim, SY Lee; (VI) Manuscript writing: All authors; (VII) Final approval of manuscript: All authors.

Correspondence to: Chan Yeong Heo, MD, PhD. Department of Plastic and Reconstructive Surgery, Seoul National University College of Medicine, Seoul National University Bundang Hospital, 82 Gumi-ro 173beon-gil, Bundang-gu, Seongnam 463-707, Korea. Email: lionheo@gmail.com.

Background: While the number of implant-based immediate breast reconstructions has increased, two-stage reconstructions still comprise a significant proportion. Some studies have reported chest wall depression (CWD) following tissue expander insertion; however, there have been no reports on chest wall recoiling following expander removal. Here, we present a case of CWD resulting from tissue expander use for breast reconstruction, with subsequent chest wall recoiling following expander removal.

Case Description: A 40-year-old woman had previously undergone skin-sparing mastectomy and tissue expander insertion at another hospital 7 months previously. She presented to our institute and complained of pain and restricted shoulder movement, desiring the removal of the tissue expander. A preoperative computed tomography (CT) scan showed CWD on the expander-inserted side; the antero-posterior (AP) length of the right chest wall was 127.2 mm and that of the left side was 150.2 mm. During the surgical procedure, a capsulectomy was performed, followed by the reconstruction of the right breast using a free transverse rectus abdominis myocutaneous flap. The patient exhibited symptom improvement immediately after the surgery and a 12-month follow-up CT scan revealed recoiling of the chest wall (right side, 147.4 mm; left side, 153.7 mm).

Conclusions: This case highlights the potential for CWD and recoil following tissue expander use in breast reconstruction. It is essential for surgeons to be aware of this phenomenon and to provide thorough explanations to patients who have undergone expander insertion, particularly those who have received radiation therapy.

Keywords: Breast reconstruction; tissue expander; chest wall depression (CWD); recoiling phenomenon; case report

Submitted Jan 17, 2023. Accepted for publication Jul 20, 2023. Published online Sep 04, 2023.

doi: 10.21037/gs-23-25

View this article at: <https://dx.doi.org/10.21037/gs-23-25>

[^] ORCID: Jong-Ho Kim, 0000-0003-0998-6358; Se Yeon Lee, 0000-0002-3501-4942.

Introduction

Implant-based breast reconstructions are commonly performed, which include two-stage expander-implant and direct-to-implant techniques (1). Recently, trends in mastectomy and reconstruction have shifted toward conserving the skin envelope and nipple areolar complex using the immediate direct-to-implant method, in accordance with data suggesting its oncologic safety (2,3). Despite this recent transition, two-stage reconstructions still comprise a significant proportion of such procedures. A mastectomy including the skin envelope is required for tumors close to the skin, and a two-stage procedure using a tissue expander is needed to obtain a more optimal aesthetic result (4).

Complications such as infection, hematoma, and skin flap necrosis can occur following the insertion of a tissue expander (5). Some studies have reported chest wall depression (CWD) following tissue expander insertion; however, chest wall recoiling following expander removal has not been previously reported (6-8). The chest wall can undergo remodeling or deformation due to continuous mechanical forces exerted by the physical properties of the cartilage (9). Similarly, due to these characteristics of the cartilage, when the causative factor exerting pressure is removed, recoiling can occur. While there have been mentions of the possibility of such phenomenon in the literature, there have been no report documenting this occurrence. Here, we present a case of CWD resulting from using a tissue expander for breast reconstruction and recoiling following expander removal. We present this article in accordance with the CARE reporting

checklist (available at <https://gs.amegroups.com/article/view/10.21037/ggs-23-25/rc>).

Case presentation

A 40-year-old woman had previously undergone skin-sparing mastectomy and tissue expander insertion at another hospital 7 months earlier. Following insertion of the tissue expander, she had undergone radiation therapy to the submuscular plane, and the expander had been fully inflated with 550 cc of saline. She then presented at our hospital for breast reconstruction, requesting removal of the tissue expander, and underwent breast reconstruction with an autologous tissue-based flap. On physical examination, a Baker grade III capsular contracture was observed and she complained of increased discomfort post-mastectomy radiation therapy, which included intermittent pain and restriction of shoulder motion.

A preoperative computed tomography (CT) scan showed CWD on her right side, with the antero-posterior (AP) length of the right chest wall being 127.2 mm and that of the left side being 150.2 mm (*Figure 1*). CWD was intraoperatively identified after tissue expander removal, which predominantly extended from the middle to the lateral sides (*Figure 2*). No pliability was noted in the depressed region, and it is presumed that this phenomenon is attributable to a gradual alteration induced by the pressure of the expander. A capsulectomy was performed and the right breast was reconstructed using a free transverse rectus abdominis myocutaneous flap. No major complications were noted during the postoperative period. The patient demonstrated immediate postoperative improvement in symptoms, including alleviation of intermittent pain and restoration of restricted shoulder motion. A CT scan at 12-month follow-up showed recoiling of the chest wall (right side, 147.4 mm; left side, 153.7 mm; *Figure 3*). A difference was observed in the AP length of the chest wall during inhalation and expiration. When calculated based on the postoperative length of the left side, the recoiled length was approximately 17.2 mm. Postoperative follow-up was uneventful and the shoulder motion restriction and pain-related symptoms improved.

All procedures performed in this study were in accordance with the ethical standards of the institutional and/or national research committee(s) and with the Helsinki Declaration (as revised in 2013). Written informed consent was obtained from the patient for publication of this case report and accompanying images. A copy of the written

Highlight box

Key findings

- There is a potential for chest wall depression (CWD) and recoil following tissue expander use in breast reconstruction

What is known and what is new?

- Some studies have reported CWD following tissue expander insertion
- This is a first report for chest wall recoiling following expander removal.

What is the implication, and what should change now?

- It is essential for surgeons to be aware of this phenomenon and to provide thorough explanations to patients who have undergone expander insertion, particularly those who have received radiation therapy.

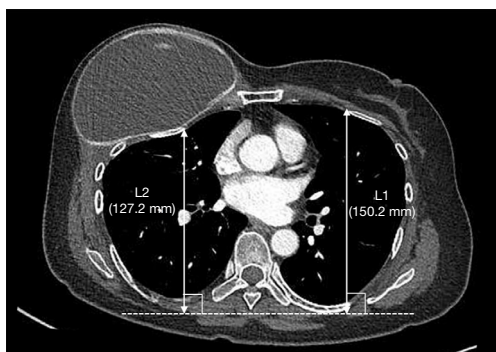


Figure 1 Preoperative CT image. CWD can be identified on the right chest; the antero-posterior length of the right chest wall was 127.2 mm and that of the left side was 150.2 mm. L1: preoperative left chest wall; L2: preoperative right chest wall. CT, computed tomography; CWD, chest wall depression.

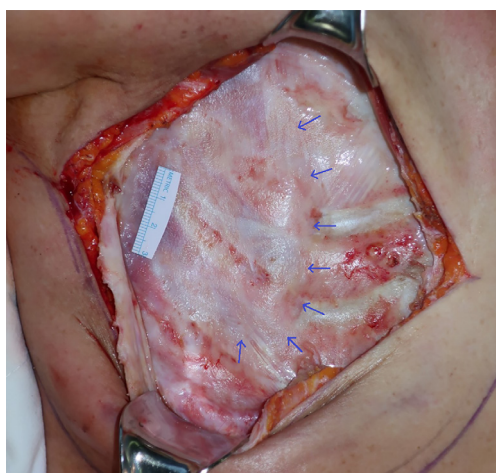


Figure 2 Intraoperative findings. A capsule was observed around the implant and CWD after expander removal. CWD mainly occurred on the cartilaginous portion (blue arrows). CWD, chest wall depression.

consent is available for review by the editorial office of this journal.

Discussion

We reported a case of tissue expander-induced CWD and recoiling following expander removal. Our patient complained of pain and discomfort on the operated side of the chest and a CT scan showed prominent CWD due to the inflated tissue expander. Her symptoms improved with

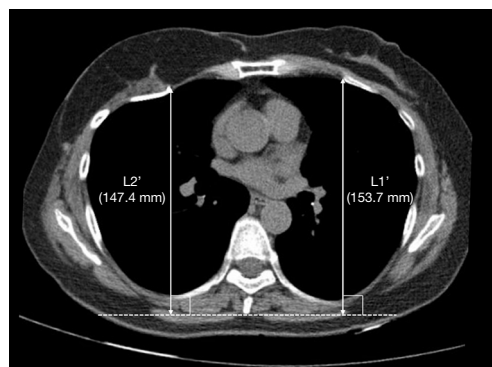


Figure 3 Postoperative CT image. CT scan at the 12-month follow-up showed reconstructed right breast with autologous tissue and recoiling of right chest wall (right side, 147.4 mm; left side, 153.7 mm). Estimated recoiled length was approximately 17.2 mm. Estimated recoiled length = $L2' - L2 \times (L1'/L1) = 147.4 - 127.2 \times (153.7/150.2) = 17.2$ mm. L1': postoperative left chest wall; L2': postoperative right chest wall. CT, computed tomography.

recoiling of the chest wall; the causal relationship between this recoiling and her symptoms was unclear, although intraoperative capsulectomy is known to have a high probability of improving symptoms.

Several studies have elucidated various complications after placement of tissue expanders, including infection, seroma, capsular contracture, and mastectomy flap necrosis (10,11), with complications related to patients' comorbidities, high body mass index, tobacco use, and adjuvant radiotherapy. Adkinson *et al.* reported that the success rate for subsequent implant reconstruction could be lower in patients with expander-related complications (5). These common postoperative complications have previously been discussed; however, few studies have reported on CWD following tissue expander insertion. Sariguney *et al.* reported a flattening of the chest wall underneath the tissue expander and Makiguchi *et al.* reported that capsular contracture may be a risk factor for CWD (6,7). Makiguchi *et al.* stated that the recoiling phenomenon could occur after expander removal; however, to our knowledge, no case reports have been published concerning this phenomenon.

Sariguney *et al.* stated that continued inflation to the point where the skin did not stretch well would be likely to increase pressure on underlying bony or cartilaginous structures (7). The worsening of our patient's symptoms following radiation therapy may have been related to the decreased skin elasticity induced by the radiation effect. Our patient also presented with a Baker grade III capsular

contracture, which may have influenced the CWD.

One recent study reported that CWD occurred after direct-to-implant reconstruction to a lesser degree than when using an expander, and that CWD had mainly occurred on the cartilaginous portion of the chest (12). It is well-recognized that cartilage is deformed through continuous pressure (9). In our patient, who was relatively young, the CWD was more prominent on the cartilaginous portion that had not been replaced with bone. The mechanical characteristics of cartilage would appear to explain this recoiling phenomenon. However, future studies that compare younger and older patients with costal cartilage calcification are needed. Additionally, it should be noted that our patient received radiation therapy, which has been previously identified as a risk factor for CWD (6,12). It was reported that radiation-induced fibrosis of the overlying skin envelope can increase resistance to expansion, potentially resulting in an elevated risk of CWD (12). Therefore, surgeons should be aware of and explain about this phenomenon to patients who have undergone expander insertion followed by radiation therapy.

In Korea, patients undergo implant-based breast reconstructions using smaller sized breast implants compared with those used in western countries, and the implant height typically ranges from 30 to 50 mm at our institute. Minor depression is unlikely to have a significant impact, depending on the degree of depression and the extent of recoiling. However, if the AP length of recoiling is 17.2 mm, as observed in this case, asymmetry can result; therefore, it is necessary to consider the recoiling phenomenon after expander removal. Surgeons might consider inserting lower height implants if there is a prominent CWD after the removal of the expander. In addition, it is important to inform the patient that in cases where significant depression is observed during imaging evaluations, there is a possibility of recoiling following the procedure. However, since the same degree of recoiling cannot be guaranteed and there have been no major studies on the extent of recoiling after expander removal, inserting lower-height implants requires careful consideration. Future studies investigating CWD risk factors and the degree of CWD are needed.

Conclusions

We report a case of CWD and recoiling, which has seldom been considered in previous studies. Many patients undergo breast reconstruction using a tissue expander; however,

no case studies have reported on CWD and recoiling following tissue expander removal. In our case, CWD and recoiling mainly occurred on the cartilaginous portion. The recoiling may possibly be explained due to the mechanical characteristics of cartilage, although further studies are needed to verify this. In conclusion, reconstructive surgeons should be aware of this phenomenon when they identify CWD after expander removal, and consider adjusting the implant height in accordance with the degree of recoiling.

Acknowledgments

Funding: None.

Footnote

Reporting Checklist: The authors have completed the CARE reporting checklist. Available at <https://gs.amegroups.com/article/view/10.21037/gc-23-25/rc>

Peer Review File: Available at <https://gs.amegroups.com/article/view/10.21037/gc-23-25/prf>

Conflicts of Interest: All authors have completed the ICMJE uniform disclosure form (available at <https://gs.amegroups.com/article/view/10.21037/gc-23-25/coif>). The authors have no conflicts of interest to declare.

Ethical Statement: The authors are accountable for all aspects of the work in ensuring that questions related to the accuracy or integrity of any part of the work are appropriately investigated and resolved. All procedures performed in this study were in accordance with the ethical standards of the institutional and/or national research committee(s) and with the Helsinki Declaration (as revised in 2013). Written informed consent was obtained from the patient for publication of this case report and accompanying images. A copy of the written consent is available for review by the editorial office of this journal.

Open Access Statement: This is an Open Access article distributed in accordance with the Creative Commons Attribution-NonCommercial-NoDerivs 4.0 International License (CC BY-NC-ND 4.0), which permits the non-commercial replication and distribution of the article with the strict proviso that no changes or edits are made and the original work is properly cited (including links to both the formal publication through the relevant DOI and the license).

See: <https://creativecommons.org/licenses/by-nc-nd/4.0/>.

References

1. Kim JW, Lee JH, Kim TG, et al. Breast reconstruction statistics in Korea from the Big Data Hub of the Health Insurance Review and Assessment Service. *Arch Plast Surg* 2018;45:441-8.
2. Galimberti V, Vicini E, Corso G, et al. Nipple-sparing and skin-sparing mastectomy: Review of aims, oncological safety and contraindications. *Breast* 2017;34 Suppl 1:S82-4.
3. Mesdag V, Régis C, Tresch E, et al. Nipple sparing mastectomy for breast cancer is associated with high patient satisfaction and safe oncological outcomes. *J Gynecol Obstet Hum Reprod* 2017;46:637-42.
4. Pacella SJ. Evolution in Tissue Expander Design for Breast Reconstruction: Technological Innovation to Optimize Patient Outcomes. *Plast Reconstr Surg* 2018;142:21S-30S.
5. Adkinson JM, Miller NF, Eid SM, et al. Tissue Expander Complications Predict Permanent Implant Complications and Failure of Breast Reconstruction. *Ann Plast Surg* 2015;75:24-8.
6. Makiguchi T, Atomura D, Nakamura H, et al. Quantitative assessment and risk factors for chest wall deformity resulting from tissue expansion for breast reconstruction. *Breast Cancer* 2019;26:446-51.
7. Sariguney Y, Ayhan S, Eryilmaz T. Chest wall deformity after tissue expansion. *Scand J Plast Reconstr Surg Hand Surg* 2008;42:108-9.
8. Sinow JD, Halvorsen RA Jr, Matts JP, et al. Chest-wall deformity after tissue expansion for breast reconstruction. *Plast Reconstr Surg* 1991;88:998-1004.
9. Grodzinsky AJ, Levenston ME, Jin M, et al. Cartilage tissue remodeling in response to mechanical forces. *Annu Rev Biomed Eng* 2000;2:691-713.
10. Berry T, Brooks S, Sydow N, et al. Complication rates of radiation on tissue expander and autologous tissue breast reconstruction. *Ann Surg Oncol* 2010;17 Suppl 3:202-10.
11. Tsoi B, Ziolkowski NI, Thoma A, et al. Safety of tissue expander/implant versus autologous abdominal tissue breast reconstruction in postmastectomy breast cancer patients: a systematic review and meta-analysis. *Plast Reconstr Surg* 2014;133:234-49.
12. Kim JH, Lee S, Najmiddinov B, et al. Risk factors for chest wall depression after implant insertion for breast reconstruction: a retrospective quantitative study. *Gland Surg* 2022;11:1333-40.

Cite this article as: Kim JH, Lee SY, Heo CY. Chest wall depression caused by tissue expander use in breast reconstruction with recoiling following expander removal: a case report. *Gland Surg* 2023;12(9):1313-1317. doi: 10.21037/gs-23-25