



# Comparative analysis between ultrasonic shears versus advanced bipolar device in transoral endoscopic thyroidectomy: a randomized controlled trial

Shin-Young Park<sup>#</sup>, Myung Ho Shin<sup>#</sup>, Young Mi Hwang, Yun Suk Choi, Jin Wook Yi<sup>^</sup>

Department of Surgery, Inha University Hospital & College of Medicine, Incheon, Korea

*Contributions:* (I) Conception and design: JW Yi; (II) Administrative support: YS Choi, JW Yi; (III) Provision of study materials or patients: SY Park, JW Yi; (IV) Collection and assembly of data: MH Shin, YM Hwang; (V) Data analysis and interpretation: SY Park, YS Choi, JW Yi; (VI) Manuscript writing: All authors; (VII) Final approval of manuscript: All authors.

<sup>#</sup>These authors contributed equally to this work.

*Correspondence to:* Jin Wook Yi, MD, PhD. Department of Surgery, Inha University Hospital & College of Medicine, 27 Inhang-ro, Jung-gu, Incheon 22332, Korea. Email: jinwook.yi@inha.ac.kr

**Background:** The transoral endoscopic thyroidectomy vestibular approach (TOETVA) is the most recently developed minimally invasive technique with no skin incision. For tissue dissection and bleeding control, the use of proper energy devices is very important in endoscopic thyroid surgery. To date, there have been no clinical studies reported regarding which energy device is better in TOETVA, ultrasonic shears or advanced bipolar device. The aim of our study is to determine which energy device is more useful for TOETVA.

**Methods:** This study was designed as an open-label, prospective randomized controlled trial in a single university hospital. Patients were randomly assigned to the ultrasonic group or advanced bipolar group before the surgery. From June 2020 to May 2022, 40 patients were enrolled (20 patients were assigned to the ultrasonic group, and 20 patients were assigned to the advanced bipolar group). Primary endpoints were operation time for lobectomy, number of camera cleanings, and blood loss during the lobectomy. Secondary endpoints were pain score, postoperative drainage, and blood chemistry. A single endocrine surgeon had performed all surgeries.

**Results:** There were no significant differences between the two groups in age, sex, body mass index (BMI), tumor location, preoperative cytology, or surgical extent. The time for lobectomy was significantly shorter in the advanced bipolar group (33.8±6.4 vs. 41.9±9.0 minutes,  $P=0.002$ ). The number of camera cleanings was significantly lower in the advanced bipolar group (2.9±1.6 vs. 5.8±2.5 times,  $P<0.001$ ). Estimated blood loss was also significantly less in the advanced bipolar group (11.5±17.3 vs. 81.8±99.5 mL,  $P=0.004$ ). Postoperative hospital stays, drainage, pain score, laboratory findings, and complications were not significantly different between the two groups.

**Conclusions:** According to this study, advanced bipolar device showed better performance, with a shorter operation time, less camera cleaning, and less blood loss. We suggest that advanced bipolar device can be a better choice in TOETVA.

**Trial Registration:** ClinicalTrials.gov identifier: NCT04320901.

**Keywords:** Endoscopic thyroidectomy; oncologic thyroid surgery; remote access thyroidectomy; thyroid cancer; transoral thyroidectomy

<sup>^</sup> ORCID: 0000-0002-9296-8443.

Submitted Jun 01, 2023. Accepted for publication Aug 31, 2023. Published online Sep 18, 2023.

doi: 10.21037/gs-23-227

View this article at: <https://dx.doi.org/10.21037/gs-23-227>

## Introduction

### Background

Thyroid cancer has increased in incidence in the past three decades (1). Recent cancer statistics worldwide have indicated that the global incidence rate of thyroid cancer is 10.1 per 100,000 in women and 3.1 per 100,000 in men. It represents one in every 20 cancers diagnosed among women (2). The primary treatment for thyroid cancer is surgical removal of the thyroid gland with or without lymph node dissection. Conventional open thyroidectomy has been performed since approximately 100 years ago using a transverse skin incision on the anterior neck (3). This incision leaves a permanent noticeable scar on the anterior neck. While other cancers are common in older people, the prevalence of thyroid cancer is most frequent in individuals aged 30–50 years who are socially active, and the incidence is approximately three times higher in women (4). In some cases, hypertrophic scars or keloids appear on the scar. It leads to not only cosmetic problems but also psychological stress in patients, eventually decreasing their quality of life (5). For this reason, various thyroid surgery methods have been developed to avoid leaving a scar in the front of the neck.

After the first report of endoscopic parathyroidectomy by Gagner in 1996 and video-assisted thyroid lobectomy by Hüscher *et al.* in 1997, many remote access endoscopic

thyroid surgeries have been attempted, concurrent with the development of laparoscopic surgery devices during the past decade (6–12). In 2016, Anuwong introduced his successful transoral endoscopic thyroidectomy vestibular approach (TOETVA), which removes the thyroid gland through the oral vestibule without significant complications such as infection and mental nerve injury (13). Subsequently, TOETVA became the most famous endoscopic thyroidectomy method in the world (14–17).

### Rationale and knowledge gap

The thyroid gland has a rich vascular supply, and both arterial and venous flow come from carotid and subclavian arteries and subclavian or internal jugular veins. Therefore, special caution should be taken to prevent bleeding during thyroid surgery. In endoscopic thyroid surgery, the use of energy devices is very important for tissue dissection and bleeding control without manual ligation by tie or clips. Currently, there are two types of energy devices being used widely in thyroid surgery: ultrasound-based device and advanced bipolar device. In conventional open thyroid surgery, many clinical studies have been reported on the effectiveness and safety of two devices. Therefore, there is sufficient clinical evidence that both devices can be safely applied in open thyroid surgery (18,19). However, no clinical study has yet addressed which energy device is more efficient regarding operation time and safer in TOETVA.

### Highlight box

#### Key findings

- Advanced bipolar device showed better performance in thyroidectomy vestibular approach (TOETVA) compared to ultrasonic shears, with a shorter operation time, less camera cleaning, and less blood loss.

#### What is known and what is new?

- In open thyroid surgery, there is sufficient clinical evidence to support the safe use of both ultrasonic shears and advanced bipolar device.
- This study is the first randomized controlled trial on energy device use in TOETVA.

#### What is the implication, and what should change now?

- We suggest that advanced bipolar device can be a better choice in TOETVA. This study provides a good reference for the selection of energy devices in TOETVA.

### Objective

The aim of our study is to determine which energy device is more useful for TOETVA using a randomized controlled trial. We present this article in accordance with the CONSORT reporting checklist (available at <https://gs.amegroups.com/article/view/10.21037/gs-23-227/rc>).

## Methods

### Patients

This study was designed as an open-label, prospective randomized controlled trial at a single university hospital. Patients who were scheduled for TOETVA were enrolled

in this study. The inclusion criteria were as follows: patients aged between 20 and 70 years old, thyroid tumors without local invasion or distant metastasis on preoperative ultrasound, normal function of vocal cord on preoperative laryngoscopy or ultrasound, and no significant abnormalities in the preoperative laboratory tests. The study was conducted in accordance with the Declaration of Helsinki (as revised in 2013). The study was approved by the Institutional Review Board of Inha University Hospital (No. INHAUH 2020-01-033) and informed consent was obtained from all individual participants.

Patients who met the following criteria were excluded: patients who had taken aspirin or antiplatelet drugs within seven days before admission, severe medical comorbidities (uncontrolled diabetes or hypertension, chronic renal failure, coagulation disorder, etc.), history of cardiovascular disease (angina pectoris, heart failure, myocardial infarction, coronary artery disease, stroke, transient ischemic attack, etc.), substance or alcohol abuse history, concurrent esophageal or airway disease, history of neck irradiation or neck surgery, participation in other clinical trials within 30 days, severe drug allergy, and pregnancy or lactation.

This study was registered on ClinicalTrials.gov (NCT04320901).

### ***Surgical procedures***

A single endocrine surgeon had performed all surgeries (Yi JW). The indications for TOETVA and the steps of the thyroidectomy procedure were described elsewhere in the report of a previous study (20). After trocar placement in the oral vestibule, the steps of the endoscopic period were as follows: subcutaneous flap creation by an energy device, mid-line strap muscle division, isthmus division, thyroid mobilization, superior pole dissection, recurrent laryngeal nerve and parathyroid identification, berry ligament dissection and lower pole dissection, with or without central lymph node dissection. A comparative view of important scenes during TOETVA according to ultrasonic shears and advanced bipolar device is shown in *Figure 1*. According to random allocation, a single energy device was used during the surgery, ultrasonic shears or advanced bipolar device. Intraoperative neuromonitoring was used in all surgeries using the NIM-3 device (Medtronic, Minneapolis, MN, USA).

### ***Energy devices***

Two types of energy devices were used in this study. For

the ultrasonic group, Harmonic ACE<sup>®</sup> +7 Laparoscopic Shears 36 cm with Advanced Hemostasis (Ethicon US, LLC, Cincinnati, USA) were used, and for the advanced bipolar group, LigaSure<sup>™</sup> Maryland Jaw Laparoscopic Sealer/Divider 37 cm (Medtronic, Minneapolis, MN, USA) was used.

### ***Outcome evaluation***

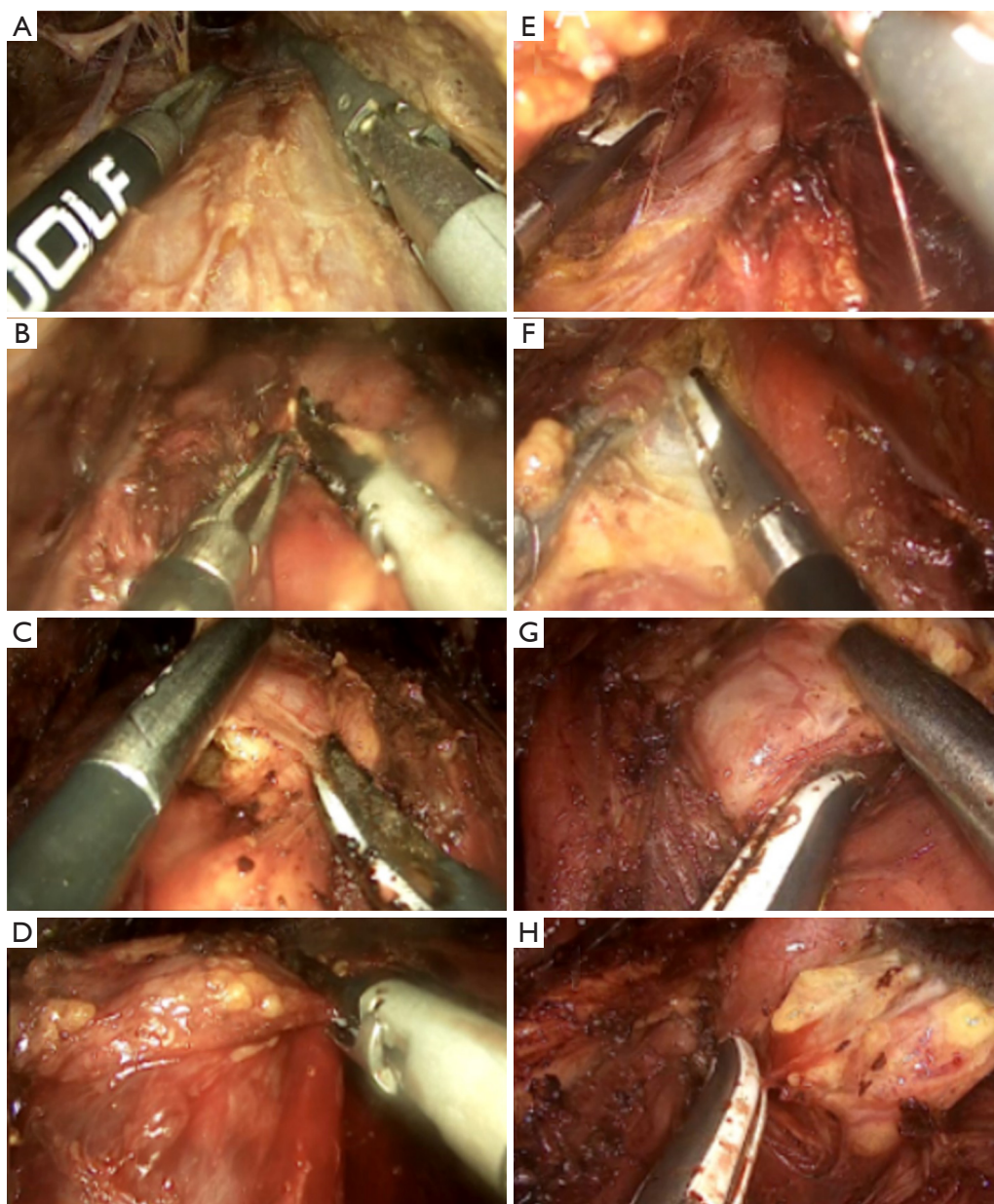
The primary endpoints were operation time for lobectomy, number of camera cleanings, and estimated blood loss during surgery. The operation time for lobectomy was defined as the time from endoscopic camera to completion of thyroid lobectomy. The secondary endpoints were pain score by visual analogue scale (VAS), the amount of postoperative drainage, and laboratory findings including white blood cell (WBC) count and C-reactive protein (CRP) on the first and second postoperative days. The drainage amount (mL/day) was measured from the cumulative Jackson-Pratt (JP) drain amount over 24 hours and checked at 7:00 am on the first and second postoperative days.

For safety assessment, complications such as vocal cord dysfunction and transient hypoparathyroidism after total thyroidectomy were also evaluated. The vocal cord was assessed by laryngoscopy examination or laryngeal ultrasound at the outpatient clinic. Hypoparathyroidism was defined as a serum parathyroid hormone (PTH) level less than 10 pg/mL within 6 months of surgery.

### ***Sample size calculation and randomization***

Due to the lack of a previous study of energy devices in TOETVA, the sample size was calculated based on a previous study in open thyroid surgery. In a randomized study conducted by Sartori *et al.* in 2008 that compared ultrasonic shears and advanced bipolar device in open thyroidectomy, the ultrasonic group showed a significantly shorter operation time (94±24 *vs.* 129±32 minutes,  $P < 0.05$ ) (21). We set the alpha error as 0.05 and the 1 -  $\beta$  error as 0.95. Considering the dropout rate of 10–15%, the number of subjects required for recruitment was set up to 20 in each group (a total of 40 subjects) according to the sample size calculation using G\*Power software version 3.1.9.2 (Bonn, Germany).

Patients were allocated randomly to the ultrasonic group or advanced bipolar group at a 1:1 ratio applying a randomization program encoded with the R-program. Randomization was performed before the surgery day. Blinding was applied only to the patients, who were



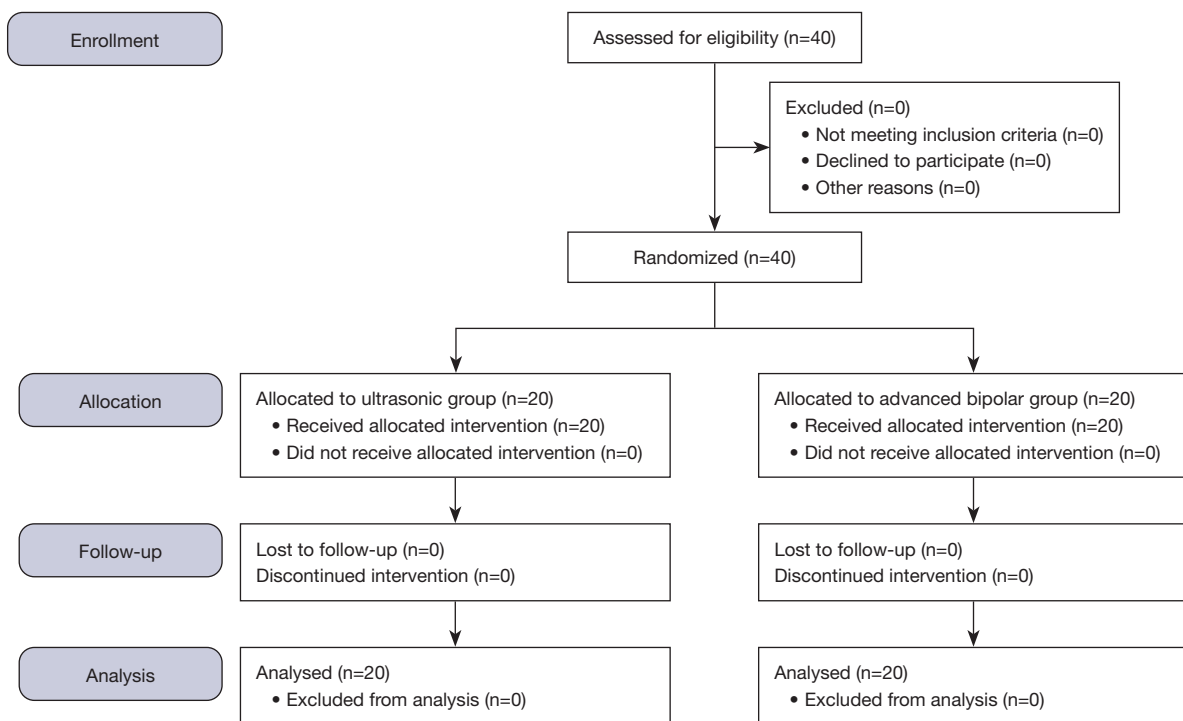
**Figure 1** TOETVA procedures. Images show comparisons of the ultrasonic shears and advanced bipolar devices. Flap creation using (A) ultrasonic shears and (E) advanced bipolar device; isthmectomy using (B) ultrasonic shears and (F) advanced bipolar device; dissection of the superior pole using (C) ultrasonic shears and (G) advanced bipolar device; dissection of the RLN using (D) ultrasonic shears and (H) advanced bipolar device. TOETVA, transoral endoscopic thyroidectomy vestibular approach; RLN, recurrent laryngeal nerve.

unaware of their allocation status until the completion of the three-month follow-up.

#### *Statistical analysis*

Continuous variables were compared using unpaired *t*-tests,

and categorical variables were analyzed by the chi-squared or Fisher's exact test according to sample size. The numeric results were expressed as the mean  $\pm$  standard deviation (SD), and a *P* value under 0.05 was considered indicative of statistical significance. All statistical analyses were carried out using version 4.0.5 of the R programming language (R:



**Figure 2** Flow chart of study enrollment.

A Language and Environment for Statistical Computing; Vienna, Austria. <https://www.R-project.org/>).

## Results

From June 2020 to May 2022, 40 patients were enrolled (20 patients were assigned to the ultrasonic group, and 20 patients were assigned to the advanced bipolar group), as shown in *Figure 2*. No dropout occurred during the study period.

*Table 1* shows the clinical characteristics of the 40 enrolled patients. All patients were female. There were no significant differences between the two groups in age, sex, body mass index (BMI), tumor location, preoperative cytology, or surgical extent. A total of 35 lobectomies and five total thyroidectomies were performed.

The pathological findings are described in *Table 2*. The pathological diagnoses were papillary thyroid carcinoma in 27 patients, nodular hyperplasia in eleven patients, and noninvasive follicular thyroid neoplasm with papillary-like nuclear feature (NIFTP) in two patients. There were no significant differences between the two groups in pathologic diagnosis, tumor size, tumor multiplicity, extrathyroidal extension, lymphatic invasion, vascular invasion, number of

lymph nodes retrieved, number of metastatic lymph nodes, presence of *BRAF*<sup>V600E</sup> mutation, or presence of *TERT* promoter mutation, as described in *Table 2*.

The perioperative variables are described in *Table 3*. The operation time for lobectomy was significantly shorter in the advanced bipolar group (33.8±6.4 vs. 41.9±9.0 minutes,  $P=0.002$ ). The number of camera cleanings was significantly lower in the advanced bipolar group (2.9±1.6 vs. 5.8±2.5 times,  $P<0.001$ ). The estimated blood loss during surgery was significantly less in the advanced bipolar group (11.5±17.3 vs. 81.8±99.5 mL,  $P=0.004$ ). Postoperative hospital stay days, amount of postoperative drainage, and visual analogue pain scale were not significantly different between the two groups. No significant difference was observed in the laboratory findings and postoperative complications.

## Discussion

TOETVA is the most recently developed minimally invasive technique in thyroid surgery that does not require a skin incision. The concept of transoral approach thyroidectomy was initially proposed by Wilhelm *et al.* in 2011 using one sublingual incision and bilateral vestibular incisions of the

**Table 1** Clinical characteristics of enrolled patients (N=40)

Variables	Ultrasonic group (n=20)	Advanced bipolar group (n=20)	P value
Sex			
Male	0	0	
Female	20	20	
Age (years)	41.8±11.87	46.6±9.7	0.169
BMI (kg/cm <sup>2</sup> )	24.96±5.16	24.07±3.63	0.532
Tumor location			0.598
Right	8	11	
Left	10	8	
Bilateral	2	1	
Fine needle aspiration cytology	16	18	0.376
Nondiagnostic or unsatisfactory (Bethesda I)	0	0	
Benign (Bethesda II)	3	2	
Atypia of undetermined significance or follicular lesion of undetermined significance (Bethesda III)	4	1	
Follicular neoplasm or suspicious for follicular neoplasm (Bethesda IV)	2	2	
Suspicious for malignancy (Bethesda V)	2	6	
Malignant (Bethesda VI)	5	7	
Surgical extent			0.253
Right lobectomy	7	11	
Left lobectomy	9	8	
Total thyroidectomy	4	1	

Data are presented as mean ± standard deviation or number. BMI, body mass index.

mouth (22). However, there were many complications, such as mental nerve injury and infection. Endoscopic thyroidectomy using a vestibular approach was proposed by Wang in 2014 and showed better surgical outcomes (23). However, after Anuwong announced a method called TOETVA in 2015, it began to become popular all over the world (13,24,25). According to many studies and systematic reviews, TOETVA is a feasible and safe method for the treatment of patients with benign thyroid nodules and selected differential thyroid carcinomas (14,26-31).

The thyroid gland is one of the highly vascularized organs in the human body (32,33). Arteries and veins are directly connected to the carotid and subclavian arteries and subclavian or internal jugular veins. As such, careful hemostasis during thyroid surgery is very important because postoperative bleeding can cause life-threatening

complications by airway compression (33). In open thyroid surgery, dissection and ligation of thyroid vessels can be easily achieved by hand-ties or surgical clips. However, in endoscopic thyroid surgery, hand tie is impossible, and applying clips is also difficult compared to open surgery. Therefore, proper use of energy devices is not only very important because one cannot perform it without using them to prevent bleeding in endoscopic surgery, especially in thyroidectomy.

Currently, there are two types of energy devices being used in endoscopic surgery: ultrasound-based coagulation and shear devices and advanced bipolar vessel sealing and cutting device. The ultrasonic device uses ultrasonic vibrations to cut and coagulate tissue, with the active blade of the scalpel vibrating at 55,000 Hz (34,35). The high frequency generates heat, denatures protein, and seals

**Table 2** Pathologic findings

Variables	Ultrasonic group (n=20)	Advanced bipolar group (n=20)	P value
Largest tumor size (cm)	1.37±1.36	1.61±1.58	0.61
Multiplicity			0.677
Single	17	16	
Multiple	3	4	
Pathologic diagnosis			0.938
Papillary thyroid carcinoma	13	14	
Nodular hyperplasia	6	5	
NIFTP	1	1	
Gross extrathyroidal extension			0.243
Negative	8	11	
Positive	0	2	
Extrathyroidal extension			0.717
Negative	9	11	
Microscopic	3	5	
Lymphatic invasion			0.549
Negative	10	10	
Positive	3	5	
Vascular invasion			0.75
Negative	11	12	
Positive	2	3	
Retrieved lymph nodes	3.18±2.14	2.82±1.89	0.677
Metastatic lymph nodes	0.55±0.69	0.36±0.67	0.538
<i>BRAF</i> <sup>V600E</sup> mutation			0.745
Negative	3	4	
Positive	10	10	
<i>TERT</i> promoter mutation			
Negative	13	11	
Positive	0	0	

Data are presented as mean ± standard deviation or number. NIFTP, noninvasive follicular thyroid neoplasm with papillary-like nuclear feature.

vessels with minimal lateral thermal spread. The ultrasonic device seals vessels up to 5 mm in diameter (19). Advanced bipolar device applies a precise amount of bipolar electrical energy and pressure to fuse collagen and elastin in blood vessels, sealing it permanently (36). Advanced bipolar device can seal vessels up to 7 mm in diameter (33). The ultrasonic devices have a not insulated active tip, enabling

surgeons to perform delicate and precise tissue dissection. On the other hand, the advanced bipolar devices stand out for their insulated mandible, which ensures a safer surgical experience. Ultrasonic devices are characterized to produce more vapor during tissue ablation, while bipolar devices, in contrast, are associated with the generation of more smoke during tissue coagulation.

**Table 3** Perioperative variables

Variables	Ultrasonic group (n=20)	Advanced bipolar group (n=20)	P value
Operation time for lobectomy (min)	41.9±9.0	33.8±6.4	0.002
Camera cleaning (times)	5.8±2.5	2.9±1.6	<0.001
Postoperative hospital stay (days)	3.1±0.5	3.5±0.8	0.067
Estimated blood loss during surgery (mL)	81.8±99.5	11.5±17.3	0.004
Postoperative drainage (mL)			
Postoperative first day	63.8±28.6	74.1±30.5	0.275
Postoperative second day	42.4±14.8	40.8±17.1	0.753
VAS for pain			
Postoperative first day	2.9±0.5	2.9±0.4	1.000
Postoperative second day	2.4±0.6	2.5±0.5	0.574
WBC (n/mL)			
Postoperative first day	8,737±2,775.6	9,810±2,829.5	0.233
Postoperative second day	5,363±1,699.4	7,086±1,931.6	0.058
CRP (mg/dL)			
Postoperative first day	1.4±1.2	1.4±0.9	0.997
Postoperative second day	2±1.6	1.9±1.6	0.836
Postoperative complications			0.311
Hypoparathyroidism	1	0	
Vocal cord palsy	0	0	
Esophageal injury	0	0	
Tracheal injury	0	0	
Postoperative bleeding	0	0	

Data are presented as mean ± standard deviation or number. VAS, visual analogue scale; WBC, white blood cell; CRP, C-reactive protein.

Previously, some case studies showed a significant reduction in operative times by using ultrasonic or advanced bipolar devices compared to the traditional clamp-and-tie techniques in conventional open thyroid surgeries (37-40). Nemeth *et al.* conducted an analysis of the American College of Surgeons National Surgical Quality Improvement Program data in 2022 and found that in thyroidectomy, vessel sealant devices, such as ultrasonic and advanced bipolar devices, were associated with a lower risk of complications, including hypocalcemia, hematoma, and deep vein thrombosis. The study also suggested that these devices are a more effective method of hemostasis than traditional techniques (41). Several randomized control trials comparing ultrasonic and advanced bipolar devices in open thyroid surgery reported that there was no significant difference

in operation time, length of hospital stay, postoperative wound drainage, or surgical complications (19,42-46). To date, none of the available energy devices have been found to be significantly superior to the others in terms of clinical outcome, and the choice of energy device remains a matter of surgeon's preference in open thyroid surgery (47).

Despite many clinical studies in open thyroid surgery, there are no comparative studies or randomized controlled trials that address energy devices in TOETVA. Currently, this study is the first randomized clinical trial to evaluate which energy device, ultrasonic or advanced bipolar, is better in TOETVA. In our study, there was no difference in terms of patients' demographics, clinical characteristics, and pathologic findings as shown in *Table 1*, indicating that the randomization of patients was good. Our study



showed that the advanced bipolar group had significantly better performance in operation time ( $33.8 \pm 6.4$  vs.  $41.9 \pm 9.0$  minutes,  $P=0.002$ ) and number of camera cleanings ( $2.9 \pm 1.6$  vs.  $5.8 \pm 2.5$  times,  $P<0.001$ ). The shorter operation time in the advanced bipolar group is probably because advanced bipolar device requires less camera cleaning during surgery. Due to the high frequency of the ultrasonic vibrations and the jaw temperature rising above  $200^\circ\text{C}$  in the ultrasonic device, vapor scatters to adjacent areas and makes the camera lens dirty (48). For this reason, the camera easily becomes blurred and requires more cleaning during surgery. However, the advanced bipolar device utilizes electrical energy between the two jaws, with each jaw fully sealed by the insulator, and only creates vapor between the jaws. For this reason, the number of times the camera is wiped is reduced, which is thought to shorten the operation time. Intraoperative bleeding was also less in the advanced bipolar group in our study (estimated blood loss,  $11.5 \pm 17.3$  vs.  $81.8 \pm 99.5$  mL,  $P=0.004$ , respectively). These results showed that the microvascular hemostasis performance is better with advanced bipolar device than with ultrasonic scalpel. It also suggested that the amount of exudate generated from tissue dissection during thyroid surgery was smaller in the advanced bipolar group. In open surgery, both groups may experience minimal blood loss and the difference may not be pronounced due to the possibility of achieving hemostasis through conventional techniques, in addition to the use of energy devices. However, in TOETVA, where achieving hemostasis through conventional techniques is not possible, the difference in blood loss between the two groups may be more pronounced. In TOETVA, meticulous hemostasis is more challenging compared to open surgery, as surgeons are required to perform traction with one hand while using energy devices for dissection with the other hand, potentially leading to increased bleeding. However, postoperative hospital stay days, amount of postoperative drainage, visual analogue pain scale, and surgical complications were not significantly different between the two groups. Thus, although ultrasonic and advanced bipolar devices exhibit differences in operating time and intraoperative blood loss, we showed that both instruments can be safely applied in TOETVA. Taken together, our results suggest that both surgical devices can be safely applied in TOETVA, but advanced bipolar device was the better device, as it exhibited a faster operation time and less blood loss than ultrasonic scalpel.

Our study is the first randomized controlled trial on energy device use in TOETVA. In our study, all surgeries were performed by a single experienced endocrine

surgeon with near 3,000 cases of experience in thyroid surgery. Among these cases, approximately 1,000 were performed using the robotic bilateral axillo-breast approach (BABA) technique, and around 350 cases were conducted using TOETVA. Notably, the surgeon reported having 150 cases of TOETVA experience in 2020 and 500 cases of robotic BABA thyroid surgery experience in 2021 (31,49). It is worth mentioning that this surgeon typically employs both energy devices almost equally and has previously published a retrospective study comparing the two energy devices in robot BABA thyroid surgery in 2020 (50). So, the effect of the surgeon's proficiency, surgeon's preference, or familiarity could be ignored in comparisons, and we could focus on the surgical performance by the instruments. Therefore, we believe that our results can be used as a good reference for many surgeons to select energy equipment when performing TOETVA. The limitations of our study are as follows. In studies on the use of specific devices in surgery, achieving double blinding is impossible. Therefore, since the operator knows which surgical instrument to use, the bias may act accordingly. In addition, since the study was limited to a single institution by an experienced surgeon, results from other institutions and novice surgeons are needed to make our results more generalizable. Although the results were well obtained with a relatively small sample size, there is a need to enroll a larger number of patients through multicenter studies. By expanding the research to include a larger number of cases and multiple surgeons in future studies, we can better mitigate potential biases and ensure broader applicability of the study results. The inherent selection bias of TOETVA candidacy, influenced by surgeon experience and comfort, is also a limitation of this study. In future research, we will also include a discussion on the costs and learning curve of TOETVA.

## Conclusions

Advanced bipolar device showed better surgical performance in TOETVA in terms of shorter operation time, less camera cleaning, and less blood loss. However, neither device showed any difference in postoperative complications or patient prognosis. We suggest that the results of our research will serve as a good reference for energy equipment selection in TOETVA.

## Acknowledgments

*Funding:* This work was supported by a research grant from

Inha University Hospital.

## Footnote

*Reporting Checklist:* The authors have completed the CONSORT reporting checklist. Available at <https://gs.amegroups.com/article/view/10.21037/gS-23-227/rc>

*Trial Protocol:* Available at <https://gs.amegroups.com/article/view/10.21037/gS-23-227/tp>

*Data Sharing Statement:* Available at <https://gs.amegroups.com/article/view/10.21037/gS-23-227/dss>

*Peer Review File:* Available at <https://gs.amegroups.com/article/view/10.21037/gS-23-227/prf>

*Conflicts of Interest:* All authors have completed the ICMJE uniform disclosure form (available at <https://gs.amegroups.com/article/view/10.21037/gS-23-227/coif>). The authors have no conflicts of interest to declare.

*Ethical Statement:* The authors are accountable for all aspects of the work in ensuring that questions related to the accuracy or integrity of any part of the work are appropriately investigated and resolved. The study was conducted in accordance with the Declaration of Helsinki (as revised in 2013). The study was approved by the Institutional Review Board of Inha University Hospital (No. INHAUH 2020-01-033) and informed consent was obtained from all individual participants.

*Open Access Statement:* This is an Open Access article distributed in accordance with the Creative Commons Attribution-NonCommercial-NoDerivs 4.0 International License (CC BY-NC-ND 4.0), which permits the non-commercial replication and distribution of the article with the strict proviso that no changes or edits are made and the original work is properly cited (including links to both the formal publication through the relevant DOI and the license). See: <https://creativecommons.org/licenses/by-nc-nd/4.0/>.

## References

- Seib CD, Sosa JA. Evolving Understanding of the Epidemiology of Thyroid Cancer. *Endocrinol Metab Clin North Am* 2019;48:23-35.
- Sung H, Ferlay J, Siegel RL, et al. Global Cancer Statistics 2020: GLOBOCAN Estimates of Incidence and Mortality Worldwide for 36 Cancers in 185 Countries. *CA Cancer J Clin* 2021;71:209-49.
- Hannan SA. The magnificent seven: a history of modern thyroid surgery. *Int J Surg* 2006;4:187-91.
- Health Insurance Review & Assessment Service. 2023. Available online: <https://opendata.hira.or.kr/home.do>
- Brown BC, McKenna SP, Siddhi K, et al. The hidden cost of skin scars: quality of life after skin scarring. *J Plast Reconstr Aesthet Surg* 2008;61:1049-58.
- Gagner M. Endoscopic subtotal parathyroidectomy in patients with primary hyperparathyroidism. *Br J Surg* 1996;83:875.
- Hüscher CS, Chiodini S, Napolitano C, et al. Endoscopic right thyroid lobectomy. *Surg Endosc* 1997;11:877.
- Miccoli P, Bellantone R, Mourad M, et al. Minimally invasive video-assisted thyroidectomy: multiinstitutional experience. *World J Surg* 2002;26:972-5.
- Ikeda Y, Takami H, Niimi M, et al. Endoscopic thyroidectomy and parathyroidectomy by the axillary approach. A preliminary report. *Surg Endosc* 2002;16:92-5.
- Sasaki A, Nakajima J, Ikeda K, et al. Endoscopic thyroidectomy by the breast approach: a single institution's 9-year experience. *World J Surg* 2008;32:381-5.
- Kang SW, Jeong JJ, Yun JS, et al. Robot-assisted endoscopic surgery for thyroid cancer: experience with the first 100 patients. *Surg Endosc* 2009;23:2399-406.
- Choi JY, Lee KE, Chung KW, et al. Endoscopic thyroidectomy via bilateral axillo-breast approach (BABA): review of 512 cases in a single institute. *Surg Endosc* 2012;26:948-55.
- Anuwong A. Transoral Endoscopic Thyroidectomy Vestibular Approach: A Series of the First 60 Human Cases. *World J Surg* 2016;40:491-7.
- Wang Y, Zhou S, Liu X, et al. Transoral endoscopic thyroidectomy vestibular approach vs conventional open thyroidectomy: Meta-analysis. *Head Neck* 2021;43:345-53.
- Rossi L, Materazzi G, Bakkar S, et al. Recent Trends in Surgical Approach to Thyroid Cancer. *Front Endocrinol (Lausanne)* 2021;12:699805.
- Cohen O, Tufano RP, Anuwong A, et al. Transoral endoscopic vestibular approach for thyroidectomy and parathyroidectomy - From promise to practice. *Am J Otolaryngol* 2021;42:103022.
- Pace-Asciak P, Russell JO, Tufano RP. Surgical treatment of thyroid cancer: Established and novel approaches. *Best Pract Res Clin Endocrinol Metab* 2023;37:101664.
- Rahbari R, Mathur A, Kitano M, et al. Prospective

- randomized trial of ligasure versus harmonic hemostasis technique in thyroidectomy. *Ann Surg Oncol* 2011;18:1023-7.
19. Lee SH, Nguyen TK, Ong WS, et al. Comparing the Utility and Surgical Outcomes of Harmonic Focus Ultrasonic Scalpel with Ligasure Small Jaw Bipolar Device in Thyroidectomies: A Prospective Randomized Controlled Trial. *Ann Surg Oncol* 2019;26:4414-22.
  20. Yi JW, Yoon SG, Kim HS, et al. Transoral endoscopic surgery for papillary thyroid carcinoma: initial experiences of a single surgeon in South Korea. *Ann Surg Treat Res* 2018;95:73-9.
  21. Sartori PV, De Fina S, Colombo G, et al. Ligasure versus Ultracision in thyroid surgery: a prospective randomized study. *Langenbecks Arch Surg* 2008;393:655-8.
  22. Wilhelm T, Metzger A. Endoscopic minimally invasive thyroidectomy (eMIT): a prospective proof-of-concept study in humans. *World J Surg* 2011;35:543-51.
  23. Wang C, Zhai H, Liu W, et al. Thyroidectomy: a novel endoscopic oral vestibular approach. *Surgery* 2014;155:33-8.
  24. Anuwong A, Ketwong K, Jitpratoom P, et al. Safety and Outcomes of the Transoral Endoscopic Thyroidectomy Vestibular Approach. *JAMA Surg* 2018;153:21-7.
  25. Lee SH, Moorthy R, Nagala S. Evolution of transoral endoscopic thyroidectomy vestibular approach according to the IDEAL framework. *Br J Surg* 2022;109:497-502.
  26. Shan L, Liu J. A Systemic Review of Transoral Thyroidectomy. *Surg Laparosc Endosc Percutan Tech* 2018;28:135-8.
  27. Camenzuli C, Schembri Wismayer P, Calleja Agius J. Transoral Endoscopic Thyroidectomy: A Systematic Review of the Practice So Far. *JLS* 2018;22:e2018.00026.
  28. Tartaglia F, Maturo A, Di Matteo FM, et al. Transoral video assisted thyroidectomy: a systematic review. *G Chir* 2018;39:276-83.
  29. Chen S, Zhao M, Qiu J. Transoral vestibule approach for thyroid disease: a systematic review. *Eur Arch Otorhinolaryngol* 2019;276:297-304.
  30. Fernandez-Ranvier G, Meknat A, Guevara DE, et al. Transoral Endoscopic Thyroidectomy Vestibular Approach. *JLS* 2019;23:e2019.00036.
  31. Ahn JH, Yi JW. Transoral endoscopic thyroidectomy for thyroid carcinoma: outcomes and surgical completeness in 150 single-surgeon cases. *Surg Endosc* 2020;34:861-7.
  32. Mohebbati A, Shaha AR. Anatomy of thyroid and parathyroid glands and neurovascular relations. *Clin Anat* 2012;25:19-31.
  33. Smith RB, Coughlin A. Thyroidectomy Hemostasis. *Otolaryngol Clin North Am* 2016;49:727-48.
  34. Voutilainen PE, Haapiainen RK, Haglund CH. Ultrasonically activated shears in thyroid surgery. *Am J Surg* 1998;175:491-3.
  35. Karvounaris DC, Antonopoulos V, Psarras K, et al. Efficacy and safety of ultrasonically activated shears in thyroid surgery. *Head Neck* 2006;28:1028-31.
  36. Lachanas VA, Prokopakis EP, Mpenakis AA, et al. The use of Ligasure Vessel Sealing System in thyroid surgery. *Otolaryngol Head Neck Surg* 2005;132:487-9.
  37. Materazzi G, Ambrosini CE, Fregoli L, et al. Prevention and management of bleeding in thyroid surgery. *Gland Surg* 2017;6:510-5.
  38. Calò PG, Pisano G, Medas F, et al. The use of the harmonic scalpel in thyroid surgery. Our experience. *Ann Ital Chir* 2012;83:7-12.
  39. Ramouz A, Rasihashemi SZ, Safaeiyan A, et al. Comparing postoperative complication of LigaSure Small Jaw instrument with clamp and tie method in thyroidectomy patients: a randomized controlled trial [IRCT2014010516077N1]. *World J Surg Oncol* 2018;16:154.
  40. Revelli L, Damiani G, Bianchi CB, et al. Complications in thyroid surgery. Harmonic Scalpel, Harmonic Focus versus Conventional Hemostasis: A meta-analysis. *Int J Surg* 2016;28 Suppl 1:S22-32.
  41. Nemeth ZH, Kong K, Hwang R, et al. Vessel Sealant Devices in Thyroidectomies: An ACS-NSQIP Study. *South Med J* 2022;115:304-9.
  42. Pons Y, Gauthier J, Ukkola-Pons E, et al. Comparison of LigaSure vessel sealing system, harmonic scalpel, and conventional hemostasis in total thyroidectomy. *Otolaryngol Head Neck Surg* 2009;141:496-501.
  43. Kwak HY, Chae BJ, Park YG, et al. Comparison of surgical outcomes between papillary thyroid cancer patients treated with the Harmonic ACE scalpel and LigaSure Precise instrument during conventional thyroidectomy: a single-blind prospective randomized controlled trial. *J Surg Res* 2014;187:484-9.
  44. Ruggiero R, Gubitosi A, Conzo G, et al. Sutureless thyroidectomy. *Int J Surg* 2014;12 Suppl 1:S189-93.
  45. Hwang SO, Jung JH, Park HY, et al. A Prospective, Randomized Study between the Small Jaw® and the Harmonic Focus® in Open Thyroidectomy. *Otolaryngol Head Neck Surg* 2014;150:943-8.
  46. Hammad AY, Deniwar A, Al-Qurayshi Z, et al. A Prospective Study Comparing the Efficacy and Surgical

- Outcomes of Harmonic Focus Scalpel Versus LigaSure Small Jaw in Thyroid and Parathyroid Surgery. *Surg Innov* 2016;23:486-9.
47. Bakkar S, Papavramidis TS, Aljarrah Q, et al. Energy-based devices in thyroid surgery-an overview. *Gland Surg* 2020;9:S14-7.
48. Kim FJ, Chammas MF Jr, Gewehr E, et al. Temperature safety profile of laparoscopic devices: Harmonic ACE (ACE), Ligasure V (LV), and plasma trisector (PT). *Surg Endosc* 2008;22:1464-9.
49. Choi YS, Shin WY, Yi JW. Single Surgeon Experience with 500 Cases of the Robotic Bilateral Axillary Breast Approach (BABA) for Thyroid Surgery Using the Da Vinci Xi System. *J Clin Med* 2021;10:4048.
50. Ryu HB, Ahn J, Kim JH, et al. Harmonic versus LigaSure for Flap Creation in Bilateral Axillary Breast Approach Thyroid Surgery. *J Endocr Surg* 2020;20:69-77.

**Cite this article as:** Park SY, Shin MH, Hwang YM, Choi YS, Yi JW. Comparative analysis between ultrasonic shears versus advanced bipolar device in transoral endoscopic thyroidectomy: a randomized controlled trial. *Gland Surg* 2023;12(9):1191-1202. doi: 10.21037/gs-23-227