



Lenvatinib and selpercatinib successfully treated RET fusion gene-positive papillary thyroid carcinoma cardiac metastases: a case report

Soji Toda^{1^}, Yayoi Yamamoto², Yoichiro Ookubo³, Hiroyuki Hayashi⁴, Takashi Tsunematsu⁵, Mei Kadoya⁶, Katsuhiko Masudo¹, Hiroyuki Iwasaki¹

¹Department of Endocrine Surgery, Kanagawa Cancer Center, Yokohama, Japan; ²Department of Diagnostic and Interventional Radiology, Kanagawa Cancer Center, Yokohama, Japan; ³Department of Pathology, Kanagawa Cancer Center, Yokohama, Japan; ⁴Department of Pathology, Yokohama Municipal Citizen's Hospital, Yokohama, Japan; ⁵Department of Cardiology, Kanagawa Cancer Center, Yokohama, Japan; ⁶Department of Breast and Thyroid Surgery, Yokohama City University Medical Center, Yokohama, Japan

Contributions: (I) Conception and design: S Toda; (II) Administrative support: K Masudo, H Iwasaki; (III) Provision of study materials or patients: S Toda, Y Yamamoto, T Tsunematsu; (IV) Collection and assembly of data: Y Ookubo, H Hayashi; (V) Data analysis and interpretation: M Kadoya; (VI) Manuscript writing: All authors; (VII) Final approval of manuscript: All authors.

Correspondence to: Soji Toda, MD. Department of Endocrine Surgery, Kanagawa Cancer Center, 2-3-2 Nakao, Asahi-ku, Yokohama 241-8515, Japan. Email: toda.soji.im@yokohama-cu.ac.jp

Background: Cardiac metastasis from thyroid cancer is rare and has an extremely poor prognosis. Although some patients who undergo heart surgery survive, the therapeutic effectiveness of systemic therapy is limited.

Case Description: A 53-year-old woman with a history of papillary thyroid carcinoma (PTC) presented with cough and right chest discomfort. She underwent total thyroidectomy, followed by three rounds of radioactive iodine therapy, to treat pulmonary metastasis. Metastases to the lung, chest wall, liver, heart, and lymph nodes were observed on computed tomography. Core needle biopsy of the tumor in the right chest wall revealed the recurrence of PTC. Cardiac metastasis was discovered by echocardiography and cardiac magnetic resonance imaging, and blood test indicated a thyroglobulin level of 851 ng/mL. Based on the presence of cardiac metastasis and strong clinical symptoms, the condition was assumed to be fatal, and lenvatinib was started right away. Three weeks after starting lenvatinib, every metastatic lesion shrank. Once the *ERC1-RET* fusion gene was identified, we switched to selpercatinib therapy. Ten weeks after starting selpercatinib, every tumor shrank and blood thyroglobulin dropped to 68.1 ng/mL. Initial symptoms such as cough and right chest pain improved. Lenvatinib- and selpercatinib-related adverse effects can be managed with supportive care.

Conclusions: To the best of our knowledge, this is the first case of successful systemic therapy for cardiac metastasis from PTC. Conventionally, cardiac surgery is the main treatment for cardiac metastasis, but now systemic therapy is also an important alternative.

Keywords: Cardiac metastasis; papillary thyroid carcinoma (PTC); *RET*; selpercatinib; case report

Submitted Jun 14, 2023. Accepted for publication Sep 22, 2023. Published online Oct 26, 2023.

doi: 10.21037/gs-23-252

View this article at: <https://dx.doi.org/10.21037/gs-23-252>

[^] ORCID: 0000-0002-2977-4419.

Introduction

The most common type of thyroid cancer, papillary thyroid carcinoma (PTC), has a good prognosis. Patients under the age of 55 years have a <5% risk of thyroid cancer-related death at 10 years after diagnosis even if they have distant metastases (1). Surgery and radioactive iodine (RAI) therapy have been the mainstays of treatment for many years, and they can manage many cases of PTC. However, in recent years, molecular-targeted drugs have been developed, and treatment strategies are changing. Multiple kinase inhibitors such as sorafenib and lenvatinib have demonstrated prolongation of progression-free survival in RAI-refractory progressive differentiated thyroid carcinoma, thereby becoming the first-line therapy (2,3). Furthermore, comprehensive cancer genomic profiling tests have confirmed that many actionable genetic alterations, such as *BRAF*, *RET*, and *NTRK*, also occur in advanced thyroid cancer (4). Certain *RET* inhibitors, including selpercatinib and pralsetinib, have high efficacy, especially for thyroid tumors with *RET* alterations (5,6). Advanced thyroid tumors are increasingly being treated with these drug therapies based on the driver genes. However, cardiac metastasis from thyroid cancer is rare and has an extremely poor prognosis. A systematic review found that median survival from detection of cardiac metastases was 12.5 weeks, and all patients with at least short-term survival underwent cardiac surgery (7,8). Heart surgery was once the sole option for treating thyroid cancer cardiac metastasis; however, this option is not always available. To the best of our knowledge, there are no reports of PTC-related systemic therapy for cardiac metastasis. Therefore, we describe a case of effective

systemic therapy for multiple cardiac metastases. We present this case in accordance with the CARE reporting checklist (available at <https://gs.amegroups.com/article/view/10.21037/ggs-23-252/rc>).

Case presentation

A 53-year-old woman presented with cough, right chest pain, and difficulty lifting her right shoulder. She had a history of PTC with pulmonary metastasis when she was 15 years old. She underwent total thyroidectomy followed by three rounds of RAI therapy. Thereafter, a family doctor had prescribed her levothyroxine for >20 years without imaging tests. She did not have a family history of cancer and her only medical history was thyroid cancer and uterine fibroids. She was taking 125 µg/day of levothyroxine and 1 µg/day of alfacalcidol.

Metastases to the lung, chest wall, liver, heart, and lymph nodes in the neck, mediastinum, and right axilla were discovered on computed tomography (CT) (*Figure 1*, *Table 1*). PTC recurrence was discovered during core needle biopsy of the tumor in the right chest wall, wherein cells with intranuclear inclusions grew in a papillary manner. Necrotic foci were found in some regions. Thyroid transcription factor-1, paired box 8, and thyroglobulin were positive and p53 was partially positive on immunohistochemical staining (*Figure 2*). Electrocardiogram indicated total right bundle branch block; the left ventricular septum and right ventricular apex had mass lesions according to echocardiography (*Figure 3A,3B*). The use of cardiac magnetic resonance imaging (CMR) revealed masses at the ventricular septum and the apex (*Figure 3C,3D*). Thyroid stimulating hormone (TSH) and thyroglobulin levels in blood were 0.053 µIU/mL (normal range, 0.61–4.23 µIU/mL) and 851 ng/mL (normal range, 0–35.1 ng/mL) respectively, whereas antithyroglobulin antibody levels were below the detection threshold. Derived from the presence of multiple masses and hyperthyroglobulinemia, we diagnosed any mass lesions are thyroid carcinoma metastases.

Based on the presence of cardiac metastasis and strong clinical symptoms, the patient's condition was assumed to be fatal, and lenvatinib (24 mg per day) was started immediately. Three weeks after starting lenvatinib, CT scan showed that most of the metastatic lesions were decreasing in size. Moreover, the Oncomine Dx Target Test system, a gene panel test using a next-generation sequencer, detected the *ERC1-RET* fusion gene from the biopsy specimen. Fatal adverse-events due to major hemorrhage have been reported

Highlight box

Key findings

- This is the first case of cardiac metastasis of papillary thyroid carcinoma treated successfully with systemic therapy.

What is known and what is new?

- Cardiac metastasis of thyroid cancer has an extremely poor prognosis, and only patients who undergo cardiac surgery can survive for a long time.
- Papillary thyroid carcinoma with cardiac metastasis can be shrunk and controlled by systemic therapy such as lenvatinib or selpercatinib.

What is the implication, and what should change now?

- Systemic therapy has emerged as a significant alternative in patients with difficult to resect cardiac metastases.

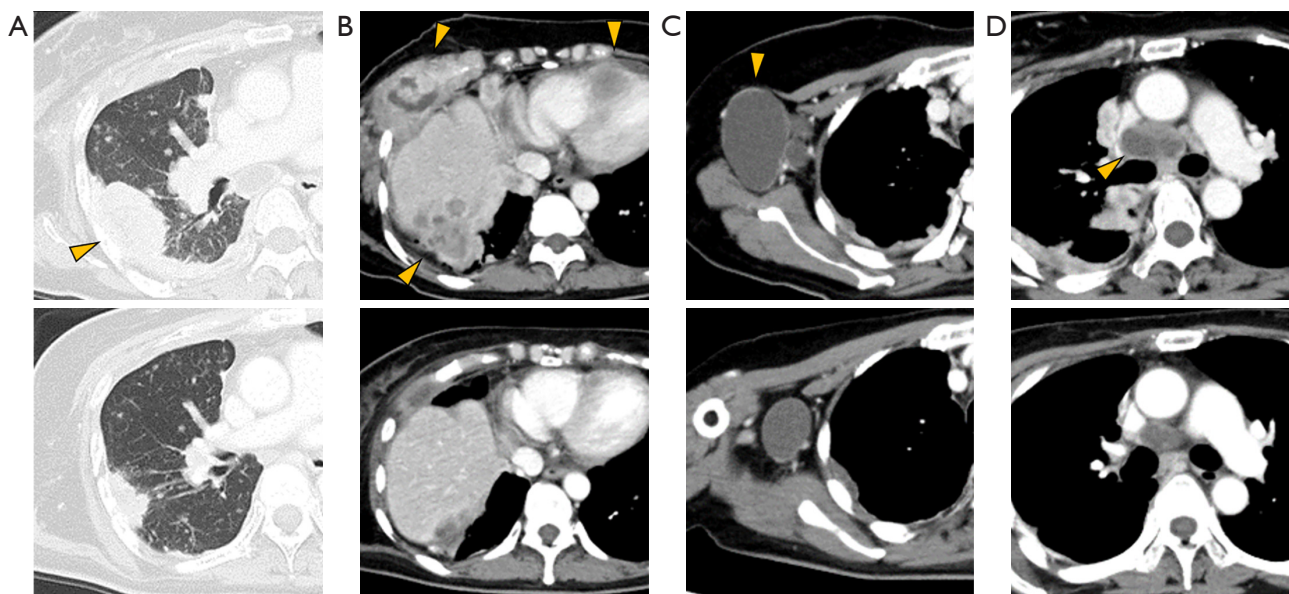


Figure 1 Results of computed tomography (upper row) before treatment with drugs and (lower row) 13 weeks after lenvatinib and selpercatinib treatment began. Arrows indicate metastatic lesions of the lung (A), chest wall, liver, and heart (B), and as well as the lymph nodes in the right axilla (C) and the mediastinum (D).

Table 1 Longest diameter of each metastatic site and blood thyroglobulin level

Item	Timing of examination (after the initiation of treatment)				
	First visit	3 weeks	8 weeks	13 weeks	20 weeks
Longest diameter of metastatic site (mm)					
Right axilla lymph node	39.3	29.3	28.9	26.6	25.1
Mediastinum lymph node	20.8	17.3	14.2	14.3	12.4
Lung	50.2	40.9	39.2	36.6	35.5
Chest wall	86.3	70.7	64.4	58.3	53.0
Liver	52.8	46.1	45.3	40.9	34.6
Heart	48.5	39.3	35.7	35.1	35.1
Blood test					
TSH ($\mu\text{U/mL}$)	0.053	ND	3.959	2.322	0.104
Tg (ng/mL)	851	ND	194	68.1	63.9

Lymph nodes are measured in short axis. TSH, thyroid stimulating hormone; ND, no data.

in lenvatinib. Therefore, we changed our treatment from lenvatinib to selpercatinib. Initially, selpercatinib (160 mg) was administered twice daily. Seven days after the initiation of selpercatinib, the electrocardiogram QT interval corrected with the Bazett formula was prolonged to 502 msec. Subsequently, selpercatinib was reduced to

120 mg twice daily after one week of withdrawal. Ten weeks after the selpercatinib treatment began, CT scan showed that the tumors had shrunk further (*Figure 1*), and blood thyroglobulin level decreased to 68.1 ng/mL. Initial symptoms, such as cough and right chest pain, improved. Hypertension (grade 3, Common Terminology Criteria for

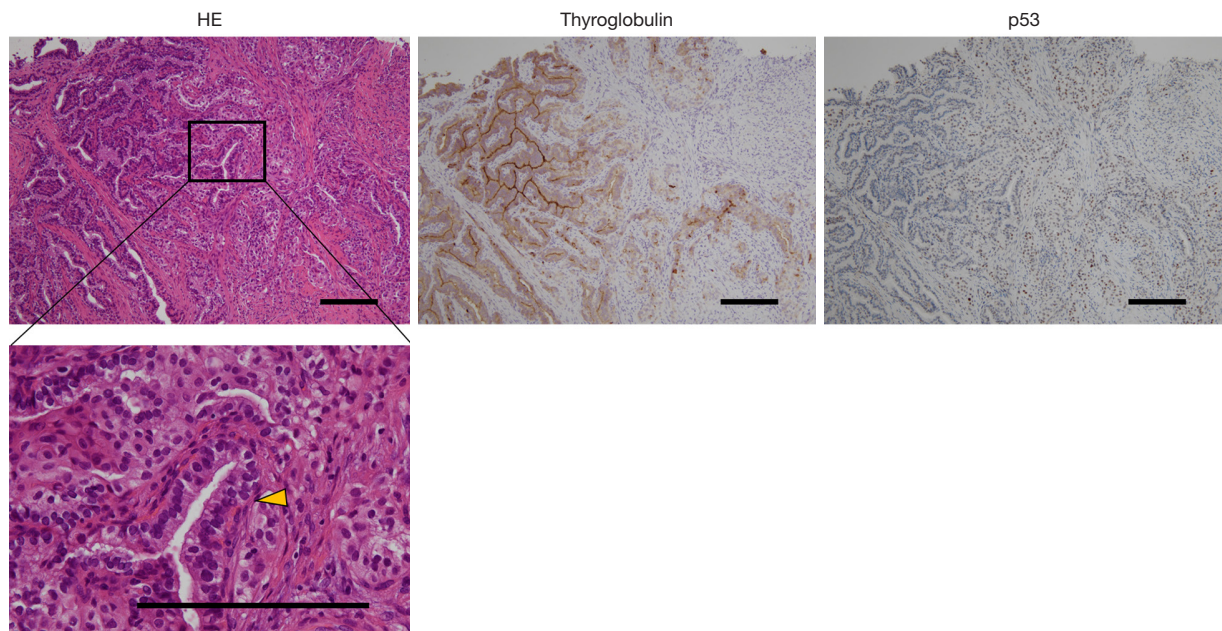


Figure 2 Pathological biopsy findings. In HE staining, cells with intranuclear inclusions (arrow) proliferated in a papillary manner. In immunohistochemical staining, thyroglobulin and p53 were partially positive. The scale bar represents 200 μ m. HE, hematoxylin and eosin.

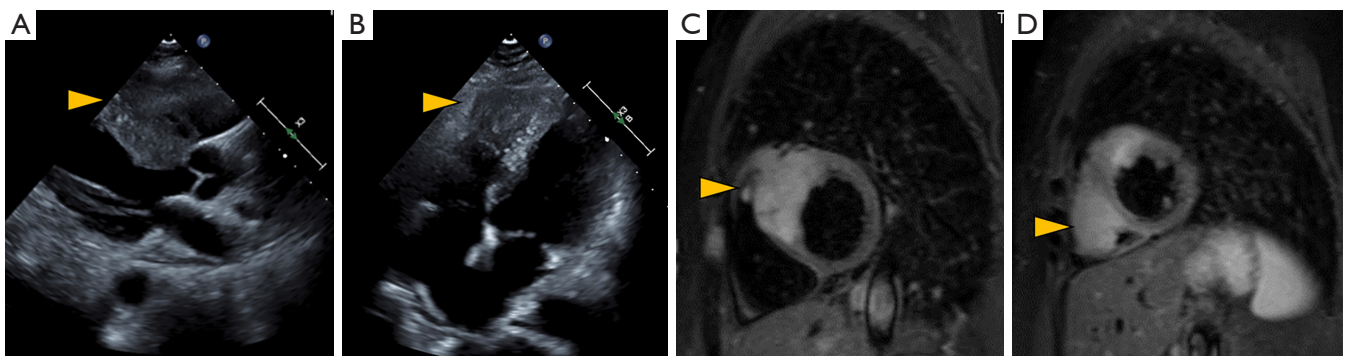


Figure 3 Cardiac metastasis imaging. (A,B) Echocardiography. (C,D) T2-weighted magnetic resonance imaging of cardiac metastasis. Arrows indicate metastatic lesions in the left ventricular septum (A,C) and right ventricular apex (B,D).

Adverse Events version 5.0), proteinuria (grade 3), platelet count decreased (grade 2), and cheilitis (grade 1) were observed after initiation of lenvatinib. Adverse events other than hypertension were resolved with the discontinuation of lenvatinib. Although dry mouth (grade 1) and dysgeusia (grade 2) occurred after starting selpercatinib, these adverse events were manageable with supportive therapy. 30 weeks after the initiation of systemic therapy, she is alive and without major obstacles to daily life.

All procedures performed in this study were in accordance with the ethical standards of the institutional

and/or national research committee(s) and with the Helsinki Declaration (as revised in 2013). Written informed consent was obtained from the patient for publication of this case report and accompanying images. A copy of the written consent is available for review by the editorial office of this journal.

Discussion

PTC often results in distant metastases in the lungs and bones. It may sometimes lead to metastases in the brain or

Table 2 Summary of cases of cardiac metastasis from thyroid carcinoma reported since 2011

Case	Age (years)	Sex	Histology	Location of cardiac metastasis	Treatment for cardiac metastasis	Outcome	Year	Citation
1	70	M	PDTC with clear cells features	Right ventricle	Heart surgery	Death; 3 weeks	2011	(9)
2	54	F	PTC, tall cell variant	Right atrium	Heart surgery	Alive; 2 years	2012	(10)
3	76	M	PTC	Apical septum	UN	UN	2013	(11)
4	52	M	HCTC	Left atrium	UN	UN	2014	(12)
5	57	F	Squamous cell carcinoma	Ventricular septum	Paclitaxel and concurrent irradiation, lenvatinib	Death; 2 months	2017	(13)
6	58	UN	Clear cell thyroid cancer	Right atrium	Heart surgery	Alive	2017	(14)
7	52	F	FTC, oncocytic variant	Apical septum	Heart surgery	Alive	2018	(15)
8	49	F	MTC	Atrial septum	UN	UN	2020	(16)
9	70	F	FTC	Left atrium	Heart surgery	Alive	2020	(17)
10	69	F	ATC	Right ventricle	UN	UN	2021	(18)
11	61	M	ATC	Right atrium	UN	UN	2021	(18)
12	57	F	FTC	Left ventricle	Heart surgery	Alive	2021	(19)
13	63	F	HCTC	Right atrial septum	Heart surgery	Alive; 8 years	2021	(20)
14	45	F	MTC	Right ventricular apex	Vandetanib	Alive; 13 years	2021	(21)
15	63	F	MTC	Right ventricle and atrium	Vandetanib, heart surgery	Death; 6 years	2021	(21)
16	76	F	MTC	Right ventricle	Heart surgery	Death; 40 months	2022	(22)

M, male; PDTC, poorly differentiated thyroid carcinoma; F, female; PTC, papillary thyroid carcinoma; UN, unknown; HCTC, Hurthle cell thyroid carcinoma; FTC, follicular thyroid carcinoma; MTC, medullary thyroid carcinoma; ATC, anaplastic thyroid carcinoma.

skin; however, cardiac metastases are extremely rare (1,7). In a literature review of cardiac metastasis published in 2011, 55 cases over a 130-year period were found. The most common histologic type of thyroid carcinoma with cardiac metastasis was anaplastic carcinoma, but it was also found in papillary, follicular, poorly differentiated, and medullary carcinomas. Average survival from the detection of cardiac metastases was 12.5 weeks. All patients with at least short-term survival had undergone cardiac surgery (8). Therefore, surgery is recommended in operable cases. Since 2011, 16 cases of cardiac metastasis from thyroid cancer have been reported, and many of the long-term survivors also underwent cardiac surgery (9-22) (*Table 2*). Combined with the literature review in 2011, the most common histologic types were ATC in 12 cases, followed by PTC in 10 and follicular thyroid carcinoma (FTC) in 9 cases (*Figure 4*). In contrast, systemic therapy for thyroid cancer has become

well-established in recent years, and its use in two instances of cardiac metastasis from medullary thyroid carcinoma has been reported. Vandetanib therapy was successful in patients for 4 and >11 years (21). To our knowledge, however, only vandetanib therapy for medullary carcinoma has been shown to be effective in treating thyroid cancer with cardiac metastasis.

Although cardiac metastases are often not recognized or checked for, they are likely to be found incidentally on CT scans. Echocardiography and CMR are useful methods for scrutinizing cardiac metastasis (8). CMR provides high-resolution assessment of anatomical sites and cardiac function. In a report examining CMR in various carcinomas, excluding thyroid cancer, 22% of cardiac metastatic cases involved multiple cardiac chambers. Additionally, right-sided chamber involvement was prevalent in hematogenous and lymphatic metastases, whereas the placement of the

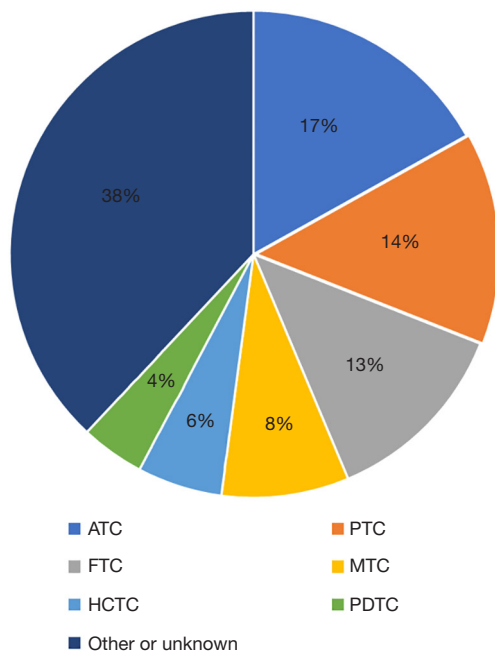


Figure 4 Histology of cardiac metastasis. ATC, anaplastic thyroid carcinoma; PTC, papillary thyroid carcinoma; FTC, follicular thyroid carcinoma; MTC, medullary thyroid carcinoma; HCTC, Hurthle cell thyroid carcinoma; PDTC, poorly differentiated thyroid carcinoma.

pericardium was common in direct invasion (23). Further, medullary thyroid cancer diagnosis using immuno-positron emission tomography scan with anti-carcinoembryonic antigen bispecific antibody and gallium-68-labeled peptide has been reported to be successful (21).

In this case, it was necessary to start medical treatment as soon as possible because the condition was fatal. As lenvatinib is the first-line drug for papillary thyroid cancer with an unknown driver gene, it was started immediately. We switched to selpercatinib as the *RET* fusion gene was found to be the driving gene. We considered that the risk of fatal major bleeding events was lower with selpercatinib than with lenvatinib because there were no adverse events due to vascular rupture in the clinical trial of selpercatinib (5). Lenvatinib has been associated with fatal hemorrhagic episodes. In a single-center retrospective study, cutaneous fistulas formed in 34.4% of patients with ATC and 8.9% of those with DTC after lenvatinib therapy, of which 16.6% experienced major bleeding (24). However, no adverse events related to cardiac metastasis have been reported with lenvatinib. The response rate for thyroid cancer in clinical trials is 64.7% for lenvatinib and 79% for selpercatinib,

both of which are very high (3,5). Selpercatinib has a known resistance mechanism (25), but the resistance mechanism for lenvatinib is unknown. Lenvatinib is a multikinase inhibitor (26) and is unlikely to develop resistance. In this case, after starting treatment with lenvatinib and selpercatinib, the tumor shrank and the symptoms improved. Therefore, it is considered that the treatments were effective, at least in the short term. However, due to the short follow-up period, it is not known whether the systemic therapy improves long-term prognosis.

Conclusions

This is the first case of cardiac metastasis of PTC treated successfully with systemic therapy. Conventionally, cardiac surgery was the primary treatment for cardiac metastasis; now, systemic therapy has emerged as a significant alternative. It is important to choose therapeutic drugs based on gene and adverse-event profiling.

Acknowledgments

The authors would like to thank Enago (<https://www.enago.jp/>) for the English language review.

Funding: None.

Footnote

Reporting Checklist: The authors have completed the CARE reporting checklist. Available at <https://gs.amegroups.com/article/view/10.21037/gS-23-252/rc>

Peer Review File: Available at <https://gs.amegroups.com/article/view/10.21037/gS-23-252/prf>

Conflicts of Interest: All authors have completed the ICMJE uniform disclosure form (available at <https://gs.amegroups.com/article/view/10.21037/gS-23-252/coif>). The authors have no conflicts of interest to declare.

Ethical Statement: The authors are accountable for all aspects of the work in ensuring that questions related to the accuracy or integrity of any part of the work are appropriately investigated and resolved. All procedures performed in this study were in accordance with the ethical standards of the institutional and/or national research committee(s) and with the Helsinki Declaration (as revised in 2013). Written informed consent was obtained from the

patient for publication of this case report and accompanying images. A copy of the written consent is available for review by the editorial office of this journal.

Open Access Statement: This is an Open Access article distributed in accordance with the Creative Commons Attribution-NonCommercial-NoDerivs 4.0 International License (CC BY-NC-ND 4.0), which permits the non-commercial replication and distribution of the article with the strict proviso that no changes or edits are made and the original work is properly cited (including links to both the formal publication through the relevant DOI and the license). See: <https://creativecommons.org/licenses/by-nc-nd/4.0/>.

References

- Schlumberger M, Leboulleux S. Current practice in patients with differentiated thyroid cancer. *Nat Rev Endocrinol* 2021;17:176-88.
- Brose MS, Nutting CM, Jarzab B, et al. Sorafenib in radioactive iodine-refractory, locally advanced or metastatic differentiated thyroid cancer: a randomised, double-blind, phase 3 trial. *Lancet* 2014;384:319-28.
- Schlumberger M, Tahara M, Wirth LJ, et al. Lenvatinib versus placebo in radioiodine-refractory thyroid cancer. *N Engl J Med* 2015;372:621-30.
- Pozdeyev N, Gay LM, Sokol ES, et al. Genetic Analysis of 779 Advanced Differentiated and Anaplastic Thyroid Cancers. *Clin Cancer Res* 2018;24:3059-68.
- Wirth LJ, Sherman E, Robinson B, et al. Efficacy of Selpercatinib in RET-Altered Thyroid Cancers. *N Engl J Med* 2020;383:825-35.
- Subbiah V, Hu MI, Wirth LJ, et al. Pralsetinib for patients with advanced or metastatic RET-altered thyroid cancer (ARROW): a multi-cohort, open-label, registrational, phase 1/2 study. *Lancet Diabetes Endocrinol* 2021;9:491-501.
- Durante C, Haddy N, Baudin E, et al. Long-term outcome of 444 patients with distant metastases from papillary and follicular thyroid carcinoma: benefits and limits of radioiodine therapy. *J Clin Endocrinol Metab* 2006;91:2892-9.
- Catford SR, Lee KT, Pace MD, et al. Cardiac metastasis from thyroid carcinoma. *Thyroid* 2011;21:855-66.
- Pazzano V, Narducci ML, Santangeli P, et al. Poorly differentiated thyroid carcinoma with cardiac metastasis and pulmonary embolism as first clinical presentation: case report and review of the literature. *J Endocrinol Invest* 2011;34:164-5.
- Kaul S, Tulchinsky M, Campbell DB, et al. Isolated cardiac metastasis from papillary thyroid cancer: prolonged survival with late diagnosis related to inadequate positron emission tomography preparation. *Thyroid* 2012;22:443-4.
- Yarmohammadi H, Tacher V, Faulhaber PF, et al. Imaging of dedifferentiated papillary thyroid carcinoma with left ventricular metastasis: A rare presentation of papillary thyroid metastatic disease. *J Cancer Res Ther* 2013;9:490-2.
- Giovanella L, Treglia G, Ceriani L, et al. Left atrial metastasis of Hürthle-cell thyroid carcinoma mimicking myxoma. *J Nucl Cardiol* 2014;21:406-7.
- Yoshihiro T, Tsuchihashi K, Kusaba H, et al. Cardiac metastasis of squamous cell carcinoma of the thyroid gland with severe disseminated intravascular coagulation: A case report. *Mol Clin Oncol* 2017;6:91-5.
- Martínez-Milla J, Cortés M, Lara JI, et al. Cardiac metastasis of clear cell thyroid cancer. *J Nucl Cardiol* 2017;24:2037-9.
- Stegger L, Rahbar K, Schülke C, et al. A Cardiac Metastasis of Follicular Thyroid Carcinoma With Partly Squamous Cell Differentiation: Detection in FDG-PET Preceded Visibility on Echocardiography and MRI by More Than a Year. *Clin Nucl Med* 2018;43:e473-4.
- El Ghannudi S, Germain P, Schneegans O, et al. Cardiac metastasis from medullary thyroid carcinoma: insights from multimodal molecular imaging and magnetic resonance imaging. *Eur Heart J Cardiovasc Imaging* 2020;21:231-2.
- Peng CH, Tai HC, Chung JY, et al. Thyroid Cancer With Cardiac Metastasis Presented With New Onset of Atrial Fibrillation. *J Acute Med* 2020;10:45-7.
- Cianciulli TF, Argento LV, Saccheri MC, et al. Cardiac metastasis from primary anaplastic thyroid carcinoma. *Medicina (B Aires)* 2021;81:637-40.
- Zieliński J, Kołsut P, Kuśmierczyk M, et al. Left ventricular wall invaded by thyroid cancer metastasis. *Kardiologia Pol* 2021;79:89-90.
- Blossey RD, Kleine-Döpke D, Ringe KI, et al. Recurrent Hurthle cell thyroid carcinoma does not preclude long-term survival: a case report and review of the literature. *J Med Case Rep* 2021;15:399.
- Buffet C, Leboulleux S, Kraeber-Bodéré F, et al. Cardiac Metastasis from Medullary Thyroid Cancers with Long-Term Survival under Vandetanib. *Eur Thyroid J* 2021;10:517-22.

22. Tricard J, Chermat A, Abdelkafi E, et al. Giant intracardiac medullary thyroid cancer metastasis. *J Card Surg* 2022;37:5455-6.
23. Pun SC, Plodkowski A, Matasar MJ, et al. Pattern and Prognostic Implications of Cardiac Metastases Among Patients With Advanced Systemic Cancer Assessed With Cardiac Magnetic Resonance Imaging. *J Am Heart Assoc* 2016;5:e003368.
24. Iwasaki H, Toda S, Murayama D, et al. Relationship between adverse events associated with lenvatinib treatment for thyroid cancer and patient prognosis. *Mol Clin Oncol* 2021;14:28.
25. Rosen EY, Won HH, Zheng Y, et al. The evolution of RET inhibitor resistance in RET-driven lung and thyroid cancers. *Nat Commun* 2022;13:1450.
26. Matsui J, Yamamoto Y, Funahashi Y, et al. E7080, a novel inhibitor that targets multiple kinases, has potent antitumor activities against stem cell factor producing human small cell lung cancer H146, based on angiogenesis inhibition. *Int J Cancer* 2008;122:664-71.

Cite this article as: Toda S, Yamamoto Y, Ookubo Y, Hayashi H, Tsunematsu T, Kadoya M, Masudo K, Iwasaki H. Lenvatinib and selpercatinib successfully treated RET fusion gene-positive papillary thyroid carcinoma cardiac metastases: a case report. *Gland Surg* 2023;12(10):1441-1448. doi: 10.21037/gS-23-252