



Surgical treatment of breast cancer related lymphedema—the combined approach: a literature review

Denis Drobot^{1^}, Assaf Aviram Zeltzer^{1,2^}

¹Department of Plastic and Reconstructive Surgery, Rambam Health Care Campus, Haifa, Israel; ²Bruce and Ruth Rappaport Faculty of Medicine, Technion, Israel

Contributions: (I) Conception and design: Both authors; (II) Administrative support: AA Zeltzer; (III) Provision of study materials or patients: Both authors; (IV) Collection and assembly of data: D Drobot; (V) Data analysis and interpretation: Both authors; (VI) Manuscript writing: Both authors; (VII) Final approval of manuscript: Both authors.

Correspondence to: Prof. Assaf Aviram Zeltzer, MD, PhD. Department of Plastic Surgery, Rambam Health Care Campus, HaAliya HaShniya St., 8, Haifa 3109601, Israel. Email: a_zeltzer@rambam.health.gov.il.

Background and Objective: Breast cancer therapy is a common cause of lymphedema, a chronic condition resulting from impaired fluid drainage through the lymphatic system. The accumulation of fluid in the affected limb leads to swelling, inflammation, and fibrosis, causing irreversible changes. While conservative therapy is the initial treatment for lymphedema, it may prove ineffective for advanced-stage cases that require surgical intervention. Physiological approaches such as lymphaticovenous anastomosis (LVA) and vascularized lymph node transfer (VLNT) aim to restore lymphatic circulation, while reductive approaches such as excision of excess tissue and liposuction (LS) aim to eliminate fibrofatty tissue. In advanced stages of breast cancer-related lymphedema, a treatment that incorporates both physiological and reductive methods is advantageous. The timing of these approaches varies, and recent simultaneous procedures have been introduced to address both aspects in one surgery. Additionally, lymphedema treatment can be combined with breast reconstruction. Current imaging techniques provide a better assessment of the lymphedematous limb, aiding in the tailoring of a personalized combined approach within a single surgery. This study aims to review the combined approach for breast cancer-related lymphedema treatment and propose a new therapeutic algorithm based on recent literature. The research aims to optimize the management of breast cancer-related lymphedema and improve patient outcomes.

Methods: PubMed/MEDLINE was used as the database to conduct a review of the currently available literature concerning combined surgical techniques for treating breast cancer related lymphedema (BCRL).

Key Content and Findings: In our review, we discuss imaging methods for assessing lymphatic system anatomy and function in surgical preparation and decision-making. Simultaneously, we examine a range of combined surgical techniques for treating BCRL, encompassing the combined physiologic approach, breast reconstruction with physiologic surgery, and the combination of reductive and physiologic procedures. Our emphasis remains on key parameters, including patient demographics, lymphedema staging, procedure types, follow-up duration, and objective limb measurements.

Conclusions: Surgical treatment of BCRL can include several surgical modalities that can be performed simultaneously. Current imaging techniques enable the tailoring of a personalized combined one-stage surgery for BCRL patients.

Keywords: Breast cancer; lymphedema; combined; treatment; surgery

Submitted Jun 12, 2023. Accepted for publication Dec 08, 2023. Published online Dec 22, 2023.

doi: 10.21037/gs-23-247

View this article at: <https://dx.doi.org/10.21037/gs-23-247>

[^] ORCID: Denis Drobot, 0000-0001-6149-8306; Assaf Aviram Zeltzer, 0000-0002-3465-0752.

Introduction

Breast cancer is the most diagnosed cancer among women globally, affecting around 1.38 million females annually (1). Lymphedema is a frequent iatrogenic complication in Western countries that commonly arises following lymphadenectomy as part of breast cancer treatment, and its risk is often amplified by adjuvant radiotherapy (2,3). The incidence of lymphedema is substantial in breast cancer therapy, with rates of 5.6% for sentinel lymph-node biopsy and 19.9% for axillary lymph node dissection (2).

Lymphedema is a chronic and incurable disease that results from an impaired drainage of interstitial fluid through the lymphatic system, leading to protein-rich fluid accumulation in the interstitial space (4). The accumulation of fluid not only causes regional swelling, inflammation, and fibrosis that can advance over time, but it also induces lipogenesis, fat deposition, and connective tissue overgrowth, which ultimately may result in irreversible induration of the affected area (5-7).

The primary treatment approach for lymphedema is conservative therapy, which encompasses a range of therapeutic modalities, including general measures such as limb elevation, exercise, and diet, as well as compression therapy and physiotherapy, such as manual lymphatic drainage (MLD) and complete decongestive therapy (CDT) (8-10). Conservative therapy frequently proves to be ineffective for individuals with late-stage, nonpitting lymphedema (9,11). Therefore, surgical intervention is employed for advanced lymphedema, as well as in combination with conservative treatment for earlier stages (12,13).

The management of lymphedema through surgery involves two different methods: physiological and reductive approaches. Two common techniques that follow a physiological approach are lymphaticovenous anastomosis (LVA) and vascularized lymph node transfer (VLNT). LVA works by creating a connection between high-pressure subcutaneous lymphatic vessels and low-pressure venules, thereby restoring local lymphatic circulation (12-15). On the other hand, VLNT involves the transplantation of functional lymph nodes to re-establish the natural flow of lymphatic fluid (15-17).

Significant reduction in limb volume can be achieved through these procedures, especially if they are conducted during the early stages of lymphedema, before the emergence of lymphatic sclerosis, soft tissue fibrosis, and excess fat deposition (18-20).

In cases of late-stage lymphedema, employing a reductive approach that focuses on eliminating the accumulated fibrofatty tissue can be highly advantageous. While excision of excess tissue and liposuction (LS), the primary methods utilized in this approach, yield significant and enduring reductions in limb volume, conservative therapy is necessary to maintain the results (21-23).

In advanced stages of breast cancer related lymphedema (BCRL), a combined treatment that involves both physiologic and reductive approaches could be advantageous (24-27). The literature presents variation in the timing of applying each therapeutic approach, and recently a simultaneous procedure that involves both approaches in one surgery has been introduced (28-31). Moreover, treatment of lymphedema could be achieved simultaneously with breast reconstruction (32). The purpose of this study is to review the topic of the combined approach for the treatment of breast cancer-related lymphedema and to suggest a new therapeutic algorithm based on recent literature. We present this article in accordance with the Narrative Review reporting checklist (available at <https://gs.amegroups.com/article/view/10.21037/ggs-23-247/rc>).

Methods

PubMed/MEDLINE was used as the database to conduct a review of the currently available literature concerning combined surgical techniques for treating BCRL (*Table 1*). Our search encompassed studies published between January 1, 2010, and April 20, 2023. The search terms utilized consisted of a combination of Medical Subject Heading (MeSH) terms and pertinent free-text words that were present in the titles or abstracts. The terms included in the initial query were “lymphedema”, “lymphoedema”, “breast cancer related lymphedema”, “breast cancer lymphedema”, “lymphaticovenular”, “microsurgery”, “anastomosis”, “lymphaticovenular anastomosis”, “lymph nodes”, “vascularized lymph node transfers”, “liposuction”, “reductive”, and “breast reconstruction”, for more detail, see *Table S1*. Additionally, we executed supplementary queries based on relevant reference information obtained from the searched articles.

The process of electronic searching, screening of titles and abstracts, and the inclusion of articles was undertaken by the first author (D.D.). Prior to the analysis of each selected article, relevant data was determined for extraction. For all the articles that were included, we recorded the number of patients, the stage of lymphedema, the type

Table 1 The search strategy summary

Items	Specification
Date of search	20/04/2023 to 27/05/2023
Databases and other sources searched	PubMed/MEDLINE
Search terms used	“Lymphedema”, “breast cancer lymphedema”, “microsurgery”, “anastomosis”, “lymphaticovenular anastomosis”, “lymph nodes”, “vascularized lymph node transfers”, “liposuction”, “reductive”, “breast reconstruction”
Timeframe	01/01/2010–20/04/2023
Inclusion and exclusion criteria	Inclusion criteria: studies that included more than one type of surgery in the treatment of BCRL Exclusion criteria: non-English articles
Selection process	The first author (D.D.) selected studies that included combined surgical approach for the treatment of BCRL
Additional considerations. Cited articles within relevant articles were also considered	Prior to analyzing each selected article, relevant data was determined for extraction. Results from each study were documented and verified by two independent reviewers (D.D. and A.A.Z.)

BCRL, breast cancer related lymphedema.

of surgery performed, and objective measurements of lymphedema.

The findings from each study were methodically documented and cross-verified by two independent reviewers (D.D. and A.A.Z.). Furthermore, the studies were categorized into three distinct surgical groupings (as detailed below), and their pertinent data was presented in *Tables 2–4*.

Clinical manifestation, indications and contraindications

Breast cancer therapy increases the risk of developing upper extremity lymphedema (2). During surveillance visits, it is important to closely monitor these patients and refer them for early intervention upon diagnosis, as symptoms of lymphedema tend to progress over time, with limb volume increasing rate of 1.80–15.8%/year (44). Most patients will present with symptoms within the first three years of breast cancer therapy (45,46). Further, with continued fluid stasis, the lymphatic system becomes overloaded, leading to pitting edema followed by non-pitting edema, fat deposition, and fibrosis, which is frequently permanent (stage 2 and 3) (6,8).

Combined treatment that involves several physiologic and reductive modalities in one surgery, with or without simultaneous ipsilateral autologous breast reconstruction, is indicated in patients with advanced stage postmastectomy

lymphedema, stages II–III according to the International Society of Lymphology (ISL), with deposition of fat and fibrotic tissue, refractory to conservative treatment. Combined treatment is contraindicated in patients with active cellulitis, open wounds in the lymphedematous arm, untreated or uncontrolled primary cancer, or those who are medically unfit to undergo surgery safely, or those who are not compliant with conservative therapy. These indications and contraindications are comparable to those that are used for surgical multimodal lymphedema treatment (24,25,27).

Preoperative clinical assessment and imaging

Preoperative evaluation of the patient’s lymphedema includes clinical examination and measurement of the limb volume. Out of convenience, the most common method uses a tape for limb circumferential measurements for applying the truncated cone formula. There are also less common techniques such as water displacement volumetry and perometry (7,8).

Lymphoscintigraphy, which is regarded as the gold standard for diagnosing lymphedema, provides information regarding both lymphatic anatomy and function (7,8). This information could assist in choosing the appropriate physiological surgery (24). While LVA requires functioning lymphatics, VLNT could be performed also when lymphatic channels are obstructed (24,25). Moreover, it

Table 2 Combined physiologic approach

Author (reference)	Patients	Lymphedema stage	VLNT type	Number of LVA performed	Average follow up time (months)	Objective limb measurements (mean)
Masia (33)	40	N/A	SCIP/SIEA	N/A (range, 1–7)	18 m	Excess circumference reduction rate: N/A (range, 12–86.7%) Circumference reduction: N/A (range, 0.9–6.1 cm)
Chang (34)	33	2.78 (ICG staging)	SCIP/SIEA (part of DIEP)	1.5 (range, 1–4)	19.7 m	Excess volume reduction: 60.4%
Beederman (15)	N/A, 104 (SUEL group)	N/A, SUEL group: 1.7 (ISL); 2.8 (ICG staging)	SC/LT/GR	N/A, 2.8 (UX group)	SUEL group: 61 patients (3 m); 28 patients (6 m); 38 patients (12 m); 14 patients (24–48 m)	Excess volume reduction: N/A, 25.7% (UX group at 12 m)
Chu (35)	4	2.37 (ICG staging)	SCIP/SIEA (part of DIEP)	N/A	N/A, research group (15.8 m)	Excess volume reduction: 39.4% (range, 4.2–44.8%)
Garza (36)	N/A, 120 (SUEL group)	N/A, total group: 1.8 (ISL); 3 (ICG staging)	SC/LT/GR	N/A, 2.5 (VLNT + LVA group)	SUEL group: 45 patients (3 m); 16 patients (6 m); 34 patients (12 m); 14 patients (24 m)	Average reduction in volume differential: N/A, 23.1% at 12 m (SUEL group)
Masià (37)	44	N/A	SCIP/SIEA	N/A (range, 1–7)	N/A, research group (16 m)	Excess circumference reduction rate: N/A (range, 12–89.6%), Circumference reduction: N/A (range, 0.9–6.1 cm)

VLNT, vascular lymph node transfer; LVA, lymphaticovenular anastomosis; N/A, not applicable; SCIP, superficial circumflex iliac artery perforator; SIEA, superficial inferior epigastric artery; ICG staging, according to the M.D. Anderson classification; DIEP, deep inferior epigastric perforator flap; SUEL, secondary upper extremity lymphedema; ISL, International Society of Lymphology staging system; SC, supraclavicular; LT, lateral thoracic; GR, groin; UX, upper extremity.

can be integrated with computed tomography for reverse lymphatic mapping and three dimensional localization of lymph nodes prior to VLNT (47).

Indocyanine green (ICG) lymphography enables examining the function of the superficial peripheral lymphatic system prior to surgery. Several lymphedema staging systems are based on this imaging method, and they could potentially assist in guiding treatment protocols (25,27). This technique assists identifying potential functional lymphatic vessels for LVA or for recipient site of VLNT (48). Performing reverse lymph node mapping prior to VLNT can help identify and avoid critical lymph nodes responsible for lymphatic drainage from the donor site, and also reduce the risk of lymphatic damage during suction-assisted lipectomy (8,47,48).

Magnetic resonance lymphangiography (MRL) is a

precise technique for imaging and 3D mapping of both superficial and deep lymphatic channels, as well as adjacent structures like veins in the lymphedematous limb. It can offer extensive information that may assist in surgical decision-making, enhancing pre-surgical preparation, and leading to shorter surgery time and smaller incisions (48,49).

Combined surgical techniques

Combined physiologic approach

LVA is a microsurgical procedure that restores local lymphatic circulation by anastomosing a functional lymphatic vessel within a local vein in a lymphedematous limb (12–15). Briefly, the technique involves intradermal injection of ICG into the web spaces of the affected limb. Functional lymphatic vessels are stained along their path,

Table 3 Breast reconstruction combined with a physiologic surgery

Author (reference)	Patients	Lymphedema stage	Breast reconstruction	Physiologic approach	Average follow up time (months)	Objective limb measurements (mean)
Nguyen (38)	29	N/A	DIEP, n=12; TRAM, n=17	VLNT (SCIP/SIEA)	11 m	Excess volume reduction: 11% at 12 m
Chang (34)	54	2.83 (ICG staging)	DIEP	VLNT (SCIP/SIEA), n=54; LVA, n=33	20.5 m	Excess volume reduction at 12m: VLNT + LVA group: 60.4%; VLNT group: 57.8%
Engel (39)	15	1.75 (CLG) LVA group; 2.45 (CLG) VLNT group	DIEP/PAP	VLNT (GR), n=11; LVA, n=4	VLNT group (15.4 m); LVA group (6.4 m)	Circumferential difference: LVA group: 11.1%; VLNT group: 19.7% Circumferential reduction rate: LVA group: 11.6%; VLNT group: 24.9%
Masià (37)	16	N/A	DIEP/SIEA	VLNT (SCIP/SIEA) + LVA	N/A, research group (16 m)	Excess circumference reduction rate: N/A (range, 42–89.6%) Circumference reduction: N/A (range, 2.9–6.1 cm)
Chen (40)	10	N/A	DIEP, n=3; TRAM, n=7	VLNT (GR)	12 m	Circumference reductions at 12 m: 2.12 cm
Ciudad (27)	10	2 (ISL)	DIEP	VLNT (GE)	N/A, research group (26.4 m)	Circumferential reduction rates at 12 m: 56.5%
Chu (35)	3	2.16 (ICG staging)	DIEP	VLNT (SCIP/SIEA)	N/A, research group (15.8 m)	Excess volume reduction: 39.4% (range, 4.2–44.8%)
Saaristo (41)	9	N/A	DIEP/TRAM	VLNT (SCIP)	6 m	Circumferential difference at 6 m: antebrachium: 1.22 cm; brachium: 1 cm
Dancey (42)	18	N/A	DIEP	VLNT (GR)	14 m	N/A
Nahabedian (43)	9	N/A	DIEP/TRAM	VLNT (GR)	N/A	N/A

N/A, not applicable; DIEP, deep inferior epigastric perforator flap; TRAM, transverse rectus abdominus myocutaneous flap; VLNT, vascular lymph node transfer; SCIP, superficial circumflex iliac artery perforator; SIEA, superficial inferior epigastric artery; ICG staging, according to the M.D. Anderson classification; LVA, lymphaticovenular anastomosis; CLG, Cheng lymphedema grade; PAP, profunda artery perforator flap; GR, groin; ISL, International Society of Lymphology staging system; GE, gastroepiploic.

and lymphography can allow their mapping and precise identification during surgical exploration. A local vein is anastomosed to a chosen functional lymphatic vessel, and then intra-operative ICG lymphography can demonstrate its patency (12,13,50). LVA is indicated for early-stage lymphedema that is resistant to conservative therapy (24,25). The best results, which include circumference and volume reduction, are demonstrated in stages I and II, when lymphatics are still functioning and fibrofatty deposition is not dominant (12,20,26).

VLNT is a microsurgical procedure that involves the harvesting of a flap containing lymphatic tissue, along with its associated arteriovenous supply, and implanting it in a lymphedematous limb (25,50). It is hypothesized that the

implantation of healthy lymphatic tissue improves local lymphatic drainage through two main mechanisms. The first mechanism suggests that the flap acts as a local 'sponge' that drains local extracellular lymphatic fluid into the anastomosed vein (50,51). The second mechanism proposes that VLNT enhances lymphangiogenesis by releasing local growth factors such as vascular endothelial growth factor (VEGF-C) (41,50). These mechanisms do not require the recipient lymphedematous limb to have a functional lymphatic system, thus making VLNT a suitable procedure for treating late-stage lymphedema (24,25,27).

Possible recipient sites for VLNT include the wrist and the axilla. Opting for the axilla as the recipient site offers the advantage of concurrently releasing scar tissue in the

Table 4 Reductive procedure combined with a physiologic procedure

Author (reference)	Patients	Lymphedema stage	Physiologic procedure	Reductive procedure	Average follow up time (months)	Objective limb measurements (mean)
Ciudad (27)	38	3 (ISL)	LVA, n=36; VLNT (GE), n=2	ICG lymphography guided tumescent LS	N/A, (26.4 m for all research group)	Circumference reduction rate: LVA 85%; VLNT 75%
Leppäpuska (29)	21	2 (ISL)	VLNT (SCIP)	LS Dry, n=18; wet, n=3	48.9 m	Excess volume reduction: 87.7%, 691.7 cc
Ciudad (30)	12	2b-3 (ISL)	LVA	VASER and ICG lymphography guided tumescent LS	N/A, research group (14 m)	Circumference reduction rate 90%
Brazio (28)	6	2 (ISL)	VLNT (SC/GE/GR)/LVA	ICG lymphography guided tumescent LS	N/A, research group (9.8 m)	Excess volume reduction: 82%
Ciudad (31)	6	3 (ISL)	VLNT (GE)	RRPP	14.2 m	Circumference reduction rate 74.5%

ISL, International Society of Lymphology staging system; LVA, lymphaticovenular anastomosis; VLNT, vascular lymph node transfer; GE, gastroepiploic; ICG staging, according to the M.D. Anderson classification; LS, liposuction; N/A, not applicable; SCIP, superficial circumflex iliac artery perforator; VASER, vibration amplification of sound energy at resonance; ICG, indocyanine green; SC, supraclavicular; GR, groin; RRPP, radical reduction with perforator preservation.

axillary region, which can address potential axillary vein strictures and enhance the range of motion (52,53). This localized intervention serves to minimize the recurrence of contractures by introducing well-vascularized tissue to the radiated area, and it fosters local lymphangiogenesis to restore lost pathways for lymphatic drainage (53).

For patients lacking a functional lymphatic system capable of countering gravity-induced lymph flow, the wrist can be a beneficial recipient site. The local anatomy of the wrist capitalizes on the radial artery as a high-pressure afferent inflow conduit into the lymph node flap, while the cephalic vein functions as the low-pressure efferent drainage vessel (54). Although not achieving statistical significance, a comparison with the axilla as the recipient site reveals that the wrist recipient site exhibits superior improvements in quality of life, functionality, and the discontinuation of compression garments (55). This phenomenon could be explained by the proximity of the “pump mechanism” to the hand, leading to more effective local edema reduction. Despite the potential for a lesser lymphatic drainage effect, patients who prioritize the aesthetic aspect of their wrist can opt for the medial elbow as the recipient site (56).

A meta-analysis indicates no statistically significant difference in terms of limb circumference reduction rate or excess volume reduction between the wrist and axilla as recipient sites. Currently, there is no consensus on the optimal location for the recipient site for VLNT in patients with BCRL (55). Therefore, further prospective

randomized controlled trials comparing these two sites are strongly encouraged.

Several authors presented a combined physiologic approach that includes both LVA and VLNT in a single operation (*Table 2*) (15,33-35). Prior to surgery ICG lymphography is performed to evaluate the lymphedema stage according to M.D. Anderson classification. As the stage progresses, the imaging of patent lymphatic vessels decreases while the imaging of dermal backflow increases (20). LVA planning could be achieved only in the first 3 stages, when imaging of patent lymphatic vessels is demonstrated (15,34). MRL can also aid in evaluating lymphatic function and surgical planning (33). In cases of dysfunctional lymphatic system, a reductive approach could be proposed (33).

Performing LVA and VLNT in a single surgery (*Figure 1*) could result in synergistic benefits as they work through different mechanisms. LVA provides immediate postoperative improvement, while VLNT offers long-term lymphedema improvement by promoting lymphangiogenesis (15).

Breast reconstruction combined with a physiologic surgery

Post-mastectomy patients could benefit from autologous breast reconstruction, especially those who have already received radiotherapy (57,58). Microvascular breast

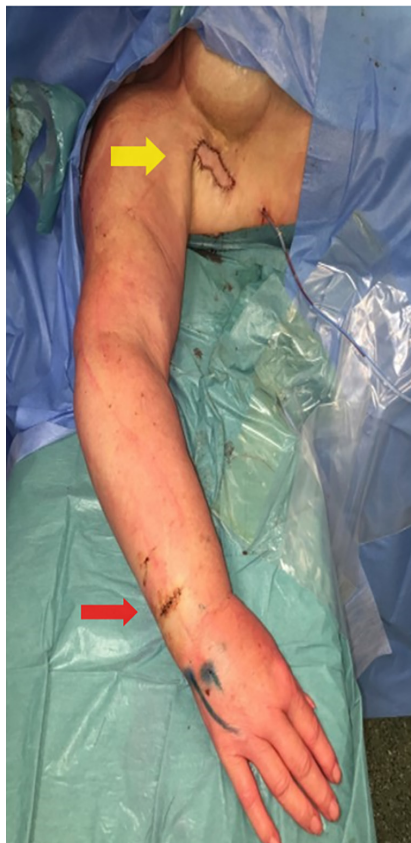

Figure 1 Combined physiological surgery including VLNT and LVA. A 62-year-old post mastectomy patient who suffers from pitting BCRL stage 2 (ISL). Combined physiologic surgical treatment was tailored for the patient, which included left lateral thoracic VLNT to the right axilla (yellow arrow) and distal LVA at the level of the wrist (red arrow). VLNT, vascular lymph node transfer; LVA, lymphaticovenular anastomosis; BCRL, breast cancer related lymphedema; ISL, International Society of Lymphology staging system.

reconstruction (MBR), which utilizes free lower abdominal flaps such as the deep inferior epigastric perforator (DIEP) flap and transverse rectus abdominis musculocutaneous (TRAM) flap, has demonstrated a lower incidence of BCRL and a possible reduction in lymphedema symptoms (59,60).

During the last decade, several authors have demonstrated a combined approach for treating post-mastectomy lymphedema patients, which involves breast reconstruction, VLNT, and scar release to restore the configuration and function of the breast (Table 3) (27,34,35,37-43). The advantage of this approach over a staged one is that the patient does not have to go through two major and time-

consuming surgeries. When the ICG lymphography pattern demonstrates patent lymphatics, some authors also combine LVA with no significant difference in operative time or hospital stay (Figure 1) (34,35). Although LVA provides immediate postoperative improvement, after 12 months, the improvement was equivocal to the control group (34).

The superficial groin lymph nodes are predominantly used as the donor site for VLNT in the combined approach (Figures 2,3) (27,34,35,37-40,42,43). As the groin lymph nodes drain the lymphatics of the leg, harvesting them could result in iatrogenic lymphedema at the donor site, as demonstrated in previous reports (61-63). Harvesting lymph nodes superior to the superficial circumflex iliac vein and lateral to the superficial inferior epigastric vein, which predominantly drain the lower abdomen, lower back, and upper gluteal region, may reduce this complication (64,65). Another method involves using reverse lymphatic mapping to locate and harvest lymph nodes that drain the abdomen while avoiding the harvesting of the sentinel lymph node that drains the ipsilateral leg (47).

Reductive procedure combined with a physiologic procedure

Chronic lymphedema is characterized by the deposition and hypertrophy of adipose tissue and fibrosis to a degree where pitting may be absent (7,66). While physiologic procedures can improve lymphatic drainage, they cannot remove the accumulated fat and fibrosis (28,66). Only a reductive approach can significantly reduce the amount of accumulated fibrofatty tissue (28,66). The main two reductive surgeries are LS and surgical excision.

LS in lymphedema is a modified surgery of the standard cosmetic technique for reducing fibrofatty content in lymphedema patients (30,50,67). While it is typically performed circumferentially, step-by-step from distal to proximal, performing it longitudinally can help reduce the risk of lymphatic injury (68,69). The tumescent technique has a better safety profile when compared to the wet and dry techniques, as it reduces the risk of iatrogenic lymphatic damage and blood loss (68-70). A systematic review showed that LS could reduce excess volume by more than 100%, but usually sustaining the results requires continuous compressive therapy (71,72). In some patients the use of compression garment could be reduced and even discontinued by applying VLNT (73,74). Other benefits of this procedure include improvement in the quality of life, skin blood flow, range of motion, decreased incidence of cellulitis in the affected extremity, as well as fewer inpatient

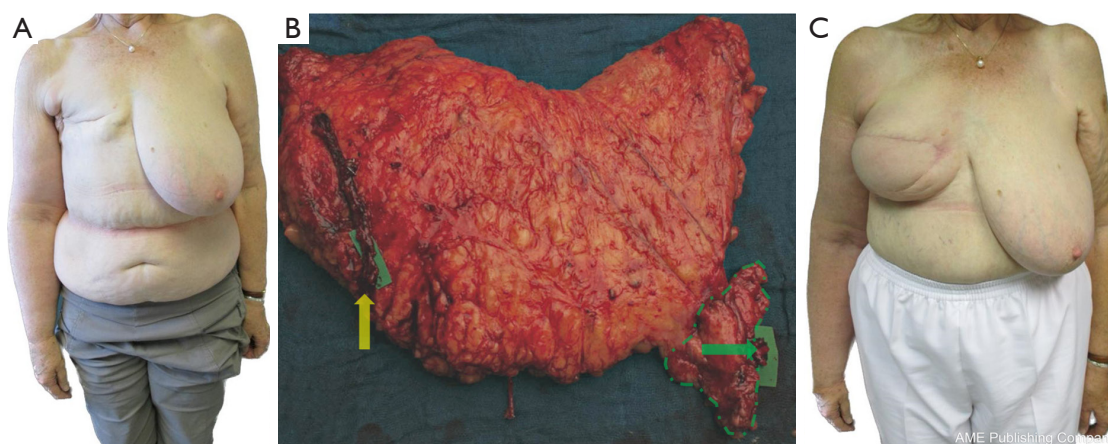


Figure 2 Breast reconstruction combined with VLNT. (A) A 68-year-old post mastectomy patient who suffers from BCRL stage 2 (ISL). (B) Breast reconstruction using DIEP free flap (yellow arrow point on its pedicle) with groin VLNT (the green line delimits its area; green arrow points on its pedicle) implanted to the axilla. (C) Patient at 6 months follow-up. VLNT, vascular lymph node transfer; BCRL, breast cancer related lymphedema; ISL, International Society of Lymphology staging system; DIEP, deep inferior epigastric perforator.

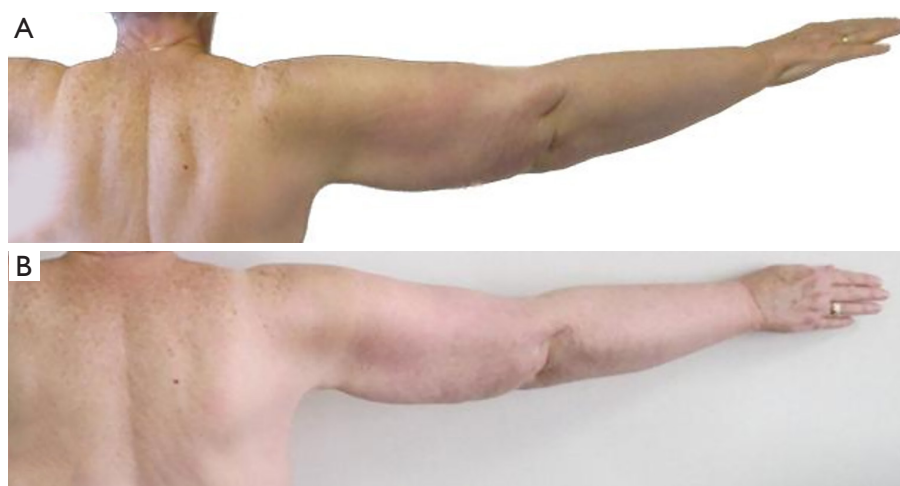


Figure 3 Limb volume after breast reconstruction combined with VLNT. (A) Per-operative image of the right lymphedematous hand. (B) Follow-up, 1 year after surgery. Excess volume reduction: 28%. VLNT, vascular lymph node transfer.

admissions for IV antibiotic therapy (66,67,72).

For patients who suffer from large volume, advanced-stage lymphedema with advanced fibrotic disease, LS could be ineffective, and surgical excisional debulking techniques could be beneficial.

Historically, these techniques include radical excision of skin, subcutaneous tissue, and part of the fibrotic fascia, followed by skin grafting (Charles procedure), and staged excision of subcutaneous tissue (Sistrunk, Homans, and Miller) (50,75-77). The disadvantages of those techniques include the recurrence of lymphedema, infections, skin graft

loss, and poor cosmetic results (75-77).

Radical reduction with perforator preservation (RRPP) is a modification of the traditional excisional techniques that applies the perforator flap concept. This technique involves the elevation of cutaneous flaps while preserving their supplying perforators, followed by the excision of the underlying subcutaneous tissue. This single-stage procedure offers long-lasting volume reduction and satisfactory cosmetic results (76-78).

In the treatment of advanced stages of BCRL, staged physiologic and reductive procedures are commonly

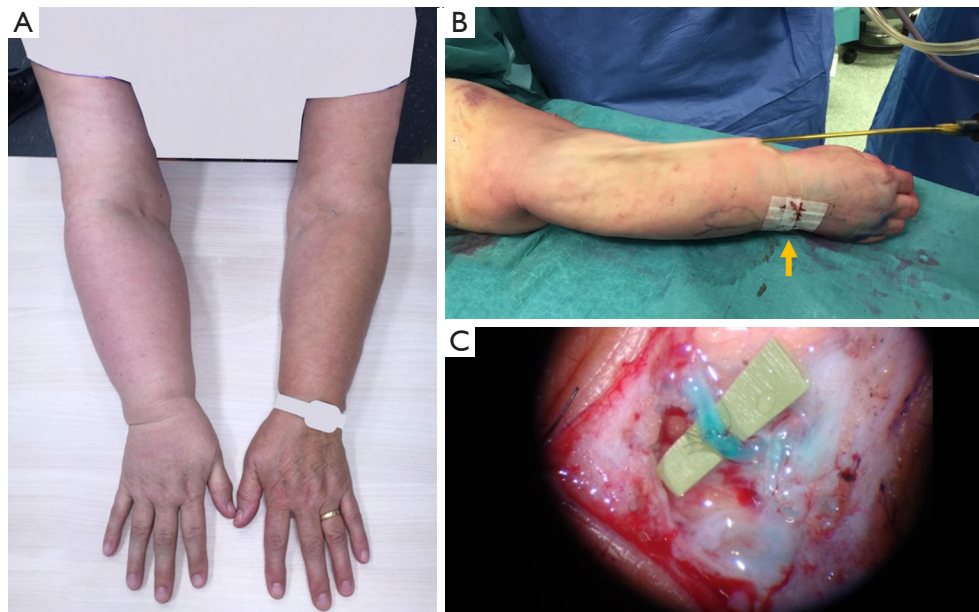


Figure 4 LS combined with LVA. (A) A 52-year-old post mastectomy patient who suffers from non-pitting BCRL stage 3 (ISL). MRL demonstrated predominant fat content thus a combined reductive with physiologic surgery was proposed (functional lymphatic vessels in the distal arm). (B,C) Per-operative images. LVA (C) was performed in the dorsal wrist (yellow arrow, B). LS, liposuction; LVA, lymphaticovenular anastomosis; BCRL, breast cancer related lymphedema; ISL, International Society of Lymphology staging system; MRL, magnetic resonance lymphangiography.

employed (79,80). Recently, several authors have described a combined approach that aims to restore physiological lymphatic drainage and reduce the accumulated excess fibrofatty tissue (*Figure 4, Table 4*) (27-31).

Discussion

The treatment of BCRL consists of several therapeutic modalities, initially including conservative measures such as compression therapy and physiotherapy (8,9). If unsatisfactory results are observed, the use of advanced diagnostic imaging is required to establish the most suitable surgical therapeutic approach (48,49). There is a consensus that LVA requires functional lymphatic vessels, which are typically found in the early stages of lymphedema but could also be found in late stages (12,14,15,20). On the other hand, VLNT can be applied at any stage, even with obstructed lymphatics (24,25,27). Physiologic surgeries aim to decrease extracellular lymphatic fluid, while the reductive approach focuses on removing accumulated fibrofatty tissue. Several therapeutic algorithms propose a logical staged approach for treating lymphedema while considering factors such as lymphedema clinical staging, ICG lymphography

staging and pre-operative mapping, lymphatic anatomy and function as demonstrated by lymphoscintigraphy and MRL, lymph-node donor site, and the possibility of breast reconstruction (24,25,27,78,81).

In this study, we present recent attempts in the literature to ‘bypass’ the reconstruction ladder in the treatment of BCRL by combining different therapies to decrease the total number of surgeries and to maximize therapeutic effect. This approach allows us to propose a new comprehensive therapeutic algorithm for the treatment of BCRL (*Figure 5*).

Physical examination is highly important for lymphedema staging as it can provide a rough indication of the content that fills the edematous limb. While pitting edema suggests that the dominant content of the edematous limb consists of extracellular lymphatic fluid, which correlates with early-stage lymphedema, non-pitting edema suggests that the dominant content is of a fibrofatty nature, which correlates with advanced-stage lymphedema (6-8).

Imaging assessment of lymphatic system function is crucial for tailoring the best-matching surgical therapy for each patient. Lymphoscintigraphy provides a comprehensive evaluation of the lymphatic system’s function in the affected limb. It can reveal the presence of channels and lymph

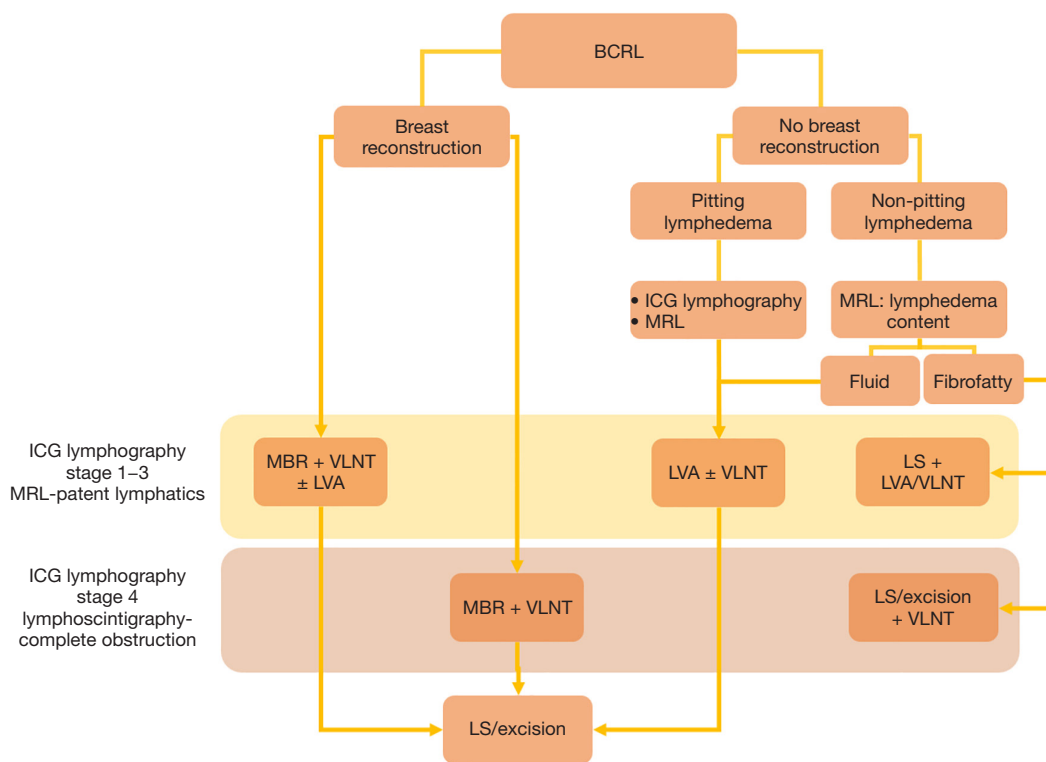


Figure 5 The combined approach for surgical treatment of breast cancer related lymphedema (algorithm). BCRL, breast cancer related lymphedema; ICG, indocyanine green; MRL, magnetic resonance lymphangiography; LVA, lymphaticovenous anastomosis; VLNT, vascularized lymph node transfer (including scar release for axilla as the recipient site); LS, liposuction; MBR, microvascular breast reconstruction; Excision, refers to procedures such as Charles procedure and radical reduction with perforator preservation.

nodes, track the tracer’s progression, and demonstrate abnormal circulation or patterns and/or dermal backflow (7,8). When lymphatic channels are demonstrated, LVA can be performed after precise localization of the channels using ICG lymphography or MRL (8,12,49). However, even in cases where there is a complete obstruction of lymphatic vessels and no lymphatic channels can be identified, one cannot be certain that functional channels are entirely absent. Additional imaging may be necessary to exclude the presence of functional lymphatics (82,83). ICG lymphography demonstrates a real-time function of the superficial lymphatic system by mapping contrast agent progression through the subdermal lymphatic collecting vessels (48). This allows planning a suitable location for performing LVA.

When severe dermal backflow pattern is observed with no visualization of patent lymphatic vessels (stage 4), performing LVA is discouraged (25,27). MRL is the most comprehensive imaging technique available for lymphatic evaluation. Its greatest advantage over other

modalities is its ability to provide a 3D evaluation of the entire tissue, including lymphatic vessels, veins, and the surrounding tissues (49). This enables detailed preoperative microsurgical planning and provides information about the nature of the edematous limb. When there is a predominant lymphatic content, a physiologic approach should be proposed, whereas when there is a predominant deposition of fibrofatty tissue, a reductive approach should be considered (28,49). When physiologic procedure alone does not result in a satisfactory result, a second reductive procedure should be considered.

BCRL patients who require breast reconstruction can benefit from a simultaneous physiological surgery (34,38). Imaging of patent lymphatic vessels can determine whether LVA should be performed. To our knowledge, a simultaneous reductive surgery such as LS or RRPP has never been performed in combination with breast reconstruction and a physiological surgery. Therefore, it could be offered as a subsequent surgery or, if possible, combined into a one-stage surgery.

It is important to understand that clinical staging assigns “one stage” to the entire limb, while the imaging staging can vary in different zones of the affected limb. Thus, the imaging based combined approach offers the most effective treatment in a single intervention.

Conclusions

Surgical treatment of BCRL can include several surgical modalities that can be performed simultaneously. Current imaging techniques enable the tailoring of a personalized combined one-stage surgery for BCRL patients.

Acknowledgments

Funding: None.

Footnote

Provenance and Peer Review: This article was commissioned by the Guest Editors (Tine Engberg Damsgaard, C. Andrew Salzberg and Jørn Bo Thomsen) for the series “Hot Topics in Breast Reconstruction World Wide” published in *Gland Surgery*. The article has undergone external peer review.

Reporting Checklist: The authors have completed the Narrative Review reporting checklist. Available at <https://gs.amegroups.com/article/view/10.21037/gS-23-247/rc>

Peer Review File: Available at <https://gs.amegroups.com/article/view/10.21037/gS-23-247/prf>

Conflicts of Interest: Both authors have completed the ICMJE uniform disclosure form (available at <https://gs.amegroups.com/article/view/10.21037/gS-23-247/coif>). The series “Hot Topics in Breast Reconstruction World Wide” was commissioned by the editorial office without any funding or sponsorship. The authors have no other conflicts of interest to declare.

Ethical Statement: The authors are accountable for all aspects of the work in ensuring that questions related to the accuracy or integrity of any part of the work are appropriately investigated and resolved. All clinical procedures described in this study were performed in accordance with the ethical standards of the institutional and/or national research committee(s) and with the Helsinki Declaration (as revised in 2013). Written informed consent

was obtained from the patients for the publication of this article and accompanying images.

Open Access Statement: This is an Open Access article distributed in accordance with the Creative Commons Attribution-NonCommercial-NoDerivs 4.0 International License (CC BY-NC-ND 4.0), which permits the non-commercial replication and distribution of the article with the strict proviso that no changes or edits are made and the original work is properly cited (including links to both the formal publication through the relevant DOI and the license). See: <https://creativecommons.org/licenses/by-nc-nd/4.0/>.

References

1. Jemal A, Bray F, Center MM, et al. Global cancer statistics. *CA Cancer J Clin* 2011;61:69-90.
2. DiSipio T, Rye S, Newman B, et al. Incidence of unilateral arm lymphoedema after breast cancer: a systematic review and meta-analysis. *Lancet Oncol* 2013;14:500-15.
3. Johnson AR, Kimball S, Epstein S, et al. Lymphedema Incidence After Axillary Lymph Node Dissection: Quantifying the Impact of Radiation and the Lymphatic Microsurgical Preventive Healing Approach. *Ann Plast Surg* 2019;82:S234-41.
4. Chevillet AL, McGarvey CL, Petrek JA, et al. The grading of lymphedema in oncology clinical trials. *Semin Radiat Oncol* 2003;13:214-25.
5. Mortimer PS. The pathophysiology of lymphedema. *Cancer* 1998;83:2798-802.
6. Grada AA, Phillips TJ. Lymphedema: Pathophysiology and clinical manifestations. *J Am Acad Dermatol* 2017;77:1009-20.
7. Warren AG, Brorson H, Borud LJ, et al. Lymphedema: a comprehensive review. *Ann Plast Surg* 2007;59:464-72.
8. The diagnosis and treatment of peripheral lymphedema: 2020 Consensus Document of the International Society of Lymphology. *Lymphology* 2020;53:3-19.
9. Thompson B, Gaitatzis K, Janse de Jonge X, et al. Manual lymphatic drainage treatment for lymphedema: a systematic review of the literature. *J Cancer Surviv* 2021;15:244-58.
10. Eyigör S, Cinar E, Caramat I, et al. Factors influencing response to lymphedema treatment in patients with breast cancer-related lymphedema. *Support Care Cancer* 2015;23:2705-10.
11. Lasinski BB. Complete decongestive therapy for treatment of lymphedema. *Semin Oncol Nurs* 2013;29:20-7.

12. Drobot A, Bez M, Abu Shakra I, et al. Microsurgery for management of primary and secondary lymphedema. *J Vasc Surg Venous Lymphat Disord* 2021;9:226-233.e1.
13. Qiu SS, Pruijboom T, Cornelissen AJM, et al. Outcomes following lymphaticovenous anastomosis (LVA) for 100 cases of lymphedema: results over 24-months follow-up. *Breast Cancer Res Treat* 2020;184:173-83.
14. Scaglioni MF, Fontein DBY, Arvanitakis M, et al. Systematic review of lymphovenous anastomosis (LVA) for the treatment of lymphedema. *Microsurgery* 2017;37:947-53.
15. Beederman M, Garza RM, Agarwal S, et al. Outcomes for Physiologic Microsurgical Treatment of Secondary Lymphedema Involving the Extremity. *Ann Surg* 2022;276:e255-63.
16. Cheng MH, Loh CYY, Lin CY. Outcomes of Vascularized Lymph Node Transfer and Lymphovenous Anastomosis for Treatment of Primary Lymphedema. *Plast Reconstr Surg Glob Open* 2018;6:e2056.
17. Schaverien MV, Asaad M, Selber JC, et al. Outcomes of Vascularized Lymph Node Transplantation for Treatment of Lymphedema. *J Am Coll Surg* 2021;232:982-94.
18. Ozturk CN, Ozturk C, Glasgow M, et al. Free vascularized lymph node transfer for treatment of lymphedema: A systematic evidence based review. *J Plast Reconstr Aesthet Surg* 2016;69:1234-47.
19. Chung JH, Baek SO, Park HJ, et al. Efficacy and patient satisfaction regarding lymphovenous bypass with sleeve-in anastomosis for extremity lymphedema. *Arch Plast Surg* 2019;46:46-56.
20. Chang DW, Suami H, Skoracki R. A prospective analysis of 100 consecutive lymphovenous bypass cases for treatment of extremity lymphedema. *Plast Reconstr Surg* 2013;132:1305-14.
21. Miller TA, Wyatt LE, Rudkin GH. Staged skin and subcutaneous excision for lymphedema: a favorable report of long-term results. *Plast Reconstr Surg* 1998;102:1486-98; discussion 1499-501.
22. Schaverien MV, Munnoch DA, Brorson H. Liposuction Treatment of Lymphedema. *Semin Plast Surg* 2018;32:42-7.
23. Granoff MD, Pardo J, Singhal D. Power-Assisted Liposuction: An Important Tool in the Surgical Management of Lymphedema Patients. *Lymphat Res Biol* 2021;19:20-2.
24. Carl HM, Walia G, Bello R, et al. Systematic Review of the Surgical Treatment of Extremity Lymphedema. *J Reconstr Microsurg* 2017;33:412-25.
25. Schaverien MV, Coroneos CJ. Surgical Treatment of Lymphedema. *Plast Reconstr Surg* 2019;144:738-58.
26. Chang DW, Dayan J, Greene AK, et al. Surgical Treatment of Lymphedema: A Systematic Review and Meta-Analysis of Controlled Trials. Results of a Consensus Conference. *Plast Reconstr Surg* 2021;147:975-93.
27. Ciudad P, Bolletta A, Kaciulyte J, et al. The breast cancer-related lymphedema multidisciplinary approach: Algorithm for conservative and multimodal surgical treatment. *Microsurgery* 2023;43:427-36.
28. Brazio PS, Nguyen DH. Combined Liposuction and Physiologic Treatment Achieves Durable Limb Volume Normalization in Class II-III Lymphedema: A Treatment Algorithm to Optimize Outcomes. *Ann Plast Surg* 2021;86:S384-9.
29. Leppäpuska IM, Suominen E, Viitanen T, et al. Combined Surgical Treatment for Chronic Upper Extremity Lymphedema Patients: Simultaneous Lymph Node Transfer and Liposuction. *Ann Plast Surg* 2019;83:308-17.
30. Ciudad P, Manrique OJ, Bustos SS, et al. Single-stage VASER-assisted liposuction and lymphatic-venous anastomoses for the treatment of extremity lymphedema: a case series and systematic review of the literature. *Gland Surg* 2020;9:545-57.
31. Ciudad P, Manrique OJ, Adabi K, et al. Combined double vascularized lymph node transfers and modified radical reduction with preservation of perforators for advanced stages of lymphedema. *J Surg Oncol* 2019;119:439-48.
32. Schaverien MV, Chang EI. Combined deep inferior epigastric artery perforator flap with vascularized groin lymph node transplant for treatment of breast cancer-related lymphedema. *Gland Surg* 2021;10:460-8.
33. Masia J, Pons G, Nardulli ML. Combined Surgical Treatment in Breast Cancer-Related Lymphedema. *J Reconstr Microsurg* 2016;32:16-27.
34. Chang EI, Ibrahim A, Liu J, et al. Optimizing Quality of Life for Patients with Breast Cancer-Related Lymphedema: A Prospective Study Combining DIEP Flap Breast Reconstruction and Lymphedema Surgery. *Plast Reconstr Surg* 2020;145:676e-85e.
35. Chu CK, Hanasono MM, Chang EI. Treatment of multiple limb lymphedema with combined supermicrosurgical techniques. *Microsurgery* 2023;43:13-9.
36. Garza RM, Beederman M, Chang DW. Physical and Functional Outcomes of Simultaneous Vascularized Lymph Node Transplant and Lymphovenous Bypass in the Treatment of Lymphedema. *Plast Reconstr Surg* 2022;150:169-80.

37. Masià J, Pons G, Rodríguez-Bauzá E. Barcelona Lymphedema Algorithm for Surgical Treatment in Breast Cancer-Related Lymphedema. *J Reconstr Microsurg* 2016;32:329-35.
38. Nguyen AT, Chang EI, Suami H, et al. An algorithmic approach to simultaneous vascularized lymph node transfer with microvascular breast reconstruction. *Ann Surg Oncol* 2015;22:2919-24.
39. Engel H, Lin CY, Huang JJ, et al. Outcomes of Lymphedema Microsurgery for Breast Cancer-related Lymphedema With or Without Microvascular Breast Reconstruction. *Ann Surg* 2018;268:1076-83.
40. Chen R, Mu L, Zhang H, et al. Simultaneous breast reconstruction and treatment of breast cancer-related upper arm lymphedema with lymphatic lower abdominal flap. *Ann Plast Surg* 2014;73 Suppl 1:S12-7.
41. Saaristo AM, Niemi TS, Viitanen TP, et al. Microvascular breast reconstruction and lymph node transfer for postmastectomy lymphedema patients. *Ann Surg* 2012;255:468-73.
42. Dancey A, Nassimizadeh A, Nassimizadeh M, et al. A chimeric vascularised groin lymph node flap and DIEP flap for the management of lymphoedema secondary to breast cancer. *J Plast Reconstr Aesthet Surg* 2013;66:735-7.
43. Nahabedian MY. Microvascular breast reconstruction and lymph node transfer for postmastectomy lymphedema patients. *Gland Surg* 2012;1:1-2.
44. Casley-Smith JR. Alterations of untreated lymphedema and its grades over time. *Lymphology* 1995;28:174-85.
45. McDuff SGR, Mina AI, Brunelle CL, et al. Timing of Lymphedema After Treatment for Breast Cancer: When Are Patients Most At Risk? *Int J Radiat Oncol Biol Phys* 2019;103:62-70.
46. Petrek JA, Senie RT, Peters M, et al. Lymphedema in a cohort of breast carcinoma survivors 20 years after diagnosis. *Cancer* 2001;92:1368-77.
47. Dayan JH, Dayan E, Smith ML. Reverse lymphatic mapping: a new technique for maximizing safety in vascularized lymph node transfer. *Plast Reconstr Surg* 2015;135:277-85.
48. Du X, Liu C. Application of imaging in lymphedema surgical therapies. *Gland Surg* 2020;9:582-8.
49. Zeltzer AA, Brussaard C, Koning M, et al. MR lymphography in patients with upper limb lymphedema: The GPS for feasibility and surgical planning for lymphovenous bypass. *J Surg Oncol* 2018;118:407-15.
50. Gallagher KK, Lopez M, Iles K, et al. Surgical Approach to Lymphedema Reduction. *Curr Oncol Rep* 2020;22:97.
51. Cheng MH, Huang JJ, Wu CW, et al. The mechanism of vascularized lymph node transfer for lymphedema: natural lymphaticovenous drainage. *Plast Reconstr Surg* 2014;133:192e-8e.
52. Montag E, Okada AY, Arruda EGP, et al. Influence of vascularized lymph node transfer (VLNT) flap positioning on the response to breast cancer-related lymphedema treatment. *Rev Col Bras Cir* 2019;46:e2156.
53. Garza R 3rd, Skoracki R, Hock K, et al. A comprehensive overview on the surgical management of secondary lymphedema of the upper and lower extremities related to prior oncologic therapies. *BMC Cancer* 2017;17:468.
54. Lin CH, Ali R, Chen SC, et al. Vascularized groin lymph node transfer using the wrist as a recipient site for management of postmastectomy upper extremity lymphedema. *Plast Reconstr Surg* 2009;123:1265-75.
55. Chocron Y, Azzi AJ, Bouhadana G, et al. Axilla versus Wrist as the Recipient Site in Vascularized Lymph Node Transfer for Breast Cancer-Related Lymphedema: A Systematic Review and Meta-Analysis. *J Reconstr Microsurg* 2022;38:539-48.
56. Cheng MH, Chen SC, Henry SL, et al. Vascularized groin lymph node flap transfer for postmastectomy upper limb lymphedema: flap anatomy, recipient sites, and outcomes. *Plast Reconstr Surg* 2013;131:1286-98.
57. Yun JH, Diaz R, Orman AG. Breast Reconstruction and Radiation Therapy. *Cancer Control* 2018;25:1073274818795489.
58. Yoshimoto H, Hamuy R. Breast Reconstruction After Radiotherapy. *Adv Wound Care (New Rochelle)* 2014;3:12-5.
59. Chang DW, Kim S. Breast reconstruction and lymphedema. *Plast Reconstr Surg* 2010;125:19-23.
60. Mehrara B. Reduced incidence of breast cancer-related lymphedema following mastectomy and breast reconstruction versus mastectomy alone. *Breast Dis* 2013;24:259-60.
61. Sulo E, Hartiala P, Viitanen T, et al. Risk of donor-site lymphatic vessel dysfunction after microvascular lymph node transfer. *J Plast Reconstr Aesthet Surg* 2015;68:551-8.
62. Pons G, Masià J, Loschi P, et al. A case of donor-site lymphoedema after lymph node-superficial circumflex iliac artery perforator flap transfer. *J Plast Reconstr Aesthet Surg* 2014;67:119-23.
63. Vignes S, Blanchard M, Yannoutsos A, et al. Complications of autologous lymph-node transplantation for limb

- lymphoedema. *Eur J Vasc Endovasc Surg* 2013;45:516-20.
64. Zeltzer AA, Anzarut A, Braeckmans D, et al. The vascularized groin lymph node flap (VGLN): Anatomical study and flap planning using multi-detector CT scanner. The golden triangle for flap harvesting. *J Surg Oncol* 2017;116:378-83.
 65. Tourani SS, Taylor GI, Ashton MW. Anatomy of the superficial lymphatics of the abdominal wall and the upper thigh and its implications in lymphatic microsurgery. *J Plast Reconstr Aesthet Surg* 2013;66:1390-5.
 66. Brorson H. Liposuction in Lymphedema Treatment. *J Reconstr Microsurg* 2016;32:56-65.
 67. Granzow JW. Lymphedema surgery: the current state of the art. *Clin Exp Metastasis* 2018;35:553-8.
 68. Brorson H, Ohlin K, Svensson B. The facts about liposuction as a treatment for lymphoedema. *Journal of Lymphoedema* 2008;3:38-47.
 69. Hoffmann JN, Fertmann JP, Baumeister RG, et al. Tumescence and dry liposuction of lower extremities: differences in lymph vessel injury. *Plast Reconstr Surg* 2004;113:718-24; discussion 725-6.
 70. Klein JA. Tumescence technique for local anesthesia improves safety in large-volume liposuction. *Plast Reconstr Surg* 1993;92:1085-98; discussion 1099-100.
 71. Brorson H, Svensson H. Liposuction combined with controlled compression therapy reduces arm lymphedema more effectively than controlled compression therapy alone. *Plast Reconstr Surg* 1998;102:1058-67; discussion 1068.
 72. Forte AJ, Huayllani MT, Boczar D, et al. Lipoaspiration and Controlled Compressive Therapy in Lymphedema of the Upper Extremity: A Comprehensive Systematic Review. *Cureus* 2019;11:e5787.
 73. Agko M, Ciudad P, Chen HC. Staged surgical treatment of extremity lymphedema with dual gastroepiploic vascularized lymph node transfers followed by suction-assisted lipectomy—A prospective study. *J Surg Oncol* 2018;117:1148-56.
 74. Nicoli F, Constantinides J, Ciudad P, et al. Free lymph node flap transfer and laser-assisted liposuction: a combined technique for the treatment of moderate upper limb lymphedema. *Lasers Med Sci* 2015;30:1377-85.
 75. Sapountzis S, Ciudad P, Lim SY, et al. Modified Charles procedure and lymph node flap transfer for advanced lower extremity lymphedema. *Microsurgery* 2014;34:439-47.
 76. Salgado CJ, Mardini S, Spanio S, et al. Radical reduction of lymphedema with preservation of perforators. *Ann Plast Surg* 2007;59:173-9.
 77. Salgado CJ, Sassu P, Gharb BB, et al. Radical reduction of upper extremity lymphedema with preservation of perforators. *Ann Plast Surg* 2009;63:302-6.
 78. Ramachandran S, Chew KY, Tan BK, et al. Current operative management and therapeutic algorithm of lymphedema in the lower extremities. *Asian J Surg* 2021;44:46-53.
 79. Leung N, Furniss D, Giele H. Modern surgical management of breast cancer therapy related upper limb and breast lymphoedema. *Maturitas* 2015;80:384-90.
 80. Nardulli ML. Breast cancer-related lymphedema: focus on surgical treatment. *Plast Aesthet Res* 2020;7:15.
 81. Tobias T, Zeltzer AA. Current concepts of lymphedema treatment for the breast cancer patient: a clinical practice review. *Ann Breast Surg* 2023;7:8.
 82. Mihara M, Hara H, Araki J, et al. Indocyanine green (ICG) lymphography is superior to lymphoscintigraphy for diagnostic imaging of early lymphedema of the upper limbs. *PLoS One* 2012;7:e38182.
 83. O'Donnell TF Jr, Rasmussen JC, Sevic-Muraca EM. New diagnostic modalities in the evaluation of lymphedema. *J Vasc Surg Venous Lymphat Disord* 2017;5:261-73.

Cite this article as: Drobot D, Zeltzer AA. Surgical treatment of breast cancer related lymphedema—the combined approach: a literature review. *Gland Surg* 2023;12(12):1746-1759. doi: 10.21037/gs-23-247

Table S1 Search strategy (PubMed)

No.	Query	Results
3	(#1) AND (#2)	1,411
2	("anastomosis"[Title/Abstract] OR "lymphaticovenular"[Title/Abstract] OR "lymphaticovenular anastomosis"[Title/Abstract] OR "lymph nodes"[Title/Abstract] OR "vascularized lymph node transfers"[Title/Abstract] OR "liposuction"[Title/Abstract] OR "reductive"[Title/Abstract] OR "breast reconstruction"[Title/Abstract]) AND ((2010/1/1:2023/4/20[pdat]) AND (english[Filter]))	104,612
1	("lymphedema"[MeSH Terms] OR "lymphedema*" [Title/Abstract] OR "lymphoedema*" [Title/Abstract] OR "breast cancer related lymphedema*" [Title/Abstract] OR "breast cancer lymphedema*" [Title/Abstract]) AND ((2010/1/1:2023/4/20[pdat]) AND (english[Filter]))	8,878